WZ 3.L.50

BOSTON
MEDICAL LIBRARY
8 THE FENWAY

TEXT-BOOK

OF

OPERATIVE SURGERY

Digitized by the Internet Archive
in 2011 with funding from
Open Knowledge Commons and Harvard Medical School

http://www.archive.org/details/textbookofoperat02koch

TEXT-BOOK

OF

OPERATIVE SURGERY

BY

DR. THEODOR KOCHER

PROFESSOR OF SURGERY AND DIRECTOR OF THE SURGICAL CLINIC
IN THE UNIVERSITY OF BERN

THIRD ENGLISH EDITION

AUTHORISED TRANSLATION FROM THE FIFTH GERMAN EDITION

BY

HAROLD J. STILES, M.B., F.R.C.S. EDIN.

SURGEON TO THE CHALMERS HOSPITAL, EDINBURGH
SURGEON TO THE ROYAL EDINBURGH HOSPITAL FOR SICK CHILDREN
LECTURER ON APPLIED ANATOMY, UNIVERSITY OF EDINBURGH

AND

C. BALFOUR PAUL, M.B., F.R.C.S. EDIN.

ASSISTANT SURGEON, ROYAL EDINBURGH HOSPITAL FOR SICK CHILDREN

WITH 415 ILLUSTRATIONS

IN TWO VOLS.
VOL. II

NEW YORK
THE MACMILLAN COMPANY
LONDON: ADAM AND CHARLES BLACK
1911

23.4.30.

First English Edition (*translated from the Second German Edition*) *published in* 1895.
Second English Edition (*translated from the Fourth German Edition*) *published in* 1903.
Third English Edition published in 1911.

CONTENTS

SECTION V

Surgery of the Head and Trunk

A. SURGERY OF THE HEAD 383

1. *Soft Parts of the Scalp* 383

2. *The Face, including the Nose, Mouth and Fauces* 383

(*a*) *Surgery of the Eye and Orbit* 384

(*b*) *Surgery of the Nose and Associated Cavities* 384

1. Exposure of the Nasal Cavity and Sinuses 387
2. Naso-maxillary Route—Radical Operation for Pansinusitis Nasalis . . . 388
3. Bucco-nasal Route . . . 390
4. Opening the Maxillary Sinus (Antrum of Highmore) . . 390
5. Opening the Frontal Sinus . 391
6. Opening the Ethmoidal Sinuses 393

(*c*) *Surgery of the Jaws* 394

7. Resection of the Upper Jaw . 394
8. Osteoplastic Resection of the Upper Jaw 398
9. Osteoplastic Resection of Upper Jaw to expose the Base of the Skull 398
10. Removal of the Pituitary Body 400
11. Exposure of the Retro-maxillary Fossa . . . 400
12. Resection of the Lower Jaw . 400
13. Osteoplastic division of the Lower Jaw 403
14. Resection of the Temporo-maxillary Joint . . . 403

(*d*) *Surgery of the Auditory Organ* 404

15. Exposure of the Middle Ear . 404
16. Trephining the Mastoid Process (Schwartze's Operation) . . 405
17. Radical Operation on Middle Ear. 406
18. Suppuration of the Labyrinth 409
19. Operation for Intracranial Complications. 409
20. Trephining for Cerebral Abscess 409

(*e*) *Surgery of the Salivary Glands* 411

21. Submaxillary Salivary Gland . 411
22. Excision of the Parotid Gland . 411

(*f*) *Surgery of the Mouth and Pharynx* 413

23. Incisions into the Tongue and at the Floor of the Mouth . 414
24. Excision of the Tongue from the Mouth 414
25. Operation for Advanced Cancer of the Tongue. 417
26. Excision of the Tongue with simultaneous Resection of the Central Portion of the Jaw 420
27. Excision of the Tongue where there is Lateral Disease of the Jaw 420

28. Excision of a Carcinoma of the Base of the Tongue . . . 422
29. Operation for Cleft Palate . . 423
30. Tonsillotomy 423
31. Excision of Tumours of the Tonsils 423

B. SURGERY OF THE NECK 424

(*a*) *Normal Incisions in the Cervical Region* 424

32. Normal Incision for the Upper Lateral Triangle of the Neck 424
33. Normal Incision for the Inferior Lateral Triangle of the Neck . 427

(*b*) *Surgery of the Larynx* 427

34. Circumscribed Median Laryngotomy and Laryngectomy . 427
35. Partial Pharyngo-Laryngotomy . 428
36. Median Subhyoid Laryngo-Pharyngotomy . . . 428
37. Total Laryngectomy . . . 431
38. Tracheotomy 432
(*a*) High Tracheotomy (Crico-Tracheotomy) . . . 432
(*b*) Low Tracheotomy . . . 434

(*c*) *Surgery of the Pharynx and Œsophagus* 434

39. Subhyoid Pharyngotomy . . 434
40. Medio-Lateral Pharyngectomy (Retro-Laryngeal Resection of Pharynx) 435
41. Lateral Pharyngotomy . . 438
42. Œsophagotomy 440
43. Resection of the Œsophagus . 440
44. Pharyngoplasty and Œsophagoplasty 442
45. Surgery of the Retro-Pharyngeal Space 442
46. Radical Operation for Congenital Fistula in the Neck . 443
47. Operation for Spastic Torticollis 443
48. Exposure of the Thoracic Duct . 446

(*d*) *Surgery of the Thyroid Gland* 446

49. Indications for and Results of Operation for Goitre . . 446
50. Conditions influencing Extirpation of a Goitre . . . 447
51. Comparison with other Methods 449
52. Normal Procedure for Excision of a Movable Goitre . . . 449
53. Procedure in Difficult Cases . 456
54. Excision of a Median Goitre . 458
55. Enucleation of a Goitre . . 460
56. Resection of a Goitre . . . 461
57. Enucleation-Resection and Enucleation-Excision of a Goitre 462
58. Evacuation and Fragmentation of a Goitre 463
59. Operation for Intrathoracic Goitre 464
60. Excision of the Thyroid when Resection of the Sternum and Ribs is necessary . . . 466
61. Operation for Recurrent Goitre . 466
62. Excision of Exophthalmic Goitre 467
63. Ligature of the Thyroid Arteries 467
64. Excision of an Inflamed Goitre . 468
65. Excision of Malignant Tumours of the Thyroid . . . 469
66. Transplantation of the Thyroid Gland 469

(*e*) *Surgery of the Thymus Gland* 470

67. Excision of the Thymus Gland . 470

C. SURGERY OF THE THORAX 471

(*a*) *Surgery of the Thoracic Wall* 471

68. Amputation of the Mamma . 471
69. Operation for Cancer of the Breast 471
70. Radical Operation for Cancer of the Breast 472

(*b*) *Advances in the Surgery of the Thoracic Organs* 478

(*c*) *Prevention and Treatment of Traumatic Pneumothorax* 479

(*d*) *Drainage of the Thoracic Cavity* 482

(e) *Surgery of the Thoracic Wall* 483

71. Resection of Ribs . . . 483
72. Resection of Ribs for Tuberculosis 485
73. Resection of Ribs for Tumours . 485
74. Resection of the Sternum . . 486

(f) *Mediastinotomy* 488

75. Anterior Mediastinotomy . 488
76. Posterior Mediastinotomy . 489
77. Costo-Transversectomy . . 491

(g) *Pleurotomy* 492

78. Indications for Pleurotomy . 492
79. Pleurotomy for Empyema . 492
80. Treatment of Neglected Empyema 494
81. Treatment of Chronic Empyema 495

(h) *Pneumotomy* 498

82. Treatment of Pulmonary Suppuration 498
83. Surgical Treatment of Tuberculosis and Actinomycosis of the Lung and their Sequelæ . 499
84. Surgery of Tumours of the Lung 500
85. Surgery of Injuries of the Lung 501

(i) *Transpleural Operations* 502

86. Transpleural Laparotomy . . 502
87. Surgery of the Thoracic Portion of the Œsophagus . . . 503
88. Transpleural Œsophagotomy . 504
89. Transpleural Œsophago-gastrostomy 505
90. Transpleural Resection of the Œsophagus 505
91. Contraindications to Transpleural Œsophagotomy . . 506

D. ABDOMINAL SURGERY 506

(a) *Laparotomy* 506

92. Indications and Conditions necessary for Success . . 506
93. Position of Incisions and Methods of Suture in Laparotomy . . 509
94. Complications after Laparotomy 511
95. Laparotomy in Peritonitis . 513
96. Laparotomy in Abdominal Tuberculosis 516
97. Laparotomy for Peritoneal Adhesions 517

(b) *Operations for Hernia* 518

98. Radical Cure of Inguinal Hernia . 518
(a) Radical Operation in Uncomplicated Inguinal Hernia . 518
(b) Radical Operation in Complicated Inguinal Hernia . 523
(c) Radical Operation in very large Inguinal Hernia . 525
99. Radical Cure of Femoral Hernia 526
100. Radical Cure of Umbilical and Ventral Hernia . . . 528
(a) Ordinary Non-adherent Small and Medium-sized Umbilical Hernia 528
(b) Large Umbilical and Ventral Hernia 529

(c) *Surgery of the Gall-Bladder and Bile Ducts* 530

101. Summary and Development . 530
102. Indications for Operation, and Remarks on Technique . . 531
103. Cholecystostomy . . . 535
(a) When there is Pericystitis with Adhesions to the Abdominal Wall . . . 537
(b) When the Gall-Bladder is free or easily isolated . . 537
104. Cholecystotomy . . . 538
105. Cholecystectomy . . . 542
106. Cholecystenterostomy . . 545
107. Choledochotomy . . . 547
(a) In the free part of the Duct 547
(b) Retroduodenal . . . 548
108. Choledocholithotripsy . . 549
109. Choledocho-enterostomy . . 550
110. Duodenocholedochotomy and Duodenocholedochostomy . 550
(a) Transduodenal Choledocholithotomy 550

(*b*) Transduodenal Choledocho-duodenostomy . . . 551
111. Hepaticotomy and Hepatico-lithotripsy 552

(*d*) *Surgery of the Liver* 555

114. Surgical Treatment of Cirrhosis of the Liver 555
115. Talma's Operation for Ascites . 556
(*a*) Exo-epiplopexy and Simple Epiplopexy 557
(*b*) Splenopexy 557
112. Hepaticostomy and Hepatico-enterostomy . . . 553
113. External Hepatocholangiostomy and Hepatocholangioenterostomy 554
116. Hepatopexy 557
117. Liver Abscesses and Cysts . 558
118. Resection of the Liver . . 558
119. Ligature of the Hepatic Artery and Portal Vein . . . 561

(*e*) *Surgery of the Pancreas* 561

120. General Remarks . . . 561
121. Operations for Secondary Diseases of the Pancreas . . . 562
122. Intrinsic Operations on Pancreas 563
(*a*) Exposure of the Pancreas for Injury 563
(*b*) Drainage and Excision of Pancreatic Cysts . . . 563
(*c*) Extirpation of Solid Tumours of Pancreas 564
(*d*) Surgical Treatment of Acute Pancreatitis . . . 564
(*e*) Pancreolithotomy and Wirsungo-duodenostomy . 565

(*f*) *Surgery of the Spleen* 565

123. Splenotomy and Splenectomy . 565
124. Splenopexy (Rydygier) . . 566

(*g*) *Surgery of the Stomach* 566

125. General Remarks . . . 566
126. Gastroenterostomy — General Rules 567

(*a*) *Gastro-jejunostomia Inferior Longitudinalis* 568

127. Gastro-jejunostomia Antecolica Inferior Longitudinalis . . 568
128. Gastro-jejunostomia Retrocolica Inferior Longitudinalis . . 570

(*b*) *Gastro-jejunostomia Inferior Verticalis* 572

129. Gastro-jejunostomia Antecolica verticalis cum enteroanastomosi 575
130. Gastro-jejunostomia Retrocolica Inferior Verticalis Y-Formis . 576

(*c*) *Gastroduodenostomy* 579

131. Gastrectomy 585
(*a*) Partial Gastrectomy . . 586
132. Pylorectomy 586
133. Technique of Pylorectomy with Gastroduodenostomy . . 588
134. Pylorectomy with Gastro-jejunostomy 597
135. Pylorectomy by the Rydygier-Billroth Method, No. 1 . . 597
136. Pylorectomy after Henle, Mikulicz, and Rydygier . . 597
137. Irregular and Partial Circular Gastrectomy 598
138. Gastrectomy Associated with Resection of the Colon . . 599
139. Gastrectomy with Resection of the Cardia 599
(*b*) Total Gastrectomy . . 601
140. Technique of Total Gastrectomy 601
(*c*) Total Gastrectomy with Œsophago-duodenostomy . 602
(*d*) Total Gastrectomy with Œsophago-jejunostomy . 603
141. Gastroplasty 603
142. Gastrostomy 604
(*a*) Direct Gastrostomy . . 604
(*b*) Tavel's Jejuno-gastrostomy 608
(*c*) Roux's Œsophago-Jejuno-gastrostomy . . . 609

(*h*) *Surgery of the Intestines* 610

143. General Remarks on Intestinal Surgery 610
144. Enterostomy 611
(*a*) Temporary 611
(*b*) Permanent 611

145. Duodenostomy 614
146. Jejunostomy 616
147. Colostomy 617
148. Appendicostomy . . . 620
149. Entero-anastomosis and Intestinal Occlusion . . . 621
150. Lateral Anastomosis . . . 622
151. Entero-anastomosis with Unilateral or Bilateral Occlusion . 623
152. Intestinal Resection—General Remarks 625
153. Resection of Small Intestine . 627
154. Ileo-Cæcal Resection . . . 630
155. Resection of Large Intestine . 633

(*i*) *Surgery of the Rectum* 648

157. Excision of the Rectum, Indications 648
158. Technique of Amputation of the Rectum 650
(*a*) Lisfranc's Perineal Operation 650
(*b*) Kocher's Coccygeal Method with Posterior Median Incision 651
(*c*) Septic Excision of Rectum by a Longitudinal Incision through its Posterior Wall . 656
(*d*) Excision of Rectum with Vaginal Section . . . 657
159. Sacral Method of Amputating the Rectum 657
160. Combined Method of Amputation of the Rectum . . . 658
161. Resection of the Lower Part of the Pelvic Colon . . . 660
162. Excision of Hæmorrhoids . . 662
163. Operation for Prolapse of the Anus and Rectum . . . 663

(*k*) *Surgery of the Kidneys* 666

164. General Remarks . . . 666
165. Indications for Exposure of the Kidney and Ureter . . 666
166. Exposure of the Kidney with Division of the Capsule—Decortication—Nephropexy . 668
167. Nephrotomy, Nephrolithotomy, Pyelotomy . . . 671
168. Nephrectomy 672
(*a*) Lumbar 673
(*b*) Transperitoneal . . . 674
169. Excision of the Suprarenal Body 674

(*l*) *Surgery of the Ureter* 674

170. General Remarks . . . 674
171. Intraperitoneal Anastomosis of the Ureter with Ureter and Bladder 675
(*a*) Uretero-anastomosis . 675
(*b*) Uretero-cystostomy . . 675
(*c*) Uretero-trigono-sigmoidostomy 678
172. Extraperitoneal Operations on the Ureter 680
(*a*) Surgery of the Lumbo-renal Portion 680
(*b*) Surgery of the Abdomino-pelvic Portion . . . 682
(*c*) Surgery of the Intramural and Intravesical Portion . 682

(*m*) *Exposure of the Bodies of the Lumbar Vertebræ* 683

173. Lumbo-vertebrotomy . . 683

(*n*) *Surgery of the Bladder* 683

174. High (Suprapubic) Cystotomy . 683
175. High (Suprapubic) Cystostomy 686
176. Cystectomy, Total and Partial 687
(*a*) Resection of the Bladder (Suprapubic) . . . 687
(*b*) Total Excision of the Bladder (Suprapubic and Combined Method) . . 688
177. Perineal Cystotomy . . . 689

(*o*) *Surgery of the Prostate and Urethra* 689

178. General Remarks . . . 689
179. Prostatectomy 689
(*a*) Transvesical Enucleation of Prostate (Suprapubic) . 690
(*b*) Perineal Prostatectomy . 693
(*c*) Real Total Excision of Prostate 696
180. External Urethrotomy with Excision, and Plastic Operation 697

(*p*) *Surgery of the Male Reproductive Organs* 698

181. General Considerations . . 698
182. Castration 699
183. Operation for Varicocele . . 700
184. Operation for Hydrocele . . 700
185. Orchidopexy for Retention of the Testis 701
186. Vasectomy 701
187. Excision of the Seminal Vesicles — Total Castration including the Vasa Deferentia and Seminal Vesicles 702
188. Amputation of the Penis . . 703
189. Removal of Lymphatic Glands from the Groin, and from the Region of the Iliac and Obturator Vessels . . 704

(*q*) *Surgery of the Female Reproductive Organs* 704

190. The Alexander-Adams Operation 704
191. Exohysteropexy 706

APPENDIX 709

INDEX 715

ILLUSTRATIONS

SECTION V

Surgery of the Head and Trunk

FIG.		PAGE
255, 256.	Author's "Normal Incisions" for Head and Neck	384, 385
257.	Osteoplastic Exposure of the Orbit	386
258.	Paramedian Incision for Radical Operation on the Nasal Cavity	388
259.	Killian's Radical Operation on the Frontal Sinus	393
260.	Result after Complete Excision of the Upper Jaw	395
261, 262.	Result after Excision of both Upper Jaws for Phosphorus Necrosis	396, 397
263, 264.	Result after Excision of Lower Jaw and Photograph of Jaw removed	402
265.	Resection of Temporo-maxillary Joint through an Angular Incision	404
266.	Radical Operation on Middle Ear	407
267.	Exposure of the Middle Ear	408
268.	Opening the Mastoid Antrum and the Lateral Sinus	410
269.	Photograph showing Action of Facial Muscles after the Wound for splitting the Cheek transversely has healed	412
270.	Result after Excision of the Tongue by splitting the Cheek	413
271.	Instrument for forcibly separating the two Lobes of the divided Lower Jaw	414
272.	Author's Normal Operation for Advanced Cancer of the Tongue	419
273.	Küttner's Muscle Flap for Exposure of the Deep Structures in the Upper Part of the Anterior Triangle of the Neck	425
274.	Author's "Normal Incisions" for Face and Neck	426
275.	Quervain's Muscle Flap for exposing the Deep Structures of the Neck	426
276.	Subhyoid Pharyngo-laryngotomy for Disease on the Left Side of the Aditus Laryngis	429
277.	Subhyoid Laryngo-pharyngotomy	430
278.	High Tracheotomy	433
279.	Subhyoid Pharyngo-pharyngotomy	436
280.	Dissection by Tramond to illustrate the Relation of the Structures in Operations on the Palate and Pharynx	437
281.	Dissection to show the distribution of the Upper Cervical Nerves	444
282.	Dissection of the Muscles of the Neck (Tramond) to illustrate Relation of the Muscles, Vessels, and Nerves, in Author's Operation for Spasmodic Wry-neck	445
283.	Collar Incision for Excision of the Thyroid Gland	450
284, 285.	Dissections to show Veins and Muscles in Collar Incision for Excision of Thyroid Gland	451
286.	Excision of Thyroid Gland	452
287.	Goitre Crushing-forceps and their Application	453
288-293.	Excision of Goitre by the Angular Incision	454-459
294.	Enucleation-resection of a Hypertrophied Thyroid Nodule	462
295.	Goitre Dissector	463
296.	Goitre Forceps	465

FIG. PAGE
297. Goitre Spoon for releasing Intrathoracic Goitres 465
298. Skin Incision for Removal of a Carcinomatous Breast 472
299. Collins Warren's Incision for Radical Operation for Cancer of the Breast . . 473
300. Position of Patient in Radical Operation for Removal of the Breast . . . 474
301, 302. Radical Operation for Cancer of the Breast 475, 477
303. Simple Resection of Rib 483
304. Resection of Ribs to expose Surface of Liver 484
305. Incision of Osteoplastic Resection of the Manubrium Sterni 487
306. Osteoplastic Resection of Manubrium Sterni 488
307. Outline of Heart, Lungs, and Pleuræ (Spaltcholz-Merkel) 493
308. Relations of the Thoracic Viscera 494
309. Thoracotomy with Division of Nine Ribs for Fistula after Empyema . . 497
310. Resection of Ribs to expose Surface of the Liver 503
311. Transpleural Exposure of the Convex Surface of the Liver 504
312, 313-315. Radical Cure of Inguinal Hernia by Invagination-transposition Method 519, 520-522
316, 317. Lateral Transposition Method of Radical Cure of Inguinal Hernia . . 523, 524
318. Radical Cure of Femoral Hernia 527
319. Incision to expose the Gall-bladder and Bile Ducts 534
320. Hooked Incision for the Exposure of the Bile Passages in Difficult Cases . . 536
321. Cholecystotomy. Ligature of the Deep Circumflex Iliac, Common Iliac, and Common Femoral Arteries 540
322. Hepatico-duodenostomy (after Mayo) 553
323, 324. Plate, sutures (Payr) 560
325. Stomach Forceps 569
326. Gastrojejunostomia Retrocolica Verticalis 570
327. Gastrojejunostomia Retrocolica 571
328, 329. Gastroenterostomia Inferior Longitudinalis 572
330, 331. Gastroenterostomia Inferior Antecolica Verticalis 573, 574
332. Gastrojejunostomia Retrocolica Verticalis 575
333, 334. Gastrojejunostomia Antecolica cum Enteroanastomosi 576, 577
335. Intestinal Clamp 578
336-338. Y-method of Gastroenterostomy 579-581
339. Gastroduodenostomy after mobilisation of the Duodenum 583
340. Gould's Modification of Finney's Pyloroplasty 585
341. Large-sized Intestinal Crushing-forceps 589
342. Gastroduodenostomy after Mobilisation of the Duodenum 590
343-350. Pylorectomy 591-596
351, 352. Hacker-Frank-Witzel Method of Gastrostomy 605, 606
353, 354. Gastrostomy according to Kader's Method 607, 608
355, 356. Œsophago-jejuno-gastrostomy (Roux) 609, 610
357. Formation of a Fæcal Fistula 613
358, 359. Enterostomy in the Small Intestine 614, 615
360. Maydl's Y-jejunostomy 616
361. Formation of Temporary Artificial Anus in the Left Iliac Region . . . 618
362. Formation of Artificial Anus in the Pelvic Colon (Moynihan) . . . 619
363-371. Entero-anastomosis with Unilateral or Bilateral Occlusion of the Gut . . 623-625
372-374. Resection of Small Intestine 626-628
375. Intestinal Suturing 629
376-378. Ileo-Cæcal Resection 631-633
379. Enterostomy in the Large Intestine 634
380, 381. Resection of Large Intestine 636, 637
382-384. Radical Cure of Appendicitis 640-644
385-389. Excision of Rectum 652-656
390. Arrangement of Vessels in Mesentery of Colon (Gegenbauer) 662
391. Incisions to expose Kidney and Ureter 667
392. Nephrotomy. Exposure of the Vessels and Nerves of the Buttock . . . 669
393. Ureteral Anastomosis, Invagination Method 675
394. Uretero-cysto-neostomy (Depage) 676
395. Uretero-cystostomy (Sampson-Krönig) 676

FIG. PAGE
396, 397, 398. Button for Uretero-Vesical Anastomosis (Boari) 677
399, 400. Uretero-plastic Operation (Boari) 678
401, 402. Uretero-trigono-sigmoideostomy (Maydl) 679, 680
403. Angular Incision for Ligature of the Common Iliac Artery 681
404. Mesial Incision for Transperitoneal Nephrectomy 682
405, 406. Lumbo-vertebrotomy 683, 684
407. Interior of Bladder after Removal of Prostate 691
408. Transvesical Enucleation of Prostate (Legueu) 692
409. Perineal Prostatectomy (Legueu) 693
410, 411. Dissection to expose the Prostate from the Perineum 695, 696
412. Alexander-Adams Operation 705

APPENDIX

413. Arthrotomy of the Elbow and Wrist 710
414. Excision of the Wrist by the Dorso-ulnar Incision carried through the Capsule . 711
415. Excision of the Wrist by the Dorso-ulnar Incision. Second Stage . . . 712

SECTION V

SURGERY OF THE HEAD AND TRUNK

A. SURGERY OF THE HEAD

1. Soft Parts of the Scalp

The scalp is characterised by its rich vascular supply, the vessels, however, being easily accessible to ligature, because they run in the skin and subcutaneous tissue, which is firmly united to the occipito-frontalis. The arteries lie loose in the scalp, the veins not to the same extent; therefore the latter do not retract like the arteries. In hæmorrhage from the arteries, press upon the skin close to the edge of the wound and seize the vessels with artery forceps; if our toothed artery forceps do not succeed, then a ligature must be passed around the vessel by means of a curved needle. Hæmorrhage may be temporarily arrested after the manner employed by Doyen in extensive craniectomies, *i.e.* by winding an elastic tourniquet around the greatest circumference of the head.

The vessels which supply the scalp come from the frontal, temporal, and occipital regions. If, therefore, it is desirable in severe hæmorrhage from the scalp to apply a proximal ligature to the main vessels we must turn to these three regions.

Operations on the cranium have already been fully considered under the surgery of the nervous system, and need not be further referred to in this section.

Plastic operations play an important part in the surgery of the face, and are performed for congenital deformities and disfigurements due to traumatic and pathological causes. As, however, they form a class of their own, we can do no more than merely refer to a few of the more important operations. The extent to which plastic surgery of the face can be carried has been demonstrated by Senn of Chicago, who actually reconstructed a face out of a flap turned down from the scalp.

2. The Face, including the Nose, Mouth, and Fauces

The skin of the face is less dense than that of the scalp, but, like it, is extremely vascular. We must be prepared, therefore, for spurting vessels even in skin incisions. Most of the vessels lie under the cutis. As regards the *direction of incisions* (Fig. 255, 256), the general rules which have been laid down are to be applied. Above all, the facial nerve has to be avoided when operating upon the face, and incisions must be chosen which run parallel to its branches, as any injury to the nerve results in disfigurement. It is much less serious to cut through a branch of an artery than to injure a nerve, no matter how small. Accordingly the incisions should radiate from a centre which corresponds to the entrance of the nerve into the parotid. By this means lesions which interfere with expression are guarded against. Some of the vessels, however, will be divided transversely, but Stenson's duct, which runs parallel to the normal

incisions, is avoided. The muscles must be partly divided. Muscular incisions, are, as a rule, avoided; one keeps rather to the septa between them, because infected muscular wounds heal badly. Since the introduction of asepsis, however, the latter consideration no longer comes into question. Rapid union of muscle along with complete restoration of its function can now be obtained, provided the nerves of supply have not been injured. We have constantly to refer to this point in our text-book: it is preferable to cut through a powerful muscle (as, for example, the rectus abdominis) and bring about a tendinous intersection than cause its paralysis and atrophy by injuring the nerve which supplies it.

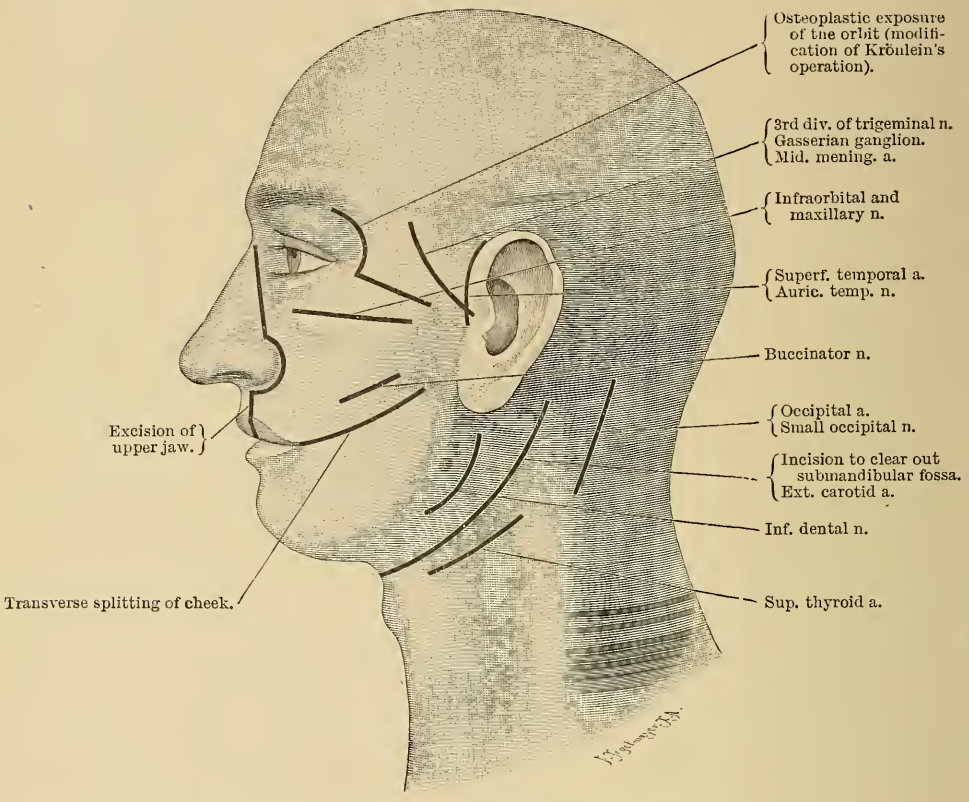

FIG. 255.—Some normal incisions for the head and neck (Kocher).

(a) Surgery of the Eye and Orbit

In the chapter on the surgery of the optic nerve we described appropriate methods by which the orbit may be exposed with preservation of the eyeball.

When the eyeball has to be sacrificed, *e.g.* in malignant disease, an extensive preliminary osteoplastic resection is unnecessary, all that is required being division of the outer angle of the eyelids.

(b) Surgery of the Nose and Associated Cavities

In all operations in the region of the nose, the mouth, and the pharynx, and especially in operations on the jaws, two indications which above all others influence

the result must receive attention, viz. the prevention of excessive hæmorrhage, and the avoidance of aspiration of blood and mucus into the bronchi and lungs.

In the removal of tumours of the nose from the base of the skull, and in resection of the upper jaw, the danger of an excessive loss of blood is great. Steps must therefore be taken to prevent the bleeding. Many authors have devoted their attention to the methods of prophylactic arrest of hæmorrhage in the above operations. We

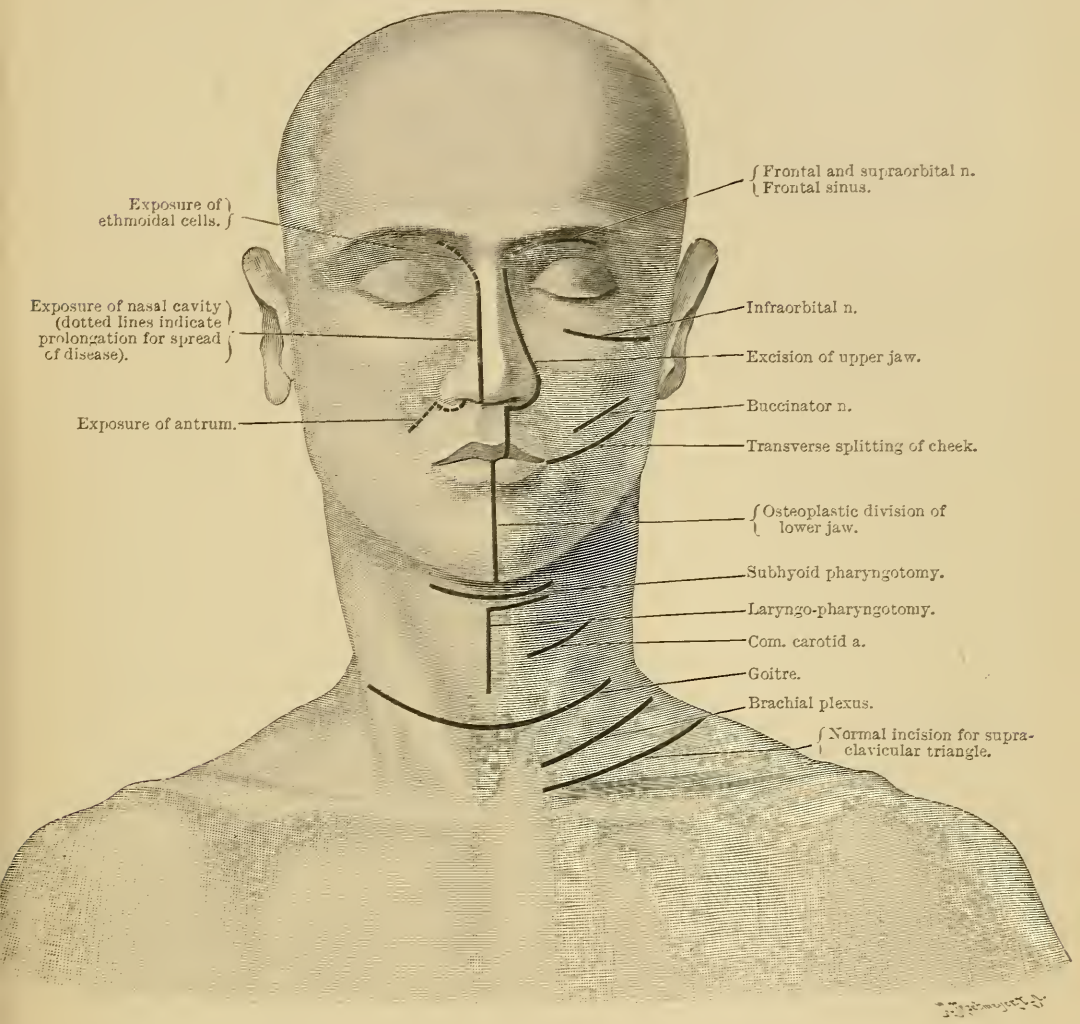

FIG. 256.—Some "normal" incisions for the head and neck (Kocher).

may refer to the work of Schlatter, who summarises the views regarding ligature of the external carotid as a preliminary operation to resections of the upper jaw. In the early editions of this work we have expressed a very different opinion from that which we now hold regarding preliminary arrest of hæmorrhage by ligature of the carotid, and, as we entirely agree with some of the conclusions which Schlatter draws from the literature of the subject, and from his own observations, we should like to express our views more decidedly.

Whatever one may say, ligature of the common carotid in an old man with arterial

sclerosis is equivalent to a death sentence. One cannot definitely enough distinguish between youth with sound vessels and age with degenerated ones. If it can be possibly avoided, the common carotid is never to be ligatured in an old man merely for the prophylactic arrest of hæmorrhage. The choice lies solely between ligature of the external carotid and temporary compression of the common carotid, the latter being the practice especially followed by Schönborn.

In advanced epithelioma of the upper jaw when the condition of the arteries is satisfactory, Fowler[1] controls the hæmorrhage very effectively by temporary ligature of the common carotid on both sides. No evil effects are observed, and we have on several occasions adopted the same procedure in excision of the Gasserian ganglion. On the other hand, according to Dawbarn, excellent results have been obtained by resection of both external carotids and their branches.

Ligature of the external carotid is, as Lipps has shown, not a dangerous operation,

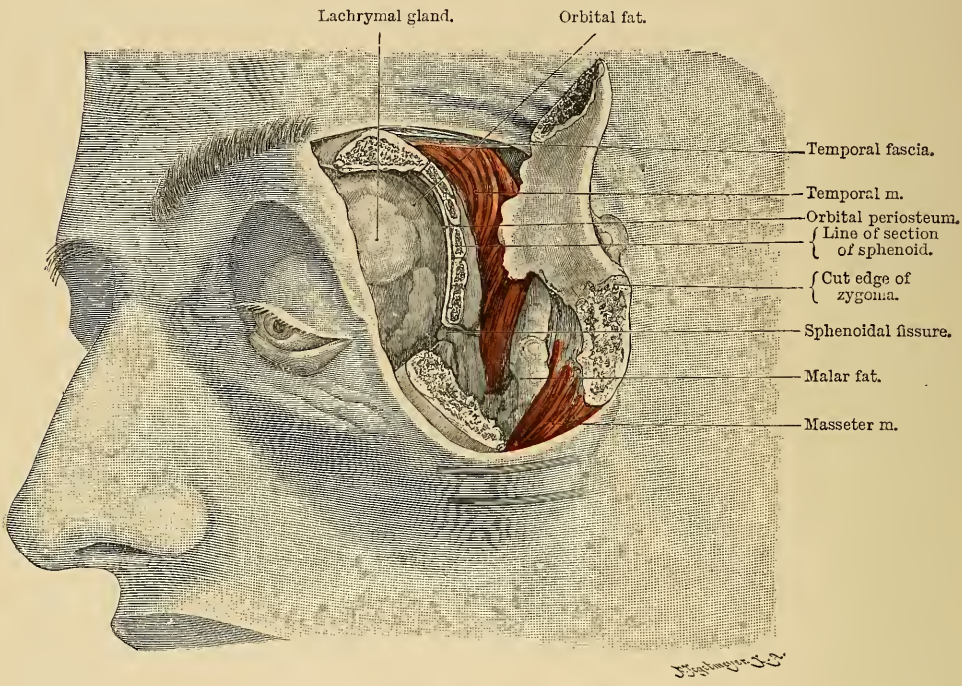

FIG. 257.—Osteoplastic exposure of the orbit.

and our own experience, along with that of others (Friedrich quite recently confirmed this view), shows that it very materially diminishes the loss of blood in dangerous resections of the upper jaw.

How far temporary compression of the common carotid is advisable when the vessels are sclerosed is as yet undecided. In one case at the end of 1898, in which we were obliged to ligature the common carotid in an old man on whom we had performed a pharyngoglossotomy, the patient was quite well after the operation, but hemiplegia, unconsciousness, and fever gradually set in, and a fatal issue followed. The subsequent cerebral softening, therefore, had caused these disturbances. Would these have been avoided if the circulation had remained free?

In young individuals with healthy arteries the common carotid may, without fear, be provisionally compressed or ligatured, as the effect on the brain, which takes the form of a unilateral diminution in the amount of blood it contains, is quite transitory.

[1] *Buffalo Med. Journ.*, June 1903.

The second indication in all operations in the upper digestive and respiratory tract, viz. the prevention of aspiration of blood and mucus, can be much more simply and securely fulfilled by the correct posturing of the patient than by a prophylactic tracheotomy and plugging of the larynx, or by performing the operation under partial anæsthesia. It is well to repeat once more (although the subject has already been considered) that the proper method is to place the patient on his back with the head and thorax sloping downwards (but not with the head alone hanging downwards), not only during the operation, but also subsequently. In this way aspiration of blood at the operation, and of the wound secretion at a later date, is most readily avoided.

Since we have carried out this procedure as a principle in all operations in connection with the mouth, nose, larynx, pharynx, and trachea, we have been able to dispense with all other precautionary measures, and have had such success with it that we cannot too strongly recommend the general adoption of this simple precaution. The head can be steadied in a perfectly convenient position upon a cushion.

The following remarks must be added regarding the after-treatment:—Those cases in which the swallowing mechanism is affected and the reflex excitability of the larynx injured, are to be clearly distinguished from these in which those functions have suffered no damage. If a patient can swallow, even with difficulty, and if he is reflexly stimulated to cough as soon as any secretion reaches the larynx, he should be allowed to sit up even on the day following the operation. One has only to see how well the patient looks and says he feels when he is allowed to sit and walk in order to be convinced of the great advantage of this plan. The patient expectorates much more freely, and aspiration pneumonia does not occur.

During the night, on the other hand, many of these patients must be placed in an inclined position with the neck lowest, and those who are unable to swallow, for example those who, in consequence of paralysis of the superior laryngeal nerve, have lost the reflex excitability of the larnyx, must keep this position for eight to fourteen days, or even longer.

1. Exposure of the Nasal Cavity and Sinuses.—Although an ulcer or new growth of the nasal mucous membrane can readily be detected with the nasal speculum, it is often difficult to estimate the extent of the disease, and especially to determine its origin and depth. It is unfortunate that so many specialists make light to their patients of the removal of "polypi" even when it is obvious that they are not dealing with an ordinary mucous polypus or a pedunculated simple fibroma.

In these cases, nothing short of a thorough exposure of the nose and affected accessory cavities can effect a cure. But at the same time one must be able to assure the patient that any resulting disfigurement will not be of a serious nature. We must therefore be able to thoroughly expose the cavities by incisions which are neither unsightly nor injurious.

It is important that one should know how to enlarge the nares for the purpose of securing a better view or of palpating the parts with the finger. The simplest way of effecting this is by *splitting the nasal septum*, a method which we recommend. The blades of a strong pair of scissors are introduced, one into each nostril, as far back as possible, and the cartilaginous septum is divided. Blood spurts from the small arteries of the septum. The finger can then be introduced into the nose, the walls of which can be manipulated. In ozæna this procedure suffices to clear up the cause, and especially to discover and remove circumscribed areas of diseased bone. The introduction of a couple of sutures enables us to bring about union so exact that practically no visible result of the interference is left.

In deviations of the nasal septum the narrowed nostril must be exposed and an incision made on to the projecting cartilage (or bone), off which the mucous membrane is stripped and the projecting portion of the cartilage resected with forceps.

In all operations undertaken for malignant new growths, very thorough access must be obtained so that one can get a good view of the nasal cavity in order to define the extent of the disease, and especially so that one may be able to remove all the disease and at the same time control the hæmorrhage. In such cases it is

desirable to employ a definite incision which, when prolonged, will enable us to reach the accessory sinuses (maxillary, ethmoidal, frontal, and sphenoidal).

Methods of Access from the Front (Naso-maxillary Route)

2. Radical Operation for Pansinusitis Nasalis (Moure).—The normal operation, which fulfils the above requirements and causes a minimum of disfigurement, consists in splitting the nose close to the middle line, a method also recommended by Dieffenbach and König (Fig. 258). The incision is not made exactly in the middle line, on account of the furrow which runs along the anterior edge of the septal

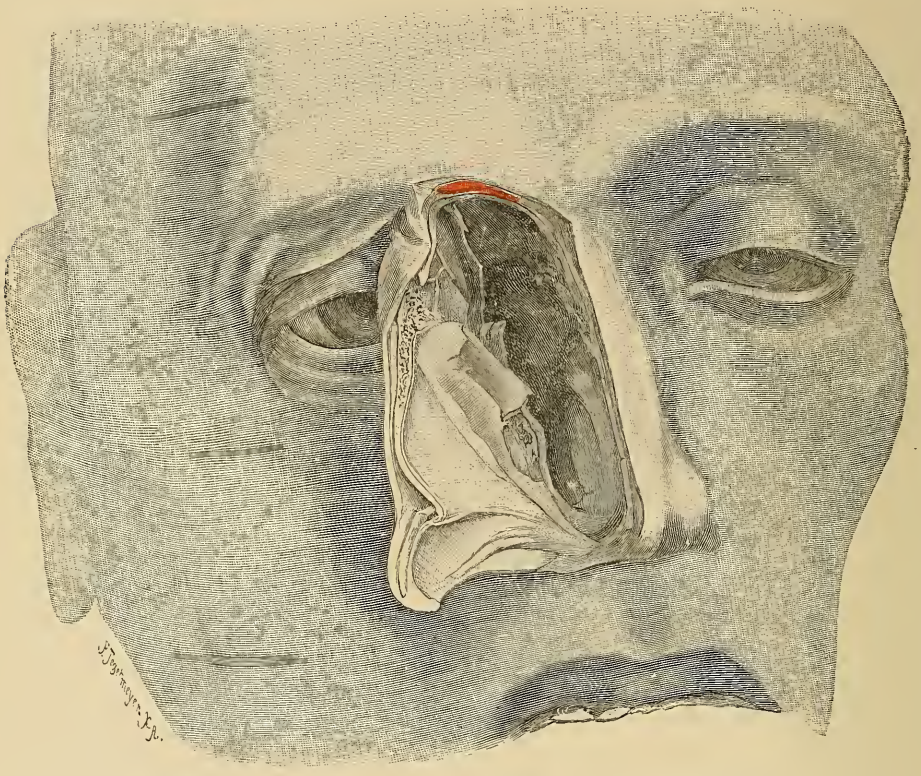

FIG. 258.—Paramedian incision for radical operation on the nasal cavity. The nasal bone and frontal process of the superior maxilla on one side have been divided and the lateral wall of the nose has been turned outwards. The ethmoid and its os planum are removed, exposing the sharp edge of bone between the orbital and nasal cavities. The frontal sinus has been opened up by removing its floor. The nasal septum is exposed lower down.

cartilage of the nose. A cicatrix along this furrow would, by contraction, render it visible, and so produce distinct disfigurement. By division of the lateral nasal cartilage and the nasal bone a little to one side of the middle line, a cicatrix is obtained which is scarcely visible. This incision has the advantage that, if necessary, it can be easily enlarged without disfigurement, *i.e.* a so-called radical operation can be performed,[1] and several or all of the sinuses can be opened up (polysinusitis). By prolonging the incision on to the eyebrow[2] access is obtained to either the

[1] *Vide* Cheval, *Bull. Soc. Roy. Brux.*, 1905, No. 9.

[2] The transverse incision below the lower lid (Terrier, Athané) is to be discarded on account of the ascending branches of the facial nerve to the orbicularis palpebrarum.

ethmoidal cells or the frontal sinus. It can further be extended in the naso-labial fold, thus allowing the ala nasi to be freed, and can then be carried outwards in the oblique fold between the cheek and the lip. Lastly, it may be carried downwards through the upper lip near the middle line when a further separation of the soft parts is desired.

The bridge of the nose is split in the middle line, but the level at which the transverse incision through the bone is made varies (higher or lower) according to the seat of the disease.

The base of the nasal bone on the diseased side is divided with bone-forceps, the root of the frontal process of the superior maxilla detached with the chisel from below upwards towards the orbit, and the lateral wall of the nose turned outwards as a flap.

As is the rule in new growths if one wishes to expose the antrum of Highmore at the same time, the inner wall of the antrum is detached from the horizontal plate of the palate bone with the chisel and is removed as far as necessary, the inferior turbinate being also excised if required. In this way the nasal cavity and the antrum of Highmore can be easily converted into one large cavity.

If the ethmoid is much involved, the incision is carried along the eyebrow, dividing the periosteum alongside the nasal bone and stripping it back over the lachrymal bone and the os planum of the ethmoid (the lacrymal sac being preserved) so that the bone may be removed if necessary from the cribriform plate above, to the anterior margin of the sphenoidal sinus behind.

The frontal sinus may be opened through the same incision by removing the bone forming its floor, a process which also entails the removal of the nasal spine and the floor of the sinus.

By this means one continuous cavity is obtained from the frontal sinus above to the antrum of Highmore and the floor of the nose.[1] Posteriorly the thin anterior wall of the sphenoidal sinus is easily opened at a depth of about 6 cm. If the disease is situated upon the outer wall of the nose and extends to the upper jaw, then it is better to *split the nose laterally*. An incision is made along the groove around the ala nasi and extending upwards, either as far only as the summit of the osseous anterior nares, the detached side of the nose being thrown upwards and inwards, or the division may be extended upwards along the nasal process of the upper jaw, and transversely through the root of the nasal bone. In this way very good access is got to the anterior part of the nose, so that tubercular ulcerations can be readily exposed to thorough local treatment. The method, however, has the disadvantage of throwing out of action some of the muscular fibres, namely, the pyramidalis nasi and the levator alæ nasi. As, however, the muscular incisions generally heal by first intention, and the nerve-supply remains partly intact, no noteworthy interference with the play of the features results. The nasal branches of the facial artery are divided, but its angular termination is avoided at the upper part of the wound. By careful suturing the scar ultimately becomes almost invisible.

The method of Chassaignac and Bruns, in which the nose is turned aside laterally, has been occasionally practised; according to Czerny's experience (Naab), it is a good method for naso-pharyngeal fibromata which occupy the anterior part of the nose, as it may bring about a radical cure. In this procedure the whole nose is turned over to one side by dividing the septum by means of two incisions which meet at an oblique angle, the one from above, the other from below. The junction of the nasal bone with the nasal process of the superior maxilla of the opposite side is broken across.

If it be necessary to see farther back into the nose than is possible by the above methods, then a partial osteoplastic resection of the upper jaw may be made whereby the inner, the anterior, and a portion of the upper wall of the antrum are turned outwards, and a view far back into the posterior nares is obtained.

In contrast to the access obtained from in front which may be called the naso-maxillary route, which we have described as the "normal" operation because it is suitable

[1] *Vide* also Grünwald, *Rhinochir. Mitteilungen, Centralbl. f. Chir.* Bd. 3, 1906.

even for diffuse disease extending from the frontal sinus down through the ethmoidal bone to the floor of the nasal cavity and into the antrum of Highmore, there are other methods which should be used according to the localisation of the tumour, *i.e.* the bucco-nasal route (below) or the naso-orbital route (above).

3. The Bucco-Nasal Route. Denker[1] employs the buccal route, originally introduced by Rouge for the treatment of ozæna even for malignant tumours of the nose. In the former edition of this work we described Rouge's method of opening the nasal cavity by an incision through the sub-labial mucous membrane, with separation of the cartilaginous portion of the nose from the osseous nares and septum, followed by turning up of the nose and cheeks. Rouge divides the mucous membrane below the nares in the fold between the gum and the upper lip as far as the wisdom tooth, and raises the soft parts with a raspatory as far up as the infraorbital margin, at the same time elevating the mucous membrane in the inferior and middle meatus for a distance of 5 cm. He then opens into the antrum from the front and removes its nasal wall. It is thus seen that the first stage of the operation corresponds with the ordinary method of opening the antrum from the canine fossa, with, however, a freer removal of the anterior and nasal walls. It causes no disfigurement; but in the case of a new growth situated high up, the access is not so satisfactory as that provided by the naso-maxillary route, while the bleeding is less easily controlled, and the results are more uncertain.

4. Opening the Maxillary Sinus (Antrum of Highmore). The simplest and therefore the best method of obtaining free and dependent drainage in suppurative conditions (especially acute) of the antrum, is to open the antrum through the canine fossa in the mouth, where the bone between the strong buttresses on either side formed by the nasal process and the ridge of the malar bone is thin.

The mucous membrane is incised down to the bone, obliquely from before backwards immediately below the line of reflection of the lip, the incision being made rather lower posteriorly, but invariably made so that there remains a fold of mucous membrane in the lower side to hold stitches. The periosteum is detached upwards, exposing an area of bone the size of the terminal phalanx of the finger, the bone being afterwards chiselled out with a gouge 1 cm. broad. A finger is then introduced into the cavity and any necrosed bone, stumps of teeth or tumour are felt for. The bleeding in acute cases may be very active if the antral mucous membrane is hyperæmic and swollen, and may have to be controlled by rapidly packing the antrum with strips of iodoform gauze.

When the bleeding is slight, as occurs in chronic cases, a communication may be made with the inferior meatus of the nose by pushing a curved trocar through the thinnest part of the inner wall below the middle of the inferior turbinate bone, after which the gauze packing may be passed through to the nose, and the opening in the mouth closed with a few catgut sutures.

A suitable method for obtaining simple drainage of the antrum when exploration is not required, is to bore upwards with a perforator through the socket of the second bicuspid or of the first or second molar tooth, the first molar, according to v. Stein, giving most room. This method is only suitable, however, in cases where prolonged drainage of the purulent contents is desired. A small self-retaining silver tube can be readily introduced, by which means excellent drainage is provided.

A third method of opening into the antrum without making a skin incision is to break through its *inner wall* below the middle of the inferior turbinated bone, using a bent, sharp-pointed perforator (Mikulicz). The advantage of this method is that the pus flows, not into the mouth, but into the nose, its disadvantage, however, being that it does not, like the operation from the mouth, open the lowest part of the antrum. Neither of the two latter methods allows of direct inspection of the antrum, or of the introduction of the finger into it.

Friedrich of Greifswald has introduced a modification of the Luc-Caldwell operation (Hajek) for the radical cure of antral empyema. The method provides a permanent communication between the nose and the antrum and thus prevents

[1] *München med. Wochenschrift*, 1906, No. 20.

stagnation of the antral secretion. The inner wall down to the floor of the antrum is freely removed.

When it is important to avoid an external scar, the anterior surface of the superior maxilla may be exposed by making an incision in the fold between the gum and upper lip as was originally adopted by Rouge for the treatment of ozæna. The bony margin of the nares is then chiselled away and the antrum brought into communication with the inferior meatus by removing the anterior part of the nasal wall.

Friedrich's operation is rendered more easy if an incision is made in the fold of the ala nasi, and a second oblique one in the fold between the lip and cheek down to the bone. An area of bone, 1 cm. square, is then removed with a hammer and chisel and Luer's forceps from the osseous margin of the nares, after which the nasal wall of the antrum is cut away above the floor of the antrum for a distance 1 cm. high extending 3 cm. backwards, part of the inferior turbinate bone being removed as well.

The antrum is then explored with the finger, thoroughly scraped out, and plugged from the nose. When the incisions are stitched up no noticeable scar is left.

After opening the nasal cavity, access is got to the *nasal duct* under the anterior end of the inferior turbinate bone $1\frac{1}{2}$ cm. ($\frac{5}{8}$ in.) behind the edge of the osseous anterior nares. The *antrum of Highmore* is reached by passing outwards under the middle turbinal $2\frac{1}{2}$ cm. (1 in.) behind the above bony edge, while higher up, under the same turbinated bone, a probe may be passed into the duct of the *frontal sinus*. The direction of the canal, as well as that of the nasal duct, is about parallel to the lateral wall of the osseous anterior nares.

Fronto-Nasal Methods

5. To open the Frontal Sinus.—Simple exploratory puncture of the frontal sinus may be performed according to the method devised by us and described by A. Kocher, in which a drill is pushed through the skin over the inner third of the eyebrow (no incision being made) and then bored through the bone. The presence of purulent contents in the sinus can be determined with an exploring syringe.

In cases of empyema the sinus is drained by the following method :—

(*a*) *Opening the Sinus.* After shaving off the eyebrow, an incision is carried down to the bone along the supraorbital margin as far as the middle line. The upper edge of the wound, along with the separated periosteum, is drawn well upwards. The supratrochlear and supraorbital nerves, and the accompanying arteries, are divided, but the branches of the facial nerve to the occipito-frontalis, corrugator, and orbicularis muscles, which are of greater importance, are avoided. It is seldom necessary to make a second incision passing obliquely upwards towards the middle line. After raising up the skin and periosteum with a raspatory, the sinus is opened with a chisel, or rotating burr, at the inner end of the superciliary eminence. The anterior wall contains diplöe, and is richly supplied with blood, so that one must be prepared for bleeding. The posterior wall consists only of the vitrea. Beneath the anterior wall is the mucous membrane, which is smooth and bluish when healthy but bluish-red, friable, and markedly thickened when suppurating. After dividing the mucous membrane, a probe may be passed downwards and backwards from the sinus into the nose under the anterior end of the middle turbinal, and, after forcibly dilating the canal, drainage is established by the introduction of a tube.

It is well for this purpose to make use of a very light silver drainage tube, having two or three flanges towards the sinus, so that it may be firmly retained in position, but at the same time be sufficiently yielding, so that with a firm pull from below the flanges may come together, and may not prevent the withdrawal of the tube towards the nose. The tube must be worn until the suppuration ceases. As a rule it is better, without further separation of the periosteum, to cut through the bone with a straight chisel from the initial opening, first in an outward, and then in

an upward direction, the extent of the sinus in both these directions being first ascertained by a probe.

By means of an elevator the triangular portion of bone which has thus been formed, along with its periosteum, can be broken across and folded upwards and outwards. The entire mucous lining may be completely removed with a small sharp spoon. In this way a complete cure is obtained by establishing free drainage into the nose. An iodoform gauze tampon is introduced and the wound partially sutured, secondary sutures being introduced two days later.

The above method suffices for acute and recent cases in which there is merely a purulent catarrh of the sinus, for example, in those cases which occur as a complication of acute rhinitis, or in infectious diseases without visible continuous infection from below (*e.g.* influenza). In cases of longer duration, on the other hand, the mucous membrane does not recover, the surface of the bone becomes diseased, the ethmoid cells become involved from the pus flowing over them, and thus permanent healing is prevented. These cases must be relieved by a radical operation.

(*b*) *The Radical Operation on the Frontal Sinus.* Three radical methods may be mentioned. The first, generally referred to as Kuhnt's method, but performed by us much earlier, consists in the obliteration of the sinus by the removal of the whole of the anterior wall of the sinus. In this method the above-described angular incision must be employed. The sinus is opened as described, the soft parts along with the periosteum are separated, the anterior wall of the sinus is then removed with cutting bone forceps, and the diseased mucous membrane scraped out ; no drainage is employed, and the soft parts are applied to the posterior wall of the sinus.

The disadvantage of this operation is that considerable deformity results, even although the cicatrix itself is scarcely visible. The forehead appears to be irregularly sunken in. This method is, therefore, to be limited to the most obstinate cases, and to those where danger of intracranial complications is feared. The deformity might be avoided if the anterior wall were folded back by the osteoplastic method, and the posterior wall removed ; but the fear of an intracranial retention of pus forbids this procedure, which could only be considered if subdural suppuration already existed. Jansen's method of removing merely the orbital wall of the sinus and packing is not to be compared in its results to the removal of the whole wall.

To prevent the deformity an osteoplastic method has been introduced. In an earlier edition of this work we stated that, as a rule, it was better, instead of proceeding from a small opening into the sinus, to divide the anterior wall at both extremities with bone forceps without separating the periosteum, and then to break across the bony flap at its base. In this way a free view is obtained of the whole cavity, thus allowing of complete removal of the disease. Küster, Gussenbauer, and Czerny have methodically carried out the osteoplastic trephining. Czerny's incision produces much more deformity than that employed by us and accepted by Golovine. Golovine, by means of a variable incision, forms a flap of bone with its base at the supraorbital margin. Killian has attempted to minimise the disfigurement by resecting the anterior and inferior walls of the sinus, leaving, however, a supraorbital bridge of bone (Fig. 259).

The osteoplastic method, as compared with that of making a small trephine opening, allows not only of a thorough removal of the diseased mucous membrane and bone, but it also enables the drainage opening to be placed at the deepest part of the cavity, this, as Küster has rightly insisted, being essential when dealing with cavities with rigid walls. Drainage may also be carried out conveniently by passing a tube from the nose and out through the skin, so that the cavity may be thoroughly washed out.

A third method is especially adapted to meet the last indication, which is so important if a radical cure is to be obtained ; it attacks the opening of the fronto-nasal duct and the ethmoidal cells to a varying extent, so as to permanently prevent any pocketing of pus, or any hindrance to perfectly free drainage into the nasal cavity. Winkler splits the nose in the middle line. Killian performs a temporary resection of the nasal bone and of the nasal process of the superior maxilla. Barth, by means

of a longitudinal incision, turns aside a still more limited flap of bone, consisting merely of the nasal bone and the nasal process of the frontal bone.

In Barth's operation, after the bone has been folded back, the diseased mucous membrane of the frontal sinus is seen to project from above forwards into the wound, and can be freely incised and the frontal sinus plugged; then the upper part of the nasal cavity may be laid freely open by means of the spoon, chisel, and scissors, so that a permanent free communication between the frontal sinus and the cavity of the nose is obtained. This method of placing the opening of the sinus towards the nose is

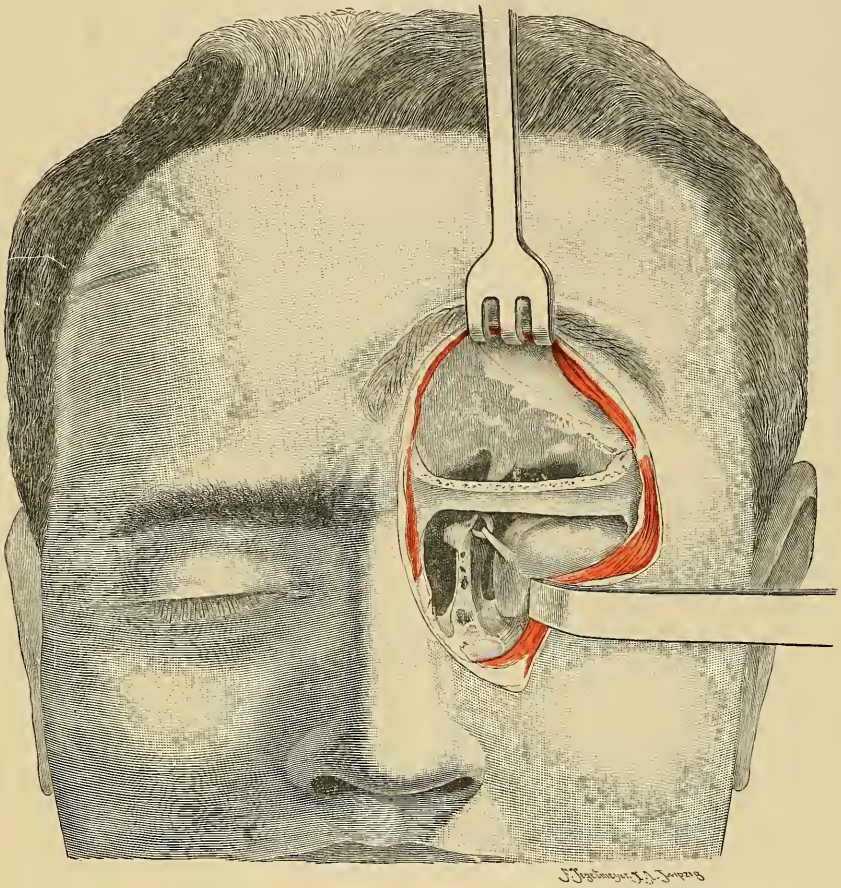

FIG. 259.—Killian's radical operation on the frontal sinus. The supraorbital margin has been retained in the form of a bridge (from a dissection by Tramond).

specially indicated in all cases where disease of the nose, especially of the ethmoidal cells, is combined with inflammation of the sinus, whether primary or secondary. The operation has been methodically developed by Killian, with whose name it is commonly associated. The main feature of the operation is that, by providing sufficient room in front, and removing the floor of the sinus, the anterior ethmoidal cells are entirely cleared out, and a free communication between the nose and frontal sinus is permanently procured. The after-treatment consists merely in frequent douching of the nose, provided an intense affection of the sinus does not render it desirable to stuff the cavity for several days with iodoform or xeroform gauze.

6. Opening the Ethmoidal Sinuses (Treatment of Ethmoiditis). The ethmoidal

sinus has already been alluded to in describing the incision for exposing the nasal together with the accessory cavities. The exposure of the roof of the naso-pharynx is considered in the section dealing with excision of the upper jaw, which is a necessary preliminary.

(c) Surgery of the Jaws

7. Resection of the Upper Jaw (Figs. 260, 261, 262). In order to have the courage to carry out a partial or total resection of the upper jaw with the necessary thoroughness during the early stage of a malignant tumour—that is, to expose the diseased parts so thoroughly that all suspicious tissues may be removed with certainty —it is indispensable to be acquainted with methods of operation which do not result in too serious disfigurement. The play of the features, more especially, must not be unnecessarily interfered with. It is not, therefore, a question of obtaining fine scars, but of preserving intact the branches of the facial nerve. To this end the following incision is recommended.

It is almost always desirable, in the first place, to remove the glands at the angle of the jaw and at the anterior border of the sterno-mastoid by the "normal incision for the submaxillary triangle." The opportunity should at the same time be taken to ligature the external carotid, as this preliminary procedure greatly diminishes the bleeding and allows the operator to see exactly what he is doing.

Temporary occlusion of the common carotid proves even more satisfactory. This is effected by passing a stout four-ply ligature round the artery and bringing the loop out of the wound, while the edges of the wound are protected by means of aseptic gauze fixed to the skin. The loop may be pulled taut by an assistant, by which means the bleeding is completely kept in check.

Having thus taken steps to make the operation bloodless, we make an incision through the upper lip along the naso-labial ridge into the nasal orifice, from thence close around the ala of the nose, and obliquely upwards and inwards along the osseous anterior nares to the junction of the frontal bone with the nasal process of the upper jaw. In this way the levator alæ nasi muscle alone is divided, which will scarcely affect the expression of the features. Fig. 260 shows how slight the deformity is. It is limited, in fact, to a slight falling in of the cheek and sinking down of the lower eyelid.

Should the above incision, which Esmarch ascribes to Nélation, give an insufficient view, there are two ways of obtaining a more free access : in the case of tumours which extend far back, by the addition of an independent incision extending transversely outwards from the angle of the mouth, as has been more fully described for obtaining free access to the buccal cavity. The operation thus becomes similar to that performed by Fergusson. This is a very suitable incision to employ when the new growth has extended far backwards along the alveolar margin and roof of the mouth.

As a rule an incision at a higher level is necessary in order to get sufficient access to the region of the orbit and the malar bone. It is made in such a way that it falls between the upper and lower areas of the facial nerve, at the lower edge of the orbicularis palpebrarum, above the origins of the levator labii superioris and zygomatic muscles (our normal upper jaw incision below the infraorbital margin). This incision is similar to that described by O. Weber, except that it is directed obliquely downwards to avoid the branches of the facial nerve. Still better access is obtained if the incision divides the inner canthus of the eye, and is continued outwards and slightly downwards from the outer canthus. The mucous membrane is divided along the lower lid. This is practically Dieffenbach's incision, but he splits the nose in the middle line.

The flap, including the whole of the healthy soft parts and the nerves, is reflected outwards, and the bone (or tumour) exposed by dividing the reflection of the mucous membrane of the cheek. Hæmorrhage is temporarily arrested by grasping firmly the base of the flap, which allows of the vessels (angular, labial, infraorbital, and transverse facial) being secured and ligatured. Immediate and thorough arrest of the hæmorrhage is a very important step in the operation.

Next comes the separation of the upper jaw from its connections. When the disease is extensive the nasal process of the upper jaw, together with the nasal bone, is divided with the chisel and bone pliers from the highest part of the osseous anterior nares, and the division is continued backwards through the lachrymal and ethmoid bones as far as the hinder end of the spheno-maxillary fissure, no injuries of importance being inflicted. As regards the connection of the upper jaw with the malar bone, the line of division will depend upon the extent of the disease, being made either at the maxillo-malar junction, or in such a way as to remove the malar bone as well, by dividing its zygomatic and frontal processes with a chisel. For this a small separate incision must be made, the edges of which must be drawn firmly apart with sharp hooks.

There remains now the third connection, namely, with the upper jaw of the

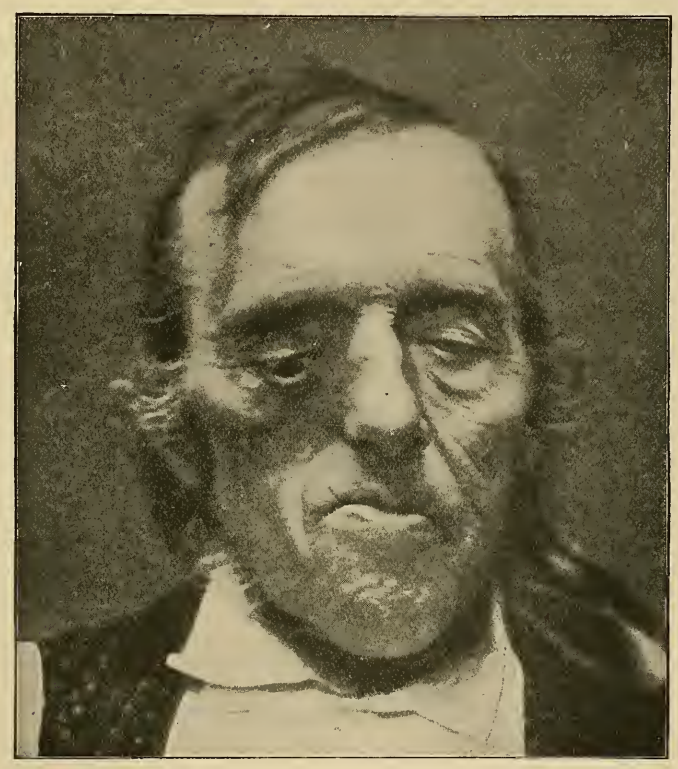

FIG. 260 shows the result after complete excision of the upper jaw (for a malignant tumour) by the angular incision.

opposite side. The mucous membrane and periosteum of the palate having been divided down to the bone beyond the disease, and the soft palate having been separated from the hard palate with the knife, or better with the thermo-cautery, a chisel is placed between the median incisors, and the hard palate is cut through in its entire length. If the latter procedure is difficult, cutting forceps may be used.

Lastly, the connection with the pterygoid process is to be considered. By drawing the flap forcibly backwards, the soft parts (mucous membrane, buccinator, and the two pterygoid muscles) can be separated from without as far back as the pterygoid process, and the hæmorrhage having been properly arrested, the process is chiselled through from the exterior. When the pterygoid is not to be removed the upper jaw is separated from it by forcibly wrenching it downwards, a process which should be carried out rapidly in order that the arrest of hæmorrhage may at once be proceeded

with, as the large terminal branches of the internal maxillary artery (spheno-palatine, descending palatine, and infraorbital) have been torn through.

As regards after-treatment there are two methods: if the bleeding has quite ceased, the wound should be irrigated half-hourly with very warm normal salt solution; if the bleeding continues, the cavity should be packed with xeroform gauze, and not changed until it becomes loose.

The main point to be observed in the after-treatment is the prevention of aspiration pneumonia by raising the foot of the bed when the patient is recumbent. We allow our patients up as early as the second day.

For quite localised tumours, as well as for the removal of sequestra, an incision

Fig. 261.—Excision of both upper jaws for phosphorus necrosis, without an external incision. Photograph taken four weeks after operation. The patient wears no artificial mould.

through the upper lip into the nose will suffice. We have recently performed a complete resection of both jaws for phosphorus necrosis without making any external skin incision. In such cases, owing to the periosteum being left, the disfigurement is so slight that it is hardly possible to realise that so serious an operation has been performed.

The after result is very different in cases of malignant tumours, which involve the entire upper jaw, and especially those which have developed from the *antrum of Highmore*. Here recurrence is the rule, because by our present methods we cannot be sure of removing all the disease. The fault lies partly in the disregard of prophylactic means to prevent hæmorrhage, and partly in incorrect posturing of the patient.

In all those cases where we cannot with certainty determine the boundaries of the new growth we must make up our mind from the beginning to extend our incisions, on the one hand, well beyond the region of the upper jaw, and, on the other, we must not shrink from removing the skin covering the tumour as far as it is adherent. The excision of a large portion of the cheek and eyelid will, of course, have to determine the form of the incision.

Where it is not necessary to remove the skin, we recommend, where the disease is extensive, the employment of a modified Dieffenbach's incision, *i.e.* perpendicularly through the upper lip along the naso-labial groove, and vertically upwards through the nose just external to the middle line. At the root of the nose the incision is carried outwards along the palpebral fissure, and from the outer canthus outwards and downwards, as far as the posterior part of the zygomatic arch. The large flap is then reflected backwards as far as the masseter, and the bleeding arrested. The

FIG. 262.—Photograph of patient, 10 years after resection of both upper jaws for phosphorus necrosis.

eyeball should be removed under all circumstances, in order that a fair opportunity may be provided for the removal of the diseased tissues in the region of the ethmoid and of the spheno-maxillary fissure down to the base of the skull, as it is here that recurrence is specially apt to occur. The next step in the operation is the division of the base of the external angular process of the frontal and then of the posterior part of zygomatic arch, after which it is determined how far the tumour has implicated the region of the ethmoid, the nasal bones, and the orbit, so that one may keep wide of its limits in these regions. The nasal bone, along with the nasal process of the upper jaw and the orbital plate of the ethmoid, is then severed from the frontal. The base of the pterygoid process must be chiselled through from the outside, and removed along with the internal and external pterygoid muscles. Great disfigurement after resection of the upper jaw is caused by the falling down of the eyeball and lower eyelid when the long-standing œdema has disappeared. König has introduced an excellent plastic operation to prevent this deformity. He takes a strip of muscle, two

fingers'-breadth, from the insertion of the temporal muscle, together with a piece of the anterior border of the coronoid process, which he chisels through down to its base, and having placed it transversely below the eyeball, fixes it to the remains of the nasal process of the upper jaw. In this way a support is provided for the eyeball.

8. Osteoplastic Resection of the Upper Jaw. Osteoplastic resection of the upper jaw is mainly performed as a preliminary step in the removal of tumours of the nasal cavity, which reach as high as, or originate from, the roof of the nose and naso-pharynx, and especially if they have invaded the orbital cavity. We referred to this point in considering the surgery of the nasal cavity, at the same time describing the partial resection of the jaw by which the nose and accessory cavities are reached.

A complete osteoplastic resection of the jaw may be regarded as an extended form of the naso-maxillary method, and is carried out on precisely the same lines as those recommended in the next paragraph, with this difference, however, that after the skin incision has been made, the soft parts are not dissected up, but remain in contact with the bone when the latter is reflected outwards. The subsequent disfigurement is therefore less, very fine cicatrices being obtained.

9. Osteoplastic Resection of the Upper Jaw to expose the Base of the Skull—*e.g.* for naso-pharyngeal tumours, malignant tumours of the ethmoid and sphenoid, and for diseases of the sphenoidal sinus and the pituitary body.

The exposure of the ethmoidal sinus for the removal of a malignant tumour which has involved the orbit, must be combined with resection of the upper jaw, the operation thus forming a combination of the naso-orbital and naso-maxillary routes. The latter is carried out in the manner described under *b*, page 384, but one may resect only a part of the upper jaw, leaving the horizontal plate of the palatal bone. The incision resembles that for resection of the upper jaw, but the lip is not split and the horizontal limb is made shorter. In other respects the procedure is as follows :—

The posterior nares are first plugged in the usual way with a Bellocq's sound, in order to prevent the passage of blood downwards into the air passages during any part of the operation. This may also be effected by placing the patient on his side. The nose is split close to the middle line from the affected nostril upwards between the nasal bones as far as the glabella, and firm pressure is applied with gauze pads to stop the bleeding. An incision is then made at the outer angle of the orbit down to the frontal process of the malar, which is exposed subperiosteally with a raspatory and then chiselled through, little hæmorrhage resulting. The anterior end of the zygomatic arch is dealt with in the same way. The upper jaw is chiselled through (at the level of the inferior meatus) from the floor of the nose horizontally outwards through the *antrum of Highmore*, the mucous membrane of the mouth being nowhere injured. The soft parts are then divided and the base of the nasal bone is snipped across with forceps, which are carried laterally also through the lachrymal and ethmoid bones to the floor of the orbit. In this way, without excessive bleeding, a flap consisting of the cheek and nose, together with the bone (the anterior wall of antrum, nasal process of the upper jaw, and the nasal and frontal bones), is turned outwards and downwards and the tumour exposed, which in our case filled the nasal cavity and antrum, and had, by destroying the ethmoid, penetrated the orbit.

The method above described somewhat resembles Jordan's modification of Langenbeck's osteoplastic resection of the upper jaw with temporary resection of the nose. By it Czerny (Naab) has successfully removed naso-pharyngeal fibromata.

Jordan has operated in various ways. His plan of wrenching the upper jaw and nose over to the opposite side has, like Langenbeck's, the disadvantage of a disfiguring incision, which also injures branches of the facial nerve. His first plan, which more resembles that practised by O. Weber and the author, avoids this disadvantage.

Polypi can be readily cleared out as far as the base of the skull, and when the eyeball can also be removed one can sometimes easily reach from the inner and back part of the orbit into the sphenoidal sinus, which may be investigated with the finger, and if necessary cleared out. The parts as far as the sphenoidal sinus are so readily accessible that careful cauterisation can be done up to the base of the skull,

which is exposed from the cribriform plate of the ethmoid as far back as the sella turcica.

When it is necessary to obtain access to both sphenoidal sinuses, the posterior and upper part of the nasal septum must be removed, if it be not already destroyed.

By trephining the roof of the sphenoidal sinus in a backward and upward direction it does not seem to be impossible to remove a tumour of the pituitary body (in acromegaly) after the above-described preliminary operation has been performed.

The sphenoidal sinus is exposed in exactly the same way as the ethmoidal sinus. Siebenmann does not hesitate to puncture the sphenoidal sinus above the choanæ by inserting a needle below the middle turbinate bone; and if pus is found he removes the greater portion of the anterior wall of the sinus with a sharp spoon. As the wall is thin it can be readily penetrated.

The position of the sphenoidal sinus and the manner in which it can be reached from the middle meatus is best understood by a reference to a sagittal section of the skull. The point at which the sphenoidal sinus should be penetrated lies between the posterior extremity of the middle turbinate bone and the attachment of the ala of the vomer at the upper part of the posterior opening of the nares. The puncture opening is then enlarged with a sharp spoon.

Lastly, the palatine route must be clearly distinguished from the naso-maxillary and buccal routes for exposing the nasal cavities.

The transpalatine route for exposing the roof of the nasal cavity has been described by Nélaton and Gussenbauer. It causes comparatively little injury, gives, however, rather limited access, and is only suitable for pedunculated tumours, *e.g.* polypoid fibromata and fibrosarcomata.

Gussenbauer splits the hard and soft palate in the middle line, separates the muco-periosteum on both sides and chisels off the horizontal plate of the palate as well as the vomer, by this method exposing the posterior part of the roof of the nose and naso-pharynx.

Lastly, the freest access to the whole of the nasal cavity and to the roof of the nose and naso-pharynx is provided by a method we have introduced, namely, by temporary reflection of both upper jaws.

The technique is fairly simple: The upper lip is split into the nostril near the philtrum, the mucous membrane in the fold between the jaw and the lip (and cheek) is divided sufficiently to allow of a chisel being applied above the alveolar margin so as to cut through the anterior wall at the floor of the antrum, the chisel being provided with a short projecting guard on one side. There is no resulting injury to the mucous membrane of the posterior wall, while the vessels and nerves running forwards to the horizontal plate of the palate remain undivided.

The alveolar margin and palate are divided with a broad, thin chisel exactly in the middle line in the interval between the incisor teeth. The soft palate is also divided and the edges are forcibly pulled apart with strong hooks. The mucous membrane of the nose is divided, the vomer pushed aside (or cut across) and the turbinate bones are excised if they hamper the operator.

The access obtained to the base of the skull by this method is better than is provided by any other operation, and although less room often suffices in cases of pedunculated fibromata, we consider this method necessary in dealing with tumours that have a broad attachment and especially with vascular sarcomata or carcinomata. The operation provides excellent access, with the great advantage that the resulting deformity is nil, only a very slight scar being left, and at the most the incisor teeth next the saw-cut may be slightly loosened. The two halves of the palate are then carefully approximated and its coverings, as well as the soft palate, are united with sutures. The raw surface at the base of the skull must be well packed and the end of the packing brought out through the nostril.

Up to the present, the operation has been performed six times, by Depage (twice), Larise, Bornhaupt (Falkenberg), Nicoladoni (Hertle), Payr and Enderlen. Our case has been published by Lanz.

Surgeons are agreed that the operation gives a freer access than is provided by

any other method, and that there is least subsequent injury and no disfigurement, because the palatal processes and the soft palate reunite very readily. Payr has observed very good results in two cases. The severe bleeding which often occurs is not to be attributed to the operation so much as to the condition by which it is occasioned—*i.e.* the vascularity of a broad-based tumour.

We have endeavoured to diminish the bleeding by ligaturing both external carotid arteries, a precaution which Depage and Enderlen have found of service, although less importance is attached to it by others. Fowler's temporary ligature of both common carotid arteries might prove more effective, with the addition of the loop, which we suggested and which can be pulled on if required.

The hanging position of the head is to be avoided, but the oblique position of the trunk is necessary to prevent aspiration. The anæsthetic is administered with Arnd's ether-apparatus. Depage, Larise, and Hertle perform tracheotomy. Kuhn has called attention to the special advantages of administering the anæsthetic by peroral intubation, which allows the entrance to the larynx and oesophagus to be plugged, while Payr has attempted to induce local anæsthesia by inserting the needle of a syringe below the external palpebral ligament and injecting cocain along the floor of the orbit towards the spheno-maxillary fissure.

Partsch has modified our operation inasmuch as he does not divide the palate in the middle line but merely turns back the flaps after cutting through the bone above the alveolar margin. This does not provide such good access to non-pedunculated malignant tumours, which are generally very vascular, and for which our operation is intended.

10. Removal of the Pituitary Body. Hertle has rightly observed that the diagnosis of a tumour of the pituitary body can be made with relative certainty from the presence of bitemporal hemianopia, as well as evidences of acromegaly, and that the question of excision should be considered when medical treatment has failed. The temporary reflexion of both upper jaws and the removal of the lower wall of the sphenoidal sinus would lead one down to the point where the pituitary body could be removed from the sella turcica.[1]

Hertle calls attention to his experiments on the cadaver in which he successfully excised the pituitary body without injury to the adjacent structures. Maas and Friedemann[2] have performed the operation successfully in cats, while Schloffer has made experiments on the cadaver. The orbito-naso-maxillary route, described for radical operations for polysinusitis, may also be employed to expose the sella turcica.

11. Exposure of the Retro-maxillary Fossa. Access to retro-maxillary tumours must be obtained behind the upper jaw, the successful exposure of this region depending on the removal of the zygoma and malar bone, so that we have to refer the operator to our method of osteoplastic resection of the zygoma for neurectomy of the third division of the trigeminal, and also to the osteoplastic removal of the malar bone for neurectomy of the second division of the trigeminal nerve at the base of the skull.

12. Resection of the Lower Jaw. This is a simple operation; but here again we must not produce unnecessary deformity about the mouth by injuring the supra-mandibular branches of the facial nerve.

On account of the simplicity and comparatively little mark it leaves, we employ a mesial incision, which divides the under lip and extends downwards as far as the centre of the hyoid. By this incision we can get sufficient access to disease in the neighbourhood of the symphysis and the greater part of the horizontal ramus of the lower jaw. One should not be tempted, unless it is absolutely necessary, to add a lateral incision, as it is apt to have an injurious effect on the mechanism of swallowing by injuring the muscles and nerves, and therefore to give rise to danger from aspiration pneumonia. Wyeth, in fact, used no other incision for the removal of one-half of the lower jaw for sarcoma; moreover, the mesial splitting of the lip gives rise to no noteworthy disfigurement.

When the disease involves the region of the angle and ascending ramus, and when

[1] Hertle, "Temporäre Aufklappung beider Oberkiefer nach Kocher," *Arch. für klin. Chir.* Bd. 73.

[2] Maas and Friedemann, *Berl. klin. Wochenschr.*, 1900, No. 52, and 1902, No. 19.

it is necessary to expose and clear out the submaxillary fossa for a malignant tumour, a lateral incision is added. On account of the facial nerve it must be placed below and not over the margin of the jaw; indeed it should pass upwards and backwards from the hyoid bone along the submaxillo-cervical crease to a finger's-breadth behind and below the angle of the jaw, and from thence up to the apex of the mastoid process (compare our *normal incision* for the superior triangle of the neck). The flap thus made is dissected up and fixed by a stitch or two to the skin of the face. In doing this, keep as near as possible to the bone by including the muscular structures in the flap (anteriorly, the levator menti, depressor labii inferioris, and depressor anguli oris, posteriorly, the buccinator and masseter). From the inner surface of the jaw are detached, anteriorly, the digastric, mylo-hyoid, genio-hyoid, and genio-hyo-glossus; posteriorly, the internal pterygoid. When the glands below the body of the jaw are diseased, the anterior and posterior bellies of the digastric are first exposed, and the entire bunch of the lymphatic glands, including the salivary glands, is then dissected up over the edge of the jaw.

It is important to saw through the anterior part of the jaw immediately after the incision through the lip has been made, and before detaching the muscles, in order that by drawing it well forward the soft parts may be put on the stretch. After dividing the muscles and the mucous membrane the jaw is drawn downwards so as to expose the coronoid process, which, along with the insertion of the temporal muscle, is snipped off with bone pliers. In disarticulating the condyle sharp instruments are to be avoided, so as not to wound the internal maxillary artery. The capsule of the joint and the insertion of the external pterygoid are torn through by torsion after all the other structures have been divided. The facial artery has already been divided and ligatured in dissecting up the soft parts. When the horizontal portion of the jaw is sawn across, the inferior dental artery is divided as it lies in the inferior dental canal, and may be plugged with a pellet of wax; when the entire half of the jaw is removed this artery is ligatured in the posterior and upper angle of the wound, either before or after the jaw is drawn downwards, or in dissecting up the internal pterygoid muscle, when the inferior dental nerve will be either cut or torn across. Just as in some cases of resection of the upper jaw, so here also it may be necessary, in order to avoid loss of blood, to ligature the external carotid above the superior thyroid, or, it may be, above the origin of the lingual. If the muscles connecting the tongue to the lower jaw have been necessarily divided, their stumps must be stitched forwards, as otherwise the tongue will fall back and obstruct the entrance to the larynx.

When the disease involves the ascending ramus, either primarily or secondarily to carcinoma of the pharynx, the jaw should be divided in front of the ramus (Langenbeck). We prefer, however, to use the same incision as that recommended for resection of the lower jaw in general rather than Langenbeck's incision, which descends vertically from the angle of the mouth (Esmarch), *i.e.* we employ an incision which is placed along a line extending from the mastoid process towards the hyoid bone, and modify its length according to circumstances. After ligature of the facial artery the lower border of the jaw is exposed immediately in front of the masseter, the periosteum is separated in front and behind, and the elevator is pushed through the mucous membrane, after which the lower jaw is divided with a keyhole-saw behind the molar teeth.

The ascending ramus is now drawn upwards with a hook, while the anterior part of the jaw is drawn forwards, the further steps of the operation being similar to those for resection of half the jaw.

When the entire half or the whole of the jaw has been removed, especially if the operation has been done subperiosteally, and the periosteum preserved, a mould (Claude-Martin) is to be made, over which the periosteum is stitched so that the newly-forming jaw may be properly shaped. Subperiosteal resection of the lower jaw, *e.g.* in phosphorus necrosis, is a simple operation. After the teeth, which are generally loose, have been removed, the gum and the periosteum are divided, and the latter is pushed back with a periosteum elevator to expose the diseased bone. This is then divided and removed.

FIG. 263 *a*.

FIG. 263 *b*.

Necrosis of the entire lower jaw. Photograph taken five months after operation.

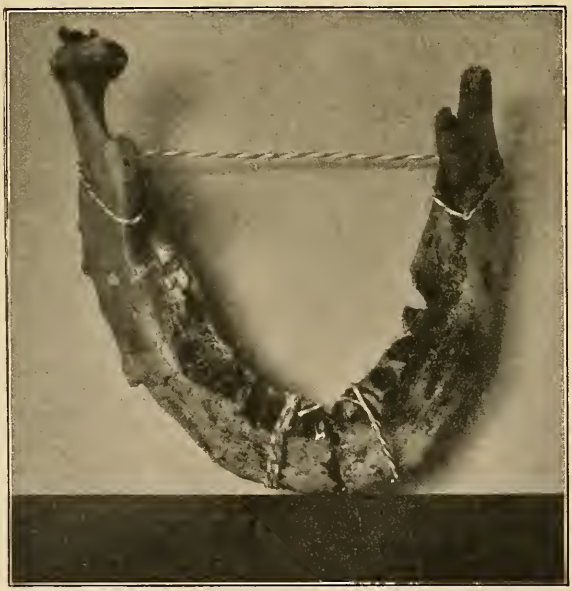

FIG. 264.—Photograph of lower jaw from same case.

Fig. 263 (*a* and *b*) shows the appearance of a patient five months after a total resection of the lower jaw where no artificial mould had been used. Fig. 264 represents the necrosed lower jaw after removal.

13. Osteoplastic Division of the Lower Jaw. In regard to the immediate insertion of an artificial mould of the jaw, Vallas and Martin assert that the skin incision must not be placed over the border of the jaw, as otherwise the mould presses on the line of suture. They advocate the use of the incision we have described, which is placed at a considerably lower level.

The wound should be completely closed without drainage, and if possible the mucous membrane of the cheek and the floor of the mouth should be united with stitches. The masseter and internal pterygoid muscles should be carefully dissected off the bone and should be subsequently united under the mould, so that the best functional results may be procured. Finally it is more advantageous to remove, rather than leave, the ascending ramus.

In former editions of this work we advocated division of the lower jaw in front of the ascending ramus for disease in the region of the isthmus of the fauces and the posterior pharyngeal wall. We are convinced, however, that ample room can be obtained even in these cases, and with the least injury, by dividing the jaw through a mesial incision (*vide* Excision of the Tongue and of the Pharynx).

We therefore regard the mesial operation as the normal method for an osteoplastic resection. The soft parts as well as the lower lip must, of course, be divided down to the hyoid bone, a method which presents no difficulty, as the dissection is carried out in the middle line in the interval between the muscles passing from the tongue to the hyoid and lower jaw. To obtain a separation of the two halves of the jaw it is necessary to divide the mucous membrane of the floor of the mouth on the affected side between the tongue and the jaw.

No disturbance of function results from splitting of the jaw, and if two drill holes are made on either side before the bone is sawn, the two halves can be so firmly united that the patient is able to open and shut his mouth without discomfort immediately after the operation has been performed (*vide* Excision of the Tongue).

14. Resection of the Temporo-maxillary Joint (Fig. 265). Resection of the temporo-maxillary articulation is performed for suppurative inflammation (often metastatic), tubercular and rheumatoid arthritis, habitual and old-standing dislocation, and for ankylosis. The chief danger in the operation lies in injury to the facial nerve, especially to the orbital twigs. A short curved incision beginning just in front of the tragus is carried vertically upwards over the zygoma, so that the skin and fascia are divided, avoiding the superficial temporal artery and vein which lie farther back, or ligaturing them—especially the vein—if they are in the way. The fascia is carefully stripped off the zygoma subperiosteally. In the course of this removal the capsule is separated below from the condyle and the joint is opened into. An elevator is then introduced and the condyle of the mandible levered out. The meniscus is now exposed and excised if necessary; the condyle is cut through with bone forceps, and the glenoid fossa scraped with a sharp spoon.

After unilateral excision mobility returns in a very short time, and even after both sides have been excised the result is satisfactory, provided that active movements are begun as early as possible, *i.e.* in two or three days if the wound is aseptic. To ensure mobility, Helferich interposes part of the temporal muscle, while Kusnakow places a piece of the masseter between the glenoid fossa and the mandible. It would be still easier to place a flap of the temporal fascia over the head of the bone. If the cartilage is retained and the muscles of mastication are not atrophied, this modification is unnecessary.

The auriculo-temporal nerve runs up behind the condyle, while the internal maxillary artery crosses below it. By the above method we once cut down and reduced a dislocation of the jaw of four months' duration, obtaining an excellent result, also in a similar case of more than a year's duration.

Difficulty in opening the jaw, due not to stiffness of the joint, but to shortening and adhesions of the soft structures, can be treated in two ways: either by separating

the soft parts from the lower jaw, or by making a false joint in front of the adhesions, by resecting as large a piece of bone as may be required (Esmarch). The operation must be varied to suit different cases.

We have obtained an excellent result in a patient in whom it was impossible to overcome spasm of the muscles of mastication by extensive subperiosteal separation of the muscles from the jaw, an operation which has also been performed by Le Dentu.

(d) Surgery of the Auditory Organ

15. Exposure of the Middle Ear (Figs. 266-268). In the great majority of cases inflammations of the middle ear (which are caused by infection from the naso-pharynx along the Eustachian tube) may result in healing, by the process of suppuration, with

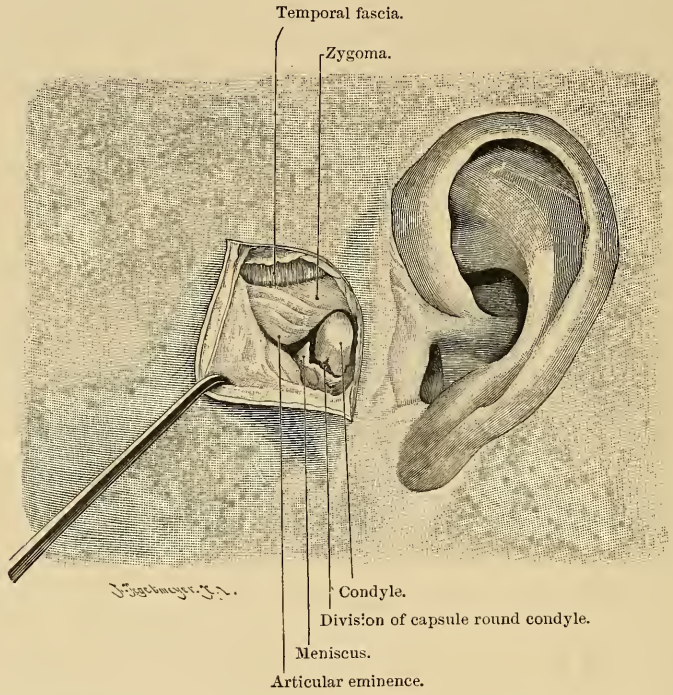

FIG. 265.—Resection of temporo-maxillary joint through an angular incision. The condyle of the jaw has been exposed and the capsule divided.

early perforation of the tympanic membrane, or when the pus is completely evacuated by incising the tympanic membrane at its lower part.

If the purulent discharge from the ear does not dry up in a short time we may conclude that the suppuration is not limited to the tympanic cavity. The floor of the cavity is flat, and therefore the flow from it is not unfavourable. The conditions are quite different when the suppuration has extended from the attic to the mastoid antrum and the mastoid cells. In this condition a free escape of pus can only take place after opening up the mastoid process, as the pus gravitates backwards and downwards, or it may be conducted from the antrum into the meatus, by removing the posterior wall of the latter.

The infective materials (most frequently diplococci and streptococci, also staphylococci), having reached the mastoid process and become stagnant, find a suitable nidus for their development, invade the thin walls, and reach the external and

internal periosteum. Perforation may take place at various points, most commonly occurring in the mastoid fossa and producing a phlegmonous swelling behind the auricle. The pus may also find its way upwards through the squamoso-mastoid suture, in which case the abscess forms above the attachment of the auricle. Lastly, perforation may take place lower down at the side of the apex of the mastoid process, the suppuration proceeding from the lower mastoid cells and causing a phlegmonous swelling under the sterno-mastoid (Bezold).

The internal periosteum of the mastoid process is the dura mater, and a periostitis in this situation is identical with pachymeningitis. Secondary to this is the development of a brain abscess in the temporo-sphenoidal lobe or cerebellum, or of basal meningitis or phlebitis of the lateral sinus, according to the site at which the transition from otitis to mastoiditis has taken place.

When the tympanic cavity is filled with stagnant pus, the result of disease in the neighbouring cavities, the infection may extend from it towards the cranial cavity, and it is especially the thin tegmen tympani through which the infected material most frequently penetrates.

If, therefore, an infective inflammation has once reached the middle ear, and if it has not subsided shortly after the escape of the exudation, the tympanic cavity, along with all its recesses and neighbouring spaces, must be freely exposed, and ready escape provided. It is interesting to observe how the fulfilment of this specially pressing indication has gradually been developed and completed in the last thirty years, until it has taken the form which we now describe as the "radical operation."

Certainly the conditions are very different when one has to deal with a recent and acute case, in which the changes are still superficial and essentially catarrhal in nature, and when the suppuration has penetrated deeply into the tissues. No doubt the radical operation, which to a large extent sacrifices the power of hearing, may often be avoided if, in acute inflammation, a complete removal of the exudation is effected at a sufficiently early period. For this purpose it suffices to open the antrum and mastoid cells, an operation [1] in the execution and exact development of which Schwartze (1873) has rendered valuable service.

16. Trephining the Mastoid Process (Schwartze's Operation). Exposure of the mastoid cells and antrum is indicated in every case where an acute inflammation of the middle ear does not at once subside after removing the cause, or after the withdrawal of the pus by paracentesis of the tympanic membrane. It is then almost certain that the exudate has extended beyond the tympanic cavity, in the first place, from the tympanic attic through the patent aditus into the antrum, and then into the mastoid cells, which in their turn are in open communication with the antrum. To open one of these cavities without opening the other is absurd. We do not speak, therefore, as in the text-books of the specialist, of "opening the antrum," but of trephining the mastoid process and its cavities.

The incision which we recommend is our auricular incision, which serves for all cases, even when a radical operation may have to be subsequently undertaken. It is very readily determined by applying the auricle against the skull, and carrying an incision down to the bone from the apex of the mastoid process alongside the posterior border of the auricle as far as its upper end. Should it be found necessary to enlarge the incision, all that is required is to carry it farther along the upper border of the auricle in order to give sufficient access from above as well as from behind. The only argument that can be urged against the incision is that the scar is not so well hidden behind the auricle as when the incision is made immediately behind the auricle. One or two spurting vessels are secured and the periosteum is separated forwards, as far as the meatus, with a sharp raspatory. At the junction of the upper and posterior walls of the osseus meatus will be found the more or less well-developed bony projection known as the supra-meatal spine of Bezold, but almost without exception the posterior end of the linea temporalis can be seen and felt distinctly. By applying a small gouge in this position and removing the bone directly inwards parallel to the osseus auditory canal, the cavity of the antrum will

[1] Originally carried out by Petit and Sassen, according to Heine.

be reached with certainty at a depth of 1·5 cm. Before the chisel is made to penetrate too deeply, it is desirable to chip away the superficial cortical layer from below in a backward direction from the above-mentioned area, so as to open the mastoid cells, at the same time retaining the cortex of the process in front.

When the cells (which lie for the most part quite superficially) have been reached, it should be noted if the suppuration has actually involved them, as in this event one has the assurance that the route for any further procedure has been opened up. The vertical portion of the lateral sinus may reach very far forwards, and although an indication of this condition is to be found in the oblique (sloping forward) instead of the vertical direction of the "*planum mastoideum*" (at the base of the mastoid process), it is nevertheless better to satisfy oneself as to the existence of this unfortunate complication by direct exposure.

After opening the cells which contain pus, it is easy, with a small Lüer's gouge-forceps, to remove the cortical coverings of all the cavities, to clear out the septa with a sharp spoon, and, by following up the deeper and upper cells, to open up the antrum until it is rendered perfectly patent. Care must be taken in using the sharp spoon that the approach to the attic is thoroughly exposed, so that free drainage from the attic is provided. In the lower part of the aditus the projection formed by the aqueduct of Fallopius and above it the external semicircular canal must not be injured.

When the operation is undertaken merely for acute cases there is no question of suture, still less of a plastic operation. After the cavity is thoroughly washed with sterilised salt solution it is swabbed with 10 per cent carbolic-alcohol solution and stuffed with iodoform gauze. Provisional sutures are passed through the edges of the wound, but are not tied until between the sixth and eighth day (secondary suturing); a drainage tube being introduced for a few days.

But it is quite another matter when the favourable opportunity has passed, for when caries and necrosis have appeared there is no longer a prospect of rapid healing. For the chronic cases of middle ear suppuration the radical operation is to be performed.

17. Radical Operation on the Middle Ear. The term "radical operation" as originally introduced by Siebenmann, was applied to cases where the antrum is so thoroughly opened that no special measures are required to keep the cavity open and clean (even in cases of cholesteatoma). It was at a later period that clearing out the tympanic cavity was included in the term.

By the radical operation (for the development of which, in its present form, we are indebted to Zaufal and Stacke) we understand the exposure not only of the mastoid cells and antrum, but of the entire tympanic cavity, including the attic (*recessus epitympanicus*) by the additional removal of the posterior and part of the superior wall of the osseous meatus. It is interesting to follow from Rheinhardt's minute description how this operation has developed step by step to the attainment of a surgically-correct procedure for the removal of infectious exudate and necrotic material. What is effected in the radical operation is nothing more than what surgeons have long done for every chronic suppurative bone affection.

After it became evident that Schwartze's operation, while reliable in acute middle-ear suppuration, was often unsuccessful in chronic cases, an endeavour was made to find a means of thoroughly exposing the tympanic cavity along with the antrum. Wolf had followed the plan of removing part of the posterior wall of the osseous meatus. Hartmann and Küster removed the whole of the posterior wall, while Bergmann added the removal of the upper wall in order to enable the tympanic cavity and the ossicles to be thoroughly cleaned out, Zaufal making the further addition of resecting the *pars epitympanica* between the antrum and the meatus. Lastly, Stacke opened the tympanic cavity directly by separating forward the cutaneous portion of the auditory canal and forming a flap from it to cover the raw bony cavity with epidermis, so as to provide a widened, instead of a too narrow, auditory canal, leading directly into the antrum and the middle ear.

Stacke's operation modified by Schwartze, Körner, and Liebermann is as follows :—

Bearing in mind the plastic character of the operation, we make the incision vertically downwards immediately behind the attachment of the auricle, dividing and ligaturing the posterior auricular artery. The periosteum is stripped forwards to the bony meatus, and backwards over the mastoid fossa, while the cutaneous portion of

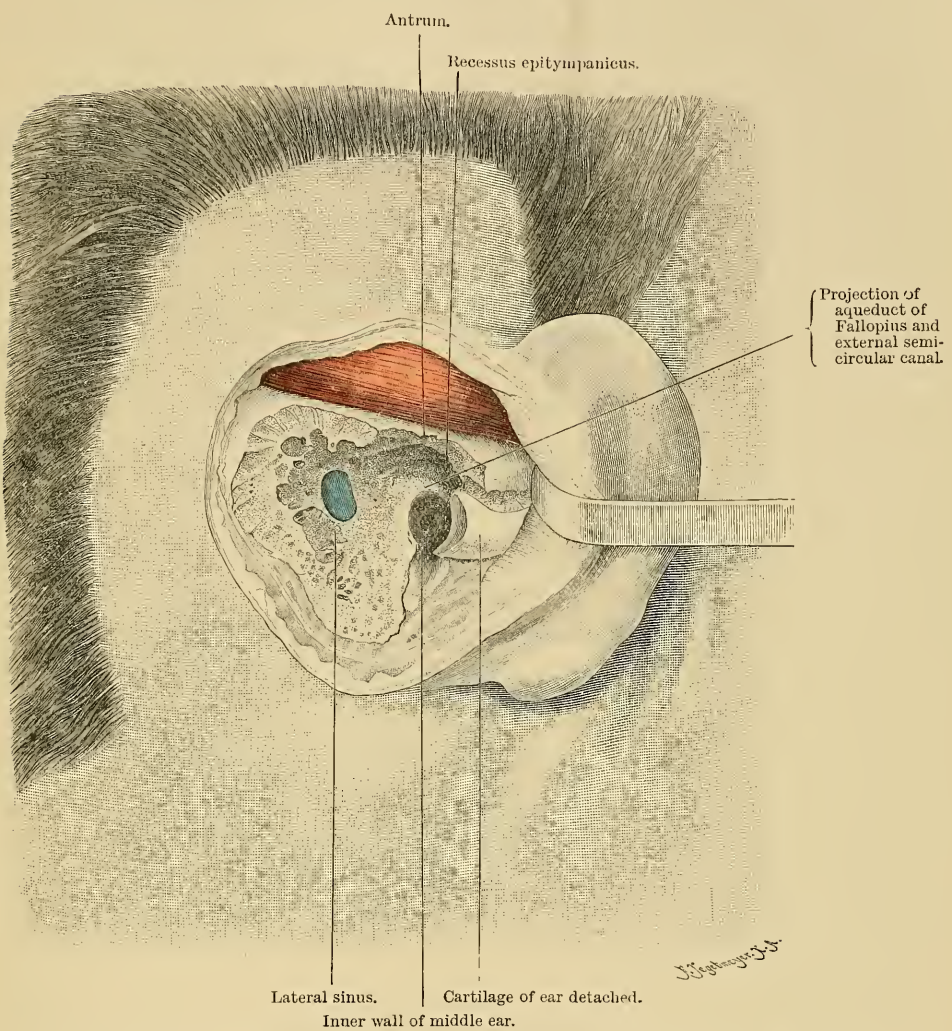

FIG. 266.—Radical operation on middle ear. The cartilage of the auricle has been divided and retracted forwards, and the mastoid process freely opened up, exposing the antrum with the tympanic attic. Immediately below the latter is seen the pale projection formed by the aqueduct of Fallopius and the external semicircular canal. The middle ear is freely exposed, the lateral sinus being seen posteriorly.

the meatus is detached with an elevator and retracted forwards with a blunt hook. Stacke divides the cutaneous part of the meatus down to the tympanum.

The mastoid cells and antrum are then exposed by applying the gouge immediately behind the external auditory meatus and below the supramastoid crest as already described.

The tympanic attic must now be thoroughly exposed and made continuous with

the middle ear and the cavity of the antrum through a wide opening bevelled downwards and outwards.

This is effected by chiselling away the posterior wall of the bony meatus, and to avoid injuring the deeply-placed external semicircular canal and the aqueduct of Fallopius immediately below it, which are recognised as two pale-coloured elevations in the lower part of the epitympanic recess, a probe is inserted into the space occupied by the membrana flaccida, which is generally found to be already perforated, and is passed from the meatus into the open antrum, the posterior and part of the superior wall of the meatus being obliquely gouged away. By this method the tympanic attic and the antrum, both of which are covered by the tegmen tympani, are exposed, and if necessary the incus and malleus may be extracted with a hook or forceps as recommended by Schwartze if they are necrosed, the stapes being left untouched.

Fig. 267.—Exposure of the middle ear. The posterior bony wall of the auditory canal has not yet been removed; a probe has been passed from the external meatus through the aditus ad antrum, so that the bone above and below may be chiselled away without injury to the aqueduct of Fallopius and the external semicircular canal, which, for purposes of clearness, are here shown opened. (From a dissection by Tramond.)

When the operation has been properly performed the wound should widen out towards the surface in a funnel-shaped manner: there should be no overhanging bony edges, and one should be able to see freely into the tympanic cavity. Rheinhardt recommends that, in addition, the upper wall of the osseous canal should always be chiselled away because it contains bony cells. A grooved director is inserted beneath the cartilaginous portion of the canal, which is divided longitudinally as high up as possible. Externally the incision is carried vertically downwards along the margin of the concha so as to produce a large flap, which is turned down, fixed by a suture, and pressed backward against the raw bony surface by means of iodoform or xeroform tampons introduced from the auditory meatus. The edges of the incision are fixed with a couple of sutures, and, after a few days, if the wound runs a favourable course, they should be definitely closed by secondary suturing.

Siebenmann splits the cutaneous layer of the meatus in its long axis and carries the end of the incision upwards and downwards in form of a Y, afterwards dissecting the cartilage out of the flap and fixing the flap against the posterior wall of the bony meatus by means of one or two deep catgut stitches. By this method he obtains a wide external meatus, which leads directly down to the cavity in the bone. The wound behind may be entirely closed by means of secondary sutures. A Thiersch graft, the raw surface of which is directed outwards, may then be introduced through the auditory meatus, so that the latter may become covered over with epidermis. If a cholesteatoma is present, Siebenmann does not scrape the epithelium away but uses it as a superficial epithelial covering.

Notwithstanding the removal of the tympanum and the tympanic ossicles, the power of hearing is preserved.[1] Indeed a marked improvement in hearing often results after removal of the diseased ossicles, as the remains of the tympanum become adherent to the stapes.

18. Suppuration of the Labyrinth. In suppurative conditions of the labyrinth, characterised by nerve-deafness, giddiness, nausea and nystagmus, Milligan[2] advises that a search should invariably be made for a fistulous track leading from the middle ear, while at the same time he advocates the opening of the vestibule through the foot-plate of the stapes. A cerebellar abscess following suppuration in the labyrinth may be reached through the inner wall of the open antrum on the posterior surface of the petrous temporal.

19. The Operation in Intracranial Complications. Körner and Macewen deserve the credit of having demonstrated the method by which extensions of suppuration towards the cranial cavity are to be reached with the greatest certainty. The radical operation, or the opening of the mastoid cells, or antrum, not infrequently leads, in acute cases, down to the dura and the wall of the lateral sinus. Heimann has proposed, especially in the suppurative forms of otitis associated with severe general symptoms, or cerebral complications of any kind, that in the operation to expose the middle ear the posterior, and eventually also the middle, fossa of the skull should be opened. Much can be said for this, and one never regrets having been too thorough. When signs of intracranial disease or of sinus thrombosis exist, the skull and the lateral sinus must be opened at the site of the diseased bone. It is always the best plan to begin the operation in the manner described above, viz. by the thorough exposure of the middle ear and its accessory cavities.

By adopting this plan one follows the route which the suppuration has taken, viz. towards the middle fossa of the skull, through the tegmen tympani, and towards the posterior fossa, through the bony wall of the lateral sinus.

In this way subdural abscesses and thrombosis of the sinus are best exposed, and with the least possible damage. Free drainage must be provided for the whole extent of the abscess. In thrombosis of the sinus its vertical portion must be exposed by chiselling away the middle third of the mastoid process in its whole length as far as its apex, any bleeding from the emissary mastoid vein being arrested by a plug of wax. If the lumen of the sinus be opened, the vessel should, as recommended by E. Meyer and Withling (Trautmann), be plugged by a xeroform gauze tampon inserted between the wall of the sinus and the bone, as far down as the jugular bulb, and upwards as far as the genu of the sinus. Infectious thrombi can then be scooped out from the sinus, which should be plugged by pressure from without, or, when it is more extensively opened, should be packed with xeroform gauze.

If the thrombosis extends beyond the genu of the sinus, bleeding may take place from the superior petrosal sinus, which must then be plugged, but the thrombus must be followed into the horizontal limb. Should the thrombus extend downwards below the bulb, its lower limit must be ascertained by palpating the neck. The internal jugular vein is then thoroughly exposed and ligatured below the thrombus, the vein being slit up and the thrombus scraped out, with the object of preventing or curing the secondary bacteræmia.

20. Trephining for Cerebral Abscesses. Abscesses of the temporo-sphenoidal

[1] *Vide* Heath, *Lancet*, Dec. 1904. [2] *Lancet*, Feb. 1904.

lobe and cerebellum which cannot be directly reached from the middle ear on account of the absence of a continuous macroscopic track of suppuration, or on account of their depth, must be dealt with by direct trephining of the skull.

Trephining for temporo-sphenoidal abscesses is performed by prolonging the auricular incision (Fig. 268) parallel to the upper margin of the auricle as far as its anterior attachment. By separating the periosteum as far as the osseous auditory canal we expose the area of the squamous portion of the temporal bone above and

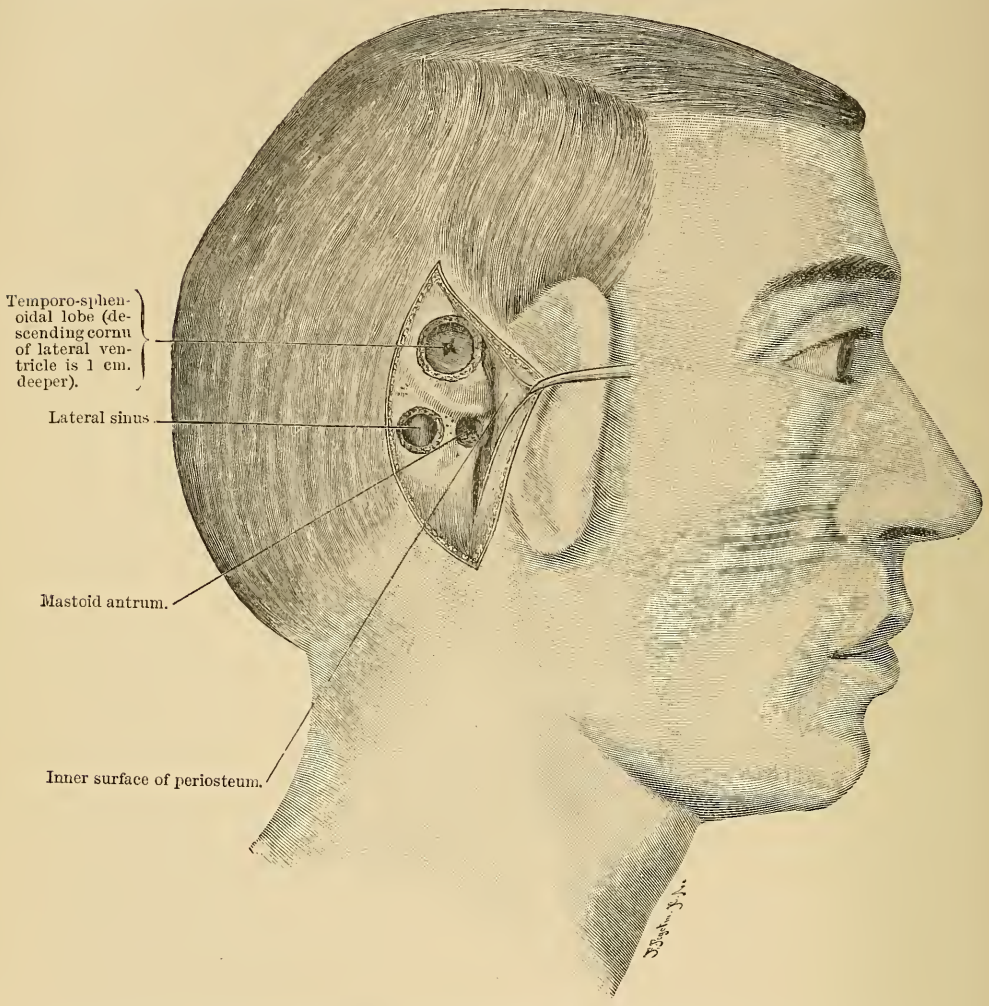

FIG. 268.—Opening the mastoid antrum and the lateral sinus. Exposure of the temporo-sphenoidal lobe and puncture of the descending horn of the lateral ventricle.

behind the ear, this area leading most certainly to the floor of the middle fossa, and by separating and lifting up the periosteum we can ascertain if an abscess exists between it and the bone. The trephine-opening lies above the posterior extremity of the temporal line, which turns horizontally forwards to form a definite ridge becoming continuous with the root of the zygoma. After division of the dura, the position of the abscess can be ascertained by palpation or puncture, should the changes in the membranes not be sufficient to indicate it. After drawing aside or ligaturing

the vessels of the pia the abscess is opened with a knife, and the opening dilated with forceps, the opening being made large enough to allow the cavity to be cautiously and thoroughly washed out. The cavity must be kept open for a few days and dusted with boracic acid and iodoform, or dressed with a xeroform tampon, the trephine-opening being stuffed with a xeroform tampon as a permanent dressing.

Trephining for an abscess of the cerebellum is performed after a previous opening of the groove for the lateral sinus, as it frequently happens that its disease forms the intermediate link in the chain of extension of suppuration. A horizontal incision is carried along the superior curved line of the occipital bone, the periosteum being separated backwards and downwards so as to expose the posterior fossa, which is opened below the lateral sinus.

(e) Surgery of the Salivary Glands

The method by which the sublingual gland is to be excised in cases of chronic inflammation, or tumour, is indicated by the position of the swelling.

21. Submaxillary Salivary Gland. In connection with the submaxillary gland it is to be observed that the incision may readily injure the cervical branch of the facial nerve to the platysma, wherefore it should not be made too high up, *i.e.* close to the border of the jaw, while, further, the platysma should be stitched separately, as we have already indicated in our introduction.

22. Excision of the Parotid. Extreme care has to be exercised in incising the parotid in cases of phlegmonous parotitis (especially the metastatic forms), because the deep incisions that are necessary may readily lead to injury of the facial nerve or to the formation of a salivary fistula. The incisions should therefore be made with careful dissection, and if possible should be in the direction of the branches of the pes anserinus. No general anæsthetic should be administered.

In the extirpation of a benign tumour of the parotid, *e.g.* lymphoma, fibroma, chondroma, myxoma, sarcoma, and the various mixed tumours, everything depends on defining the boundary between the tumour and the parotid tissue in which it is embedded, while every piece of tissue which resembles a nerve fibre should be mechanically stimulated before it is cut across, to ascertain if contraction of the facial muscles occurs. One has often to dissect out the pes anserinus entirely before the tumour can be separated.

A long vertical incision is required in dealing with malignant tumours of the parotid (sarcoma or carcinoma), beginning on the temple two fingers'-breadth above the zygoma and running vertically downwards in front of the tragus as far as a point on the anterior border of the sterno-mastoid two fingers'-breadth below the angle of the jaw. The skin is dissected up both in front and behind, and the lower border of the tumour defined as quickly as possible by incising the deep cervical fascia and exposing the anterior border of the sterno-mastoid, the external jugular vein being divided between two ligatures. If the tumour is adherent to the muscle, a portion of the upper end of the sterno-mastoid must be removed with it up to the mastoid process, where the soft parts behind the tumour are divided down to the bone. In freeing the lower border of the tumour the great vessels of the neck are exposed, the internal jugular vein being carefully isolated and any small venous branches tied.

A finger can now be passed under the tumour and the latter lifted up off the posterior belly of the digastric, which must be divided if adherent to the growth. The external carotid which is seen running upwards beneath the digastric and sterno-mastoid is readily exposed and divided between two ligatures. By this method both the styloid process with the muscles arising from it, and the anterior aspect of the mastoid process are now free. The parotid fascia in front is divided down to the masseter, and the tumour is separated from the angle of the jaw upwards, removing any adherent portions of the muscle. Not infrequently numerous veins are encountered in the cut surface of the muscle, which must be tied. At the anterior

border of the tumour below the zygoma the transverse facial artery and Stenson's duct are divided. The temporal fascia is next divided above the tumour, cutting across the superficial temporal artery and vein between two ligatures. The tumour is now freed from the zygoma above and from its anterior connections as far back as the posterior border of the ascending ramus of the jaw. If it is adherent to the joint capsule, the latter must be removed as well. No real harm results from opening into the joint. Immediately behind the joint, the external carotid divides into the superficial temporal and internal maxillary arteries, which are caught with forceps and divided.

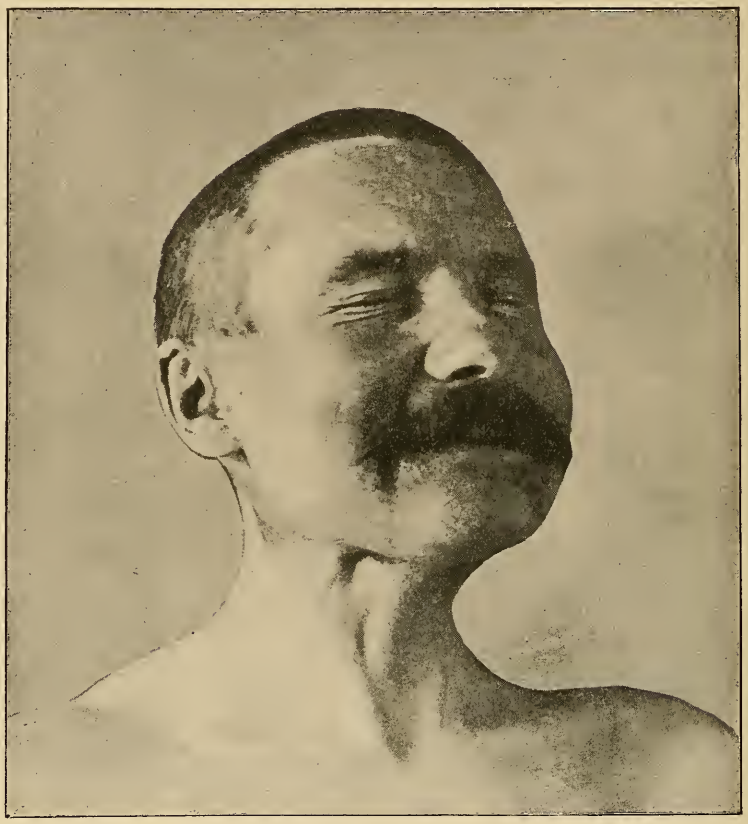

FIG. 269 shows the action of the facial muscles after the wound for splitting the cheek transversely has healed.

One has still to detach the tumour from the cartilage of the external auditory meatus, part of which may have to be removed. Any enlarged lymphatic glands along the lower border of the parotid should also be excised. If the tumour is adherent to the periosteum, a superficial layer of the mastoid process must be detached with the chisel. In this way a malignant tumour of the parotid may be successfully excised, without much loss of blood, the only serious damage being that entailed on the facial nerve, which is, of course, unavoidable.

When there are diseased glands in the neck, the incision should be prolonged down the anterior border of the sterno-mastoid as far as the omohyoid (*e.g.* in malignant disease of the tongue), and a second incision carried forwards in the fold between the floor of the mouth and the neck (*vide* our normal incision for the superior triangle of

the neck), with a thorough dissection of the glands below the jaw and beneath the sterno-mastoid.[1]

(f) Surgery of the Mouth and Pharynx

The structures in the mouth and pharynx can also be rendered accessible without osteoplastic resection of the lower jaw. An excellent method is by a *transverse*

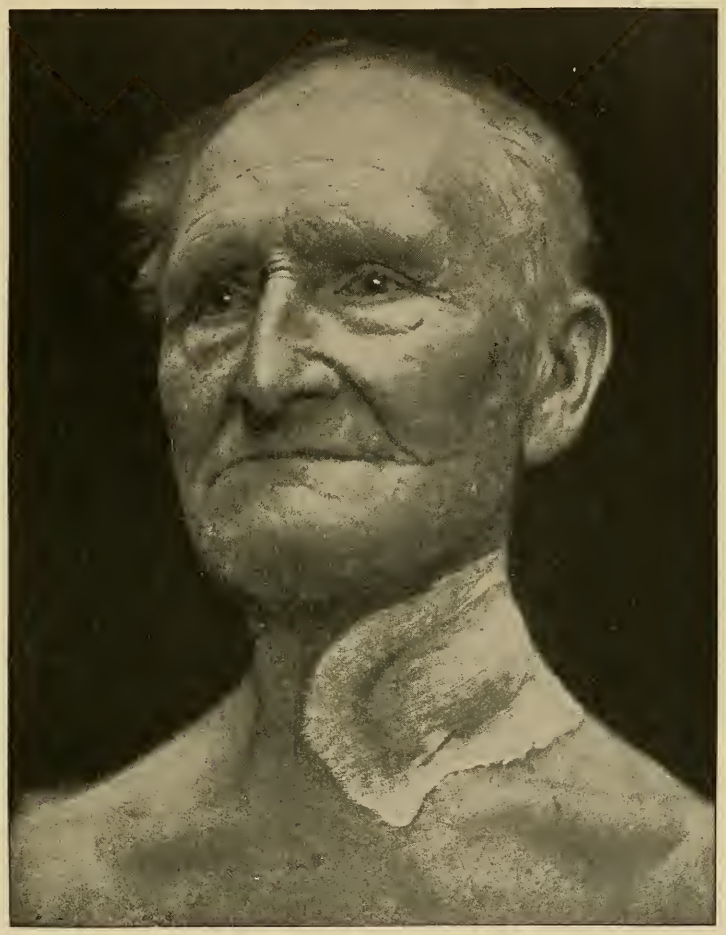

FIG. 270.—Patient after excision of the tongue by splitting the cheek.

incision through the cheek (Fig. 270), as recommended by Roser for exposing the lingual nerve; the incision extends from the angle of the mouth transversely backwards, parallel to the branches of the facial nerve, as far as the masseter, dividing skin, orbicularis oris, buccinator, and mucous membrane. Although the scar tends to become drawn in by contraction, the resulting deformity is inconsiderable (Fig. 269), because the play of the features is in no way diminished, as the branches of the facial

[1] Bedardo and Leriche (*Rev. de chir.* Bd. 12, 1906) recommended resection of the posterior border of the ascending ramus of the jaw, including the condyloid process to ensure total resection.

nerve have been preserved. *Stenson's* duct and the transverse facial artery lie above the incision, but the facial artery is divided and requires two ligatures. Krönlein has employed this incision in his retrobuccal method for resection of the trigeminal nerve, but he does not split the angle of the mouth.

As it is often necessary to obtain free access to the structures of the mouth and upper part of the pharynx up to and including the isthmus of the fauces, it appears to us to be a much better plan to make a mesial incision through the lower lip, jaw, and floor of the mouth. Sédillot had already employed it to a certain extent in excising the tongue, but we have made much more extensive use of it. When properly carried out it gives excellent access, is quite bloodless, does not leave the slightest disfigurement, and not even a temporary disturbance of function. It is important that the dissection be made exactly in the middle line between the genio-hyoids and genio-hyo-glossi. The mucous membrane of the floor of the mouth, on the diseased side, must be divided sufficiently far back to allow of thorough separation of the halves of the jaw. We use for this purpose an ecarteur of our own (Fig. 271). Subsequently the jaw must be firmly united with wire sutures, so that movement may be begun at an early stage. A periosteal suture is unnecessary.

Fig. 271.

If occasionally healing is delayed by slight necrosis, the function of the jaw is during this time not interfered with.

23. Incisions into the Tongue and at the Floor of the Mouth. These are only to be made after thoroughly opening the mouth by the introduction of a suitable gag, and after drawing forward the tongue by means of a silk loop carried deeply through it in the mesial sagittal plane. A considerable degree of anæsthesia is necessary before the mouth can be satisfactorily opened, especially in closure of the jaws caused by inflammation or by other painful infiltration of the soft parts between the upper and lower jaws, or in connection with the latter. Incisions may be made upon the dorsum of the tongue without fear of injuring the larger branches of the vessels and nerves, and whenever practicable, the middle line should be selected, as causing least injury.

The larger vessels, namely, the lingual and sublingual arteries and veins, the hypoglossal, lingual, and posteriorly the glosso-pharyngeal nerves, along with *Wharton's* duct and the ducts of *Rivini*, lie laterally and at the floor of the mouth, so that the nearer the incision is kept to the jaw the more certain are all those structures to be avoided. The lingual vessels and nerve may be exposed close to the edge of the tongue, under the inferior lingualis and upon the outer aspect of the genio-hyo-glossus. Farther back the artery is covered by the hyo-glossus. Near the tip the vessels wind towards the under surface of the tongue. Prophylactic ligature of the lingual artery is to be recommended when there is danger of severe hæmorrhage following incisions into the tongue.

24. Excision of the Tongue from the Mouth. The same method of excision may be applied to simple tumours as well as certain malignant tumours (preferably carcinoma) if the latter are circumscribed on all sides and movable. In the case of malignant tumours, however, a thorough removal of all the glands must always be made in addition.

The question then presents itself: What is the limit at which one may under-

take the removal of a carcinoma of the tongue from the mouth without a preliminary operation being required? Innocent tumours can be removed from the mouth with few exceptions.

The answer is: The tumour must be freely movable on the jaw and the floor of the mouth, and must be so placed that after the application of Museux's forceps, one can cut through healthy tissue behind it, with complete control over the bleeding. Under these circumstances the operation can be designated "the early operation for cancer of the tongue."

If we consider the permanent results of excision of the tongue for cancer, one is driven to the conclusion that, despite improvements in technique, the tongue is an organ in which the least gratifying results are obtained. The immediate mortality has, however, been greatly diminished. Between 1872 and 1889 we operated on 69 cases of cancer of the tongue, the results of which were published by Dr. Sachs. Between 1890 and 1903 our operations numbered 62 more. These cases have been followed up by Dr. Boissonaz, and the results will shortly be published in detail.

The latter series included many more advanced and difficult cases. In only 10 could the operation be performed from the mouth without a preliminary operation, while in 13 the cheek had to be split transversely; in 23 the jaw was divided in the middle line, in 4 laterally, while in 3 cases it had to be partially resected. In 7 cases complete excision of the tongue from its root was undertaken.

Of those operated on from the mouth none died; and of those in which the cheek was split one died of retro-œsophageal abscess with pleurisy and pericarditis; while of the complete excisions only one died—of pneumonia. It will therefore be observed that the operation is only exceptionally fatal, two deaths in 30 cases representing a percentage mortality of 6·6. Of the cases in which the jaw was split in the middle line 4 died, and of those in which it was divided laterally 2 died, thus giving a mortality of 14·51 per cent in the complicated cases.

We were able to obtain the subsequent history in 57 of the 62 patients. Only 5 may be regarded as radical cures, a sufficiently long interval having elapsed. In one case recurrence took place after three years, in another after ten years. Six patients who have been under observation for less than three years are in perfect health up to the present time, so that if we regard all these 6 cases as cured, our statistics as regards radical cure would be 22·8 per cent, but in absolutely certain cases, *i.e.* up to seven years 16·2 per cent have remained free of recurrence.

The importance of early operation is shown by the fact that 40 per cent of the permanent cures of lingual cancer were in cases where the operation was performed through the mouth with or without splitting of the cheek.

These results are by no means ideal, and we believe that, apart from the great importance of early operation,[1] this is largely due to the distribution of the lymphatics from the tongue which is specially favourable to the dissemination of the cancer elements. Küttner and Poirier state that the lingual lymphatics drain into very different lymph gland territories in the neck, those from the tip of the tongue leading to the suprahyoid glands which are situated in the middle line above the hyoid bone and often into glands still lower, and those from the margins of the tongue going to the lymphatic glands around the submaxillary gland in the digastric triangle; those from the centre and edge of the tongue proceed to the bifurcation of the carotid, more especially to a definite gland at the lower border of the posterior belly of the digastric, finally communicating with the chain of glands surrounding the sheath of the great vessels as far as the crossing of the omohyoid muscle. A gland of larger size occupies the angle between the omohyoid and the sterno-mastoid, *i.e.* "the omohyoid gland," and it is singularly liable to infection, of the existence of which gland we are convinced not only by Poirier's admirable injected dissections, but by our own experience.

[1] One has only to look at Butlin's results from very early operations to be convinced of how decisive this factor is: out of 14 cases 10 were free from recurrence after three years, while 4 had died of recurrence in glands.

We were recently able to observe the results of early operation in several cases in which no local recurrence took place, but in which large cancerous masses had developed in the glands at the angle of the jaw on both sides, no glands having been removed at the operation.

There is still another point which must be referred to in connection with the radical operation for cancer of the tongue, viz. that the glands on both sides of the neck may be affected. A short time ago we saw, along with Poirier, a man in whom a small epithelioma had been removed from the edge of the tongue, and in whom Poirier had thoroughly removed all the glands on the same side of the neck. There was no recurrence either on that side of the neck or in the tongue, but a large glandular swelling appeared a year after operation below the angle of the jaw on the opposite side.

What, then, is to be regarded as the ideal operation in the early stage of cancer of the tongue? The ideal operation consists in an excision of the tongue through healthy tissue, while the glands in the middle line and on both sides of the neck must be systematically removed in every case. The following is a description of the method modified by Poirier, which we regard as the best, and which we have adopted in the case of circumscribed tumours at the margin of the tongue.

An incision is made along the whole length of the anterior border of the sterno-mastoid, dividing skin, platysma, fascia, and also the transverse cervical nerve, and either avoiding or dividing the external jugular vein and the great auricular nerve. The muscle is drawn backwards and the great vessels are exposed. The omohyoid gland is next looked for at the point where the omohyoid muscle crosses the vessels, and is separated, after which the whole chain of glands is dissected up in one mass along the sheath of the vessels as far as the posterior belly of the digastric, the operator being careful to avoid the descendens hypoglossi nerve. Only small branches of the internal jugular vein require ligature.

At the upper end of the incision the glands are dissected out as high as the lower border of the parotid, the spinal accessory nerve, if not involved in the glands, being preserved.

A second incision is then made in the region of the bifurcation of the carotid following the line of our normal incision for the neck, *i.e.* from the mastoid process to the body of the hyoid bone. The skin is dissected up, the external jugular and some smaller veins are ligatured, and the flap is retracted upwards over the edge of the jaw, after which the suprahyoid glands lying in the middle line between the two anterior bellies of the digastric muscles are sought for.

The submaxillary gland is now separated from below along with the enlarged lymphatic glands which are often in close contact with it both in front and behind, a gland between the angle of the jaw and anterior border of the internal pterygoid muscle being carefully dissected out, the facial vessels clamped above and the sub-maxillary fossa thoroughly cleared. The facial and a few smaller veins are then tied and divided.

Finally, the external carotid artery, round which the hypoglossal nerve is seen to hook, is ligatured above the origin of the superior thyroid artery, allowing the operator later on to excise a carcinoma on this side of the tongue through the mouth with practically no resultant bleeding.

After a short interval the glands on the opposite side are removed in a similar manner without, however, ligature of the carotid. Poirier has occasionally seen swelling of the face from interference with the lymphatic flow follow operation on both sides, a result which may be obviated by operating in two stages.

Having removed the glands on the affected side, we remove a growth which is circumscribed and easily accessible, by the following method:—Under continuous anæsthesia, and with the mouth kept open by Whitehead's gag (which is least in the way and retains itself in position), the tongue is drawn forcibly forwards with a pair of tongue-forceps and the mucous membrane divided 1 cm. wide of the growth. By beginning the incision on the floor of the mouth, one is able to expose the vessels and nerves at an early stage, and to ligature those entering the portion of tongue to

be removed. The part to be excised is pulled forwards with Museux's forceps, which firmly grasp healthy tissue, and after defining the edges of the induration with the finger, we freely remove the growth by cutting with scissors or knife fully 2 cm. from its margin. As the carotid has been tied the bleeding is very slight, so that only a few pairs of forceps need be applied.

Before excision of the growth, however, it is convenient to transfix the tongue immediately in front of and behind the line of incision with two loops of silk, so that when the latter are tied it is easy to unite the edges of the wound with a deep continuous suture. A second superficial suture is then inserted to bring the epithelial edges into accurate contact, for which purpose Socin's aluminium bronze wire can be conveniently utilised.

It is unnecessary in the case of small growths to ligature the external carotid. Small-sized ulcers can be excised without either pain or hæmorrhage under local anæsthesia (novocain and adrenalin). Five minutes should elapse before the incision is made in the tongue. A 1 per cent solution of novocain should be used, to a gramme of which 1 min. of adrenalin has been added.

Heidenhain also strongly advocates extensive excision of the glands in cancer of the tongue as well as in cancer of the lip and other parts of the face, performing the whole operation in one stage. To ensure against local recurrence he makes a point of dividing the tongue transversely even when only one side is affected, the patients regaining the use of the muscles of the root of the tongue and floor of the mouth in a remarkable manner.

On the other hand, we have seen a number of cases where local recovery after circumscribed excision was complete, but where fatal recurrence took place in the glands. Even routine division of the whole breadth of the tongue, leaving its base and the floor of the mouth, can certainly not be regarded as a radical removal of the disease in very many cases.

To confirm this statement, one need only examine the results obtained by Butlin, who does not perform a complete excision in circumscribed cancers of the tongue. Of 14 cases, 10 were free from recurrence after three years, while 4 died from recurrence in the glands. In 38 cases where the disease recurred in our practice, in only 9 did it recur locally.

25. Operation for Advanced Cancer of the Tongue. When a lingual cancer can no longer be removed from the mouth without a preliminary operation, simultaneous removal of the primary tumour and the glands is to be avoided, because infection of the large wound in the neck will almost certainly occur and interfere with recovery.

Difficult excisions of adherent glands have the disadvantage that they involve cutting across numerous vessels, both arteries and veins, as a result of which the nutrition of the tissues in the corresponding areas of the mouth and tongue is impaired, and the edges of the wound undergo more sloughing than if one waits for the re-establishment of collateral circulation.

If the excision of the glands is undertaken secondarily, the glands are often found to be enlarged by inflammatory infection from the mouth, thus increasing the difficulty of the operation, and frequently necessitating its postponement.

It is preferable first of all to clear out the glands on both sides of the neck, as already described, and then, after the wound is healed (which, despite its size, may occur in the course of a week) to undertake the excision of the tumour in the tongue eight days later.

If the wound is to be kept free from serious infection, and if aspiration-pneumonia is to be prevented, it is essential to have the teeth, mouth and pharynx thoroughly cleansed by scraping away all tartar, by extracting all bad teeth, and by cauterising all ulcerating patches, an anæsthetic being often required to effect this when the mouth cannot be fully opened. Small abscesses and collections of decomposing matter in the crypts of the tonsils should be disinfected after their cavities have been carefully split up.

We would lay stress on the importance of not injuring the mechanism of swallowing more than is necessary, *i.e.* the muscles of the floor of the mouth tongue and

pharynx, with their nerves of supply. Further, free escape must be provided for the discharge and secretions from the mouth. It is only by careful attention to these two points that the danger from decomposition of the exudation from the wound can be reduced to a minimum. Again, the remarks we have already made about the half-sitting position the patient is to occupy during the operation, and as long as he is in bed, must be carefully attended to.

We still prefer to use the thermo-cautery to divide the muscles, in order to limit the primary infection of the freshly cut surface.

On the other hand, we no longer pack the larynx or perform a preliminary operation to control the hæmorrhage, this constituting an important advance in our present procedure. The great advantage of a tracheotomy is that the administration of the anæsthetic is simplified. We give ether by the drop method after having administered tea and brandy and a hypodermic injection of morphia half an hour beforehand.

Our "normal procedure" now consists in dividing the jaw in the middle line in all cases where the cancer extends as far back as the isthmus of the fauces, and where it has involved the arch of the palate, the fold passing to the upper jaw, the walls of the pharynx, and the soft palate. The division is performed by a modification of Roux and Sédillot's method. It can be effected with a minimum of bleeding, and gives ample room, if properly carried out, to expose and remove even pharyngeal cancer in the region of the isthmus of the fauces. No real injury is done by this method, as the jaw is sutured back in position, and movements can be performed at once without pain. The incision through the lip, if carefully sutured, leaves a hardly perceptible scar. The method has the following advantages:—The hæmorrhage is very slight, as it is more effectively controlled; the secretions of the wound are drained away in front of the hyoid much more satisfactorily; and, what is most important to our mind, by preserving the muscles of deglutition along with their nerves a better functional result is obtained than by any other method. This non-interference with deglutition is of the greatest importance in preventing secondary aspiration-pneumonia, the greatest danger which threatens the patient. It is astonishing to see how patients can swallow on the same day, on the following, or at most the third day after this operation, and hence they are able to get rid of the wound secretions and prevent their entry into the larynx.

We will take as an example a carcinoma situated far back on the side of the tongue, involving also the floor of the mouth, the anterior pillar of the fauces, the soft palate, and the lateral wall of the pharynx. The operation is performed in the following manner:—An incision is made in the middle line through the lower lip down to the bone, and extending as far as the hyoid bone, the lymphatic glands in the region of the middle line being removed and forceps applied to the divided vessels in the lip. Two holes are then drilled, without detachment of the periosteum, through the jaw on either side of the middle line, and the latter is sawn through in the interval between the first and second incisors on the affected side, a fine saw being used so that the attachments of the genio-hyoids and genio-hyo-glossi to the genial spines are left intact. Sharp hooks are inserted into the sawn surface, the mylo-hyoids and digastrics are separated in the middle line and the outer surface of the genio-hyoids and genio-hyo-glossi is reached. The two halves of the jaw are then held forcibly apart with our ecarteur shown in Fig. 271.

The tongue is drawn out of the mouth and towards the healthy side by means of a loop of silk passed through it. If this cannot be done owing to the extent of the disease it must be raised up with a finger passed behind the root of the tongue. The mucous membrane of the floor of the mouth is then divided backwards, as it tears close to the jaw if it is pulled on too much. This exposes the lingual vein, running backwards and outwards across the lateral surface of the hyo-glossus muscle, and the lingual nerve passing forward close to the edge of the tongue immediately under the mucous membrane. The hypoglossal nerve is seen crossing the outer surface of the hyo-glossus and then passing forward towards the middle line, to enter the muscular fibres of the genio-glossus. The lingual artery passes forward and

upward between the hyo-glossus and genio-hyo-glossus; it is clearly visible and can be easily ligatured at a later stage. The hyo-glossus is divided [1] and, as in all muscular

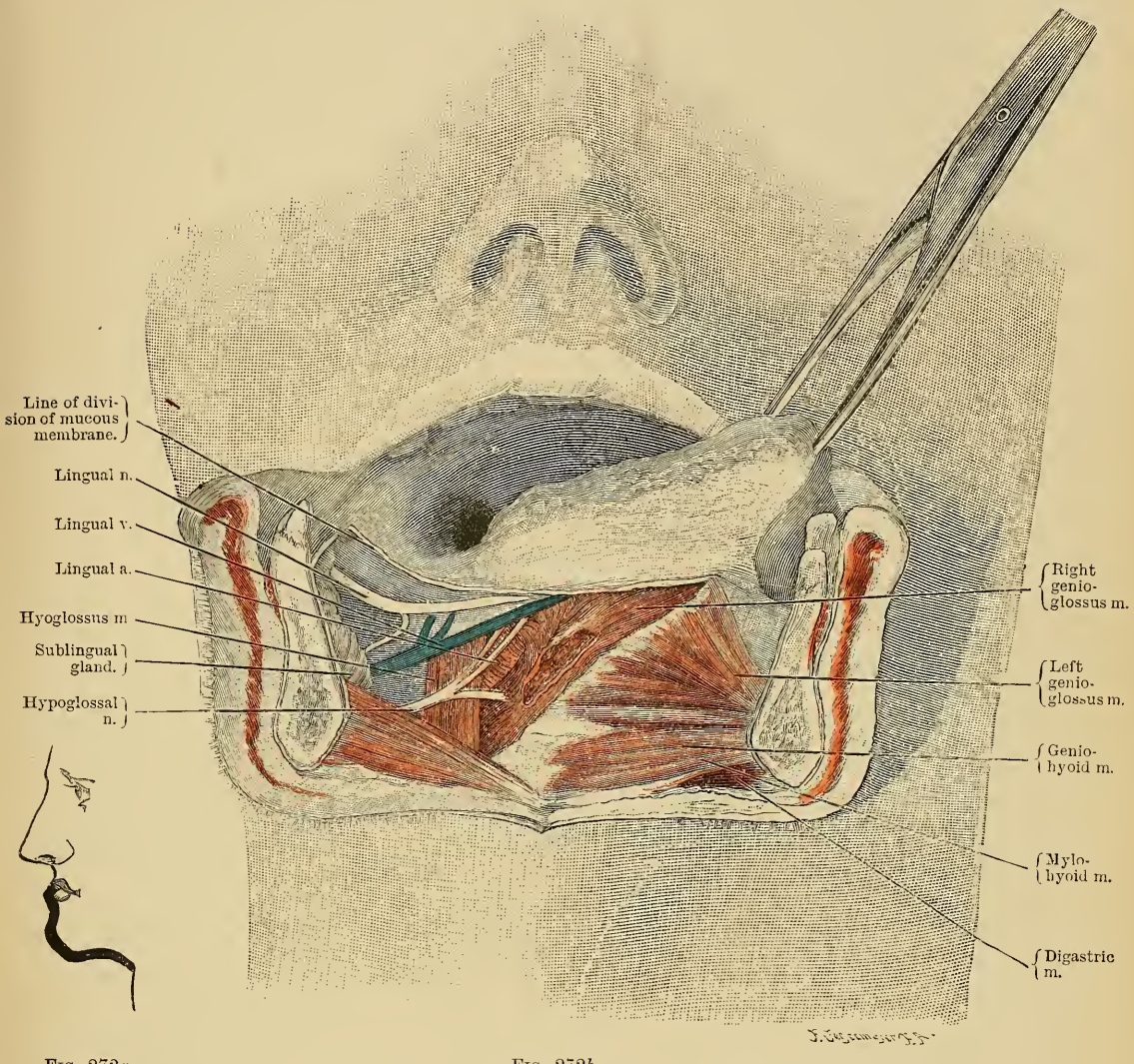

FIG. 272*a*. FIG. 272*b*.

FIG. 272*a* illustrates the incision by which the lower lip and chin are split in the middle line down to the hyoid bone.

FIG. 272*b*.—Our normal operation for advanced cancer of the tongue. The lower jaw has been split in the middle line, and the right genioglossus separated from it (as a rule we divide the muscle behind at a distance from the tumour). The mucous membrane has been divided along the side of the tongue as far back as the anterior pillar of the fauces, and the tongue (along with the tumour) detached from the jaw and forcibly pulled over to the left.

incisions immediately outside the limits of a new growth, is cauterised, a procedure which improves the prognosis by aiding in the complete removal of the disease. The

[1] All incisions should be made through healthy tissue, but as near the seat of the disease as possible to retain the greatest number of muscles and nerves.

tongue is then firmly dragged forward, and the mucous membrane far back is likewise divided with the cautery well away from the tumour if it has involved the palate and pharynx, while the stylo-glossus muscle, which is visible, and the glosso-pharyngeal nerve lying alongside it are both divided.

By division of the mucous membrane in front of the tonsil, the latter, even when invaded by the new growth, can be separated with a blunt instrument passed round its outer side, thus exposing the surface of the internal pterygoid muscle. As much of the soft palate as is affected is divided with the cautery, and the tensor and levator palati are cut through, the mucous membrane on the posterior wall of the pharynx being then divided down to the longus colli and anteriorly to the root of the tongue.

Lastly, the tongue is cut through, where it is healthy, with the thermo-cautery, and the nerves, muscles and vessels (previously ligatured) are divided on the under surface before they pass into the region of the new growth. The nerves and muscles are preserved as much as possible, in order not to interfere with the mechanism of swallowing more than is necessary.

Xeroform is rubbed into the cut surfaces, but only in a thin layer, so as not to produce toxic symptoms if swallowed. The two halves of the jaw are then approximated, and holes are bored with a drill a few millimetres from the edge of the sawn surfaces (if it has not been done before section of the jaw), the drill being pushed through the deeper soft parts in the manner Albert Kocher has described for making an exploratory puncture of the brain, without separating the periosteum, strong silver wire being pushed through, and the edges of the jaw firmly united. An opening is left a little above the hyoid bone at the posterior end of the incision, into which a strip of xeroform gauze is inserted. Bismuth paste is smeared over the line of suture. The patient is allowed to sit up next day, and may try to swallow a little tea or wine and water. Nourishment may be given through a stomach tube.

As mentioned before, this method of excising the tongue has the advantage that it can be employed whatever be the situation and extent of the disease, provided the jaw is not involved, and it can be performed with the patient in Trendelenburg's sloping position with complete anæsthesia and without a preliminary tracheotomy. It gives the best access and causes the minimum of injury.

26. Excision of the Tongue with simultaneous Resection of the Central portion of the Jaw. When the tumour has invaded the floor of the mouth and cannot be moved on the jaw, a portion of the bone corresponding to the extent of the adhesion must also be removed.

The following is a description of the method to be employed when the central portion of the jaw has been invaded from the floor of the mouth.

The lip is split in the middle line, the incision being carried down to the hyoid bone, and the skin and mucous membrane are separated on one side until a healthy portion of the jaw is reached, after which the bone is cleared of the soft parts and divided with a saw. By pulling the jaw forcibly downwards with a sharp hook, the floor of the mouth can now be examined in its whole thickness, and the limits of the new growth defined, before dividing the soft parts. Vessels and nerves can also be seen and secured before they are cut, after which the separation of the floor of the mouth is proceeded with.

The skin on the opposite side is next dissected back and the jaw divided through healthy bone in precisely the same manner. The floor of the mouth can now be divided laterally on this side, care being taken to keep wide of the disease. Finally the muscles in the middle line are divided and the dissection is carried from below into the tongue which is then cut across through healthy tissue without any resultant bleeding.

It has been our recent invariable practice to replace the portion of the jaw resected with a mould (consisting of a piece of a mandible), a method which renders swallowing possible and reduces the discomfort of the patient to a minimum.

27. Excision of the Tongue where there is Lateral Disease of the Jaw. If the cancerous growth has extended beyond the limits of the tongue and has invaded the floor of the mouth and jaw, then the nature of the interference will be so much influenced by the seat of the disease in the bone that the above normal procedure

must be departed from. If recurrence is to be prevented any adherent portion of jaw must always be freely removed. *Resection of the jaw* has been employed by many surgeons as a preliminary to the removal of extensive carcinoma of the tongue, and one would begin with this when the indications for resection are clearly present. When, however, this is not the case, we still maintain that in an extensive carcinoma of the tongue the method of extirpating the organ from its base as proposed by us is the preferable procedure.

Resection of the Tongue at its Root

This operation has in these circumstances the following advantages as compared with other operations (1) because it gives the best access, (2) because it permits of the simultaneous removal of the glands as well as all the tissue which intervenes between them and the primary seat of disease,[1] (3) because it admits of preliminary ligature of the lingual or external carotid arteries, and (4) because it allows at least the anterior attachments of the muscles of the floor of the mouth to be preserved. Von Givel has by comparisons established the advantage of this method.

According to the very exact records of our former assistant, Dr. Sachs, we have only lost one out of twelve cases; and out of five patients who remained free from recurrence seven years after operation three were operated upon by this method.

The incision begins below the mastoid process and extends along the anterior border of the sterno-mastoid, and then forwards along the crease between the floor of the mouth and the neck to the middle line, and, lastly, upwards to the lower border of the jaw. In cases where the extent of the carcinoma is limited, it need only correspond to the middle two-thirds of this incision, *i.e.* from the sterno-mastoid as far as the hyoid bone. After the subcutaneous veins have been ligatured, the flap thus formed is dissected up and fixed with a suture to the cheek. Next comes the removal of all enlarged glands under the upper end of the sterno-mastoid and beneath the angle and the body of the jaw. The anterior border of the sterno-mastoid is exposed as far down as the sheath of the large cervical vessels and the greater cornu of the hyoid bone. All the glands on the sheath of the large vessels (often extending far downwards) are excised, after the vessels proceeding to them have been ligatured.

If the carcinoma has involved the floor of the mouth, the pharynx, or the jaw, it is best to ligature at once the external carotid after ligaturing the facial vein at the anterior border of the sterno-mastoid. The anterior belly of the digastric is then exposed as far as the hyoid bone, the veins running underneath having been ligatured, after which the bunch of glands is freed below, and raised up until the entire length of the posterior belly of the digastric and the stylo-hyoid muscles are exposed in the posterior and lower part of the wound. The facial vein and the facial artery, which are put on the stretch when the submaxillary gland is turned upwards, are ligatured. The salivary and lymphatic glands are then reflected up over the border of the jaw and freed from their connections on the outer surface of the jaw, during which procedure the facial artery and vein must again be ligatured.

The lingual artery is easily exposed and ligatured by dividing the fibres of the hyo-glossus muscle a little above the posterior part of the greater cornu of the hyoid bone. The hypoglossal nerve and lingual vein, which lie upon the outer surface of the muscle, are to be preserved.

The outer surface of the mylo-hyoid muscle is now exposed, with its nerve lying on it. Above the mylo-hyoid muscle the mucous membrane is felt. After we have investigated the limits of the new growths the mucous membrane is incised from the mouth, cutting upon the finger. From the opening the mucous membrane is further divided beyond the tumour, artery forceps being applied to the more important bleeding vessels of the mucous membrane. Further hæmorrhage is readily arrested by dragging forward the soft parts by means of the finger introduced through the wound in the mouth.

[1] The glands lower down and those on the opposite side must be removed later on.

It is now an easy matter to define the anterior and posterior limits of the tumour as well as the extent to which the jaw is involved, and to remove the latter with the keyhole saw.

The tongue is detached from the hyoid bone and all infiltrated tissue removed, any hæmorrhage being readily and securely arrested. The tongue can be well drawn out through the floor of the mouth as soon as the mucous membrane has been divided

If, in order to facilitate the administration of the anæsthetic, a preliminary tracheotomy has been performed, the entrance to the larynx is at once plugged with sterilised gauze introduced from the pharynx. A morphia injection is here clearly indicated to assist the action of small doses of the chloroform, the morphia being administered a quarter to half an hour before the anæsthetic, $\frac{1}{5}$ grain for strong and $\frac{1}{6}$ for weak individuals.

The after treatment is to leave the wound open so that the entrance to the larynx may be plugged with sterilised moist (salt solution) gauze, which is to be frequently changed, a carbolic or sublimate gauze dressing being applied over the wound, and the patient fed with a tube each time the wound is dressed.

As long as swallowing is much interfered with the patient must remain in the sloped position with the head and neck dependent.

28. Excision of a Carcinoma of the Base of the Tongue. The root of the tongue and hyoid bone can be reached by dividing the jaw in the middle line, if at the same time the anterior pillars of the fauces are divided close to the tongue.

In cases of cancer of the tongue which are not accessible from the front, *i.e.* cancer of the root of the tongue, between the isthmus of the fauces and the hyoid bone, the most suitable and least injurious method to employ is subhyoid pharyngotomy, or even suprahyoid pharyngotomy. The patient being anæsthetised, and a low tracheotomy performed, the epiglottis is then exposed by the previously-described incision through skin and muscles, along the lower border of the hyoid bone. If the epiglottis is involved, the mucous membrane is divided along the upper border of the thyroid cartilage, the epiglottis is then hooked forward, and the mucous membrane on either side is divided.

The finger is now passed on to the base of the tongue, and the mucous membrane of the pharynx beyond the disease is drawn forward and divided. As soon as the pharynx is opened, the mucous membrane is anæsthetised by swabbing it with 1 per cent novocain and adrenalin (1 drop of adrenalin in 1 g. of the solution) to prevent reflex retching and coughing. It is advisable to plug the larynx if severe venous bleeding occurs, for then the dependent position is no longer required. If the disease has spread forwards into the tongue, and especially if the hyoid bone is involved, it must be split (Sallas and Esmarch). The healthy muscles on its upper surface are then divided after the vessels (especially the veins) have been ligatured, and the deep cancerous infiltration of the tongue is reached, and can be attacked from in front and behind. The lingual nerve, which is exposed on the lateral aspect of the tongue, must be divided if it is seen to enter the growth; if not, it must be freed, the vessels being similarly treated. The muscles and other tissues are then grasped with artery forceps and divided, so that the back part of the tongue can be pulled into the wound, and the organ divided transversely in front of the disease with the thermo-cautery. By this method we recently removed an extensive carcinoma which involved the whole of the base of the tongue, and had infiltrated the right wall of the pharynx and epiglottis. The bleeding was not severe, and the various structures could be well observed as they were divided.

The after-treatment consists in the free application of iodoform while the wound is kept open and packed, this being the only means of preventing aspiration-pneumonia.

When a carcinoma involves the whole breadth of the root of the tongue, there is a risk of resulting local necrosis of the remains of the tongue after excision, and decomposition and consequent sepsis may prove fatal. It is advisable, therefore, to extirpate the whole tongue, whenever its nerves and vessels have been injured laterally. In this case it is better not only to split the jaw in the middle line, but to divide the

hyoid bone into the thyrohyoid membrane, preserving the mucous membrane of the floor of the mouth as far as the condition of the growth will allow, and then, after slitting the tongue and holding the two halves apart, to decide how far the operation must extend in order to remove the disease completely.

This free median incision affords the best opportunity of dissecting towards the sides of the tongue where the vessels lie, with the least possible damage, and of carrying out thorough open-wound treatment.

29. Operation for Cleft Palate. A notable advance has been made in the treatment of cleft palate since the introduction by Wolf of the two-stage operation, which is more likely to succeed, especially in infants and in cases where the tissues are scanty. The muco-periosteal coverings of the hard palate are separated through two short incisions near the teeth, and the flaps are prepared for union by dividing the muscles laterally in the soft palate. Four to five days later the edges of the flap are united. The separated flaps readily adhere at first, and become well-vascularised and somewhat thickened, while there is the further advantage that the bleeding at the second operation is very insignificant, so that the stitches can be inserted securely and are less likely to cut out, and the child is subjected to less pain as the result of the operation.

The procedure is as follows :—Chloroform is administered, the head being dependent (ether anæsthesia is not satisfactory as it is more frequently interrupted). An incision is carried from behind forwards down to the bone near the roots of the teeth, the bleeding being controlled by pressure with the finger, after which the mucous membrane and periosteum are separated with an angled elevator. This should be done very freely, so that one can easily raise the edges of the cleft with a sharp hook and approximate them in their whole length. Division of the tensor palati on both sides close to the hamular process greatly facilitates this procedure. Gely's half-wire suture can be used with advantage (Bunge). Any smart bleeding is controlled by pressure with the finger.

30. Tonsillotomy. In tonsillotomy an injury to the internal carotid artery is, according to Zuckerkandl, not easily produced, as the artery is separated from the pharyngeal wall by the stylo-glossus and stylo-pharyngeus muscles. The tonsillar artery, on the other hand, which usually springs from the ascending palatine, may bleed severely, because it is adherent to the lower wall of the capsule of the tonsil and cannot retract. In such a case it may be necessary to ligature the external carotid.

The operation may be performed under local anæsthesia, the novocain and adrenalin solution being injected into the base of the tonsil. In simple hypertrophy of the tonsil it is not necessary to remove the whole tonsil, as only the projecting portion need be excised. In the case of malignant disease, however, it is quite different. The simplest method is to use a tonsillotome. When very severe bleeding from the tonsil occurs, Nicoladoni has suggested (Burkhard) going in above the digastric and stylo-hyoid through the posterior part of our normal incision in the neck, the operator exposing the bleeding vessel and after division of the stylo-glossus excising the tonsil from without, with subsequent closure of the wound.

31. Excision of Tumours of the Tonsils. We have lately had occasion to operate on two cases of carcinoma of the tonsil, both of them making an uneventful recovery, so that we regard the operative procedure employed as having largely influenced the result.

It appears to us important that the secondary glandular growth should not be removed at the same time. One of the patients had a hard swelling, irregular in outline, scarcely movable, and as large as two fists, situated on the left side of the neck. This was completely excised right down to the vertebral column by an angular incision with excision of the sterno-mastoid, the common jugular vein along with all the nerves, with the exception of the vagus, the phrenic, and the brachial plexus, the carotid being preserved.

The wound healed by first intention, and fourteen days later the primary sarcoma of the tonsil was excised from the mouth by splitting the cheek transversely.

If the tongue be dragged out by means of a suture passed through it, the tumour can be cut out with the thermo-cautery without any excessive bleeding, cocaine being injected into the tissues round the growth.

In the other case the access obtained by dividing the cheek transversely was not sufficient as the tumour had spread so far. We (Dec. 1899) divided the jaw in the middle line, split the muscles mesially and the mucous membrane of the floor of the mouth close to the tongue, in order to be able to forcibly separate the two halves of the lower jaw. The tongue was then dragged outwards and downwards between them. In this way excellent access to the pharynx is got, and we can warmly recommend this preliminary method of operation to expose the pharynx and structures in the region of the isthmus.

If the two halves of the lower jaw are subsequently accurately united, the patient can immediately open and close the mouth, and runs no risk of injury to the mechanism of deglutition, pneumonia by this means being prevented.

In excising the tonsil it is important first of all to divide the mucous membrane round the new growth, that is, of the soft palate, the roof of the mouth, and the base of the tongue. This can be done with little hæmorrhage by using the thermo-cautery. It will be seen then how comparatively easily, after separating the mucous membrane, one can pass the finger beneath the tumour and detach it completely from the muscles. Even in the case of a sarcoma (the size of a small apple), for which an external incision had been recommended by another surgeon, we were able to remove it successfully from the mouth.

When the tumour has been separated in this way as far as where it joins the mucous membrane of the posterior wall of the pharynx, one is, as a rule, able to tear through the thin mucous membrane with the finger, and then to pull forward the tumour sufficiently to obtain a pedicle containing the vessels, which are ligatured prior to division.

B. SURGERY OF THE NECK

(a) Normal Incisions in the Cervical Region

32. Normal Incision for the Upper Lateral Triangle of the Neck. According to our principle of arranging skin incisions along the natural cleavage lines of the skin, we find that the best incision for exposing the organs in the fossa below and behind the jaw is that which we have already given for resection of the lower jaw. It runs from the anterior part of the apex of the mastoid process to the middle of the hyoid bone, passing a finger's-breadth below and behind the angle of the jaw, where it crosses the anterior border of the sterno-mastoid muscle. This incision possesses the great advantage of falling along the boundary line, at which the muscles, running from above downwards, viz. the digastric, stylo-hyoid, genio-hyoid, mylo-hyoid, and hyo-glossus, and those running from below upwards, viz. sterno-hyoid, thyro-hyoid, and omo-hyoid, meet or terminate. The muscles which cross this boundary line are either unimportant, like the platysma, or lie to one side or posteriorly, like the sterno-mastoid and the muscles of the vertebral column.

Moreover, by this incision it is possible to avoid the important nerves, inasmuch as the main trunks lie above or posteriorly and can be drawn aside, whilst their branches ramify upwards and downwards from the line of incision. Thus the vagus, the sympathetic, the spinal accessory, and the descendens noni lie posteriorly along with the sterno-mastoid muscle, while the lowest branch of the facial, the hypoglossal, the lingual, and the glosso-pharyngeal lie above. The superior laryngeal branch of the vagus is drawn downwards.

In the third place, the incision gives access to the bifurcation of the common carotid artery and to the origin of the branches of the external carotid. The common carotid bifurcates at the level of the upper border of the thyroid cartilage, and above

it follow, in close order, the origins of the branches of the external carotid. At the same level the facial and anterior temporo-maxillary veins join to form the common facial vein, which opens into the internal jugular. With this normal incision, therefore, we can expose and ligature not only the trunks of the great vessels of the neck, but also the greater number of their branches.

We have, therefore, designated this incision *the normal incision for the superior triangle of the neck*, and all other incisions for this triangle, whether longer or shorter, are made along the same line.

Quervain has recently discussed the incisions which we regard as normal incisions

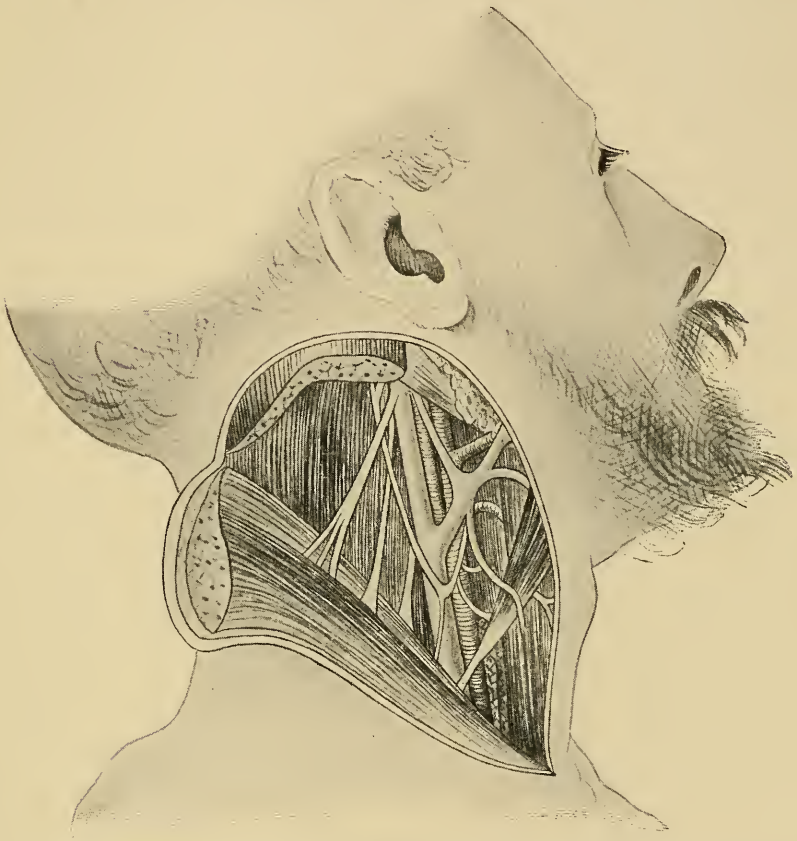

FIG. 273.—Küttner's muscle flap for exposure of the deep structures in the upper part of the anterior triangle.

for the neck, and suggested that they could be still further improved by carrying the incision through the muscles so as to form a flap, which would thoroughly expose the deep structures (*e.g.* in excising large or multiple tumours). We have satisfied ourselves of the advantage which Quervain ascribes to this additional procedure, and we reproduce one of his illustrations, which represents the admirable incision recommended by Küttner for exposing not only the anterior triangle but all the structures lying underneath the sterno-mastoid. The sterno-mastoid is divided high up (above the point of entrance of the spinal accessory) by the same incision as the skin, and is turned down with the skin flap. It is evident that a much better view is obtained by this musculo-cutaneous flap.

The muscle is subsequently united with sutures, and as its nerve has been preserved

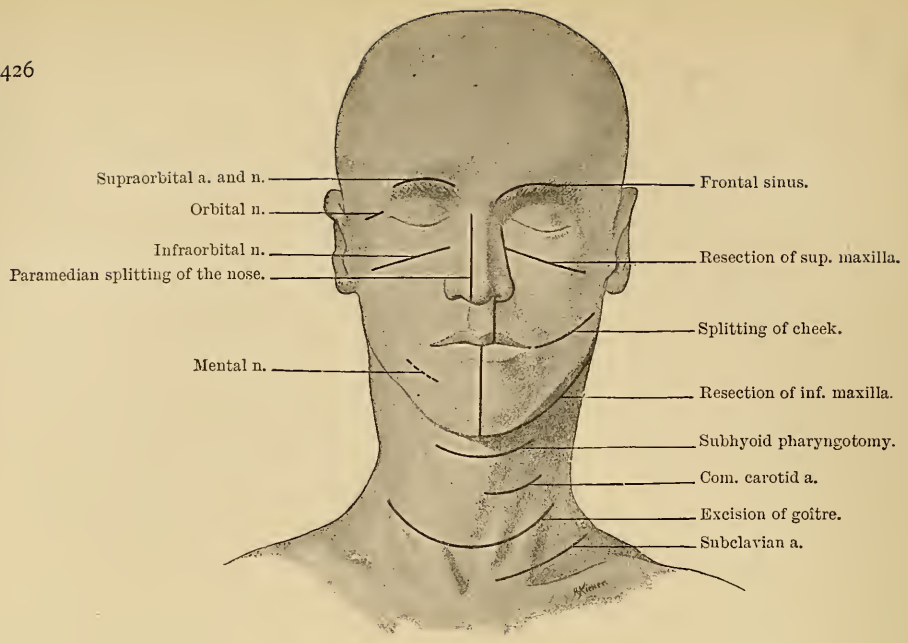

FIG. 274.

FIG. 275.—Quervain's muscle flap for exposing the deep structures of the neck.

its action is not interfered with. Division of the muscle is, however, not often necessary, as the sterno-mastoid can be sufficiently retracted to afford a good view of the vessels and structures surrounding them.

33. Normal Incision for the Inferior Lateral Triangle of the Neck (Figs. 274 and 275). This triangle is bounded by the clavicle, the sterno-mastoid, and the trapezius. The surgery of this region is simpler than that of the upper lateral triangle. It is here that the great vessels and nerves pass to the arm, and that many of the branches of the subclavian artery and vein are to be found. The floor of the triangle is formed by the first rib and the first intercostal space, together with the lateral muscles of the neck, especially the scaleni.

The *normal incision* for this region corresponds to the line of cleavage of the skin, and is almost transverse, passing from the origin of the sterno-mastoid at the clavicle outwards and slightly upwards to the edge of the trapezius. This incision is employed in ligaturing the subclavian artery, and is described with that operation (see p. 105).

Quervain, as we have already stated, turns down a flap containing the sterno-mastoid muscle in order to thoroughly expose the deep structures of the neck (Fig. 275).

We have often utilised this angled incision for the removal of a bunch of enlarged glands in the neck, but we only carry it through the skin. De Quervain's method naturally provides an easier access, but one must be careful when dividing the muscle below not to injure the transverse vein situated behind it, nor the external jugular vein at its posterior border.

(b) Surgery of the Larynx

34. Median Laryngotomy and Circumscribed Laryngectomy. Opening into the larynx is definitely indicated in intralaryngeal malignant growths, while it may also be necessary in comparatively simple tumours, as laryngeal papillomata, and in ulcers and infective diseases, as laryngeal tuberculosis. To expose the interior of the larynx by a mesial incision is a comparatively simple operation. The body and neck occupying a sloping position, the skin and fascia are divided in the middle line from the hyoid bone down to the upper part of the trachea. The following vessels are divided:—The hyoid branch of the lingual artery on the hyoid bone; the crico-thyroid artery; a transverse branch of the superior thyroid to the pyramidal process of the thyroid gland; numerous veins, some superficial (transverse connections between the two anterior jugulars), others situated under the fascia. All these vessels are carefully ligatured to prevent any after-bleeding. After dividing the skin and fascia, the muscles which ascend from the sternum to the larynx and hyoid bone are drawn aside, and the uppermost rings of the trachea exposed. The isthmus of the thyroid gland must be separated with a blunt dissector from the trachea and firmly ligatured on both sides. The upper and lower communicating veins running along its upper and lower border must be isolated and ligatured.

When severe dyspnœa is present, tracheotomy is first performed to ensure respiration, the edges of the wound are held apart, and the larynx is divided with scissors upwards exactly in the middle line. Before division of the thyroid cartilage a grooved director is introduced so as to be able to divide it exactly in the middle line between the anterior ends of the vocal cords. If the incision is carried carefully and slowly upwards, and the edges retracted with hooks, a satisfactory view is obtained, and one can avoid cutting into a possible new growth. The incision may be continued upwards in the middle line if necessary, into or completely through the epiglottis, or, if it be infiltrated by the new growth, past its sides. The division must always be carried far enough beyond the growth to allow of its thorough examination.

After the trachea has been divided a solution of novocain and adrenalin should be repeatedly painted on the surface of the mucous membrane. For this purpose we formerly used a solution composed of 5 per cent cocaine, 5 per cent antipyrin, and 1 per cent carbolic acid (introduced by Professor Stein of Moscow). According to

Valentin, it is better to inject the novocain solution at the point of entrance of the superior laryngeal nerve, the needle being inserted between the great cornu of the hyoid bone and the superior cornu of the thyroid cartilage at a distance of 3 cm. from the middle line (Frey).[1]

If the tumour is distinctly visible inside the larynx it is best to cut round it with the galvano-cautery or with a fine-bladed thermo-cautery. If it is firmly adherent at its base, the corresponding part of the wall of the larynx should be excised, the muscles being separated from its outer aspect with a blunt instrument, provided they are healthy and not infiltrated with the new growth. The cartilage is divided with strong scissors. There are a few vessels which bleed, but they can be easily secured.

It has lately been our rule to perform laryngotomy without using a general anæsthetic, and we consider a local injection of novocain (1 per cent solution for the skin incision) is preferable. If severe dyspnœa is present the novocain solution should also be injected at the point of entrance of the superior laryngeal nerve. If the operation is performed with the lower part of the body elevated, the Trendelenburg tampon, which we formerly recommended, can be dispensed with, and a more favourable view obtained, as the canula is always in the way, or a long thick rubber tube can be introduced, so as to avoid being inconvenienced by the coughing.

In regard to the after-treatment, the patient should lie with the head at a slightly lower level so as to prevent the secretions from entering the trachea, but if the sensibility of the larynx has not been destroyed, and the act of reflex coughing is unimpaired, *i.e.* if the patient can get rid of mucus by coughing, he should be allowed to sit up. Iodoform powder should always be rubbed into the raw surfaces and the wound packed, while the larynx must be plugged with iodoform gauze (wrung out of lotion) as far as the tracheotomy wound, the gauze being retained for the first few days.

As soon as the swelling in the region of the aditus laryngis is shown by the laryngoscope to have decreased, the packing may be removed, secondary sutures inserted and the tube dispensed with.

35. Partial Pharyngo-Laryngotomy. When the disease has involved not more than half of the larynx, but has invaded the aditus, splitting the larynx in the middle line no longer provides sufficient room to examine and determine the boundaries of the new growth. In these cases it must be combined with subhyoid pharyngotomy, or even better with median division of the hyoid and adjacent part of the base of the tongue.

36. Median Subhyoid Laryngo-Pharyngotomy (Fig. 276). Median subhyoid pharyngotomy is performed as follows :—An incision is made in the middle line from the hyoid bone downwards through skin and fascia over the thyroid and cricoid cartilages as far as the isthmus of the thyroid gland. The fascia (forming the suspensory ligament of the isthmus) is detached from the lower border of the cricoid, and the isthmus, along with the superior transverse communicating vein, is pushed downwards with a blunt dissector. In cases where the isthmus reaches high up, it is to be freed in the middle line at its upper and lower border, and a blunt dissector passed behind it, so that it may be divided between two strong catgut ligatures. The trachea is then opened and the patient put in the hanging position, so that blood may be prevented from running down into the trachea. The Trendelenburg position is not advisable previous to opening the trachea, as there is often marked dyspnœa due to venous congestion, and asphyxia may occur unless the patient's head be raised.

After the trachea has been opened, a thick rubber tube is inserted if necessary. The tube should be long enough to allow of its being turned on one side so as to be out of the way of further procedures. As a rule we do not use any tube at all. The incision is carried from the wound in the trachea upwards through the larynx exactly in the middle line. The surgeon must be quite certain that he reaches well above the limits of the diseased mucous membrane so that the thermo-cautery may

[1] *Arch. f. Laryngol.* Bd. 18.

be applied all round beyond the edges of the tumour. All points at which the new growth is cut into must be burnt with the thermo-cautery.

A transverse incision is now made through skin and fascia along the hyoid bone, the upper ends of the anterior jugular veins being ligatured close to the bone. The incision may be prolonged outwards along the hyoid bone through the fibres of the sterno-mastoid, the omo-hyoid, and the subjacent thyro-hyoid. The hyoid bone is

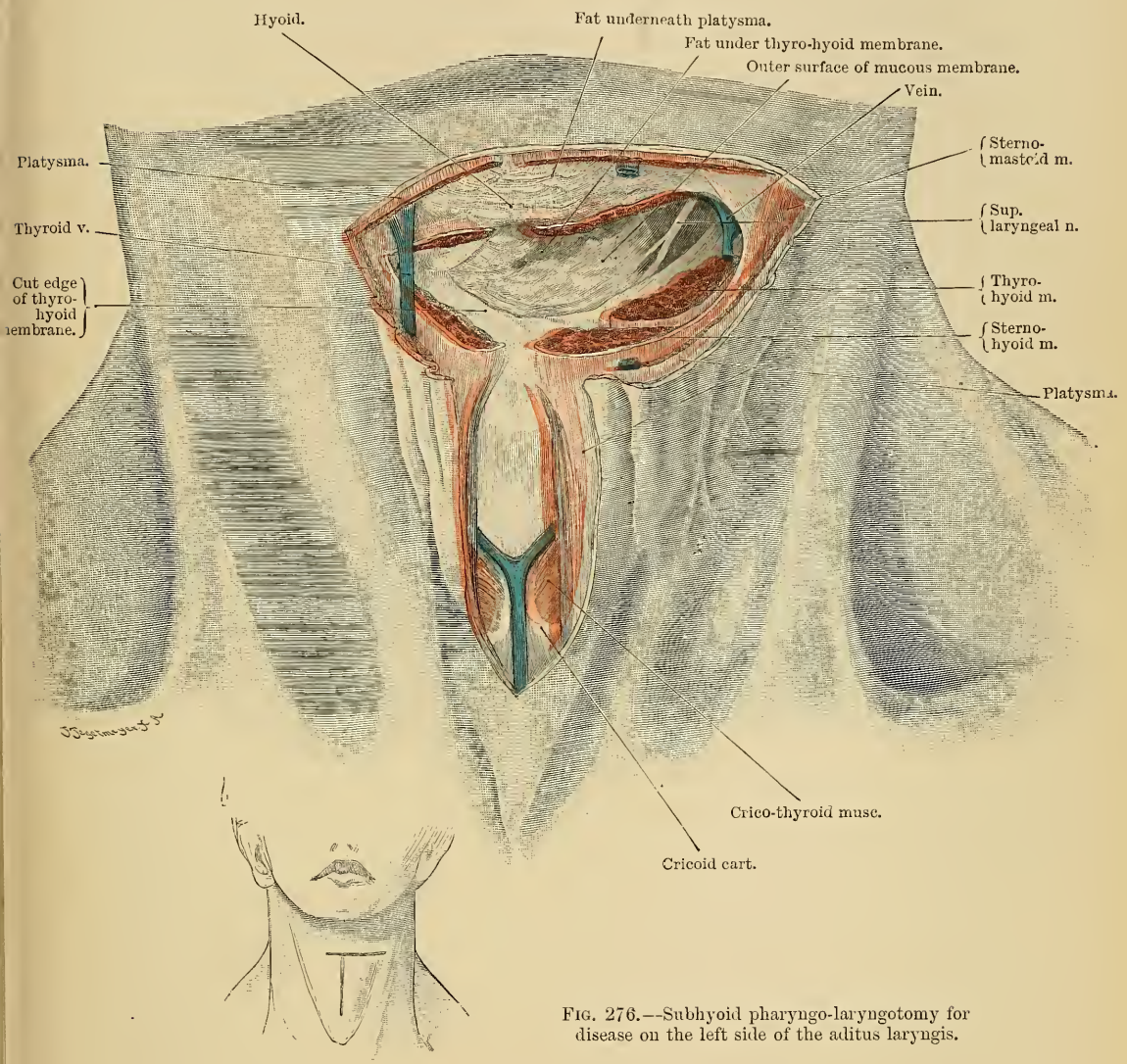

FIG. 276.—Subhyoid pharyngo-laryngotomy for disease on the left side of the aditus laryngis.

pulled upwards with a strong sharp hook. The strong central portion of the thyro-hyoid membrane, which is attached to the posterior border of the hyoid bone, is separated from the hyoid, and the projecting mucous membrane divided where it is attached to the anterior surface of the epiglottis. The tip of the epiglottis can now be seized and drawn forwards with a sharp hook. One must be careful not to divide the mucous membrane too high up behind the hyoid, as the bleeding will then be more difficult to control.

If the epiglottis is found to be healthy it is split mesially ; if diseased, the mucous membrane round it is divided and the posterior horns of the thyroid cartilage are cut through with bone forceps. Small double sharp hooks are now introduced between the edges of the wound in the thyroid cartilage, and its alæ drawn apart so as to give a clear view of the extent of the disease. The mucous membrane is then divided with the thermo-cautery and the tumour excised.

If the new growth has spread upwards on to the pharynx, the division of the

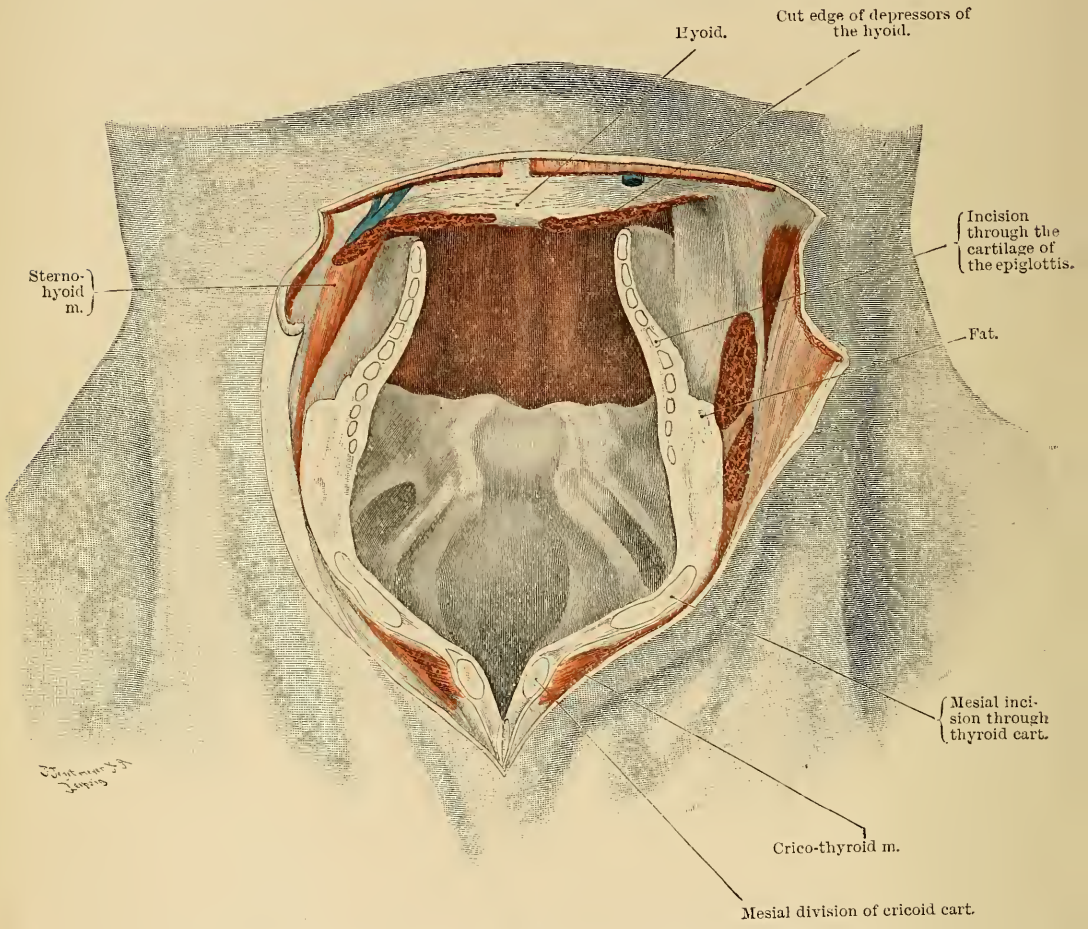

FIG. 277.—Subhyoid laryngo-pharyngotomy. The larynx is opened up, the epiglottis is split, and the edges are widely separated.

mucous membrane is continued along the arytenoid cartilage and the posterior wall of the cricoid cartilage on to the pharyngeal wall.

The soft parts have now to be separated from the outer surface of the larynx. The muscles which can be separated may be preserved, but those which are in firm contact with the cartilage must be excised over an area corresponding to that occupied by the cancer internally, the cartilage and muscles being divided with strong scissors in the groove made by the thermo-cautery.

If there is any healthy mucous membrane covering the arytenoid cartilages and posterior surface of the cricoid, it is to be freed and united to the mucous membrane of the epiglottis in front.

37. Total Laryngectomy (Operation of Watson and Czerny).[1] It generally happens that the extent of a carcinoma in the interior of the larynx, or even of the pharynx as well, is only discovered in the course of the operation. As a rule, therefore, the median incision recommended by Billroth is unavoidable for exploratory laryngotomy (*vide* Salzer, *Arch. f. klin. Chir.* Bd. 39).

In this connection we would specially observe that when the superior aperture of the larynx is free, and it is consequently unnecessary to perform subhyoid pharyngotomy to begin with, the access afforded by the longitudinal incision can be increased by splitting the hyoid bone in the middle line. We drew attention to this point in earlier editions, although it has recently been referred to as a new procedure. Keen operates on the same lines.

If it is obvious from the first that total excision alone will suffice, the operation can be simplified by avoiding splitting the larynx. For this purpose a transverse curved incision extending from one sterno-mastoid to the other across the larynx (our "collar incision," only at a higher level) will be found very satisfactory. After dissecting up the skin, fascia, and platysma as far as the hyoid bone above and the upper rings of the trachea below, the sterno-thyroid muscles are held apart with hooks, and tracheotomy is performed by cutting the trachea across below the cricoid cartilage. The cricoid cartilage is then firmly pulled up with a sharp hook, and the mucous membrane of the pharynx separated posteriorly where it is loosely attached, while the attachments of the pharyngeal constrictor muscles to the larynx are divided, and the cavity of the pharynx behind the arytenoid cartilages is entered. The larynx can now be raised up with the finger, and all the soft parts and muscles on one side which cannot be lifted off it but are only loosely connected with it, are grasped with forceps and divided. The larynx can then be partially dislocated over to the other side and a similar separation performed here.

The excision can now be completed above the upper and lateral limits of the disease by turning the larynx upwards and cutting through the superior cornua of the thyroid cartilage and the thyro-hyoid membrane in front. The trachea is stitched into a small separate opening or into the lower end of the wound so that any discharge from above does not enter it. When possible, the pharynx should be closed either by direct suture or by a plastic operation, or it may be simply packed.

The condition of the glands is an important factor in regard to the success of the operation. In none of our patients who were traced some years afterwards by Rutsch, and who exhibited no enlarged glands in the neck at the time of operation, was there cachexia, the lungs, moreover, being healthy. If there is malignant disease of the glands a radical cure cannot be expected, and total excision should not be attempted, as the epiglottis and aryepiglottidean folds are in that event invariably involved, a condition which, according to de Santi, leads to early and rapid invasion of the glands. In these circumstances simple tracheotomy serves the purpose equally well. The fact must not be overlooked that the results even of extensive excisions have improved, Garré estimating the mortality in these cases at 20 per cent, and the permanent cures at 10 per cent (1898), while our statistics show very conclusively the great advantages of early operation.

Up to the present we have performed extirpation of the larynx for cancer on 29 occasions and for sarcoma once (*vide* works of Dr. Lanz, Dr. Rutsch, and Dr. Kasansky, 1890, 1899, and 1904). In the case of the sarcoma a radical cure was obtained. On tracing the other patients some years later, seven were found to be cured (24·1 per cent), so that if we include the sarcoma case the percentage of radical cures amounts to 26·6 per cent. Of 6 cases of total excision of the larynx only one died of pneumonia, and he was free from recurrence for two years. Out of 9 cases of unilateral excision two died of other diseases, one and one and a quarter years later; two are in good health after six and eight years respectively, while of 10 circumscribed laryngectomies two are healthy after six and six and a quarter years. Further, of

[1] *Vide Wiener med. Wochenschr.*, 1870. According to Réal, Albers had already made experiments in 1829, and Watson performed the first successful total resection in 1868, while Billroth performed the second in 1872 on the basis of Czerny's experiments.

4 cases of subhyoid pharyngotomy two remain cured after periods of fourteen months and ten years.

When the operation was undertaken at an early stage of the disease, *i.e.* when the cancer was still circumscribed, and there were no enlarged glands, 50 per cent of permanent cures was obtained, a result which is very gratifying, and which shows that early diagnosis alone is required in order to make cancer in this region, as well as in other parts of the body a disease curable by surgical measures.

These favourable results obtained by circumscribed internal laryngectomy (simple median thyrotomy) are also upheld by the statistics of Semon, Sendziak, and Cuneo, while further, a sharp line of distinction must be drawn between the so-called internal carcinoma of the larynx (when the tumour is limited to the true and false vocal cords) and the so-called external cancer, in which the tumour originates in the epiglottis and aryepiglottidean folds (*vide* de Santi).[1] That a cure in laryngeal cancer, as in cancer of the tongue and other organs, depends on early operation and not on the actual method of removal employed, may be seen from earlier publications, such as Salzer's report on 29 laryngeal operations for cancer performed by Billroth up to 1889. Of these 29 cases, in which various operative methods were employed, only four remained free from recurrence, and of these only two for more than three years. *Vide* also Kraus' statistics.[2]

After-Treatment of, and Plastic Operations to follow, Extensive Resections of the Larynx and Total Laryngectomy

When the trachea has been divided transversely, Gluck's[3] procedure is at the present time the one most commonly followed, *i.e.* the trachea is stitched into the lower angle of the wound or brought out through a special opening. As a rule, a tracheotomy tube need not be worn. Gluck's procedure affords the best guarantee against aspiration-pneumonia.

Gluck's method of dealing with the pharynx is also generally accepted. It consists in stitching the anterior wall of the pharynx to the soft parts below the hyoid bone, or if this cannot be effected, in closing the pharynx by means of a plastic operation, which, if not undertaken at once, may be successfully performed at a later date, as has been shown in a series of cases.[4]

The defect is closed by dissecting up a flap of skin, which is most satisfactorily done, according to Witzel, by Gersuny's method. The epidermis is directed towards the pharynx, while the raw surface, left by the removal of the flap, is either covered in by another plastic operation, or by grafting.

Mangoldt has devised an ingenious method by which portions of the thyroid cartilage may be replaced. He removes a wedge-shaped portion from the eighth costal cartilage 5 cm. long and $\frac{1}{2}$ cm. thick, which he transplants under the skin of the neck, the perichondrium being directed outwards.

After an interval of five months he covers the deep surface of the grafted cartilage with a flap of skin, and three weeks later cuts out the skin containing the cartilage and inserts it between the lateral plates of the thyroid cartilage, employing intubation of the larynx for some time subsequently. An easier method of restoring the cartilages of the trachea and larynx, and one which we have employed with success, is to turn up a long narrow flap containing skin, periosteum, and bone from the sternum or clavicle.

38. Tracheotomy. (*a*) *High Tracheotomy* (*Crico-tracheotomy*) Fig. 278. In the great majority of cases where we are compelled to perform this operation very rapidly, *crico-tracheotomy* is the safest, and is attended with least hæmorrhage.

The uppermost tracheal rings are often covered by a well-developed thyroid

[1] De Santi, *Lancet*, June 1904.
[2] Kraus, *Policlinico*, 1890.
[3] Cf. Depage, *Annales de la Soc. belg. de Chir.*, 1897, and Keen, *Annals of Surgery*, July 1899.
[4] Cf. Gluck, *Monatschr. f. Ohrenheilk.*, April 1904.

isthmus, at the upper and lower edges of which are the large transverse communicating branches between the thyroid veins. They receive branches which descend from the pyramidal process of the thyroid, when this is present, while ascending to the process are vessels from the crico-thyroid branches of the superior thyroid artery, so that arterial branches may also cross the middle line at the upper border of the isthmus. At the posterior surface of the isthmus the inferior laryngeal branch of the inferior thyroid artery is seen passing upwards. Below the isthmus are the large and constant inferior thyroid veins, which descend vertically one on either side of the mesial plane, and along with them the occasional thyroidea ima artery. All those vessels may be avoided if crico-tracheotomy be performed. In dealing with

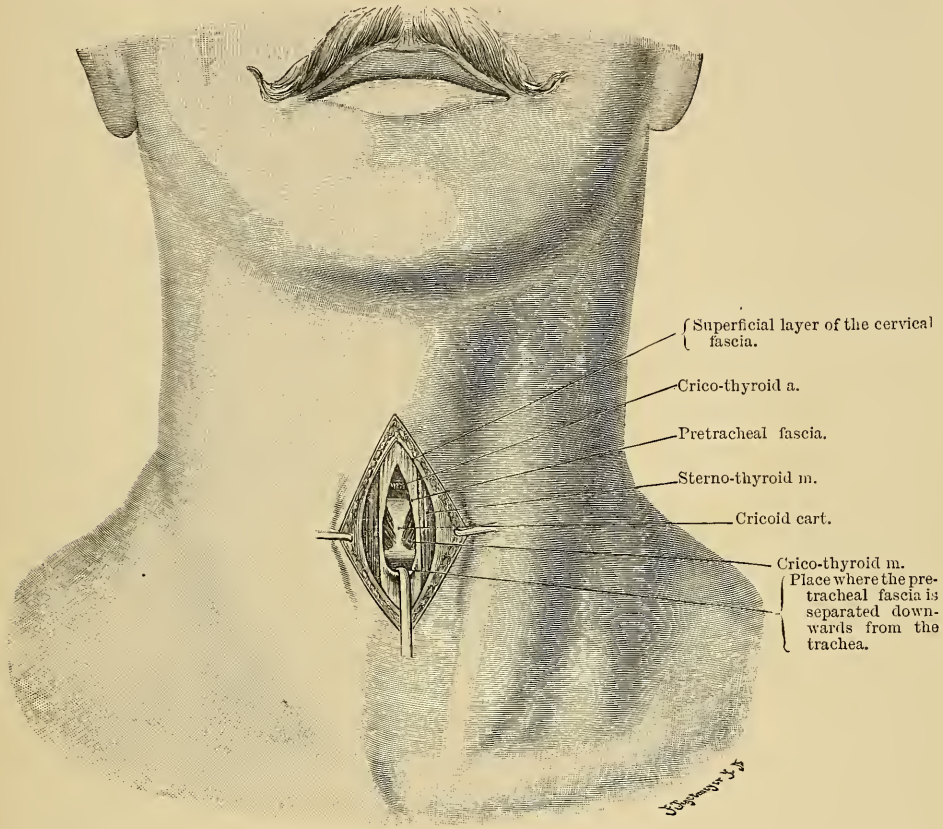

FIG. 278.—High tracheotomy.

children, especially when aggravated dyspnœa is present (in diphtheria, for example), it is advantageous to begin the incision directly over the thyroid cartilage. After dividing the skin and fascia, the adjacent edges of the sterno-hyoid muscles are exposed and drawn apart with blunt hooks. Bleeding veins are seized with artery forceps. The lower border of the cricoid cartilage, which may almost invariably be distinguished readily, is now felt for, and the fascia over it is grasped with forceps, while a small incision is made into it in the manner recommended by Bose. In young children, and when there are marked dyspnœal ascent and descent of the larynx, it is an advantage to place a small sharp hook in the exposed lower edge of the cricoid to fix it, and then to thoroughly separate the thyroid isthmus, along with the fascia and veins downwards from the front of the trachea, with a blunt dissector (Kropponde),

and to keep them held downwards with a retractor. The trachea is now rapidly penetrated with a sharp-pointed knife immediately above the retractor, and the trachea and cricoid are divided in an upward direction. The edges of the tracheal wound are at once seized with fine hooks and drawn asunder.

Unless the trachea is stabbed with a sharp-pointed knife there is a risk of its mucous membrane becoming detached.

(*b*) *Low Tracheotomy* (*below the thyroid isthmus*). If sufficient room is not got by crico-tracheotomy, or if it is desired to place the tracheal wound farther from the larynx, an incision must be carried through the skin and fascia in the middle line between the sternal muscles below the isthmus. The fascia is divided and forcibly retracted upwards with a sharp hook, along with the muscles. The inferior thyroid veins remain uninjured as they descend vertically one on either side of the mesial plane. After dividing the pretracheal fascia the trachea itself is reached: the transverse veins of the thyroid isthmus are pulled upwards with blunt hooks, while the small communicating veins at the suprasternal notch are hooked downwards. The trachea is thus exposed with a blunt instrument without injuring any vessels; in adults it is often as deep as 6 cm. (2½ in.) or more. If necessary, an aneurysm needle may be introduced between the trachea and the thyroid isthmus (previously separated from the trachea by a blunt dissector from above and below), in order that the isthmus may be divided in the middle line between two firmly tied ligatures. This is to be preferred when the trachea is to be fully exposed. It should be borne in mind that the tube must be longer than that used in high tracheotomy in case it may slip out of the trachea and come to lie behind the sternum, thereby causing serious dyspnœa.

In tracheotomy performed preliminary to pharyngotomy, laryngotomy, and laryngectomy, the low operation is preferable, as it leaves a clear field for the second operation. If there is much dyspnœa, these preliminary tracheotomies should be performed several days before the chief operation. Inferior tracheotomy, however, is always a more difficult operation to perform when there is a goitre or an enlarged isthmus involved, because the trachea is then much deeper, and there is no palpable guide to it to take the place of the cricoid cartilage.

In a number of cases serious hæmorrhage has been reported after tracheotomy. Taute has published three cases from v. Bruns' clinic, and Klauber one from Wölfler's clinic, the latter being performed for an aneurysm of the aorta. We have also experienced a case in which bleeding occurred from erosion of the innominate artery. There are now 87 cases reported in which erosion occurred, the innominate artery being involved in 56. Unfortunately, one cannot ascertain from the reports the number of these cases in which low tracheotomy was performed. There is no doubt that the danger of this fatal complication is incomparably greater in low tracheotomy, *i.e.* from pressure of the tube.

(c) Surgery of the Pharynx and Œsophagus

39. Subhyoid Pharyngotomy (Langenbeck's Operation). Subhyoid pharyngotomy, introduced by Malgaigne and Langenbeck, deserves special attention. By utilising all the advantages of this procedure the operation becomes much more frequently indicated than former authors supposed. It has the advantage of giving excellent access with little injury to the surrounding structures. Not only is the operation indicated for the removal of all growths situated at the entrance to the larynx, *e.g.* growths involving the epiglottis, aryteno-epiglottidean folds, arytenoid cartilages, mucous membrane at the level of the hyoid bone and of the sinus pyriformis, but equally for growths situated at the root of the tongue and on the lateral and posterior walls of the pharynx as far down as the œsophagus. In these conditions it is the operation *par excellence*, as it allows of an exact dissection and free removal with the least possible disturbance of function.

We have found preliminary tracheotomy and packing unnecessary when there is no

dyspnœa. Blood can be prevented entering the larynx by having the patient in the correct oblique position. Honsell too has lately deprecated preliminary tracheotomy. A general anæsthetic can be dispensed with in simple cases, and instead a .1 per cent solution of cocain can be injected for the skin incision, and 5 to 10 per cent solution can be repeatedly painted on the mucous membrane.

The incision, 4 inches long, is made along the hyoid bone from the greater horn on one side to that on the other, dividing the skin and muscular fibres of the platysma. The hyoid bone is then exposed and the anastomosis of veins crossing it is ligatured. The hyoid artery and vein lie on the bone and are retracted to the upper side of the wound. The muscles inserted into the lower border of the hyoid bone, viz. the sterno-hyoids, omo-hyoids, and the thyro-hyoids, are divided at their insertions. When the disease is unilateral the muscles on one side can be retained.

The thyro-hyoid membrane is now exposed. The central part appears as a broad, tense ligament, but the lateral parts are thinner. The central portion, which encloses fat and often a bursa, is divided transversely along the bone. The mucous membrane is similarly divided, giving rise to some spouting from small vessels. We do not consider it advisable to divide it at a distance from the hyoid, on account of the superior laryngeal nerve, which enters the larynx by piercing the lateral part of the thyro-hyoid membrane. If the twigs of the nerve are cut, the larynx becomes insensitive, and allows of the entrance of food, mucus, and wound secretions into the larynx, and as these foreign bodies cannot be reflexly coughed up, aspiration-pneumonia is developed.

The epiglottis can now be seized with a hook at its upper border and drawn forwards. This gives an excellent view of the entrance of the larynx, especially the neighbourhood of the arytenoid cartilages, which is so often the seat of disease (tuberculosis and cancer), and also of the lowest part of the pharynx and the root of the tongue. If the epiglottis must be removed, it is seized with a hook at its lowest point (which can be easily felt above the dip in the thyroid cartilage) and dragged outwards. After the mucous membrane has been divided it can be easily pulled out and cut away. As in laryngotomy, the reflex irritation of the mucous membrane must be quieted by frequent applications of a 5 per cent novocain solution, or direct anæsthesia of the superior laryngeal nerve, so as to enable the operation to be continued in comfort.

The new growth should be thoroughly removed with the thermo-cautery, the parts being clearly exposed to view. The cautery arrests all oozing and gives a better chance of a radical cure. As regards after-treatment, it is advisable to perform tracheotomy to avoid the risk of œdema glottidis, which frequently develops in an extremely insidious way, and which may give rise to asphyxia. The main wound is stuffed with iodoform gauze to prevent the chance of aspiration-pneumonia. The patient must lie with the head low whenever he is recumbent; but he should be allowed to sit up very early, to allow of easy expectoration of the secretions of the wound.

We have already described under excision of the tongue the method by which the root of the tongue is removed by a subhyoid pharyngotomy.

Honsell [1] has collected 93 cases of subhyoid pharyngotomy of which the percentage mortality in simple tumours was 25, but in the malignant cases as much as 35. The prognosis must, however, be regarded as considerably better than is indicated by these figures.

40. Medio-Lateral Pharyngectomy (Retro-Laryngeal Resection of the Pharynx) (Fig. 279). Owing to the extreme frequency of tumours, especially carcinoma, in the region of the entrance of the larynx, *i.e.* affecting one of the arytenoid cartilages and the aryepiglottidean folds, and infiltrating the lateral wall of the pharynx and the sinus pyriformis, it is advisable to give a definite description of the method of exposing the lowest part of the pharynx with the least destruction of the parts.

Just as we have lately, on principle, employed a median incision for the tongue and upper part of the pharynx, we have similarly restricted the use of lateral pharyngotomy in favour of median pharyngotomy, for cases of carcinoma such as

[1] *Beitr. z. klin. Chir.* Bd. 25.

those for which we have frequently been called upon to operate, and the results have been thoroughly gratifying as regards its precision and the minimum damage done to the surrounding structures.

The incision is made, as in subhyoid pharyngotomy, along the lower border of the hyoid, through skin and platysma, but extending farther outwards on the diseased side, and only about 1½ inches across the middle line on the healthy side. From

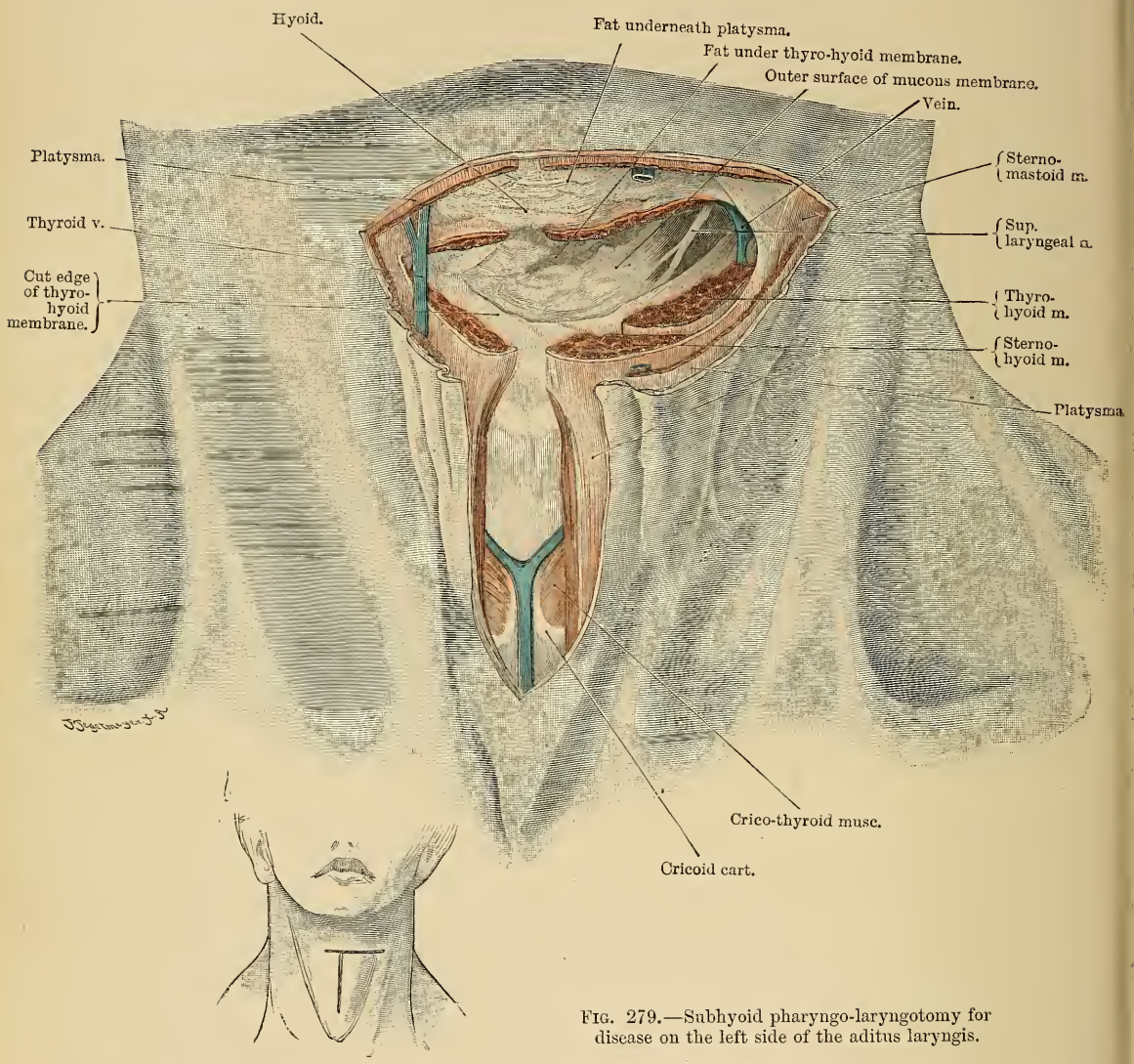

FIG. 279.—Subhyoid pharyngo-laryngotomy for disease on the left side of the aditus laryngis.

this another incision is carried through skin and fascia down to the thyroid and cricoid cartilages in the middle line as far as the isthmus of the thyroid, care being taken to avoid the vertical veins, the transverse veins being ligatured as in median laryngotomy.

On the diseased side the sterno-hyoid, thyro-hyoid, and omo-hyoid are divided parallel to the hyoid, a large lateral vein being ligatured, and the subjacent thyro-hyoid membrane is cut across as described in subhyoid pharyngotomy, the tip of the

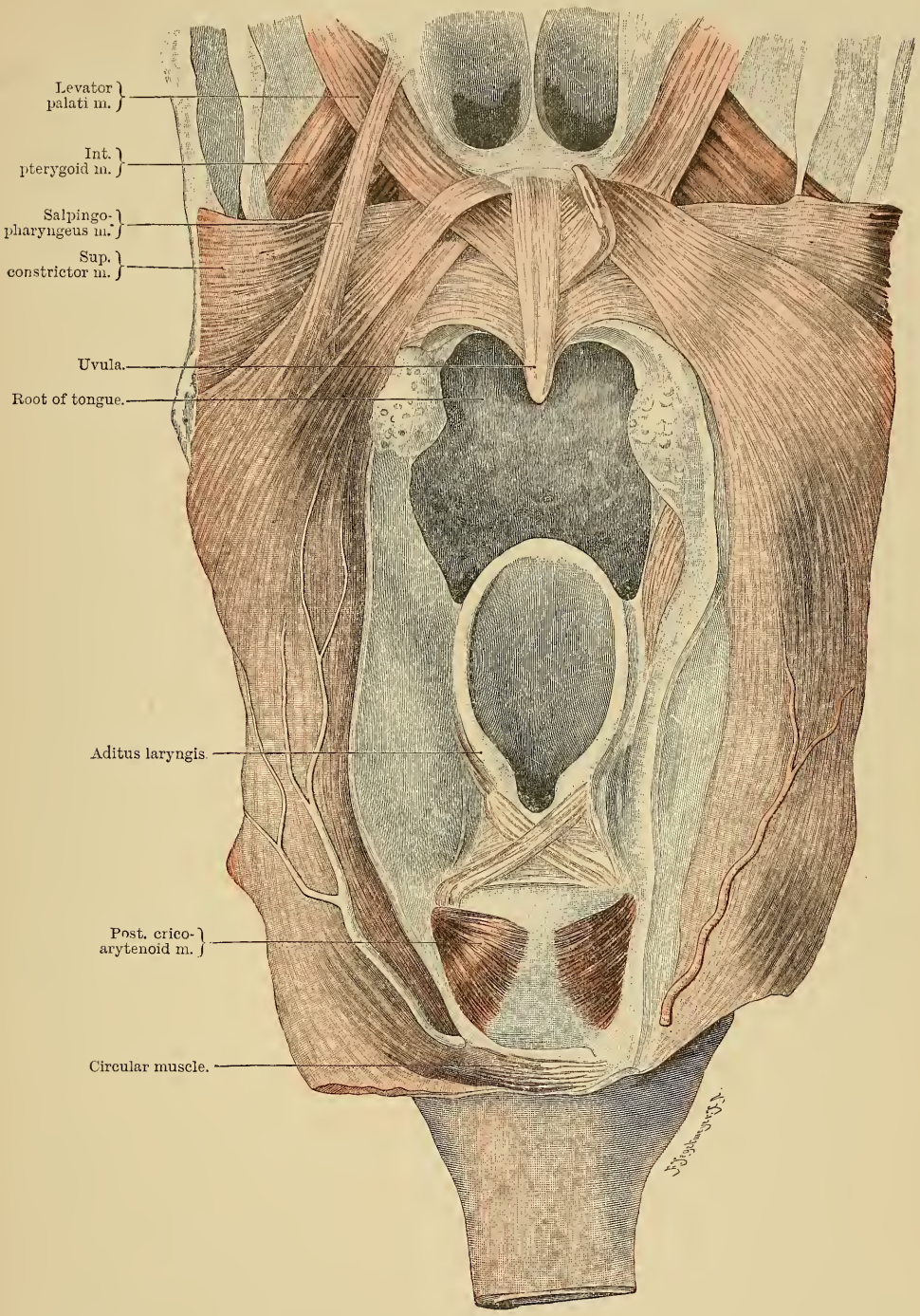

FIG. 280.—(From a dissection by Tramond.) To illustrate the relation of the structures in operations on the palate and pharynx. The entire pharynx is here split open from behind. Part of the mucous membrane has been removed in order to show the muscles.

epiglottis being then seized with a small sharp hook and dragged forwards and towards the healthy side, while the thyro-hyoid membrane is divided close to it vertically downwards as far as the thyroid cartilage.

The upper and anterior limits of the new growth are now defined, and the mucous membrane between the larynx and pharynx is divided ½ cm. wide of the disease. By this means a better view is obtained, and one is able to decide how much of the cartilaginous plate of the thyroid will have to be excised. The thyroid cartilage is not divided mesially as in pharyngo-laryngotomy (No. 35), but is split wherever it is considered best to do so, the muscles and perichondrium being first incised from without down to the cartilage, after which the latter is divided down to the mucous membrane of the larynx. If necessary, also, the cricoid may be divided behind.

The lower limits of the new growth in the pharynx or œsophagus can now be felt, and the latter opened below it. The anterior border of the cartilage is drawn forward and the mucous membrane on the posterior wall of the larynx separated as far down as the level to which the tumour in the pharynx (or œsophagus) has invaded the cartilage by which it is covered. Finally, a controlling finger is passed into the œsophagus and the mucous membrane between the larynx and pharynx is divided above, near—and often between—the arytenoid cartilages, and also the cartilaginous plate of the cricoid so far as the tumour is related to it.

As will be gathered from the description, we get at the lateral and posterior walls of the pharynx by adding to the incision parallel to the hyoid the median incision with splitting of the thyro-hyoid membrane. This allows one-half of the larynx to be powerfully pulled downwards and forwards. Removal of the base of the tongue by means of median pharyngotomy has already been described in connection with excision of the tongue. The incision extends from the chin to the thyroid cartilage; the hyoid is divided and the muscles attached to it are separated in the middle line, and thus a clear view of the root of the tongue is obtained.

This method of medio-lateral pharyngotomy is especially applicable to those cases of carcinoma of the pharynx in which the tumour is situated in the neighbourhood of the sinus pyriformis and involving to a greater or less extent the arytenoid cartilages and the œsophagus behind the cricoid.

Preliminary tracheotomy is necessary in all excisions involving simultaneously the pharynx (commencement of the œsophagus) and part of the larynx. It is advisable to perform gastrostomy in addition, so that the patient may be properly fed from the beginning, and to allow of the pharynx being plugged, or if it has been completely divided, so that it may be closed above and sutured to the skin below, with a view to a subsequent plastic operation.

Quénu and Sébileau report two cases of retro-thyroid pharyngotomy (*Rev. de Chir.*, Oct. 1904) in which a longitudinal incision was made along the outer edge of the larynx, and after dividing the superficial and deep fascia and ligaturing the superior thyroid artery and vein, the pharynx was opened behind the larynx. Division of the pharyngeal wall is facilitated if it is put on the stretch by pulling on the lateral wall of the larynx.

41. Lateral Pharyngotomy (Lateral Resection of the Pharynx). We have shown in connection with the operations on the tongue that all growths involving the fold between the upper and lower jaws, the tonsil, soft palate, and pharynx at the level of the isthmus, can be reached from the mouth by splitting the lower jaw.

As we have further shown that a medio-lateral pharyngotomy is preferable when the growth is situated below the hyoid, it follows that the indications for lateral pharyngotomy are few in number. Lateral pharyngotomy is confined to those cases in which adhesions have already formed externally, if such a case is still regarded as operable. These adhesions frequently arise as a result of the glands becoming swollen, inflamed and occasionally softened, and the pharyngeal wall and the soft parts covering it becoming adherent, the prospect of radical cure in this case being, of course, very slight.

The normal incision for the anterior triangle is used in all operations in which we have not only to expose the lateral aspect of the pharynx, the tonsils, and the base

of the tongue from without, but in which the soft tissues lying over them, and even the bones, have to be removed.

If the incision be employed in its full length, *i.e.* from the mastoid process to the hyoid bone, the lateral aspect of the tongue as far as the epiglottis and the lateral wall of the pharynx, together with the whole of the retro-pharyngeal space, may be exposed. As the posterior part of the incision must, in some cases, be taken full advantage of, the great auricular nerve and the external jugular vein must occasionally be divided.

After dividing the skin, platysma, and fascia, the submaxillary region is exposed. The facial vein which lies upon the outer surface of the posterior belly of the digastric, and the facial artery which lies beneath the submaxillary gland, together with the gland itself, must be dealt with before the floor of the mouth and the wall of the pharynx can be reached. The vessels are divided between two ligatures, while the gland is drawn out and turned upwards, or extirpated. It may be necessary also to ligature, close to their origins, the lingual, ascending pharyngeal, and ascending palatine arteries, or to tie the external carotid. In this way it is possible to draw backwards the great vessels of the neck, together with the vagus and spinal-accessory, while the arch of the hypoglossal nerve is drawn upwards. It is easier to ligature the external carotid, but ligature of a large vessel in the region of a necessarily septic wound is always attended by the danger of severe secondary hæmorrhage.

The superior laryngeal nerve and the superior thyroid artery remain beneath the lower edge of the wound. Those muscles which lie anteriorly and can be avoided must, in the interest of the swallowing mechanism, be preserved by working upwards along the inner surface of the jaw and along the internal pterygoid towards the mucous membrane. If, on account of adhesion or insufficient access, the muscles must be divided, then this is to be done in such a way that the innervation of the portions of the muscles which are spared is not interfered with. The posterior belly of the digastric and the stylo-hyoid are divided as near as possible to the hyoid bone, because their nerves of supply (from the facial) enter posteriorly; and for the same reason the stylo-glossus is divided near the tongue, the lingual and glosso-pharyngeal nerves which lie on it being avoided. The stylo-pharyngeus is divided in the region of its pharyngeal insertion, and the hyo-glossus and mylo-hyoid muscles, as far as may be necessary, at their insertions into the hyoid bone. The pharyngeal wall is now exposed, the superior constrictor above, the inferior constrictor below. When the lingual and glosso-pharyngeal nerves are involved they must, of course, be divided.

The upper part of the pharynx, however, is only thoroughly exposed to view by the *osteoplastic resection of the lower jaw* which we have already mentioned, or, expressed more exactly, by the oblique division of the jaw (from behind internally and above, obliquely forwards, outwards, and downwards) at the anterior border of the masseter, the ascending ramus being then drawn forcibly upwards and the horizontal portion forwards, or the posterior half of the ascending ramus of the jaw along with the condyle may be excised.

If the new growth involving the tongue and pharynx has extended to the fold between the upper and lower jaw and to the bone itself, it is best, after dividing the lower jaw as above described, and separating the capsule of the joint and the external pterygoid, to disarticulate and remove the ascending ramus, after detaching the healthy muscles, including the masseter. In this way subsequent closure of the jaws is most certainly avoided. The inferior dental nerve and artery are divided and the latter ligatured, as already described in resection of the lower jaw.

If the *lower part of the pharynx* behind the larynx is to be exposed, the muscles of the tongue and pharynx along with their nerves, as well as the branches of the external carotid artery, are all left undisturbed. The pharynx is opened below the superior laryngeal nerve, between it and the superior thyroid artery (which is divided). In order to expose the lowest part of the pharynx it is necessary to add to the normal incision (which is then correspondingly shortened posteriorly) a longitudinal incision, extending downwards along the anterior border of the sterno-mastoid muscle. When the lymphatic glands are adherent to the external soft parts only and can be thoroughly

removed without injury to the pharynx, it is better to perform the operation at two sittings—that is to say, first to excise the glands down to the pharynx, and it may be also to the œsophagus, and then to postpone opening the pharynx for a few days until the wound has granulated (in order that the fresh wound may not become infected with pharyngeal contents), after which medio-lateral pharyngotomy is performed.

Appendix. Suprahyoid Pharyngotomy. Jeremitsch has described a suprahyoid pharyngotomy which Spisharny has performed and for the introduction of which Grünwald claims priority. It is, however, identical with the lateral pharyngotomy described by us. If, on the other hand, the operation is performed through a mesial incision, division of the muscles attached to the hyoid bone above results, as Grünwald admits, in sinking downwards of the larynx, which makes fixation of the latter necessary. By dividing the muscles at the upper border of the hyoid bone, one gets of course a very good view into the pharynx, so good, in fact, that Hofmann's suggestion of attacking naso-pharyngeal tumours by this route appears quite justified. v. Hacker seems to have performed the first operation in man for a round-celled sarcoma of the root of the tongue.[1]

42. Œsophagotomy. The œsophagus is opened from the left anterior triangle of the neck, because it projects to the left of the trachea. If it be desired to expose it on account of the presence of a foreign body, Langenbeck's incision should be used. (According to Langenbeck, Goursand in 1738 first performed the operation.) This incision resembles that of Guattani and extends along the edge of the sterno-mastoid from the hyoid to a point one finger's-breadth above the clavicle. The skin and platysma are incised, and after dividing the fascia, the sterno-mastoid is drawn outwards, the depressors of the larynx inwards, and the omo-hyoid is divided. The thyroid fascia (outer capsule) is now incised, the gland itself is drawn inwards, and the large cervical vessels along with the descendens noni nerve are drawn outwards. The capsule of the thyroid is a part of the deep cervical fascia which is firmly blended laterally with the sheath of the large vessels. This fascia must be divided before access can be got to the œsophagus. Upon the anterior surface of the vertebral column is the longus colli muscle, and crossing it transversely, behind the common carotid, is the large inferior thyroid artery, which is to be divided between two ligatures. The red œsophageal tube now appears. Great care must be taken to avoid the recurrent laryngeal nerve, which, if necessary, is to be drawn downwards and inwards with a small hook. The nerve ascends along the groove between the trachea and the œsophagus, so that the latter must be opened quite laterally, or towards its postero-lateral aspect. It is difficult to open it in the collapsed condition. It should, therefore, be expanded by the introduction of a bougie or an olive-shaped probang. The patient is fed through a soft œsophageal tube which is passed from the wound and retained in position; the wound is stuffed with iodoform gauze. After a simple incision into the œsophagus, the latter may be closed with catgut, in which case the main wound must be left completely open, and a gauze tampon inserted in the lower end. Gussenbauer has incised deeply-situated fibrous strictures of the œsophagus through an œsophagotomy wound in the neck.

43. Resection of the Œsophagus. Resection of the cervical portion of the œsophagus is here considered, an operation which is practically always undertaken for carcinoma. We have performed it several times, and intend to publish the details of our cases.

The portion of œsophagus to be dealt with extends from behind the cricoid cartilage to the level of the episternal notch.

In 1873 Czerny first performed *œsophagectomy for carcinoma* with success. Since that date a large number of excisions have been performed, mostly in conjunction with excision of the larynx, the thyroid gland, the internal jugular vein, or lymphatic glands. Mikuliez recorded ten cases in 1886, and Rose a successful case in 1887.

The following is a description of the operation by which we successfully excised a carcinoma situated 19 cm. ($7\frac{1}{4}$ inches) from the upper incisor teeth.

[1] *Centralbl. f. Chir.*, 1906, No. 45.

The collar incision was made as for excision of the thyroid, and the skin, platysma, and fascia were dissected up. After ligaturing the thyroidea ima vein, inferior thyroid vessels and accessory lateral thyroid veins, the left lobe of the gland, which was much enlarged, was turned over to the right, and subsequently excised, the superior thyroid artery and vein being ligatured, and the isthmus crushed, tied and cut across—exactly as described for excision of the thyroid gland.

The œsophageal growth could now be readily felt and its upper and lower limits defined. It extended upwards a little beyond the cricoid, but was chiefly placed behind the upper rings of the trachea. The œsophagus was first freed at the level of the manubrium sterni, and raised up by passing an aneurysm needle behind it. Before, however, this could be effected the recurrent laryngeal nerve ascending from the thorax had to be divided. The nerve was exposed without difficulty, but on following it upwards, we found that it was flattened out on the surface of the tumour to which it was firmly adherent.

In a similar manner the lowest portion of the pharynx above the tumour on the posterior surface of the cricoid cartilage was freed by dividing the inferior constrictors.

The indurated portion of the œsophagus was now raised off the front of the vertebræ, and an attempt made to separate it from the trachea by blunt dissection; but as it was adherent to the membranous part of the trachea for most of its length, we had to remove the posterior ends of the tracheal cartilages for a distance of 4 cm. as well as a large piece of the posterior plate of the cricoid, together with the membranous part of the trachea. The tumour having been freed in this way, the œsophagus below it was drawn up on the finger, and opened in its long axis, a stiff stomach tube being inserted through the opening. The œsophagus was then firmly ligatured round the tube below the point at which the opening had been made, and cut across.

The freed portion of the œsophagus could now be completely separated from its surroundings by drawing the trachea forward with a sharp hook, after which a circular ligature was applied above the tumour, and the pharynx divided, by which means the tumour was cleanly excised wide of the disease.

The œsophageal tube was left *in situ*, the wound plugged with xeroform gauze, and the trachea opened in front, above the sternum.

The patient was kept with the head low and the trunk in an oblique position. He was allowed up the next day, and fed as generously as possible. By this method there was no soiling of the wound either at the operation or in the first few days immediately succeeding. As a precaution the edges of the mucous membrane on both stumps were touched with the thermo-cautery, while the œsophageal tube was left in position.

In a second similar case the curved transverse incision above the episternal notch proved equally satisfactory, and here also the left lobe of the thyroid had to be removed and the recurrent laryngeal nerve divided. On the other hand, the affected portion of the œsophagus, 4 cm. in length, could be separated from the trachea by blunt dissection.

In this case also an œsophageal tube was firmly tied into the lower end of the œsophagus, but it was at the same time brought out through the upper part of the pharynx and mouth, after the pharynx had been divided above the tumour and tied in position here also. The œsophagus was thus closed above and below, while the two parts were connected by the rubber tube. Tracheotomy was not immediately performed, but was found necessary later on on account of dyspnœa. On the other hand, a preliminary gastrostomy was made.

Tracheotomy and gastrostomy are necessary preliminaries to resection of the œsophagus. If a portion of the trachea has to be excised, it is better to cut the trachea across and stitch it to the skin at once, in order to avoid the danger of decomposing mucus entering its lumen. The lower end of the divided œsophagus may also conveniently be stitched to the skin, the upper end being closed and dealt with at a subsequent plastic operation. The wound must always be packed with xeroform or in part with iodoform gauze.

In regard to the direction of the skin incision, we are convinced from our experience in a third case in which an annular carcinoma extended behind the cricoid and uppermost ring of the trachea, that when the disease is situated high up, the longitudinal incision described for œsophagotomy affords sufficient access.

Hans has also described a mesial incision by which he opens the anterior wall of the œsophagus behind the trachea.

44. Pharyngoplasty and Œsophagoplasty. After an excision of the larynx and pharynx, Helferich restored the continuity with the cavity of the mouth by a plastic operation. The lower end of the pharynx, which had been closed at the first operation, was reopened and the interval between it and the œsophagus replaced by a tongue-shaped flap of skin, the cutaneous surface of which was directed inwards. The patient was able to eat and drink without discomfort. Bougies were passed at intervals, while the tracheotomy opening in the neck was left. Schalita (Mandelberg) has also restored a defect in the œsophagus after operation in a similar manner, excellent swallowing power being obtained.

Roux has recently, and with success, attempted œsophagoplasty in a very interesting manner, viz. by implanting a portion of intestine under the skin and connecting it with the œsophagus in the neck (*vide* Section on resection of the thoracic portion of the œsophagus).

45. Surgery of the Retro-pharyngeal Space. Congenital tumours are not infrequently met with in the region of the pharynx. With the exception of branchial-cleft carcinoma, they have as a rule no intimate connection with the pharyngeal wall, and can therefore be removed with comparative ease by our normal incision, without the necessity of opening the pharynx.

Special attention should be paid to the retro-pharyngeal glands, which have been accurately described by Giletti. Suppuration in these glands may occur secondary to disease in the pharynx or middle ear in children, as a result of which an acute retro-pharyngeal abscess is formed. In addition they are frequently the seat of tuberculous disease and give rise to prevertebral abscesses. A retro-pharyngeal abscess may further occur as the result of spinal caries.

The abscess pushes forwards the posterior wall of the pharynx, and may be opened by puncture at the level of the velum palati. Great care must, however, be taken to prevent the pus from entering the pharynx owing to the risk of choking or aspiration pneumonia. The method is only to be adopted in opening acute abscesses which cannot be felt from the exterior.

Tuberculous abscesses tend to spread towards the side of the neck, displacing forwards the great vessels of the neck. We were able recently to correct a diagnosis by this sign, the condition having been previously regarded as acute struma.

Such an abscess should always be opened from the exterior, as the operation can thus be performed aseptically in contrast to the method of opening through the pharynx.

For fluctuating tumours in the upper division of the anterior triangle Burkhardt recommends making the incision along the anterior border of the sterno-mastoid, and then passing inwards close to the larynx. But it is better in abscesses reaching further down to adopt Chiene's procedure, according to Bruns and Haas, and pass in at the posterior border of the sterno-mastoid. The incision is made parallel to the posterior border of the muscle, which is exposed after dividing the fascia; the superficial cervical nerves and the external jugular vein are avoided and the muscle retracted forwards with a blunt hook. The large internal jugular vein then appears and is retracted forwards after dividing the omo-hyoid. The scaleni muscles are exposed and the dissection is carried obliquely inwards along the side of the vertebral column. The abscess is now seen in front of the vertebral column, lying underneath the prevertebral fascia. Lower down in the neck, the inferior thyroid artery, which passes obliquely upwards in front of it towards the middle line, is divided between two ligatures. It is sufficient simply to push a blunt instrument through the deep fascia. Retro-œsophageal abscesses can also be evacuated by this method.

These abscesses, which result chiefly from tubercular disease of the vertebræ and

the lymphatic glands, are dangerous not only through obstructing the entrance to the larynx, but also on account of the possibility of sudden asphyxia if they be allowed to burst.

If there is necrosis of a vertebra the sequestrum can, in many cases, be removed with Lorenz's right-angled curved spoon.

Most (Breslau) has also removed a retro-pharyngeal lymphoma which had undergone caseous degeneration by dissecting between the common facial and internal jugular veins.

46. Radical Operation for Congenital Fistula in the Neck. These fistulæ which generally open at the lower end of the sterno-mastoid muscle obstinately resist all half measures of treatment. They can only be cured by complete excision of the canal, an operation which is not difficult, in spite of the deep situation of the upper part of the sinus, if the technique is properly carried out.

It is very desirable to introduce a probe, so that the direction of the canal can be defined. In one of our latest cases an excellent radiograph was obtained by injecting an emulsion of bismuth into the canal. The skin and platysma are incised down to the wall of the canal and the latter is then dissected out without difficulty as a tube, half as thick as a quill and irregularly dilated in places.

After excising an ellipse of skin round the opening, the tube is dissected up as far as the back of the great cornu of the hyoid and the posterior belly of the digastric and stylohyoid muscles. From this point onwards the tube is fairly loosely imbedded in the tissues, and is best freed by blunt dissection (v. Hacker's method). The upper end of the tube is dealt with by drawing it through the pharyngeal orifice, which generally must be dilated for this purpose, either by invaginating it from below with a fine pair of forceps, or by passing a probe from the opening in the pharynx and withdrawing it after firmly tying the tube round it. The tube is then drawn into the pharynx and mouth, ligatured and removed. By this method one can be sure of completely removing it, while at the same time its internal opening is closed. The external wound heals readily after drainage for a day or two.

47. Operation for Spasmodic Torticollis. The operative treatment of this distressing condition varies according to the nature of the spasm. Simple rotary spasm must be sharply distinguished from extensor spasm. In the former it is sufficient to throw the rotator muscles on the affected side out of gear; while in the latter, where the head is retracted, one has to paralyse temporarily a considerable extent of the extensor muscles of the back of the neck.

Neurotomy of the upper four cervical nerves is the treatment most usually adopted for rotary spasm. It is, however, a severe operation, and one which is very difficult to perform with accuracy, while it has the further disadvantage that the successive division of all the motor nerves to the muscles of the neck results in a definite paralysis. In our opinion it is a fortunate occurrence that some of the branches occasionally escape division.

If the large flap that is recommended by Gardner and Keen,[1] who originally proposed the resection of the first four cervical nerves, is made, *i.e.* by an incision extending from the external occipital protuberance to the mastoid process, and from the latter point to the spine of the sixth cervical vertebra, in order to expose the exits of the cervical nerves, one has to divide the muscles of the back of the neck to a considerable extent. We reproduce in Fig. 281 a diagram taken from Spalteholz's *Anatomy* (vol. iii.) which gives an admirable illustration of the nerves referred to.

In preference to this operation we simply divide all the affected muscles[2] and have obtained excellent results in a series of cases. We will here describe the method of performing the operation on the living subject in a case of simple rotator spasm to the right, and append an illustration of the muscles affected from a dissection made by Tramond (Fig. 282).

The first point of importance which arises in a case of right-sided rotator spasm is the division of the left sterno-mastoid, section of the spinal accessory nerve being

[1] Tubby, *Brit. Med. Journ.*, June 1906. [2] De Quervain, *Semaine médicale*, Oct. 1896.

also permissible on account of the accuracy and ease with which the branch of the nerve supplying this muscle can be reached.

To divide the sterno-mastoid an incision is made through skin and fascia along the upper third of its anterior border, after which the muscle is clearly defined (care being taken to avoid the small occipital nerve at its posterior border), and a blunt dissector passed underneath it. The whole muscle is then cut across a little below the mastoid process. In the milder cases, instead of simply cutting it across less disfigurement may be produced by elongating the muscle, while if the Z incision is used for this purpose (*vide* Tenoplasty in the introduction to Surgery of the

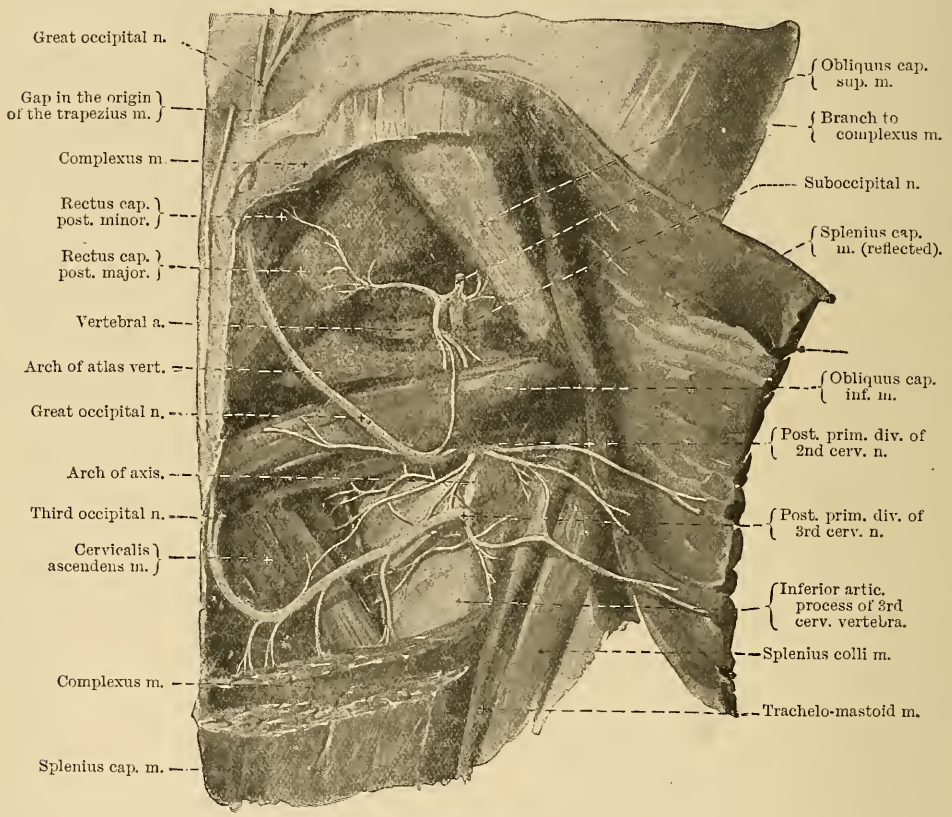

Fig. 281.

Extremities), the amount of elongation obtained must not be less than 6 cm. ($2\frac{1}{2}$ inches).

Division of the nerve, which is a simpler operation (*vide* Spinal Accessory Nerve in the surgery of the peripheral nervous system), is performed through an incision along the anterior border of the muscle, dividing the skin and platysma, and retracting the external jugular vein and great auricular nerve backwards and the facial and temporo-maxillary veins forwards.

The transverse process of the atlas is now defined, in front of which the spinal accessory is recognised as a fairly large nerve passing backwards to the deep surface of the sterno-mastoid. By raising it up on a hook, the branch proceeding to the sterno-mastoid can be readily distinguished from that supplying the trapezius. The latter, which is of large size, runs directly backwards from the sterno-mastoid and must be preserved.

The muscles of the neck, which must be divided in a case of right rotary spasm, are the right splenius capitis and colli, the right trachelo-mastoid, and the right obliquus capitis inferior.

A transverse incision, two fingers'-breadth below the superior curved line of the occipital bone, is now carried outwards and downwards from the anterior border of

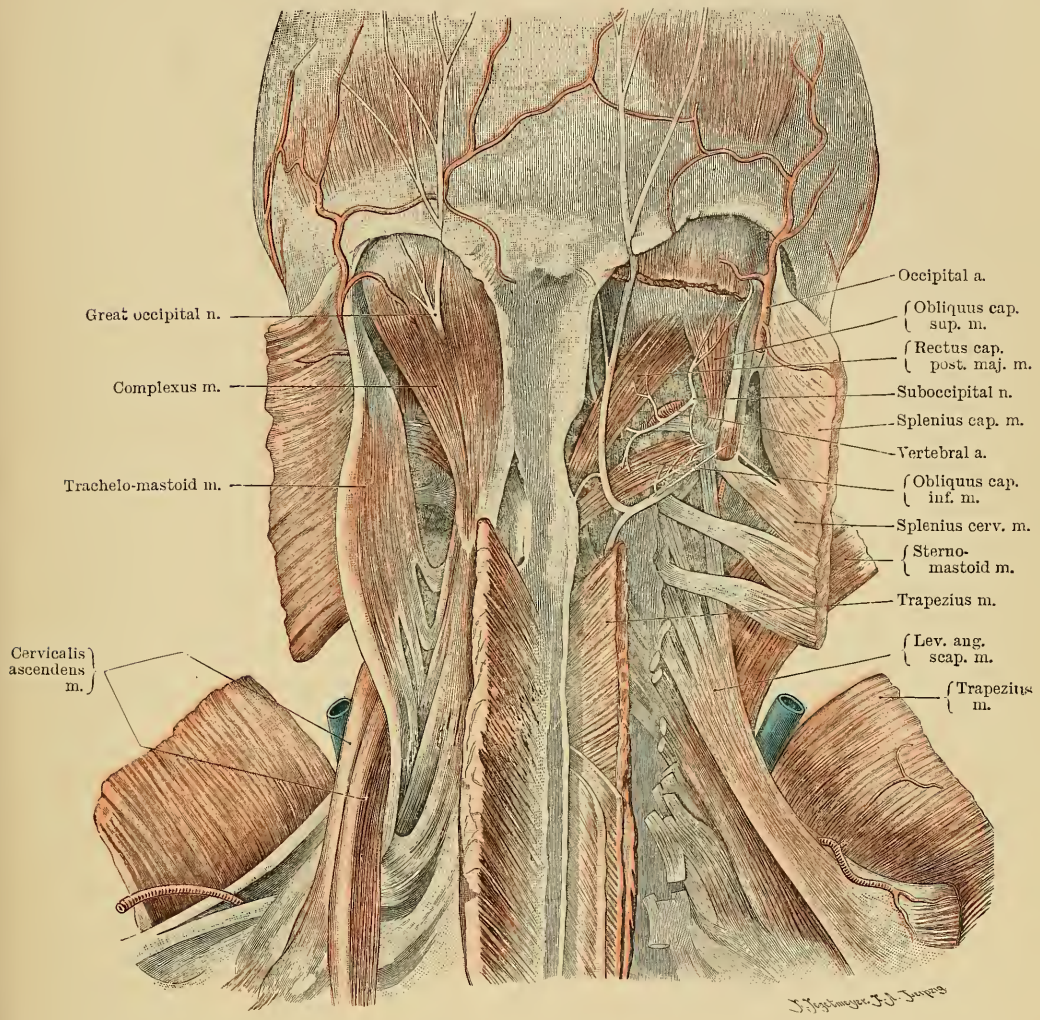

FIG. 282.—Dissection of the muscles of the neck (Tramond), to illustrate the relations of the muscles, vessels, and nerves in Kocher's operation for spasmodic wry-neck.

the trapezius to the sterno-mastoid. The splenius capitis is first divided in its entire breadth, not too near the bone, the small occipital nerve and the occipital artery being avoided. External to the splenius capitis the slender trachelo-mastoid is divided below its insertion into the mastoid process, and close to it the slips of the splenius colli to the transverse processes of the first and second cervical vertebræ are also cut across. The outer border of the thick complexus is now drawn inwards with a hook (or incised) exposing beneath it one of the most important of the rotator

muscles, viz. the obliquus capitis inferior, which passes from the spine of the second cervical vertebra to the transverse process of the atlas. This muscle must be thoroughly divided, care being taken to avoid the sensory great occipital nerve which hooks round its lower border.

The operation gives excellent results in pure rotary spasm, primary union being readily secured. On the other hand, in cases where an extensor spasm also exists, a much more drastic procedure is required. Not only must the attachments to the skull of the trapezius and complexus (sometimes also the slip of the semispinalis cervicis to the spine of the second cervical spine) be divided, but the small muscles of the neck, viz. rectus capitis posticus, major and minor, and obliquus superior as well, and occasionally on both sides.

In order to prevent excessive sinking-in of the transverse scar below the occiput, a transplantation operation may be considered, which is effected by freeing the trachelo-mastoid and stitching it to the peripheral portion of the trapezius after the latter has been divided at a distance from the occiput. Tavel recently operated on two cases by this method, and obtained satisfactory results, in the second case a plaster of Paris bandage being found of great service after the operation.

48. Exposure of the Thoracic Duct. The exposure of the thoracic duct is the same as that of the subclavian artery above the clavicle. In the root of the neck it arches outwards behind the left common carotid and opens into the subclavian vein close to its junction with the internal jugular vein. The duct may be exposed by a transverse incision through skin and fascia above the clavicle, dividing at the inner end of the incision part of the clavicular origin of the sterno-mastoid, and avoiding the external jugular vein, the incision being carried outwards as far as the anterior border of the trapezius. After the fascia and the fatty tissues have been divided the subclavian vein is seen lying on the scalenus anticus with the internal jugular vein descending towards it. The latter vein is freed along its outer border and drawn inwards, exposing the phrenic nerve (which must on no account be injured), running obliquely downwards and inwards on the scalenus anticus muscle. By dissecting carefully along the internal border of the scalenus anticus, transverse branches of the inferior thyroid artery are encountered, on dividing which the thoracic duct is discovered ascending from the mediastinum to reach the junction of the subclavian and jugular veins.

The exposure of the duct is undertaken not for the purpose of operative interference but as a precautionary measure in operations in the supra-clavicular fossa. It may, however, be ligatured or sutured in cases of injury.

Cushing was probably one of the first to suture the duct for injury. Thin silk and fine needles are required as in arteriorraphy, while the insertion of a magnesium tube, according to Payr's method, deserves occasional consideration. As a rule it is sufficient to ligature the duct or simply to pack the wound. The escape of chyle following division of the duct may prove very exhausting, but it generally ceases of its own accord. Unterberger (Garré's clinic) has collected 29 cases where the duct was injured during operation.

(d) Surgery of the Thyroid Gland

49. Indications for and Results of Operation for Goitre. The greatest number of tumours of the thyroid gland which call for surgical interference are of an innocent character. They are all included under the old term "goitre," the amount of mechanical interference with respiration depending on the relative position of the tumour. Too little attention has been paid to the altered character of the heart's action, associated with a simple goitre, which, although partly due to mechanical causes, is also greatly benefited by surgical treatment.[1]

[1] We hope shortly to deal fully with this subject, but have already expressed our opinion on it at the Medical Congress in Munich, April 1906, and on the occasion of two lectures to the Medical Societies of London and Cardiff, May 1906.

In addition, the question of surgical interference has also to be considered in Basedow's disease, as well as in inflamed and malignant goitres; in the former case early operation affords the most speedy and certain chance of success.

As a rule, a portion of the gland is excised in diseased conditions of the thyroid. In inflammatory goitres the treatment consists in incision, while in vascular goitres and in Basedow's disease, ligature of the vessels is undertaken. Apart from these minor operations (we have treated a great number of vascular goitres by ligature of the vessels), we have up to the present [1] performed excision on 3333 occasions.

The remarkable advances that have been made in wound-treatment are probably more conspicuous in this than in any other branch of surgery, notwithstanding the difficulties and the complicated character of the operation.

As we stated in a communication delivered at the German Surgical Congress, only three deaths occurred in 904 operations for simple goitre (in our third series of a thousand cases), the fatal termination in each case being attributable to cachexia, existing paralysis of both recurrent laryngeal nerves, and lesions of the heart and kidneys. If we bring up the total to 1000 by including 96 cases from our fourth series of a thousand, the percentage mortality of 0·4 per cent is obtained. In the 333 cases of our fourth thousand cases we have only lost one patient, who suffered from a high degree of dyspnœa associated with bronchitis and emphysema.

One may, therefore, conclude that in the various forms of colloid goitre, operative treatment, if carried out on definite lines, is free from danger, and should therefore be undertaken in all cases where medicinal treatment has failed, or—as happens in a large number of cases—has actually proved harmful.[2] In many cases medical treatment is hopeless from the beginning.

The iodine treatment is of no use, for instance, in the cystic goitres. It does harm in all cases where "goitre-heart" is present either in a mild or more severe degree, as well as in the inflammatory forms, while it offers no prospects of success in large nodular or in malignant goitres, especially in the latter where the favourable time for radical cure is allowed to elapse.

All goitres should be operated on when they are nodular, cystic, or becoming adherent, especially in the case of adults; when they extend into the thoracic inlet, or compress the trachea, and, lastly, when there is the least suspicion of malignancy, *i.e.* from the character of their growth, their hardness, irregularity, and fixation.

Notwithstanding these wide indications, however, one must bear in mind that here, as in all operations elsewhere, there is a limit fixed, beyond which surgery treads on uncertain ground.

50. Conditions influencing Extirpation of a Goitre. Notwithstanding all aseptic precautions and improved technique, we may lose our patient after excision of the thyroid when one or other of the following conditions exist:—

1. When there has been marked tracheal stenosis of long duration with constant emphysema and bronchitis, which, by causing imperfect oxygenation of the blood in the lungs, has interfered with the functions of other organs, especially the heart, the latter becoming dilated as a result of emphysema.

2. When the cardiac tone has been weakened by other causes, *e.g.* by general adiposity, with fatty heart; by atheroma, especially of the coronary arteries, with resulting myocarditis; by all conditions of venous stasis which have led to marked dilatation of the right side of the heart, with irregular, weak, and rapid pulse.

3. Where there is marked interference with the venous circulation, *e.g.* by a goitre pressing on the large vessels at the inlet of the chest, especially if thrombosis has occurred.

All these conditions are characterised by severe dyspnœa (which is frequently more marked and more troublesome than would be expected from the existing enlargement) and by deep cyanosis of the face, and occasionally of the hands, and, finally, by œdema of the face, hands, and feet. The puffiness of the face is often very striking.

[1] 9th Feb. 1907.

[2] Careless treatment with iodine is now more dangerous than excision of the goitre.

4. Where the entire thyroid is in a state of diffuse follicular colloid degeneration, with the healthy gland tissue reduced to a minimum. Such goitres are often of large size, and surround the trachea as a dense mass which is very slightly movable, having a firm nodulated consistence. To excise them is a difficult and bloody operation. Acute tetany may set in, and cannot always be combated by administering thyroid preparations. It is best, under these circumstances, to begin by ligaturing the vessels of supply to the gland, and, later on, when the tumour has diminished in size, to perform a unilateral excision.

5. In debilitated patients suffering from Basedow's disease, with extreme emaciation, irregularity of pulse, and a high degree of tachycardia. Even although we refrain from using either a general anæsthetic, or any antiseptic, these patients occasionally die in a few days, the wound remaining perfectly healthy. Here also preliminary ligature of the arteries is the rule, excision being performed later, if there are any indications of pressure on the trachea.

6. Where the tumour is malignant with marked infiltration and enlargement of the glands, where there are signs of thrombosis, and where the general condition of the patient is deteriorating, in which cases we have had better results and prolonged life with the administration of arsenic.

7. Where the goitre is inflamed, the inflammation involving the capsule and the structures adjacent to it. Removal of the thyroid in an acute inflammatory condition exposes the patient to the danger of a spreading wound infection; and if the goitre is in a state of chronic inflammation, its removal is often attended with severe hæmorrhage and shock (recurrent paralysis).

In those numerous cases where the above dangers (which are chiefly due to undue delay in operation) do not exist, we aim at a rapid, sure, and successful cure by operation under the following conditions:—

1. By avoiding all antiseptics, both in preparing the patient and during the operation, and by using the strictest aseptic precautions.[1]

2. By substituting novocain and adrenalin for a general anæsthetic. Nervous and sensitive patients with healthy lungs and heart may be anæsthetised with a mixture of air and ether (Braun's method) without hesitation. Vomiting during and after the operation often prevents primary healing by causing restlessness and secondary venous hæmorrhage, and by soiling of the dressings.

3. By using a large incision properly placed. We recommend our symmetrical "collar incision" as shown in Fig. 283. This incision leaves a scar which is hardly perceptible, while it gives plenty of room, and has the great advantage of enabling one to determine, in doubtful cases, which lobe is causing the greater amount of compression. We would especially warn the beginner against using small incisions which interfere with the arrest of hæmorrhage, and make it more difficult to remove more deeply-seated processes of the tumour. Our angled incision is to be preferred only in difficult highly-situated and adherent goitres, as it then greatly simplifies their removal.

4. By careful ligature of the chief arteries and veins (superior and inferior thyroid artery and veins, thyroid ima vessels, and the accessory veins), and at the same time by freeing the goitre within its fibrous capsule. This is the only way in which one can guard against severe loss of blood during the operation, against injury to the recurrent laryngeal nerve, reactionary hæmorrhage, and especially against tetany as the result of interference with the parathyroids which are related to the lower poles of the gland. Special care must be taken, if the removal of both lower poles is indicated, not to interfere with the parathyroids.

5. By preserving the sterno-laryngeal muscles along with their nerve-supply. If they are not preserved, the deformity, which results from the sinking-in of the soft parts, is considerable. We enter in the middle line between the muscles and detach

[1] The precautions we take to prevent infection have been already stated in the discussion of wound-treatment, where we showed how infection from the nose and mouth is guarded against by stretching a cloth transversely on a hoop between the neck and the head. Bungener has attempted to simplify this measure by using a small hoop hung over the ears and fixed to the chin.

them, if necessary, from their upper insertions. In this way their nerve supply remains uninjured, while the principle of muscle "disinsertion" is carried out (cf. Küttner's and Quervain's flap incisions). The divided muscles should always be carefully re-sutured.

51. Comparison with other Methods. It is convenient to call attention here to the differences between our method of operating and that of Billroth, for as Burkhard[1] has observed, various misconceptions exist in regard to their respective features. Our method is distinguished from Billroth's by the totally different skin incision that is adopted. Billroth, as a rule, employs an oblique incision which fails to leave so fine a scar as that given by the collar incision, at the same time affording less satisfactory access. A second distinction is that in our method we carefully preserve the muscles, which play an important part in the prevention of subsequent deformity.

A further difference of which too little notice has been taken, is that we dislocate the goitre *before* the main vessels are ligatured, the accessory veins alone being previously tied. It is only in this way that, as Wölfler has pointed out, the main vessels (superior and inferior thyroid artery and vein and thyroidæ imæ veins which run independently) can be ligatured at a distance from the surface of the tumour.

The latter procedure possesses great advantages, because in dissecting close to the goitre troublesome bleeding from the veins or from the parenchyma may be encountered. Finally, we shell the tumour out of its capsule, *i.e.* the outer sheath of connective tissue, with greater accuracy than is possible by Billroth's method.

We attach great importance to the careful separation of the external capsule, not only because by this method the removal of the tumour is facilitated and the application of the ligatures is rendered easier, but because it enables one to make sure that the external parathyroid bodies are detached and retained along with the capsule round the entrance of the inferior thyroid artery at the lower pole of the gland. Before the capsule can be separated, the dilated veins which we have termed the accessory veins, running from the capsule to the goitre must be double ligatured and divided as they become stretched out in the course of the dissection.

When the exteranl capsule, which might be termed the perithyroideum, and which is generally quite loose, is adherent as the result of inflammation, malignancy, or Basedow's disease, our method of operation becomes more difficult, and one has frequently to tie the vessels close to the goitre as recommended by Billroth.

Lastly, our method of dealing with the isthmus and the portion of the thyroid left behind by means of our goitre crushing-forceps is a new departure which greatly simplifies the operation. This was one of the first objects for which crushing was employed.

52. Normal Procedure for the Excision of a Movable Goitre. A symmetrical transverse curved incision is made, extending from the outer border of the one sterno-mastoid to the outer border of the other. The incision is placed at a higher or lower level according to the position of the goitre. In those lying entirely in the neck and fairly high up, the middle of the incision should be just below the cricoid cartilage, while in those which dip into the thorax it is placed just above the episternal notch. (The lower incisions as a rule leave better scars.) The skin and platysma are divided. This exposes, on the fascia, close to the middle line, the two anterior jugular veins (often double), which are frequently pushed to one side by the goitre (Fig. 285), also an oblique vein which is almost always encountered at the anterior border of the sterno-mastoid. We have termed this the oblique jugular vein (see Fig. 284). All these veins are divided between two ligatures. The external jugular vein, which crosses the sterno-mastoid obliquely from above downwards, may be avoided.

The sterno-hyoid, sterno-thyroid, and omo-hyoid muscles are now seen in the interval between the anterior borders of the two sterno-mastoids. It is important to separate the skin and subcutaneous fascia, along with the veins upwards and downwards off the muscles, so that the veins do not require to be divided a second time.

The sterno-laryngeal muscles are then separated in the middle line, and the

[1] *Centralbl. f. Chir.*, 1904, No. 29.

subjacent fascia is divided upwards and downwards upon the finger passed beneath it. The muscles are then pushed upwards towards the larynx, or incised as much as is necessary, the small muscular vessels coming from above being ligatured (Fig. 290). It is very important to see whether the fibrous external capsule of the goitre is divided at this stage or not. It must be divided, for as a rule it is only the subcapsular separation which can be easily accomplished with a blunt instrument.

Now comes an important step in the operation, viz. the dislocation of the goitre. The finger, introduced underneath the separated muscles and capsule, is carried round

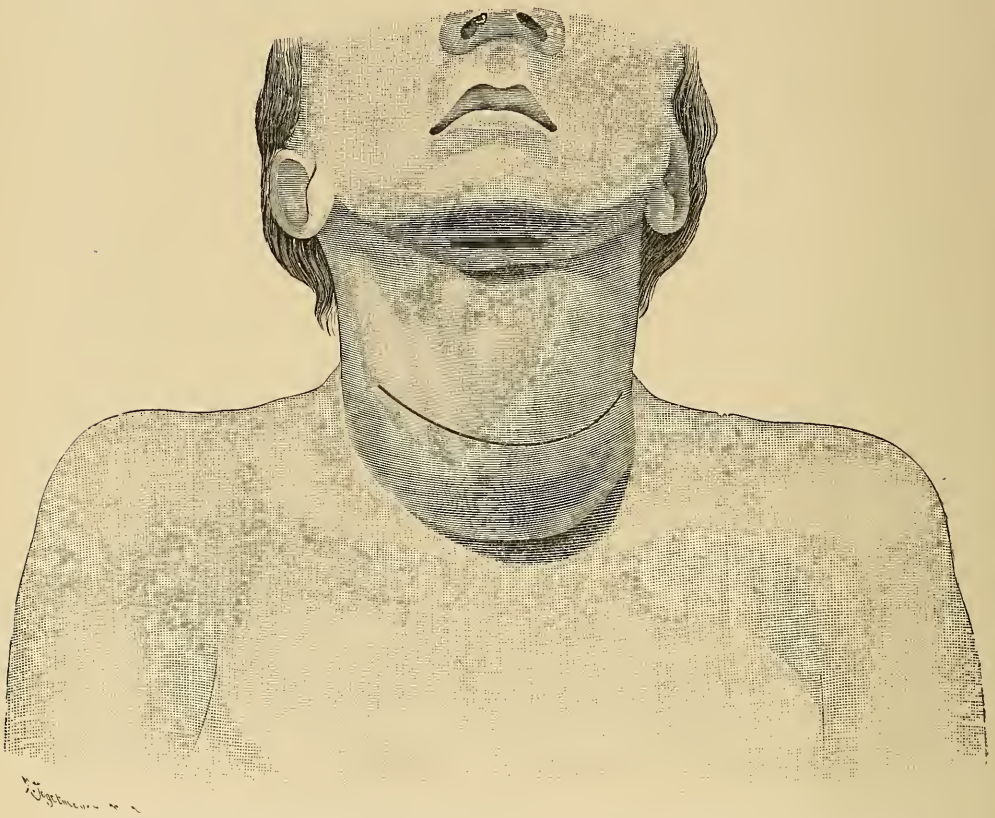

FIG. 283.—Symmetrical transverse curved incision (collar incision) for excision of the thyroid gland. The incision follows the line of cleavage of the skin of the neck, hence a fine cicatrix is obtained.

the tumour, so as to isolate and hook forward the bands which stretch from the neighbouring tissues to the gland, and which contain the veins called by us the accessory veins (Fig. 286, *a*, *b*). These veins are very well developed in large goitres. During the above procedure the muscles and external capsule are drawn aside with blunt retractors. After the accessory veins have been ligatured and divided, the dislocation of the goitre is effected by dragging it forwards with the fingers. Severe dyspnœa, if it exists, at once ceases when the dislocation is effected.

The next step is the ligation of the main vessels, which can be done seriatim. With a blunt dissector (Kropfsonde) the capsule is separated internally and externally from the upper cornu until one can isolate a pedicle consisting of the superior thyroid artery and vein, which pass downwards and inwards. These main vessels are then divided between two carefully-applied ligatures (Fig. 291).

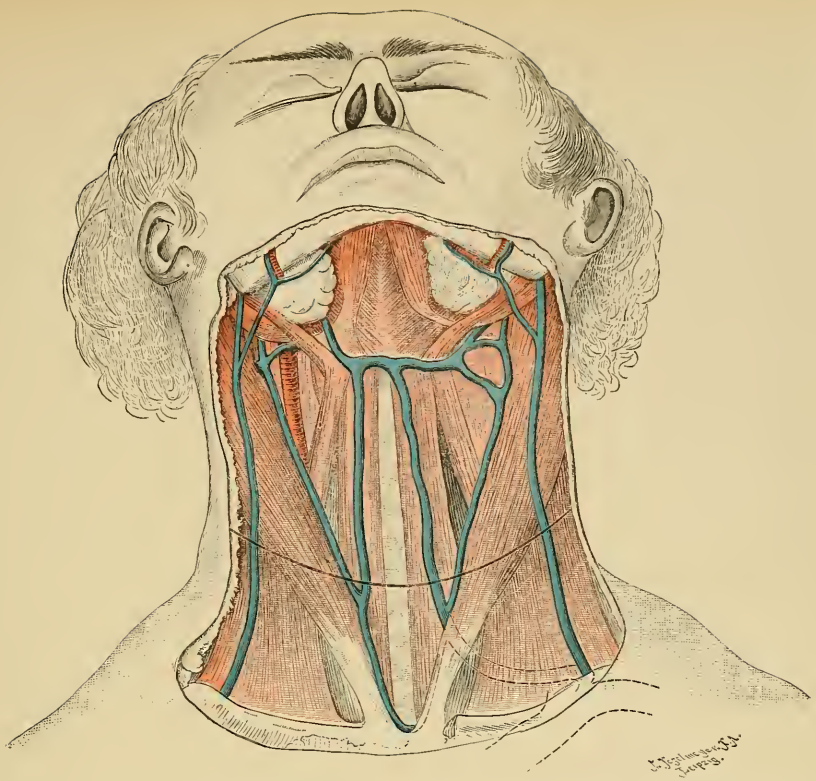

FIG. 284.—Dissection to illustrate the external, oblique, and anterior jugular veins, skin and platysma having been removed. The anterior and oblique veins are necessarily divided in making our collar incision, but the external jugular veins as a rule escape. After division of the skin, platysma, and the veins, the deep fascia is incised down to the muscles.

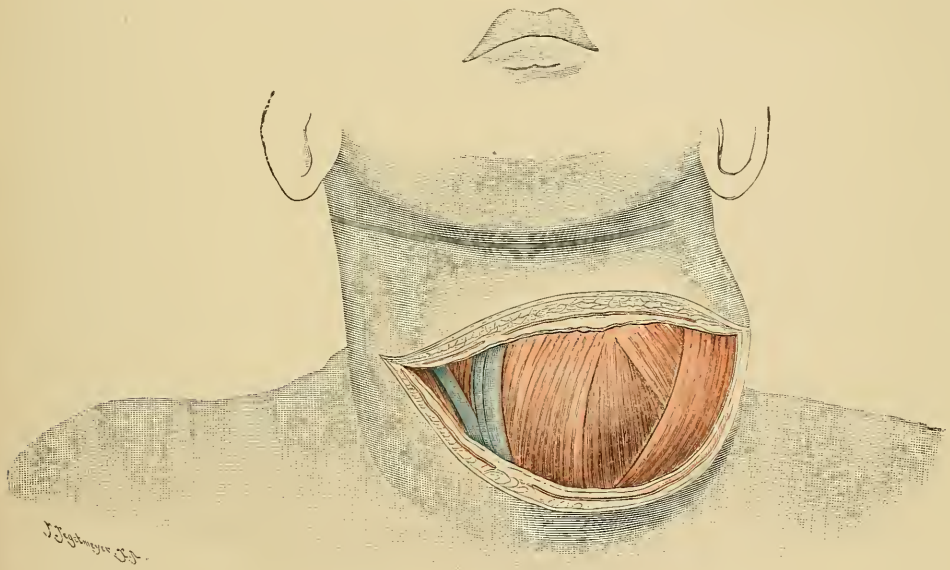

FIG. 285.—On the left of the figure are seen the anterior jugular veins, pushed well over to the right side of the neck. The sterno-hyoid and sterno-thyroid muscles are spread out over the tumour. On the right of the figure is the sterno-mastoid with the omo-hyoid seen running obliquely upwards towards the middle line, all the muscles on this side being displaced outwards.

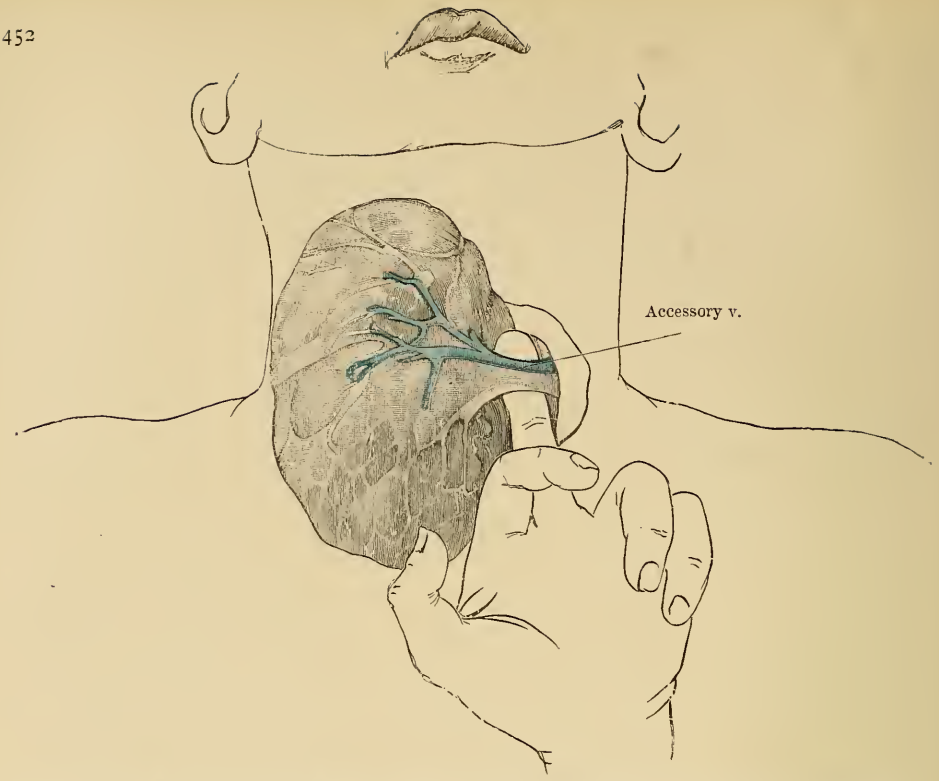

Fig. 286*a*.—The lateral and lower fibrous connection with the strands which contain the accessory veins as they pass from the inner capsule to the outer capsule are seen isolated by the finger prior to being ligatured.

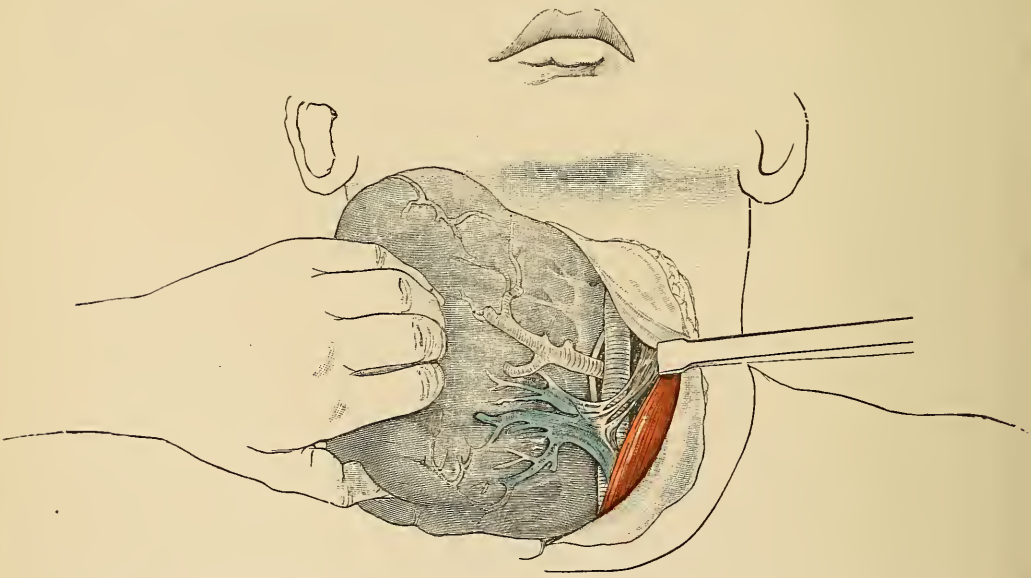

Fig. 286*b*.—The goitre is dislocated and pulled over to the opposite side, the left sterno-mastoid being well retracted to the same side (more force than shown in the figure). The common carotid artery is seen lying deeply (it is here represented as too superficial and too near the trachea). Crossing in front of it, to the posterior and lateral aspects of the goitre, are the accessory veins, and passing inwards behind it is the inferior thyroid artery, with the recurrent laryngeal nerve ascending behind it and dragged forwards by the traction on the goitre.

The inferior thyroid artery lies on the deep muscles of the neck. To expose it the tumour must be forcibly pulled to the opposite side and the muscles on the same side retracted. The vessel is then felt as a pulsating cord emerging in an oblique or transverse direction from behind the carotid, and then passing inwards to enter the

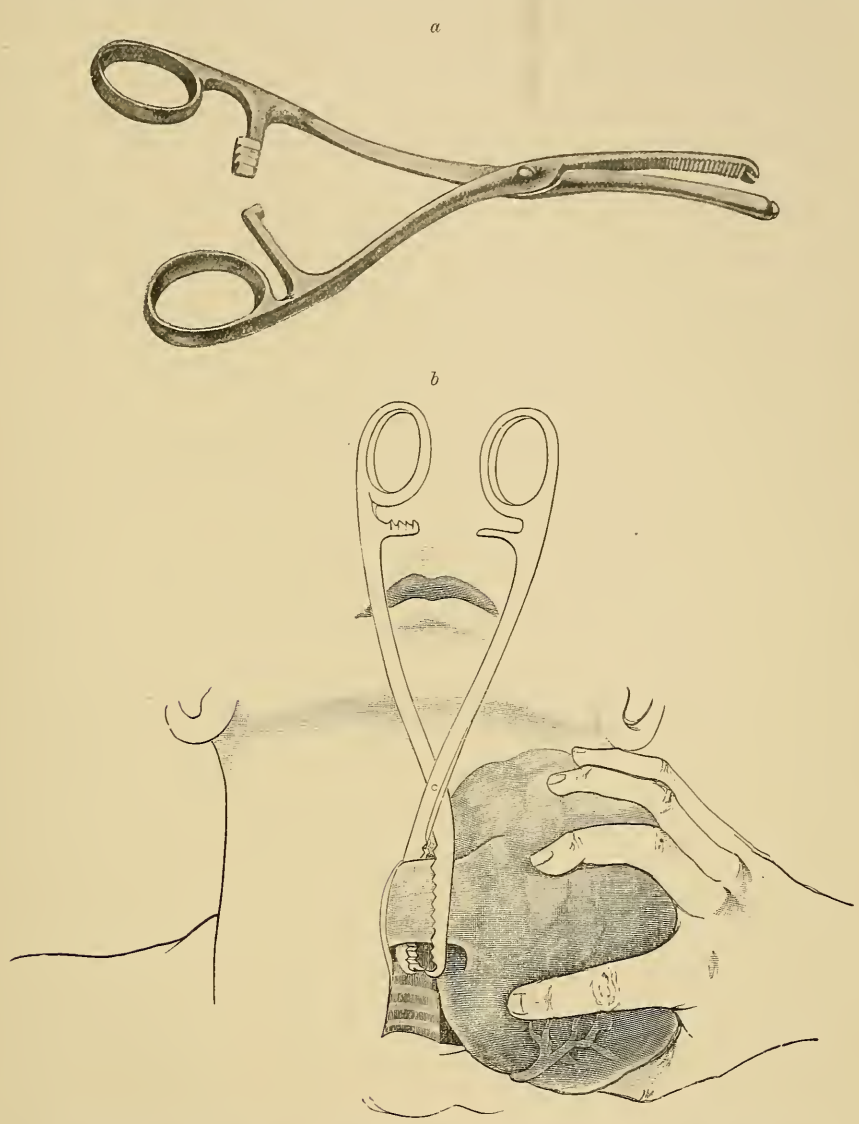

FIGS. 287 *a* and *b*.—*a*, Goitre crushing-forceps. *b*, Application of the crushing-forceps before ligaturing the isthmus.

thyroid at its attachment to the trachea. In ligaturing it, care must be taken to avoid the recurrent laryngeal nerve which ascends behind it (Fig. 291).[1]

[1] In favour of early ligature of the arteries in excision of the thyroid it is pointed out by Doyen, and extensively confirmed by Gubaroff, that venous bleeding is reduced to a minimum, not by tying the veins, because this causes congestion in other veins, but by cutting them through, and by arresting the arterial inflow by tying the arteries.

At the lower pole of the tumour, and generally entering its median surface, there is to be found occasionally a single artery, the arteria thyroidea ima. There are usually two or three large venæ thyroideæ imæ, which leave the inner and anterior aspects of the lower lobe. The outer capsule of the gland having been pushed back, these vessels are isolated with the finger or dissector and divided between two ligatures (Fig. 286 and 292).

The isthmus, and in some instances also the processus pyramidalis, still remain to

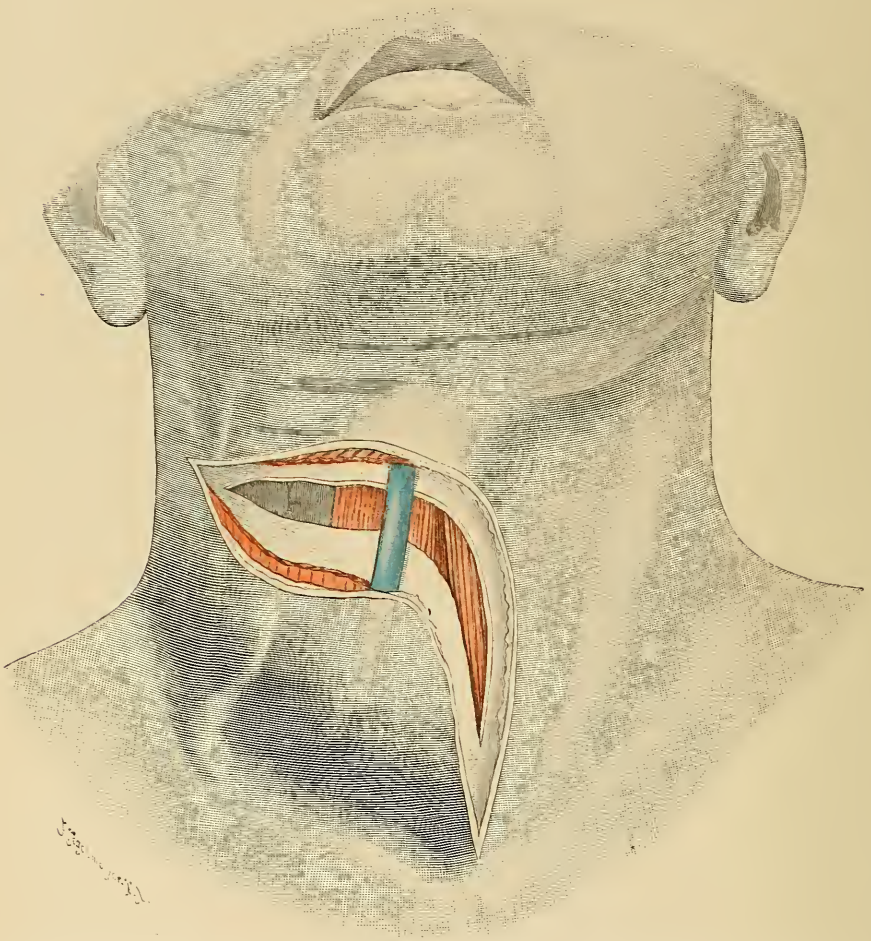

Fig. 288.—Excision of goitre by the angular incision. Stage 1: Skin, platysma and fascia have been divided, exposing the right anterior jugular vein and the depressor muscles of the larynx.

be isolated and divided. The latter is more easily freed and is supplied by a special branch of the superior thyroid artery and vein. In isolating the isthmus it is, as a rule, desirable to separate and divide the communicating branches between the veins of the two sides, which run along the upper and lower borders of the isthmus, and sometimes on its anterior surface. On account of their constant presence and size we have termed them the superior and inferior communicating veins. The isthmus can be separated from the trachea with the blunt dissector without any great bleeding, but care must be taken not to tear the trachea (Fig. 293).

Special forceps are then applied (Fig. 287*a*), and the isthmus, which is frequently

very thick, is so compressed that after removing the forceps only the vessels and connective tissues are left, which are then firmly tied with a strong ligature before being divided.

The diseased half of the thyroid is now only attached to the trachea and cricoid cartilage. If this part is healthy it should be allowed to remain, a thin layer of gland tissue being left to protect the recurrent laryngeal nerve and parathyroid from

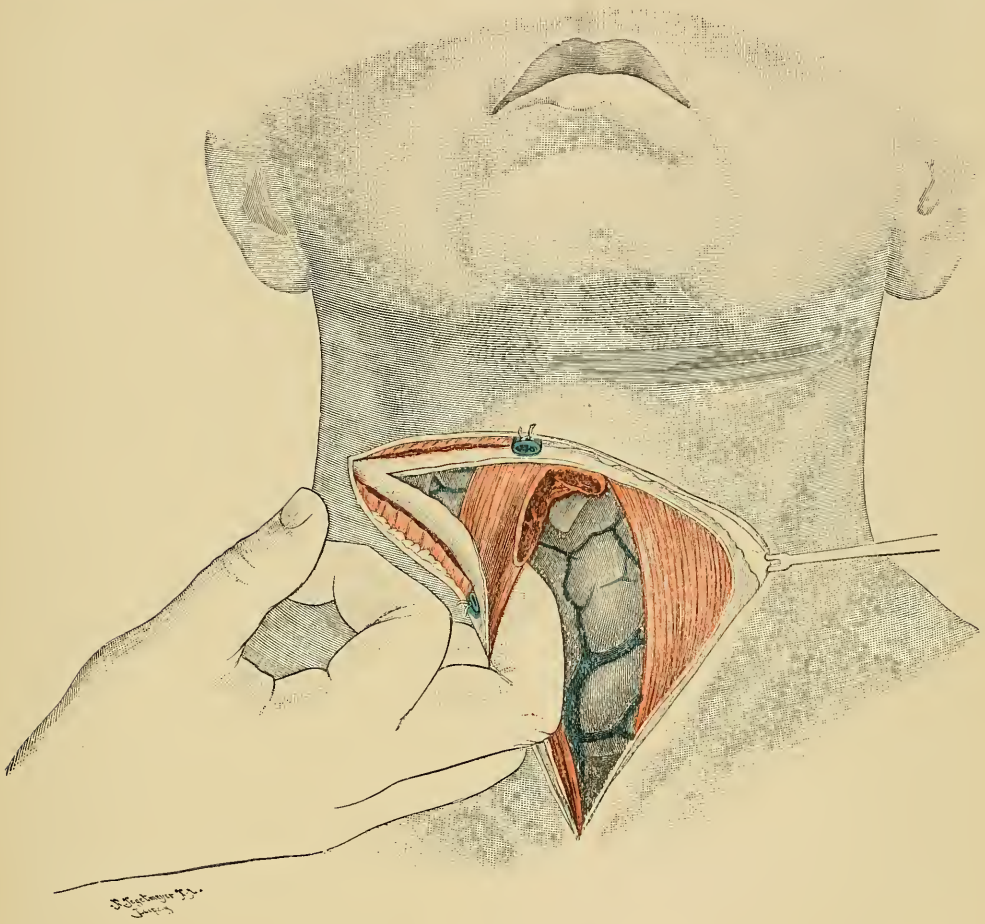

Fig. 289.—Excision of goitre by the angular incision. Stage 2: The fascia between the sterno-laryngeal muscles has been divided and a finger has been pushed underneath the right sterno-hyoid muscle, the upper insertion of which has been nicked.

being cut through or enucleated. One cannot be too careful to avoid injuring this nerve at the last moment, and it is desirable, therefore, to catch every bleeding point.

After ascertaining that the wound is dry, it is stuffed with gauze and covered with gauze towels, while the surrounding parts and the hands are purified, after which the numerous ligatures and sutures are tied, clean sterilised cotton gloves being worn for this purpose. If it has been necessary to completely cut across the upper attachments of the muscles, they should be sutured in position again, the fascia being united in the middle line. The wound is then closed with a continuous suture of fine silk (the platysma and, in stout individuals, the subcutaneous fat must also be

sutured), and a small short glass drainage tube inserted, which may generally be left in for twenty-four hours.

53. Procedure in Difficult Cases. The curved transverse incision is not invariably successful in goitres which extend high up and low down in the neck, and which are very large or firmly adherent. It is therefore in such cases as a large diffuse colloid goitre, an inflamed, or a malignant goitre, or in Basedow's disease that the angled incision greatly simplifies the operation.

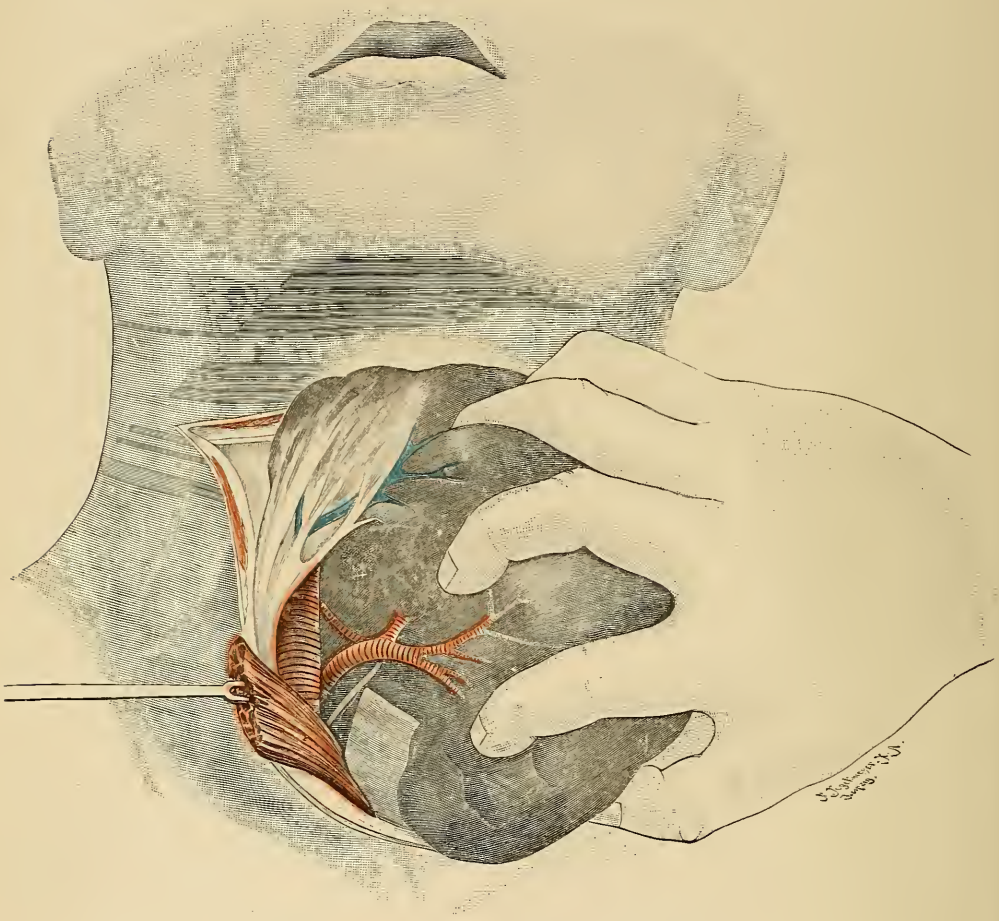

FIG. 290.—Excision of goitre by the angular incision. Stage 3: The fibrous (outer) capsule of the gland has been divided and the goitre displaced to the healthy side (dislocated). The sterno-hyoid and thyroid muscles have been cut across above and turned downwards in order to obtain more room. In the lower angle of the wound the trachea is exposed, and is crossed by the inferior thyroid artery, which passes inwards from under cover of the carotid. The recurrent laryngeal nerve is seen behind the artery. The common carotid is shown more externally, while a portion of the external gland capsule, containing an accessory jugular vein, has not yet been divided.

The angular incision begins at the level of the thyroid cartilage over the prominent part of the sterno-mastoid, and is carried forwards to the middle line following the fold of the neck, and then vertically downwards as far as the suprasternal notch. In deeply situated tumours it may be prolonged on to the manubrium sterni. To facilitate the subsequent suturing a few transverse scratches should be made with the

knife across the line of incision. The skin, and, in the transverse part of the incision, a distinct layer of platysma, are divided (Fig. 288). In the middle line, the large anterior jugular vein, and, at the anterior border of the sterno-mastoid, the "oblique

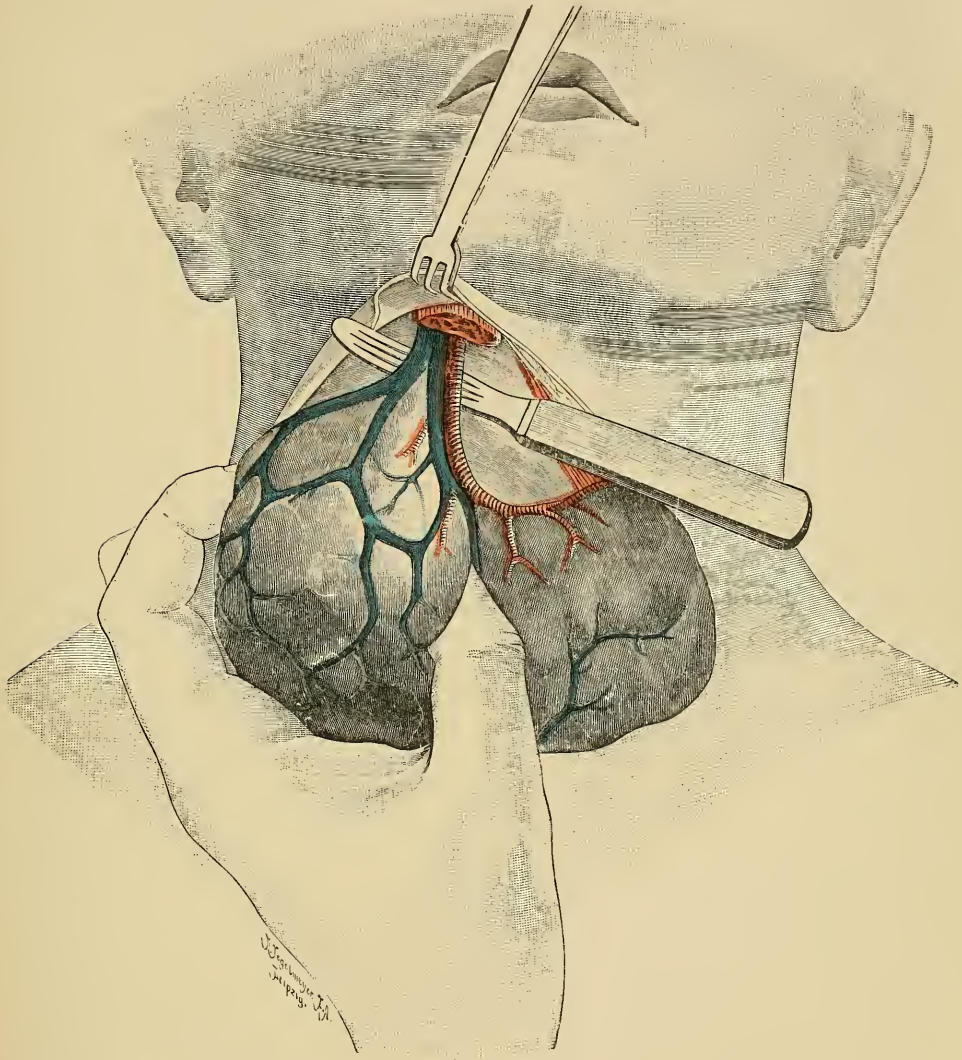

Fig. 291.—Excision of goitre by the angular incision. Stage 4: The outer gland capsule has been divided high up and the accessory veins have been ligatured, allowing the superior thyroid artery and veins to be isolated. They are here shown raised on a blunt dissector, the goitre being at the same time depressed with the left hand. In the upper angle of the wound is seen the cut end of the sterno-hyoid muscle.

jugular" vein, are double ligatured and divided. The external jugular vein, which crosses the sterno-mastoid from above downwards, can be preserved.

After division of the fascia the muscular fibres of the sterno-mastoid are freely exposed at the outer part of the horizontal limb of the incision. The muscle is thoroughly freed along its anterior border and retracted by means of blunt hooks.

In a similar manner the fibres of the sterno-hyoid and sterno-thyroid muscles are exposed and retracted upwards, with the superficial fascia covering then.

The sterno-hyoid muscles are now divided below the hyoid, and the sterno-thyroid muscles below their insertion into the thyroid, and are turned down along with the flap of skin, platysma and fascia together with the external thyroid capsule. In doing this the accessory veins are secured and divided. In this way a very good view of the anterior surface of the tumour is obtained and excellent access is got to the vessels, which are thus more readily ligatured. The accompanying figures, in

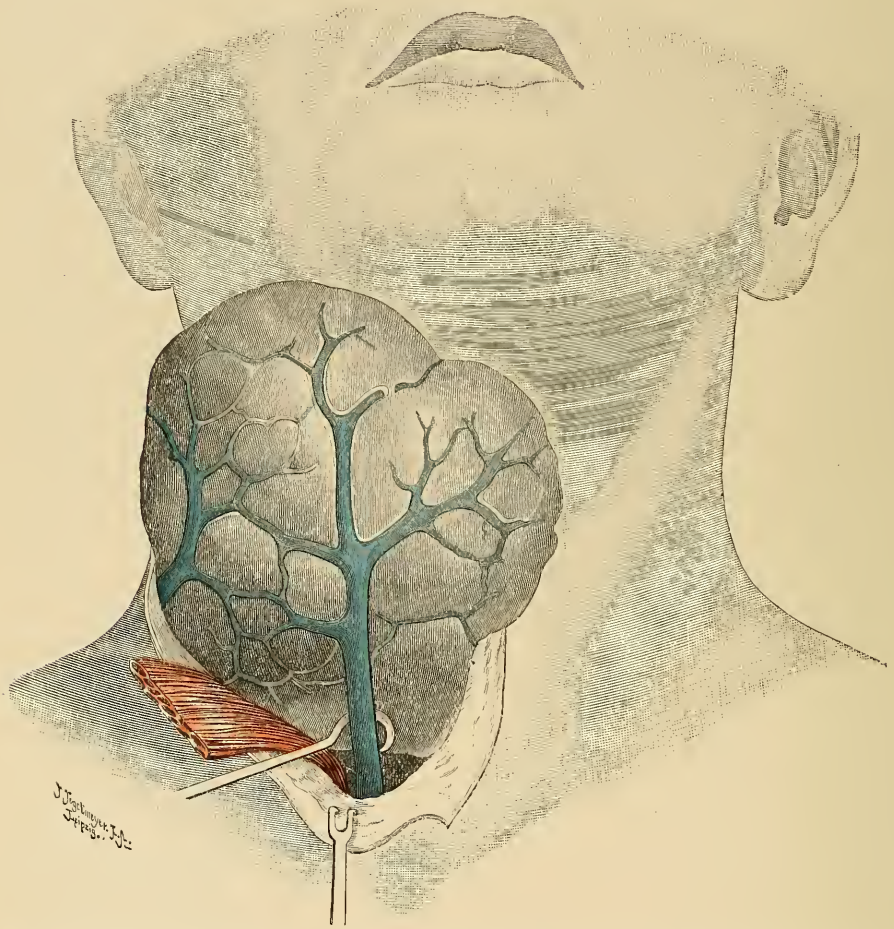

FIG. 292.—Excision of goitre by the angular incision. Stage 5: Dislocation of the goitre. The sterno-laryngeal muscles have been divided high up and drawn backwards (as a rule one should avoid cutting them completely across), the goitre has been turned upwards, and the right thyroidea ima vein isolated and raised on a hook.

conjunction with the description of the normal operation already given in detail, will sufficiently explain the subsequent steps when the angular incision is used.

54. Excision of a Median Goitre. It is comparatively uncommon to find a goitre developing from the isthmus, and one generally observes on careful examination that mesial goitres have really grown from the inner portion of one or other lateral lobe.

If, however, the tumour is actually situated in the isthmus, peculiar difficulties

are presented, since its removal entails a double division, *i.e.* of both the right and left lobes, into one or other of which the tumour often extends for some distance. It is particularly in these cases that excision is more urgently indicated, as the pressure exerted by the tumour on the front of the trachea is very considerable.

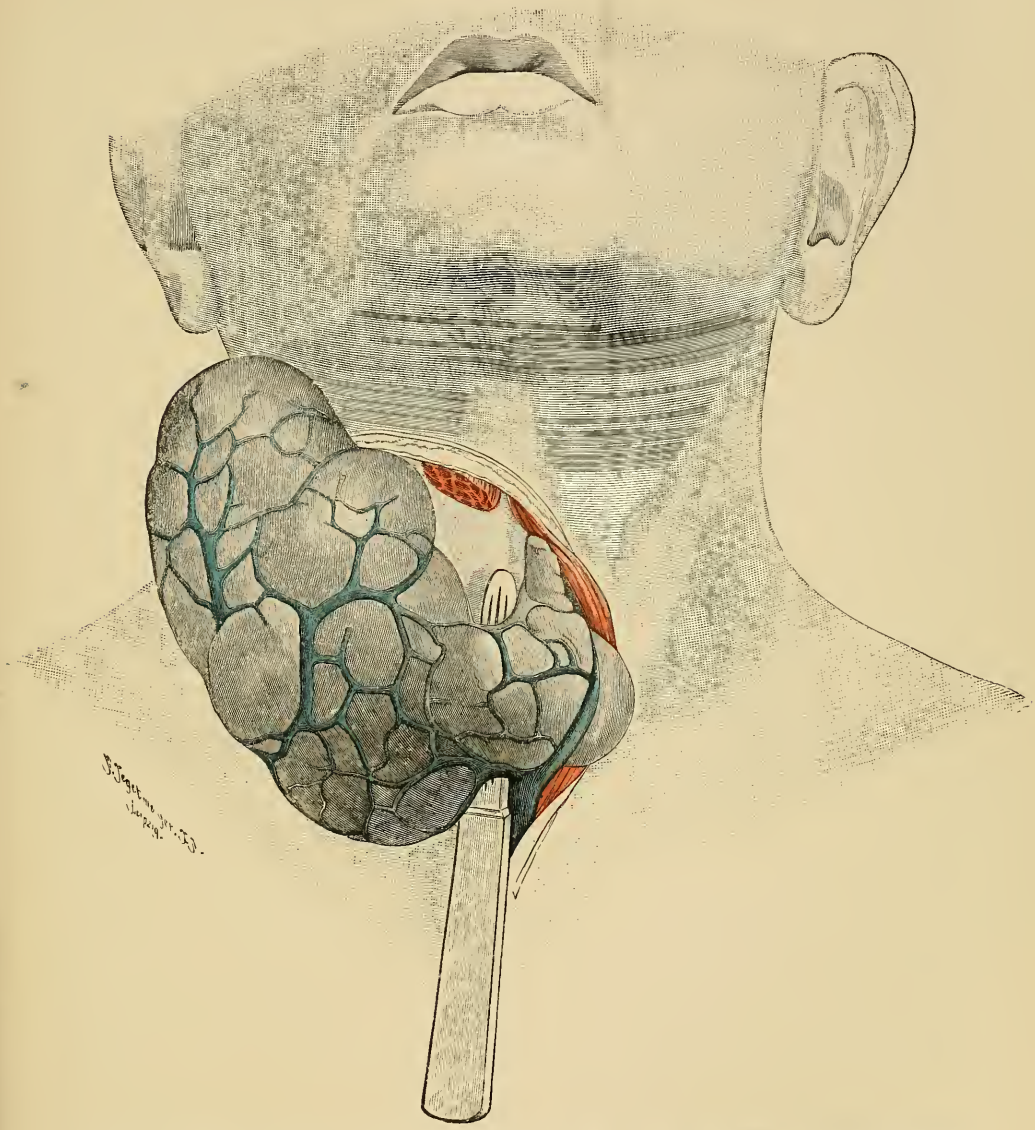

FIG. 293.—Excision of goitre by the angular incision. Stage 6: The right lobe of the gland has been completely freed from its vascular connections and a blunt dissector pushed underneath the isthmus, between it and the trachea, preparatory to the application of crushing-forceps.

In disease of the isthmus our curved transverse incision (collar incision) is specially suitable, since access must be got from both sides. As soon as the muscles are separated and the external capsule is incised, the exact relation of the tumour to the lateral lobes must be defined.

Should there be a constriction on one side of the tumour, the procedure is similar to that for the removal of a lateral nodule, *i.e.* the narrow portion is exposed, crushed, and divided. The tumour is then dissected off the trachea, the branches (not the trunk) of the superior thyroid vessels and the superior communicating veins being ligatured and divided above, while the thyroideæ imæ veins and the inferior communicating veins are dealt with in a similar manner below. One has then to attempt to obtain on the other side a pedicle which can also be crushed and divided. If this is found to be impossible, a resection must be undertaken, *i.e.* the line of division must be through the thyroid tissue itself.

The operation is much less embarrassing when the mesially-placed tumour can be enucleated, as is the case more especially with a cyst. Enucleation is here permissible, to a limited extent at least, on one or other side.

If one or other lateral lobe is diseased as well as the isthmus, the former must first of all be freed and dislocated, after which the isthmus can be dissected off the trachea as far as the other side.

55. Enucleation of the Goitre. It was v. Burkhardt who drew special attention to the difference between intra-capsular excision and enucleation. In the former the external capsule of enveloping connective tissue alone is stripped off the tumour (the peri-thyroideum), whereas in the latter one cuts into the vascular tissue of the thyroid which, in a more or less thinned and atrophied condition, covers the contained cyst (or cysts) or colloid masses (epithyroideum). On account of the great vascularity of the epithyroideum, the operation of enucleation must not be confounded in any way with intra-capsular excision, while it cannot be compared with the latter in respect to certainty of success.

Enucleation, recommended by Porta, and brought into general use by Burkhardt for cysts, and by Socin for colloid tumours, is especially indicated in those cases where there are numerous well-defined colloid nodules, both large and small, scattered equally through both halves of the thyroid. Unilateral excision is in such cases not sufficient, as the pressure on the trachea may not be more marked on one side than the other. Enucleation is therefore indicated, but in this way only the larger nodules can be removed. The operation, though not a radical one, is free from some disadvantages which the radical operations possess, as it preserves healthy gland tissue, causes no injury to the recurrent laryngeal nerve, and is simple to perform.

It is the simplicity of the procedure that frequently misleads the inexperienced into giving it the preference over excision. It is attended with more serious hæmorrhage than excision, because bleeding and general oozing occur from numerous small vessels in the capsule which is left behind. On this account, as well as from the fact that it does not ensure a radical cure, it is not a good method to employ. Along with Brunner, we have seen a great number of cases recur where merely enucleation had been performed.

As in excision, hæmorrhage must be prevented by preliminary ligature of the main vessels. There is thus no advantage in performing enucleation because the part of the gland which is left dies from want of blood-supply. Attempts have been made to diminish the bleeding by forming above and below a pedicle which contains the main vessels, to which artery forceps are then applied. This formation of a pedicle is, however, a relatively coarse procedure, as is enucleation itself. It is comparatively easy to form a pedicle at the upper pole of the goitre, but if the inferior thyroid artery is to be included in a pedicle, one has absolutely no safeguard against compressing, and so paralysing, the recurrent laryngeal nerve. In addition to all this there still remains the disadvantage that recurrence may take place. Enucleation should therefore only be performed in the following circumstances :—

1. When the other half of the thyroid is atrophied, or has already been removed at a previous operation.

2. When isolated nodules are to be felt in otherwise healthy gland tissue, especially if they are present on both sides and are giving rise to pressure symptoms.

3. When a single nodule exists which has caused extensive pressure-atrophy of the surrounding gland structure, so that vascular gland tissue is only present to a

limited extent, generally posteriorly. It is in this manner that large cysts and old colloid nodules are imbedded in the gland. Enucleation is almost forced upon us if we mistake the thin layer of gland tissue (gland capsule) for the external capsule (adventitious or false capsule) and divide it, and are satisfied that the mass can be easily separated. It is often necessary to apply numerous ligatures in the neighbourhood of less atrophied parts of the gland. The enucleation of large cysts, as is recommended by Burkhardt, is therefore justifiable, as the hæmorrhage is considerably lessened.

4. Lastly, when the goitre is very adherent to the external capsule, as a result of acute or chronic inflammation (*e.g.* after repeated hæmorrhage or a prolonged course of treatment with iodine).

Enucleation is performed as follows :—The surface of the goitre is thoroughly freed and exposed in the manner previously stated, and the muscles are retracted. At the most prominent part of the tumour, where the inner capsule (capsule proper) is thinnest, the gland tissue is incised until the nodules appear, artery forceps being applied to the edges and to each bleeding vessel. A blunt dissector is then introduced between the normal tissue (gland capsule) and the nodules, and the latter are separated and shelled out. It is often advisable to reduce the bulk of the mass by removal of its contents, or by evacuating a cyst.

The farther back one dissects with the blunt instrument the more the bleeding, so that numerous artery forceps have to be applied. As soon as it has become evident that the enucleation is going to be a matter of great difficulty, it is advisable to give up the attempt and proceed to excision, or to adopt the enucleation-resection method, to be described later. Single cysts and nodules, for example, those which have undergone recent inflammatory changes, are easily shelled out, so that the operation is soon finished. Peripherally-placed nodules are often found to have a pedicle after the gland capsule has been divided. Crushing-forceps can be readily applied to the pedicle and the removal of the nodule is thus simplified.

It is often possible to definitely arrest the hæmorrhage by including many of the bleeding points in a few ligatures, or to ligature them in a mass ; but this cannot always be done. In certain cases the bleeding may be arrested by means of a tight suture. However, it is the enucleation cases which give more trouble than the excisions, and in which the healing of the wound is more often interrupted by the formation of hæmatomata.

56. Resection of Goitre. Mikulicz has suggested resecting the diseased part of the thyroid gland, but we can only recommend the procedure for exceptional cases. Hæmorrhage is generally less easily controlled than is the case in excision, and the wound does not run such a favourable course, as large stumps of tissue are left which undergo necrosis while the ligatures occasionally become separated.

Resection is certainly rendered easier by using angiotribes, or, as we prefer to call them, histotribes (tissue crushers) (Fig. 287*a*). By means of the forceps which we have made, thick pieces of gland tissue can be so compressed and diminished in size that they can be easily included in one or more ligatures. The blades are closed upon the tissues as firmly as possible, and not until they have been removed are the ligatures applied.

This plan, however, does not succeed in every case, as the gland substance is often so brittle that the forceps cut into it, giving rise to severe bleeding, which is difficult to stop. Resection should, therefore, be restricted to the following cases :—

1. When the nodules are small and prominent and can be easily separated from the substance of the gland to a certain extent, and isolated. After raising them up they can be divided, pressure-forceps being applied behind the seat of division, after which the ligature (or even a suture) is applied, and the separation completed.

2. When we have to deal with a diffuse colloid degeneration without the formation of definite nodules, and where the firm mass presses upon both sides of the trachea and is difficult to lift out. Even in these cases a better plan would be to perform a typical unilateral excision, although it sometimes happens that the dense colloid mass on the opposite side is so firmly and widely attached to the trachea as to seriously

interfere with the healing. This also sometimes occurs where a previous unilateral excision has been done, the growth on the other side having subsequently enlarged, so that, despite free removal on one side, stenosis sometimes results.

In these circumstances preliminary ligature of the vessels on one side should be resorted to. We have also adopted this plan as a preliminary to subsequent excision in the case of diffuse colloid growths.

57. Enucleation-Resection and Enucleation-Excision of Goitre. We have introduced this combination of the preceding methods for the purpose of obviating the dangers of enucleation, and at the same time making use of its advantages. The principle of the operation consists in confining the excision to the anterior and easily accessible portion of the growth, enucleating, on the other hand, the posterior part by

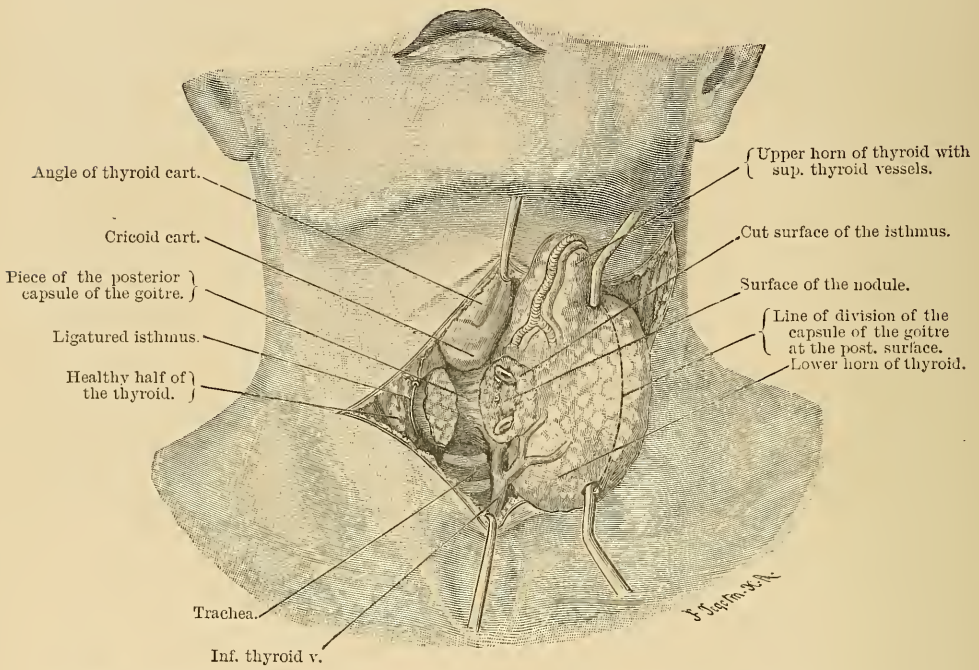

FIG. 294.—Enucleation-resection of a hypertrophied nodule from the left lobe of the thyroid. The left lobe of the thyroid has been brought out of the skin incision, the isthmus ligatured and cut across, and the cut surfaces of the latter drawn apart so as to bring into view the surface of the colloid nodule. The line of division of the capsule of the goitre is indicated on the anterior surface by the two aneurysm needles, on the posterior surface by the interrupted line (which has been placed too far forward).

resection, and leaving behind the posterior part of the inner capsule of the gland, which is usually the thickest. Fig. 294 gives to some extent an illustration of the method.

After the surface of the goitre has been fully exposed in the usual way, the isthmus, which is freed close to the tumour, is compressed, ligatured, and cut across.

In this way access is got to the tumour through an opening in the true gland capsule, as shown in Fig. 293. Into this opening a finger or blunt dissector (Kropfsonde, Fig. 295) is introduced upwards and downwards at the inner aspect of the tumour, so as to separate the gland capsule and allow of the introduction of the pressure-forceps, first in an upward, and then in a downward, direction. After the tissues have been compressed an aneurysm needle is passed under them and a ligature applied.

Under some circumstances this linear separation must be repeated in the neighbour-

hood of the upper and lower poles. By seizing the goitre and rotating it outwards, the tumour can be rapidly torn away from the inner aspect of the posterior part of the true capsule, which then constitutes the only connection the tumour has with the trachea.

The posterior wall of the capsule cannot be divided in a vertical direction without fear of injuring the recurrent laryngeal nerve, as one is working at some distance from the trachea. Bleeding may be prevented either by the careful application of artery forceps, or simply by the application of the clamp (histotribe), followed by a ligature. The dotted line in Fig. 294 is intended to represent the posterior incision through the detached inner capsule, which is to be left behind. It should have been drawn much nearer the trachea, and it is meant to be vertical.



Fig. 295. Goitre dissector.

The method has the advantage of reducing considerably the bleeding which proves so troublesome in enucleation and resection. Moreover, by leaving a well-nourished piece of gland tissue posteriorly, and the parathyroids, it does away with all anxiety regarding the opposite lobe. It also avoids any injury to the recurrent laryngeal nerve. It is obvious that the main vessels must not be ligatured before they enter the gland. But even this admirable method has a more limited field than excision. It is not to be recommended in diffuse colloid degeneration in the form of very small follicular colloid foci, but is only advisable where there are one or more large colloid or cystic masses, forming spherical tumours imbedded in relatively healthy gland tissue. It should be employed in recurrent goitres where one-half of the gland has already been removed.

58. Evacuation and Fragmentation of the Goitre. This operation which was described by us and which we have frequently practised, differs from intracapsular excision and intraglandular enucleation in that neither the perithyroideum nor the epithyroideum, *i.e.* gland tissue, is removed, as the nodule is simply incised and taken away by reducing or breaking it up, the method being analogous to "evidement" as practised for foci in bone or to "morcellement" in vogue for fibroma uteri.

The operation is chiefly indicated in large-sized cystic goitres, in order to avoid the necessity of making too large an incision in the thyroid tissue. The cyst is cut into, its wall grasped with forceps and pulled out, the surrounding tissues at the same time being pushed back.

In colloid tumours this procedure is almost forced upon the operator in those cases where a nodule with softened contents has, as the result of a periglandular adhesive inflammation, become adherent to the capsule and the surrounding tissues. Excision would here be too serious a matter.

We have seen excellent examples of this condition in nodules which had undergone degeneration after hæmorrhage. Removal of a thyroid tumour may become necessary on account of the rapid increase in its size from hæmorrhage into it, accompanied by slight inflammation. Excision in such a case is unfavourable on account of the inflammatory adhesions with the surrounding tissues, the severe bleeding, and the danger to the recurrent laryngeal nerve.

The tumour is therefore cut into with a knife, the vessels in the line of the incision being doubly ligatured. The bleeding edges of the wound are then firmly seized with artery forceps, as in enucleation, and, after rapidly clearing out the disintegrated colloid masses and clot, which form the chief contents, the soft colloid masses which remain are easily shelled out from the inner surface of the cyst with the finger. A curved needle is passed under the bleeding vessels, which are then ligatured, the cyst wall being at the same time folded. The hæmorrhage is far less than in enucleation, and the operation can be performed very rapidly. Moreover, it is almost painless, as

the gland capsule is not injured. One of our patients, who had a large, rapidly-growing hæmorrhagic colloid goitre, expressed her astonishment at the close of the operation, which was performed under cocainisation of the skin, that she had felt absolutely no pain.

The method is very suitable in those cases where one has to deal with multiple colloid nodules in both lobes which are movable and embedded in loose tissue. The nodule is grasped at its base between two fingers, raised up, and split with a knife in its entire length, by which means the capsule is stretched and a better pedicle obtained. Without relaxing our grasp we apply a pair of our pressure forceps below the fingers. The pedicle, which is thus compressed, is then ligatured with strong silk, the forceps removed, and the nodule cut away without bleeding.

In some circumstances, when the nodules are malignant and softened, and when excision is rendered impossible on account of the firm adhesions, this method of "exenteration" is very useful, as it gives immediate, though temporary, relief. In a case published some years ago, we obtained a permanent cure by the introduction into the cavity of a chloride of zinc tampon. We recently treated in this way a soft papilloma, the capsule of which was thick and firmly adherent. This procedure may often be employed in these cases instead of tracheotomy, as the latter is a very unpleasant last resource in malignant goitre.

But it is of the greatest service: (1) in nodules of large size whose contents are breaking down and softening, and which are adherent to the surrounding parts; (2) in multiple small softened tumours which can be sufficiently pulled forward to be cut into and evacuated, and where the relatively small amount of hæmorrhage can be controlled by ligature or suture; (3) especially (on account of the rapidity with which it can be done) when there is a danger of asphyxia, and when the pressure on the trachea must be quickly relieved during the operation. This is nowhere so well seen as in deeply seated nodules, and in intrathoracic goitres. Hence exenteration is often a *sine qua non* in enabling us to complete the operation in the neck.

The procedure has been erroneously ascribed to Porta, an Italian surgeon, whose method is identical with our enucleation.

59. Operation for Intrathoracic Goitre. Unfortunately the presence of an intrathoracic goitre is sometimes either overlooked altogether, or the diagnosis is made too late. An extremely sad picture is presented by a person, who has been treated for asthma, dying from this disease which is supposed to be a mediastinal tumour. If operation is delayed too long in intrathoracic goitre the outlook is certainly ominous, as asphyxia may suddenly supervene. The lungs and heart may become involved, the innominate veins and their tributaries (subclavian and internal jugular veins) have their lumen narrowed to half the proper size by the pressure of the tumour, and thrombi may form in the distended parts of the veins above. In one of our cases, after the wound had healed by first intention, and while the patient was indulging in free movement, a thrombus in the common jugular vein became loose and caused immediate death from embolism of both pulmonary arteries.

It therefore follows that timely operation should be undertaken. Cases will be found to be operable in which the tumour at first sight seemed to be quite inaccessible. We once operated on a man with marked symptoms of tracheal stenosis (but whose general health was satisfactory) and in whom a skiagram showed a large tumour which appeared to be quite beyond removal. After having satisfied ourselves, however, that the tumour moved on coughing, we ventured to make the attempt, with the result that after ten days the dyspnœa had entirely disappeared, and the patient since then has enjoyed excellent health.

The operation is difficult, and requires both skill and experience. The incision, which must be placed low down, should, as a rule, be the collar incision, as it is often difficult to tell with which side an intrathoracic tumour is connected. It is of the utmost importance that the tumour, or the healthy gland, be exposed on the side in which the nodule is situated, where it is accessible in the neck. The vessels at the upper pole of the gland, as well as the lateral accessory veins, are double ligatured and the isthmus is exposed, crushed, and divided between two ligatures. In this way

the connections of the tumour in the neck are thoroughly freed, and the gland (healthy or diseased) can then be used as a handle by which the intrathoracic growth may be pulled upwards. One must proceed very carefully and step by step expose the vessels (especially veins) which enter and leave the surface of the tumour and divide them as low down as possible between two ligatures. If necessary, the sternal portion of the sterno-mastoid should be divided, while the muscles proceeding from the sternum to the larynx should be thoroughly separated in the middle line up to their upper attachments and then widely retracted. The critical moment then comes when the tumour must be seized with the forceps (Fig. 296) we have specially devised for the purpose and dragged forcibly upwards. All the vessels entering the surface

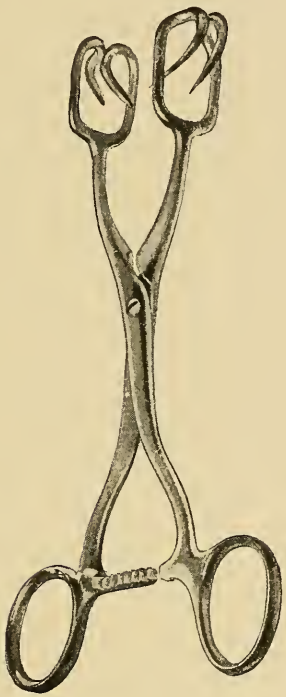

Fig. 296.—Goitre-forceps. The ring-shaped blades cause no hæmorrhage, while the recurved hooks prevent them from slipping.

Fig. 297.—Goitre-spoon for releasing intrathoracic goitres.

of the goitre should be divided between two ligatures, as otherwise they are liable to give way.

The goitre cannot always be pulled out from its deep attachments with forceps. Occasionally it is necessary to introduce a long, broad, blunt elevator, or an instrument like a spoon (Fig. 297), underneath the tumour so as to raise it up.

Lastly, in the most difficult cases, as in the one quoted above, the tumour may be too large to allow of its being delivered through the aperture of the thorax. In cystic conditions the procedure is simple: the tumour is incised, and the cyst wall is drawn forcibly upwards. Fortunately intrathoracic goitres are generally softened and cystic. In colloid and malignant tumours, on the other hand, one must decide to diminish the size of the growth by exenteration, by forcibly inserting a finger into it, and tearing out the colloid material piecemeal as in "morcellement." The bleeding is so severe that the tumour, after being diminished in size, must be drawn as quickly as possible

to the surface in order that the vessels may be tied, and also because the dyspnœa is often very aggravated at this stage. If it has not been possible to tie the inferior thyroid artery previously, this must now be done, and therefore the tumour must not be pulled out too suddenly. If, in spite of every care, the artery is torn, the bleeding may be stopped by firm pressure with the finger downwards and outwards until the vessel can be caught, which must invariably be done. Packing the wound to arrest hæmorrhage is a bad procedure.

The after-treatment, if asepsis has been attained, is conducted on the same lines as in ordinary goitre. The patient should be well enough to leave his bed in eight days, just as after other operations on the thyroid.

60. Excision of the Thyroid when Resection of the Sternum and Ribs is necessary. Whenever an intrathoracic goitre attains dimensions so large that it can no longer be completely exposed from above and its size reduced, one must abandon the attempt to excise it from the neck. If the patient is so distressed that he would take any risk rather than continue in suffering, one must decide on a resection of the sternum and ribs in order to alleviate the danger of the condition.

This operation, in which both pleural cavities may be opened, must not be undertaken without steps being taken to prevent collapse of the lungs, *i.e.* by the use of a low or high-pressure chamber. Owing to the difficult conditions attending the operation and the enormous venous distension that exists, both pleuræ may be incised or torn even in resecting the sternum, especially as one is forced to proceed hurriedly owing to the bleeding that may occur and which is very difficult to arrest, from the large branches of the internal mammary vein perforating the inner ends of the intercostal spaces.

One must therefore attempt to gain access to the thoracic cavity on one side by resecting the second and if necessary the third and fourth ribs as far out as a distance of 10 to 15 cm. (4 to 6 inches) from the edge of the sternum. If the lung is displaced and both layers of the pleura are in contact, the latter are shut off by a circular row of sutures before being opened.

The veins on the exposed capsule of the goitre are then tied, care being taken to avoid the innominate veins which are displaced outwards, and which descend alongside of the tumour, after which the tumour is exposed, and if necessary incised. It is then thoroughly broken up and drawn upwards into the neck.

Before an intrathoracic tumour is broken up, it must always be thoroughly exposed in the neck, and subsequently drawn up through the inlet of the thorax.

The hæmorrhage is not excessive during this process, and a tumour as large as a man's head may easily be shelled out of its capsule, because the thin pedicle is so compressed that the vascularity of the tumour is diminished.

61. Operation for Recurrence of the Goitre (Struma Recidiva). In the operation for recurrent tumours we have a special problem to deal with. If a goitre has been excised on one side by our normal process, it rarely happens in nodular goitres that the other lobe of the thyroid develops to such an extent as to cause trouble.[1] It occurs most commonly in diffuse follicular colloid tumours. The reasons are obvious why recurrence should occur more frequently after enucleation than after excision.[2] But if the advancing disease in the half of the thyroid which has been left behind once gives rise to dyspnœa, one must be prepared for difficulties in the operation. We have to deal, on the one hand, with growths of very large size, and, on the other hand, with those which, as a result of the previous operation, are very adherent and may extend deeply. Such growths, especially if they are very closely applied to the trachea, give rise to trouble in spite of the possibility of the displacement of the cervical viscera towards the operated side, because one cannot again perform a simple excision. It is not easy, therefore, to find an appropriate method of dealing with such diffuse colloid goitres.

We recommend the following procedure:—The tumour is thoroughly freed in the

[1] A. Kocher has considered this matter in connection with our cases.

[2] Brunner has shown that of 18 per cent of recurrences after thyroid operations the majority follow enucleation.

neighbourhood of the isthmus and of the lower pole, where the pressure is greatest, and after ligaturing the inferior thyroid artery, is dislocated in the usual manner. The arteries and veins proceeding to the upper pole need not be ligatured. A piece of the thyroid gland is left *in situ* connected with them, and, after crushing its connection with the rest of the gland, with our goitre crushing-forceps, the crushed part may be ligatured, and the remainder of the tumour excised.

If the upper pole is entirely diseased, and if the dislocation cannot be effected without ligature of the superior thyroid vessels, they should first be tied. The goitre is then dislocated and the large thyroidea ima veins ligatured at the lower pole, after which the tumour is raised (as far as possible without hæmorrhage) from the trachea and turned outwards. Without ligaturing the inferior thyroid artery, the vessels which are seen running upwards deeply in the neighbourhood of the trachea to the surface of the tumour are caught with forceps, and the goitre tissue is incised vertically close to the isthmus. In this way a posterior capsule is formed from which the colloid matter is to be removed by blunt dissection as completely as possible and the vessels tied. The dissection is to be continued laterally beneath the capsule until a flat mass of goitre tissue is separated from the posterior part of the thyroid sufficient to maintain the thyroid function. The portion thus separated is then completely severed from the part to be removed and the vessels tied.

Excision of a residual goitre is also rendered more difficult on account of the cicatrices of the previous operation. These cicatrices, which are situated on the surface of the tumour, cause adhesion to the surrounding parts, including the muscles and the capsule, so that the goitre can only be rendered movable by working from the lateral or mesial aspect under the muscles, and dividing the latter transversely where they are adherent, thus leaving the entire cicatrix attached to the goitre. No time should be wasted in separating cicatrical adhesions from its anterior surface, but the deep surface of the growth must be exposed as soon as possible where there are no adhesions.

62. Excision of Exophthalmic Goitre (Basedow's Goitre). To the present time we have operated on 200 cases of Basedow's disease (including 10 cases of struma vasculosa and 60 of a mild type) with a mortality of 4·5 per cent, this mortality being higher than in other forms of goitre. We have, however, learned how to overcome the operative risks, which are almost entirely dependent on the condition of the heart, *i.e.* toxic myocarditis.

Excision should not be undertaken when the disease is advanced, *i.e.* when the pulse, besides being rapid, is also small and irregular, or when the heart is dilated and œdema is present. If there is severe thyro-intoxication, the slightest excitement causing acceleration of the heart's action (180 beats or more per minute) with an increase in the dilatation, it is advisable to begin by ligaturing one, or possibly two, arteries, and to postpone the excision till the patient's condition shows distinct improvement.

Even then the operation is attended with considerable responsibility and requires the utmost caution. The large vessels are very readily torn, and the goitre is exceedingly vascular, even the external capsule bleeding freely, while it is often firmly adherent. Operation is thus a matter of greater difficulty, and attended with greater hæmorrhage than is the case even in malignant goitres. The result, therefore, really depends for success on the most careful arrest of hæmorrhage.

All antiseptics and anæsthetics are a source of danger owing to the toxic conditions present in these cases. The success of operative treatment in Basedow's disease depends on the patient's being seen by the surgeon at an early stage, as with early operation brilliant results can be obtained.

The angled incision is, as a rule, preferable and every vessel must be ligatured, without, however, losing time in extirpating the goitre. The separation of the outer capsule is often attended by so much bleeding that one has to dislocate the goitre rapidly and secure the main vessels. No practitioner, unless he has had considerable experience in goitre operations, should venture on an excision for Basedow's disease.

63. Ligature of the Thyroid Arteries. Ligature of the thyroid arteries is best

considered here as it is most frequently indicated in vascular goitres, and in Basedow's disease. According to Volker,[1] it was originally suggested by Muys for the treatment of ordinary goitre, while Blizzard attempted it first without success. The first successful case was performed by Walther in 1817. Porta extended the operation to the ligature of all four arteries in 1850, a suggestion which has recently been adopted by Wölfler.

Ligature of the thyroid arteries has never come into general use for ordinary goitre, for the reason that if one goes so far as to tie the main arteries, one may just as well make sure of a permanent result by removing the tumour, especially as both are effected through the same incision. Further, when the goitre is a large one, the operation is not only difficult but often unreliable.

In simple goitres, therefore, ligature is only to be considered when the vessels are greatly enlarged, and then it is sufficient to tie only the superior thyroid arteries, this procedure frequently making the subsequent removal of the goitre much less dangerous.

We regularly perform preliminary ligature of the arteries in Basedow's disease tying them in sequence in the course of eight to fourteen days. The anæmia and partial arrest of function causes in many cases such a marked improvement that excision may be subsequently undertaken.

Even without excising the gland, we can get very good results in Basedow's disease by simple ligature of three arteries. We do not consider it permissible to tie all four arteries as has been done by Wölfler and also, according to Enochin[2] by Rydygier and Rasumowsky, as the patient is then exposed to the risks of tetany and "cachexia strumipriva" from acute and chronic changes in the thyroid and parathyroids. Even should no acute necrosis of the thyroid occur (as is proved by Wölfler) the patient is exposed to the dangers consequent on the gland secretion being arrested. We ventured on one occasion to tie all four arteries with the result that severe tetany followed.

On the other hand, we may combine excision on one side with ligature of one artery on the other side, a method which we have often employed.

The technique of ligature of the thyroid arteries has been described in the section on the surgery of the vascular system (see pp. 97 and 103). The superior thyroid artery is much more easily tied than the inferior thyroid, and ligature of the former is always preferable when there is a choice. Ligature of the inferior thyroid artery may be attended with so much difficulty, *e.g.* in Basedow's disease, that one must abandon the attempt and proceed to excision. When the capsule is adherent the artery is difficult to find and the bleeding is profuse.

Unilateral ligature is best carried out through the collar incision over the middle of the thyroid (in thyroidectomy), the gland being first of all dislocated. After the vessel has been tied, the thyroid is replaced and the wound closed, no drainage being required as no cavity is left.

64. Excision of Inflamed Goitres. It is specially in large hæmorrhagic soft colloid goitres, which have become chronically inflamed and the external capsule of which is thickened and adherent, that most trouble is experienced by surgeons who have had little experience of goitre operations. Repeated hæmorrhages are probably sufficient to produce this chronic indurative type of inflammation, the character of which may cause one to suspect that the tumour is malignant, *i.e.* the capsule is thickened, and firmly adherent to the overlying muscles, while the latter are often indurated as well.

The thickening and adhesions may interfere greatly with the freeing of the goitre, especially if the great vessels of the neck are adherent. The internal jugular vein is often found to be flattened and closely connected with the coverings of the tumour, while the same is true of the superior thyroid, the thyroideæ imæ, and the accessory veins.

Unless one is very careful, bleeding of a most troublesome nature may occur if the veins are injured, because owing to the density and hardness of the adhesions it

[1] v. Volker (in v. Bramann's Dissertation), Halle, 1904.
[2] Enochin, *Arch. f. klin. Chir.* Bd. 80.

is often difficult to control it with certainty or even impossible to control it at all, by simple ligature. The prolonged administration of iodine, either internally or locally, gives rise also to a chronic inflammatory condition of the thyroid and perithyroid tissues, which very often makes the dislocation of the tumour exceedingly difficult owing to the density of the adhesions. Large and apparently movable goitrous nodules met with in old people often show similar periglandular changes.

In all these cases no attempt should be made to force a way between the outer capsule and the tumour from the front, as the adhesions are often far too firm. On the other hand, the proper interval can frequently be found much more easily from behind, *e.g.* once the superior thyroid vessels have been isolated and ligatured, by exposing the posterior surface of the tumour from above.

It is not practicable to excise the capsule along with the goitre, because of the intimate connection of the large vessels. Not infrequently its anterior wall must be left on the tumour along with the covering muscles, *i.e.* it must be cut round, although occasionally it may be separated by forcible blunt dissection.

When it is impossible to separate the capsule even posteriorly, enucleation or "exenteration" of the nodules must be resorted to. This may often be found surprisingly easy, while the bleeding may be inconsiderable, as the vessels are in many instances partially obliterated by the inflammatory process. Abscesses and inflamed cysts are generally best dealt with by simple incision.

Any existing fistulæ should be cauterised with the thermo-cautery and closely stitched, after which the adherent soft tissues on the anterior surface of the goitre should be cut round in the manner already described.

65. Excision of Malignant Tumours of the Thyroid. It is difficult to tabulate definite rules for the excision of malignant goitres. When the cancerous or sarcomatous nodules are still circumscribed and limited to the tissue of the thyroid gland, the operation does not really differ from that required in the case of colloid goitres. On the other hand, certain forms of scirrhus cancer are less vascular than colloid goitres and even less so than struma vasculosa. Sarcomata, however, may be very vascular, soft, and even pulsating.

When the disease is extensive and has invaded the greater part of the thyroid gland, the same rules hold good as for adherent goitres (previous chapter). No attempt should be made to separate the outer capsule, muscles, or adherent tissues from the goitre mass. These must be cut round and left in contact with the goitre, *i.e.* excised along with the tumour, the line of division being through healthy tissues.

In regard to the skin incision, the one that gives the best access must always be selected, *i.e.* the angled incision. For this the skin must be freely divided. It is very important to tie every vessel at an early stage, and if possible at a distance from the gland so that all the adherent tissues as well as the adjacent glands can be removed in one mass. Not only is the perithyroideum adherent to the muscles, but often to the great vessels of the neck as well, especially the veins; while smaller veins may be full of cancerous thrombi, and even the trachea and œsophagus may be so involved that it may be necessary for a portion of them to be excised. In the case of the œsophagus the smooth and movable mucosa can occasionally be left intact, a method which has the great advantage of protecting the wound from contamination with mucus from the pharynx.

The infected lymph glands are situated beneath and behind the sterno-mastoid in both its upper and lower parts. When a malignant new growth extends into the thoracic inlet as an intrathoracic malignant goitre, no attempt must be made to remove it if it is fixed at its lower end.

66. Transplantation of the Thyroid Gland. Transplantation of the thyroid gland in individuals with deficient thyroid secretion gives permanent results in comparatively few cases. Schiff performed the first intraperitoneal operation, while we originally transplanted thyroid gland-tissue in man under the skin of the neck in the autumn of 1883, since which date Bircher and Horsley have made a special study of the subject.

One of the most interesting transplantations of recent times, which has been

verified by numerous experiments, is Payr's transplantation into the spleen. We have selected numerous sites, *e.g.* the subcutaneous tissues, both surfaces of the peritoneum, and also the capsule of the thyroid and large veins and arteries. The subserous layer of the peritoneum and the spleen seem to be the best sites in which the transplanted piece of thyroid gland-tissue will grow and act as a substitute for the absent function. Recently we have followed up the suggestion made by Albert Kocher, and have transplanted thyroid tissue into the medullary cavity of the tibia.

(e) Surgery of the Thymus

67. Excision of the Thymus Gland. Excision of the thymus may be suitably considered here, as the operative procedure is very similar to that in intrathoracic goitre. Very few surgeons have had any experience in the surgery of the thymus. Rehn of Frankfurt, who is the most competent authority, delivered an address on the subject at the Surgical Congress in Berlin in 1906, referring to 28 post mortem findings and to 5 cases on which he had operated, in all of which there was undoubted pressure on the trachea.

The thymus is placed between the sternum and the trachea above, and between the sternum and great vessels or pericardium lower down. Above, it is bounded laterally by the great vessels; the phrenic nerves are in contact with its capsule, and on the left side also the vagus and recurrent laryngeal nerve as well.

The amount of pressure exerted depends not so much on the actual size as on the consistence and the antero-posterior thickness of the gland. According to Kocher, sudden attacks of dyspnœa may be produced on forcible flexion of the vertebræ, and specially by sudden swelling of the thymus of a congestive or infective nature.

It is thus seen that the conditions resulting from enlargement of the thymus are very similar to those of an intrathoracic goitre, the former occurring not infrequently in small children. The stenosis produced by enlargement of the thymus gland gives rise to dyspnœa with inspiratory stridor, sinking of the episternal fossa, with cyanosis, which may either increase gradually or take the form of transient attacks. During expiration, or more especially coughing, a swelling may project into the lower part of the neck.

The first successful thymectomy was performed in 1896 by Rehn, while the operative results were equally good in König's two cases, and in the cases reported by Ehrhardt and Purruker. The dyspnœa disappears, thus proving that in thymic asthma and in thymus-death, a mechanical interference is present. Every case must therefore be carefully considered in regard to the advisability of operative interference, especially as the operation is a simple one, and is not attended with the difficulties of an intrathoracic goitre in which the vascularity is incomparably greater.

The operation has hitherto been performed through a longitudinal incision (without a general anæsthetic). The question may be asked whether our low collar incision is not preferable as it provides more room and causes no more injury. After division of the skin (platysma) and fascia, the gland is found enclosed in a capsule which is fairly closely connected with the great vessels and pericardium.

Intracapsular removal must always be adopted, the capsule being simply pulled forwards or held up with stitches. In his first case Rehn only fixed the gland forward with stitches, while others have resected it. Ehrhardt shelled it out completely with comparative ease. The bleeding is insignificant.

Ehrhardt[1] has shown by means of experiments on animals that the gland can be quite well done without, as our experience in the case of goitre would lead us to expect. The flattening of the trachea soon recovers: if not, Kocher's dilatation suture might be employed.

[1] *Arch. f. klin. Chir.* Bd. 78.

Treatment of Intrathoracic Dermoids

The treatment of intrathoracic or mediastinal dermoids is closely allied to that of intrathoracic goitre. Surgical interference is not to be considered when a tumour is adherent in the mediastinum. Diagnosis in the early stages still leaves much to be desired, while treatment is adopted too late and the favourable time for operation is allowed to elapse. This applies, as we have seen, in the case of intrathoracic goitre as well. We have shown in a series of cases how relatively enormous intrathoracic thyroid tumours may still be successfully removed provided they are movable,—a point which can be determined clinically by means of radiography.

Dermoids and teratomata are exceptions to the rule not to attempt the removal of an adherent tumour in the mediastinum. They exhibit a pronounced tendency to contract adhesions, and may even perforate into neighbouring structures.[1] They yield very well to treatment by drainage, and in one case, where there was a tumour in the thorax, as large as a man's head, we obtained a very satisfactory result by the unusual course of opening it in the episternal fossa (jugulum). As a rule, however, it is generally necessary to undertake a resection of ribs, in order to be able to carry out drainage.[2] We shall publish our case in detail elsewhere.

C. SURGERY OF THE THORAX [3]

(a) Surgery of the Thoracic Wall

68. Amputation of the Mamma. The removal of the mamma alone is a very simple operation, and may be effected by means of a curved incision with the concavity upwards along the lower border of the gland, and fully 1 cm. below it, the gland being shelled out subcutaneously by separating it from the fascia covering the pectoralis major up to its upper border, and then dissecting it off from the skin. We have often performed the operation in this way in diffuse adenoma and multilocular adeno-cystoma (*maladie cystique*). In lipoma, circumscribed adenoma, and fibroma situated in the deeper part of the mamma, the latter may be thrown upwards, and the tumour shelled out from its under surface without removing any of the healthy gland along with it. The minimum of disfigurement is obtained, as the cicatrix is hidden in the submammary fold. When the tumour is situated superficially a simple radial incision is preferable, the skin, superficial fascia, and a thin layer of gland tissue being divided and the tumour shelled out.

69. Operation for Cancer of the Breast. Descriptions of the operation of excision of the mamma, as well as post-operative statistics, afford conclusive proof that success in the treatment of cancer of the breast depends on the removal of all the diseased lymph vessels and glands. One cannot be too thorough in the removal of the disease itself and of the lymphatic territories which it affects. The brilliant works of Halsted, Rotter, and others show the excellent results that are obtained by a radical operation.

At the same time we must not lose sight of the fact that the improvement in the results of mammary cancer refers only to the prevention of local recurrence, and that a number of these "cures" still succumb to metastases. Grossmann estimates recurrence after the lapse of three years as still about 10 per cent.

[1] A collection of 35 cases by Shaw and Williams, *Lancet*, Nov. 1905 ; *vide* also Morris, *Med. News*, Sept. 1905, with 57 cases collected from literature.

[2] *Vide* Morris, *Med. News*, Sept. 1905.

[3] The latest important works on the subject which should be read are : (1) Bryant, *Transact. of the Amer. Surg. Assoc.*, vol. 13 ; (2) Garrè and Quincke, *Grundriss der Lungenchirurgie*, 1903 ; (3) "Voies et moyens d'accès dans le thorax," Congrès de Chirurgie, Paris, 1906, von Willems et Loisin ; (4) Gerulanos, *Deutsche Zeitschr. f. Chir.* Bd. 49 ; (5) Gross, *Beitr. z. klin. Chir.* Bd. 24 ; (6) Amburger, *Beitr. z. klin. Chir.* Bd. 30.

Meanwhile, as is the case in carcinoma of the tongue and larynx, the most satisfactory results are obtained by surgeons who are in the habit of operating early. Of 91 of our cases collected by Dr. Meyer, the subjects of which died within a period of twenty years after operation, local recurrence happened in only 25·2 per cent, the others dying of metastatic growths, while of 8 cases dealt with at an early stage, in which only an incomplete operation was performed, two showed recurrence within three years, and six (75 per cent) appear to be permanently cured.[1]

As with cancer of other organs, it is the time at which the operation is carried out rather than the actual method employed that chiefly influences the ultimate prognosis in carcinoma of the breast. While this is the case, we still maintain that when operation is undertaken, in most instances it should be radical in the modern

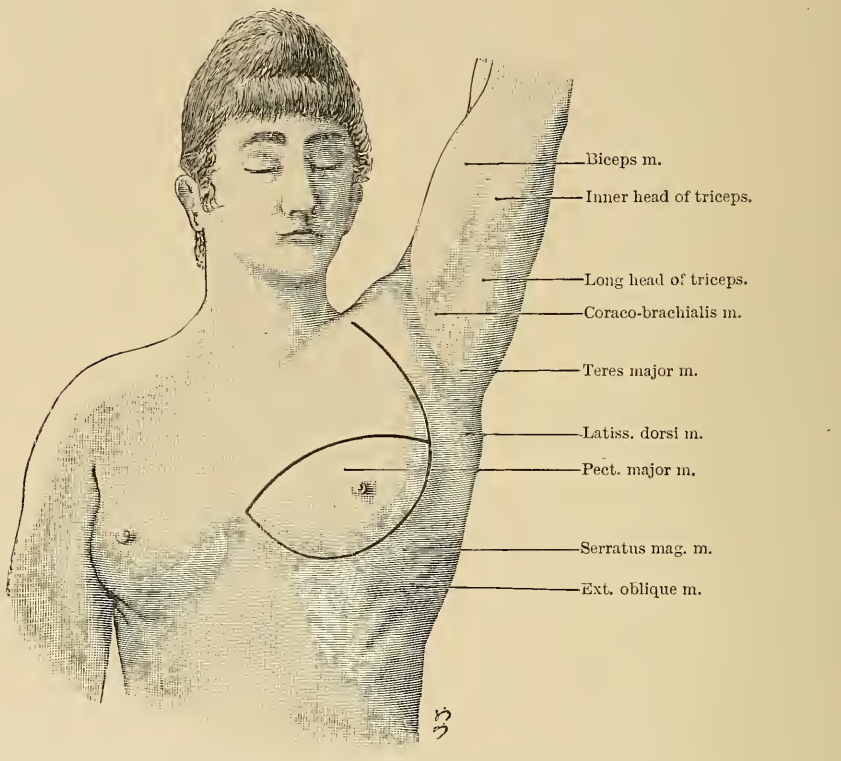

FIG. 298.—Skin incision for removal of a carcinomatous breast.

sense of the term. On the other hand, we are acquainted with individual cases of women, still enjoying the best of health, who could only be persuaded to submit to early operation on condition that we did not remove the whole breast but only excised the diseased portion.

70. Radical Operation for Cancer of the Breast (Figs. 298-302). As a rule (and the surgeon should invariably advise this), we must not be content with simply excising the gland itself, but we must simultaneously remove all those parts where cancer cells have wandered secondarily, and which are often only discovered at the operation. There are four recent researches which have very thoroughly shown in what directions cancer of the breast tends especially to spread, and which have

[1] Crile reports 80 per cent of cures in favourable cases where the mamma alone was dealt with (cf. also Schröder (Rostock), *Beitr. z. klin. Chir.*).

demonstrated the course of the local recurrences, formerly so frequent. The first paper is by L. Heidenhain,[1] the second by Harold J. Stiles,[2] the third by Grossmann,[3] and the fourth by Rotter. On the basis of a very large number of anatomical researches these authors have shown (as formerly did Gussenbauer, Waldeyer, and Langhans) that lymphatics full of cancer cells can frequently be demonstrated in the gland tissue of a carcinomatous breast, both in the immediate neighbourhood of, and also far removed from, the primary focus. The authors are all unanimous in stating that the chief direction in which the cancerous infiltration spreads is along the retro-mammary lymphatics. Moreover, cancerous emboli are to be found in the suspensory ligaments (ligaments of Cooper), in the corium, in the peri-mammary fat, as well as in the connective tissue-septa between the lobules. The efferent lymphatics open into lymphatics lying in the fascia covering the pectoral muscles. The latter drain partly into the superficial and deep pectoral glands which are situated along the free border of the pectoralis major and on its deep surface, and thence accompany the blood-vessels on their way to join the axillary glands. Only the lymphatics from the inner part of the breast follow the branches of the internal mammary to the sternal glands.

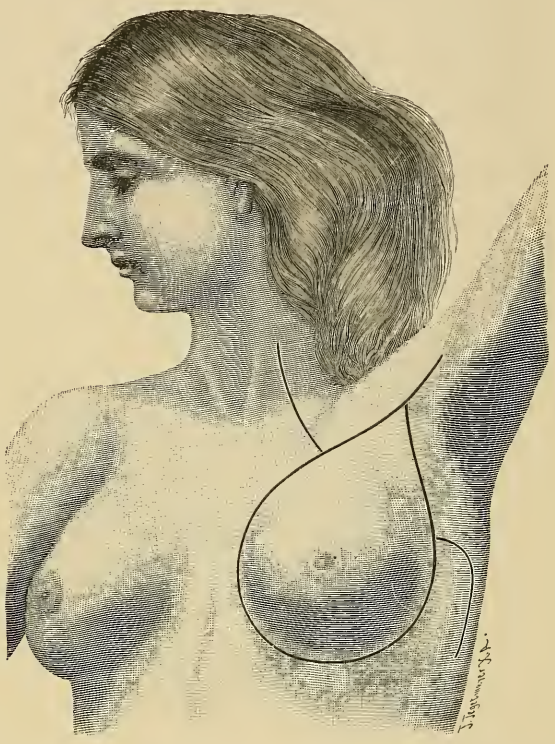

FIG. 299.—To illustrate the incision employed by Collins Warren, in the radical operation for cancer of the breast. It closely resembles that used by Willy Meyer, and the flaps are so cut that the operation is really plastic.

The excellent work and statistics of Halsted, Rotter,[4] and Joerss[5] have clearly demonstrated that the modern operation for cancer of the breast has given very much better results by keeping in mind this wide regional dissemination of the cancer cells. In the twenty years previous to 1896 we have obtained relatively good results in the 212 cases which Dr. Meyer has tabulated, 31 per cent of the cases being free from recurrence after a period of at least three years. But lately still better results have been obtained as regards both local recurrence and permanent cure.

Joerss, from a table of the results obtained by Halsted, Rotter, Cheyne, and Helferich, reckons that 42 per cent of the cases are free from recurrence after three years. Lennander has published the statistics of 74 cases operated on by Dahlgren (1887-1897); he found that 53 per cent of the cases were free from recurrence after more than three years. M'Williams, however, denies that the result of the modern "heroic" operations are better than formerly. In 100 cases, of which 66 could be traced, he only found 17 survivors (25 per cent).

[1] Langenbeck's *Archiv*, Bd. 39.
[2] *Edinburgh Medical Journal*, 1892.
[3] *Gekrönte Preisschrift*, Berlin, 1896.
[4] *Berliner klinische Wochenschrift*, 1896.
[5] *Deutsche Zeitschrift für Chirurgie*, Bd. xliv.

FIG. 300.—Position of the patient. The order in which the incisions are made is indicated by the different thickness of the lines.

Formerly it was the practice to excise the breast alone, and when glandular recurrence became manifest, the glands were dissected out singly by an incision in the axilla. Removal of the pectoral fascia was then practised by Volkmann, following which, superficial layers of the pectoral muscle were excised by Heidenhain. A portion of the pectoral muscle was next removed by Rotter, and subsequently a more extensive clearance of the axilla was adopted by Willy Meyer. The climax has now been reached in Halsted's operation, which consists in the complete removal of all the perimammary

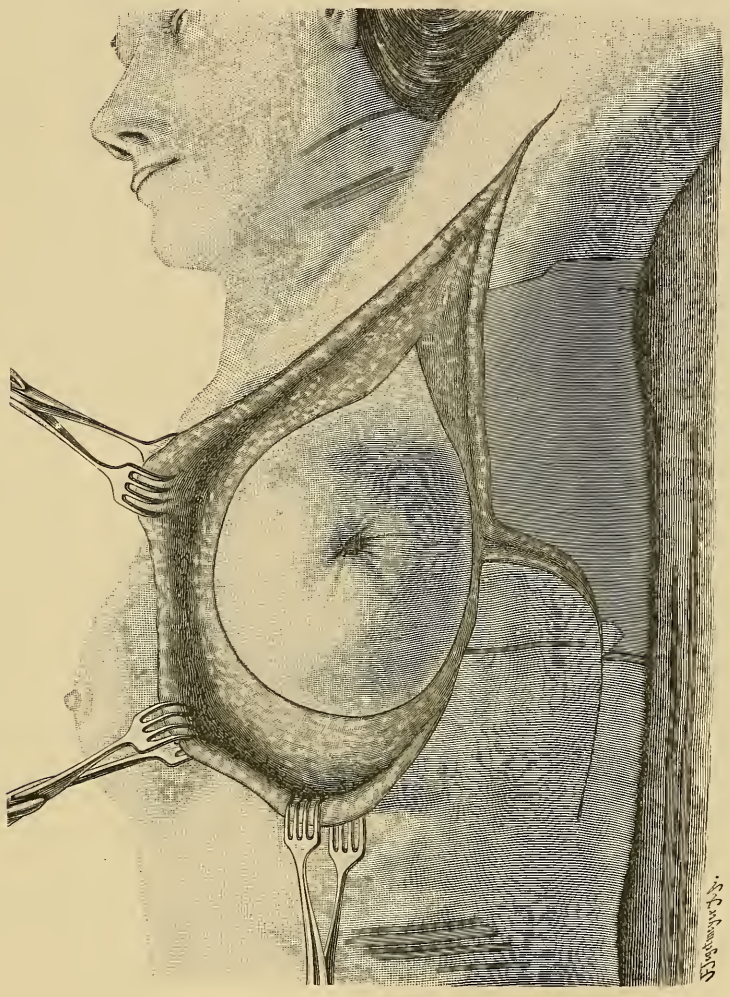

Fig. 301.

fat, clearance of the axilla and axillary fat, division and removal of the pectoral muscles from the arm, scapula and clavicle, and finally the sawing through of the clavicle and clearing out of the supraclavicular fossa. It is this very extensive operation which, according to reported cases, permits of a guarantee against local recurrence. Owing to asepsis and sure methods of arrest of hæmorrhage its risk is quite trivial.

The first part of the incision, which divides skin and fascia, begins above on the clavicle (*vide* Fig. 300) at a point slightly internal to the groove between the deltoid

and pectoralis major, and is carried downwards over the edge of the pectoralis major, across the axilla as far as its posterior fold. A superficial gland lying on the clavicle may often be found infected.

A dissector, or finger, is now passed underneath the exposed pectoralis major muscle, about two fingers'-breadth from its insertion, and the muscle is divided, while two or three vessels may have to be secured. The latissimus dorsi and teres major muscles, forming the posterior fold of the axilla, are exposed as far as the origin of the former muscle from the thoracic wall. The fascia covering the teres major, together with the fat, connective-tissue and pectoral glands, is stripped upwards by means of gauze dissection, and the subscapular nerves lying in the furrow between the latissimus dorsi and the subscapularis, as well as the posterior thoracic nerve, are exposed.

The axillary fat and the whole bunch of glands, together with the fascia covering the anterior surface of the subscapularis and serratus magnus, are reflected upwards as far as the axillary vein. The pectoralis major and its fascia are then turned down and a search is made for glands lying between it and the pectoralis minor, the pectoralis minor being then freed with the finger at the coracoid process and cut across, thus exposing the great vessels as far up as the clavicle. This division of the pectoralis minor and exposure of the axillary vessels put the pectoral branches of the axillary vessels on the stretch, and when these are secured and divided, access is obtained to the glands lying immediately below the clavicle, which must be dissected off the axillary vessels with special care.

When a gland is firmly adherent to the wall of the axillary vein, the vein must be ligatured above and below and the portion resected. If the glands behind the clavicle cannot be satisfactorily removed from below, the method employed by Halsted and Madelung should be adopted, the clavicle being sawn across obliquely from above downwards and outwards and the two halves pulled apart. For this, our incision is prolonged upwards and the superficial and deep cervical glands[1] occupying the supraclavicular fossa, are dissected out, including the gland which lies in the angle between the subclavian and jugular veins (glandula angularis). In excising this gland the thoracic duct is liable to be injured.[2]

The clavicle need not be divided if the infraclavicular glands can be satisfactorily removed from below. If there is no involvement of the infraclavicular glands, or of the glands in the costo-coracoid membrane, there is no necessity to clear the supraclavicular fossa. Certain surgeons (*e.g.* Halsted, Cushing) clear the supraclavicular fossa on principle.

Following the same principle as we have adopted in our method of complete extirpation of the tongue, we find it is only when the glands have been cleared out in one mass, and the majority of vessels supplying the primary focus have been tied, that the surgeon should proceed to the amputation of the mamma itself, together with its fat, the pectoral muscles and skin.[3] The incision is now prolonged downwards below the mamma to the sternum. The fascia and fat are stripped off the latissimus dorsi and serratus magnus, and the costal origins of the pectoralis minor are exposed. These are detached, and the perforating branches of the intercostal vessels are secured with forceps.

Passing over the ribs towards the middle line under the pectoralis major, we reach the thick sternal origin of the latter muscle and the origin of the rectus abdominis. The pectoral muscle is divided at its origin, and along with the breast is separated from the ribs and intercostal muscles. Some perforating branches of the intercostal artery are cut.

The incision is now made through the skin above the breast, and a skin flap is dissected from the subcutaneous fat as high up as the clavicle, when the clavicular

[1] Schwarz from Von Hacker's clinic has published a large body of statistics. In this excellent compilation he only records four permanent cures out of thirty-three such operations with removal of supraclavicular glands, in spite of the very radical procedure introduced by Rotter, Halsted and Kocher.

[2] Cushing has on two occasions had experience of this accident, and once was able to repair the duct by suture.

[3] Handley (*Lancet*, 1905) lays special stress on carrying the incision through the fascia two fingers'-breadth below the ensiform process in order to obviate "epigastric infection."

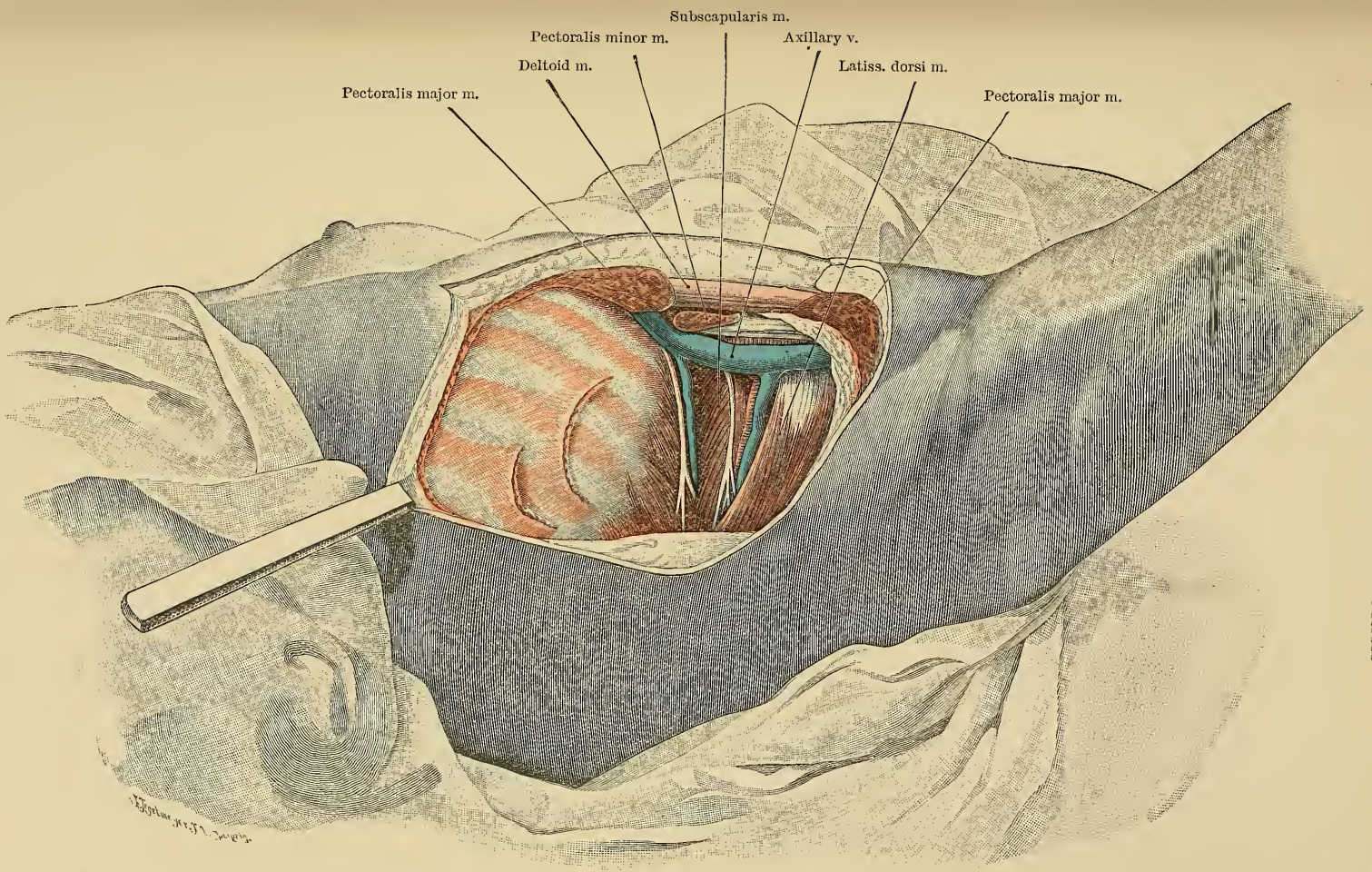

FIG. 302.—Radical operation for cancer of the breast. The mamma has been removed and the contents of the axilla have been cleared out. The axillary vein (above which is seen the axillary artery and the cords of the brachial plexus) has been cleared up to the clavicle, while, in addition, the subscapular vessels, the long thoracic vessels, and the corresponding nerves are exposed. The figure further shows the divided pectoral muscles, the ribs, and the serratus magnus, subscapularis, latissimus dorsi and teres major muscles.

origin of the pectoralis major is divided close to the clavicle and the upper costal origins of the muscle cut through.

Most of the artery forceps can be removed after twisting the vessels. Ligatures are only applied to the arteries and veins close to the main vessels, and also to the perforating branches of the intercostal vessels.

In this operation the axillary glands, the pectoral fascia, and both pectoral muscles, as well as the mamma and skin covering it, are removed in one piece. We attach special importance to the direction of our incision, because it at once exposes the muscles, which form the boundaries of the axilla, and enables one to strip the fascia, as if it were an envelope containing the contents of the axilla, in one mass from the anterior aspect of the scapula (subscapularis muscle) and the outer aspect of the thorax (serratus magnus and intercostals). It further preserves the subscapular and posterior thoracic nerves, and enables us to divide the vessels which go to supply the breast.

The wound is closed by bringing together the flap so that the axilla at any rate is completely covered. A single drainage tube is inserted at the posterior axillary fold, and should pass up between the scapula and the chest wall as far as the clavicle. The part of the wound which cannot be closed can be at once grafted by Thiersch's method.

The functional disturbances which follow such an extensive operation and removal of muscles are not so severe as one would expect, because the anterior fibres of the deltoid are able to pull the arm forwards, and the latissimus dorsi to abduct it. The movement of the arm is freer than after partial removal of the muscles. To diminish the consequent disfigurement, Collins Warren only cuts through and subsequently reunites the pectoralis minor instead of excising it, as its removal is not so essential as that of the pectoralis major. The complete removal of glands is a more important matter, and the obstruction to the flow of lymph, especially if the main vein has been ligatured, is a more serious complication. In this case a solid œdema develops, with elephantiasis of the arm, which may last for months or years, and which interferes much more with the function of the arm than does removal of the muscles.

(b) Advances in the Surgery of the Thoracic Organs

The surgery of the thoracic organs has undergone so complete a revolution since the last (4th) edition was prepared that the chapter dealing with it has had to be entirely rewritten. Hitherto operations on the chest have been practically confined to the excision of ribs and the evacuation of fluid, especially of pus, in the thoracic cavity (not so long ago abdominal surgery was similarly restricted); but surgeons have now learnt to a certain point how to overcome the risks, which have till now nullified the advantages of aseptic wound-treatment that are so well displayed in the surgery of the abdomen.

The essential feature of advance in late years consists in overcoming the danger of pneumothorax, a complication which hitherto has barred the progress of intra-thoracic surgery. A result due, however, to the enterprise of Mikulicz and Sauerbruch, and the energy of Braun and Petersen of Heidelberg, surgeons have come to appreciate the value of simple well-known measures which, when employed even without special apparatus (air chambers), can in skilled hands achieve a satisfactory measure of success.

It would almost seem that surgeons have been carried away by this sense of security and have been careless in carrying out the great principle of asepsis, as, according to recent statistics, the majority of deaths after operations on the lungs, heart, and other thoracic viscera, are attributable to infection and not to accidents during the operation.

The following operations may be distinguished—thoraco-parietotomy, thoraco-pleurotomy, thoraco-pneumotomy, thoraco-pericardiotomy, thoraco-cardiotomy, and thoraco-mediastinotomy, or briefly, thoracotomy, pleurotomy, pneumotomy, pericardiotomy, cardiotomy, and mediastinotomy, the latter including three varieties, viz. anterior, posterior and thoracic œsophagotomy.

Besides the above operations, which are undertaken either for the removal of disease in the chest-wall or to give access to intrathoracic organs, there is another category of operations in which thoracotomy is performed in order to reach, through the pleura—or as has even been suggested through the pericardium—other organs (œsophagus), and especially some abdominal viscera. These may be briefly grouped as transpleural[1] (transpericardial). At present they are principally employed for opening subphrenic abscesses or collections of fluid in the liver, and also for getting access to the stomach (*e.g.* in œsophago-gastrostomy). The œsophagus can also be approached directly through the mediastinum by the transpleural route, Jaboulay even advocating the transpericardial route.

The surgery of the thoracic wall has changed least of all, but before considering it, we find it advisable to deal with the question of the prevention and treatment of traumatic pneumothorax, as, especially in the case of new growths of the chest-wall, the surgeon must be prepared for wounding the pleura, and be ready to cope with the danger of acute pneumothorax. Otherwise, he will be hampered in the correct performance of the operation by anxiety, and will desist from a radical operation which would obviate a fatal result.

(c) Prevention and Treatment of Traumatic Pneumothorax

From experimental and clinical evidence it is well known that acute pneumothorax is a serious menace to life. No operation on the thoracic viscera, necessitating an extensive opening up of the chest-wall, can be undertaken without incurring risk. In regard to the pericardium, however, it is different. Gerulanos has shown that there is more danger in opening the right pleural cavity than the left, on account of the greater size of the right lung and its close relation with the great venous trunks and the right auricle.

The cause of the dangerous collapse that occurs in a sudden pneumothorax has been made the subject of considerable investigation. Earlier observers attributed it to displacement of the heart and great vessels; but in a series of interesting experiments, Murphy has shown that it is due to a displacement of the sagittal mesial plane of the thorax, which is caused by the sudden inrush of atmospheric air during the act of inspiration when the intrapulmonary pressure of the sound side is reduced. The mediastinum bulges into the sound half of the thorax and impedes the entrance of air into the lung on that side, while expiration is equally impeded by the mediastinum being pushed towards the side of the pneumothorax. Murphy also states that by causing traction on the mediastinum, either directly or indirectly, by pulling forward the lung, the dyspnœa and cardiac collapse are averted.

It is also a well-known clinical fact that grave symptoms result from pressure on the mediastinum; and in rapidly-increasing effusions of blood or fluid in the pleural cavity, where the displacement of the mediastinum can be demonstrated by percussion, a high degree of dyspnœa is invariably present. Considerable displacement of the heart and pressure on the great vessels may be caused by an effusion which exerts a constant pressure, but with an open pneumothorax the mediastinum swings to and fro on inspiration and expiration.

Authorities are agreed that loss of respiratory function in one lung is not sufficient to account for the dyspnœa, and Sauerbruch has proved that the respiratory volume may fall to one-tenth of the normal without serious disturbance of respiration, the same observer having also shown that the respiration of one lung may be completely shut off without producing dyspnœa, if it be previously inflated.

According to Sauerbruch's researches, the view held by Garré that the dyspnœa is the direct result of mechanical pressure on the mediastinum, which interferes with the efficiency of the sound lung, does not sufficiently explain the intensity of the respiratory disturbance; as, according to his observations, the increased rate and force of the breathing maintains the respiratory volume almost unchanged. He believes

[1] The expression "perpleural" would probably be more correct.

that the explanation lies in the fact that by the falling together of the lungs, the pressure on the thin intrapulmonary vessels is removed, and a hyperæmia results, while the normal stimulation from the vagus termination is altered, with consequent loss of tone and irregularity in breathing. The hyperæmia of the one lung produces anæmia and defective arterialization of the other, with consequent dyspnœa and rise of blood-pressure. It follows, therefore, that both pleural cavities may be opened without producing dyspnœa, provided that collapse of the lungs is at once prevented, and further, that the dyspnœa can be removed by expanding the empty lung.

Further experiments must be undertaken to determine to what extent dyspnœa is produced by displacement of the heart and great vessels, pressure on the large veins of the right heart (Gerulanos), and reflex pleural stimulation. Suffice it to say that the danger can be immediately removed by pulling on the collapsed lung and bringing it up to the thoracic wall, which has been proved by Murphy's experiments, by W. Müller, and later by Bayer, who first put it into practice intentionally. We have thus a certain and simple means of preventing the immediate danger of pneumothorax when an extensive opening in the pleural cavity has to be effected.

Delagenière and other surgeons, experienced in pulmonary operations, rely absolutely on this simple measure.

It is further gratifying to the surgeon, as well as to the patient, to know that an incomplete pneumothorax does not produce the same danger as a total pneumothorax. Garré has drawn special attention to the fact that respiration occurs again in the lung whenever the opening in the pleura is smaller than the aperture of the glottis, as in that case a certain amount of expansion takes place on inspiration, owing to the fact that the negative pressure in the pleural cavity is satisfied less rapidly than that in the lung.

Sauerbruch also showed by experiments with his air chamber that respiration can be maintained so long as even a relatively small portion of lung is in contact with the chest-wall, the intercostal muscles and diaphragm being intact.

There is a great difference between a pneumothorax that occurs rapidly and one that occurs slowly. The latter may give rise to no serious symptoms, and it seems to us that the explanation of this is to be found in the fact that the pneumothorax in the latter case is not so complete. According to Murphy's theory, on the other hand, which Garré accepts, it is maintained that the sound side has time to make up for the deficiency in inspiration by a more effective range of respiratory movement. Sauerbruch's experiments, however, prove that the absence of sudden disturbing reflexes on the part of the pleura, and the adaptation of vagus reflexes and of the heart and vessels to the new conditions, are by no means matters of indifference.

We do not attach so little importance to the simultaneous respiration in the retracted lung, as is done, for instance, by Garré, as it follows that with an open pneumothorax the respiration of the lung is obviously reversed. On expiration it is inflated by the sound lung and collapses on inspiration. This inflation with air that has been already breathed, and the respiration of the same air in the sound lung are likely to prove more harmful than beneficial. The pulmonary circulation is chiefly affected, and this, according to Sauerbruch, is the critical point. In the methods employed by Murphy, Müller and Bayer, the partial expansion of the lung is, according to Sauerbruch's theory, of more significance than simple traction on the mediastinum.

In cases where the pleura has been opened either by intention or accident, it is well to remember the great difference in danger between a complete and partial, sudden or slow-produced pneumothorax, as it is by this that the treatment is influenced.

(1) In carrying out an operation which necessitates opening the pleural cavity, the primary incision into it should be small; and, as the opening is enlarged, the rapid onset of diffuse pneumothorax is prevented by packing with warm gauze compresses (Krause). In this way the cooler air is prevented from coming in contact with a large surface of exposed pleura, and the dyspnœa from reflex stimulation is avoided.

(2) All accidental wounds of the pleura should be immediately packed with gauze

so that air may enter slowly, sudden contraction of the lung (by its own elasticity) being thus prevented.

(3) When a more extensive opening of the pleura is desired, *e.g.* in palpating the lung, after it has been examined and the nature of the lesion determined, the lung itself should be immediately seized (preferably with Kocher's artery forceps), pulled into the wound and temporarily sutured to one edge of the wound (Pneumopexy). Quénu and Longet have shown that these sutures should include the intercostal muscle (possibly even rib) as well as the parietal pleura, lung tissue, and the visceral pleura.

(4) When the nature and situation of a lesion in the lung demand an extensive opening in the pleura it is of the utmost importance that a preliminary pneumopexy should be performed, to prevent collapse of the lung while the development of pneumothorax is rendered impossible by passing deep supporting-sutures through the underlying lung, prior to incising the pleura, and by shutting off the pleural cavity from the area of lung, on which the operation is to be performed, by Roux's "continuous circular suture."

(5) A similar suture is adopted for "pleuroparietopexy,"—a preliminary to transpleural operations, a circular area of parietal pleura being sutured to the diaphragmatic layer before the pleural cavity is incised.

(6) When the situation of the lesion or tumour in the lung has not been determined, and it is necessary to insert the whole hand into the pleural cavity, this limiting suture, the use of which we owe to Delagenière, is out of the question for the purpose. In such cases we may either at once pull forward the lung and fix it to the wound as described above, or we may follow Dollinger's plan, and slowly and carefully produce an artificial pneumothorax, either at the operation or a day or two previously. The advantage of this is, that when the operation is performed, the danger of sudden circulatory and respiratory changes is compensated, while, further, it furnishes clear proof of the comparative safety of a partial pneumothorax.

The method here recommended for avoiding the danger of pneumothorax can be easily adopted by any practical surgeon, and should encourage him to take active measures in certain conditions and in cases of urgency, *e.g.* in injury to the lung with dangerous bleeding.

The favourable results obtained by Müller, Bayer, Keen, Delagenière, Garré and others, justify the adoption of such measures. We are undoubtedly indebted to the untiring efforts of Quénu and Longet, Tuffier and Hallion, Fell-O'Droyer, Brauer, and, above all, Mikulicz and Sauerbruch, that an operation which necessitates an extensive opening of the pleura has now become a comparatively safe procedure, provided the necessary apparatus is at hand.

We are at present engaged in testing the practical value of Kronecker's apparatus for artificial respiration, the simplest method of which, however, is that recommended by Quénu and Longet, Tuffier and Hallion, and Fell, the next being the "over-pressure method" of Brauer, Petersen, Engelken, and also of Quénu and Longet. Sauerbruch's method entails the most complicated apparatus. Nevertheless, Sauerbruch has supplied the most satisfactory proofs of the reliability of his procedure. We shall afterwards refer to this subject.

The method recommended by Loisin is simple in technique, but is difficult to accomplish. It consists in plugging through a bronchoscope, the bronchus on the side to be operated on by means of an indiarubber ball. When the lung is inflated, collapse is prevented, and the respiration of the other lung is not interfered with.

In all operations in which the pleura has to be extensively opened special attention must be paid to the position of the patient. The natural inclination is to lay the patient on the sound side, but this position is always to be avoided, as it impedes the movements of the sound side, and entails additional risk, when the pleura is full of fluid or when there is a pneumothorax. It is highly probable that the position the patient occupies may explain the want of agreement that exists amongst different observers as to the severity of the dyspnœa in cases where the pleura has been freely opened.

Besides the restriction of respiratory movements, the displacement of the mediastinal septum, or, on the other hand, of the heart and lung, by an accumulation of fluid, must not be forgotten. Garré has shown that the dyspnœa can be diminished by placing the patient on the affected side, which is made to project well over the edge of the table. In pleurotomy, it should be the rule to place the patient on his back, or possibly even on his abdomen.

(d) The question of Drainage of the Thoracic Cavity

It is worth while considering the circumstances in which drainage should be used after opening the thorax, either to remove collections of fluid, or after operations which admit of primary union. As the thorax is a rigid-walled cavity, it cannot be regarded in the same light as a cavity with soft walls or as an open wound. The indications, as we shall see subsequently, for draining the peritoneal cavity are of a different nature.

At the last surgical congress in Paris, Willems and Soison communicated two excellent articles (entitled, "Voies et Moyens d'accès dans le thorax") in which the question of drainage from the point of view of excluding sepsis was considered, especially by Willems.

All experimental attempts at producing artificial adhesions in the pleura have shown that adhesions do not easily form on account of the constant movements of the lung, while the lung, if it is separated from the chest-wall, has a tendency to retract as soon as a positive pressure is established in the pleural cavity by the entrance of atmospheric air.

There is no reason, therefore, for inserting a drainage tube into an open pleural cavity unless the end of the tube is immersed in the fluid to be evacuated, or care is taken by some other means to shut off the cavity to be drained.

In the case of aseptic operations air should be hermetically excluded by inserting several layers of firmly-tied sutures. More care, however, must be paid to asepsis in the case of the pleura than, for instance, the peritoneum, because in the former a localized infection is not so easily shut off by adhesions.

Before hermetically closing the wound, the lung must be brought in contact with the chest-wall, as there is no positive pressure to keep it there analogous to that produced inside the abdomen by the viscera.

When the lung cannot be fixed to the chest-wall by pneumopexy, the pneumothorax must be removed by aspiration, or Witzel's method may be adopted. The latter consists in displacing the air in the pleura with weak boracic lotion or normal saline[1] and then removing the fluid by aspiration. The method is complicated but thorough, and should be employed whenever the pleura has been contaminated during the operation, or when blood has escaped into it. In the latter case, however, it is not necessary to insist upon entirely displacing the air by Witzel's method. According to Sauerbruch, washing the pleural cavity with warm sterile salt-solution is sufficient for cleansing purposes.

On the other hand, drainage of the pleural cavity must be employed for the removal of infective fluids. Quénu and Longet, and also Delagenière and Willems, have justly emphasised this procedure, and recommend, at the same time, continuous aspiration with a suction apparatus, the latter taking either the form of a large cupping glass (Mikulicz), or an actual aspiration apparatus connected with a water pump (Perthes, Seidel). Stork employs a simple method, in which a suction flask (breast pump) is exhausted by means of a column of water flowing from one vessel into another.

Aspiration can also be combined with simultaneous plugging, as the pleural cavity can be satisfactorily closed by means of firm packing. This has been demonstrated by Krause, who found that, by packing gauze round a tube for the arrest of hæmorrhage, air was excluded from the pleura. The gauze, however, should contain a good permanent antiseptic such as xeroform, vioform, or iodoform.

[1] Bardenheuer has demonstrated the advantage of salt-solution.

Sauerbruch, who has had great experience of pulmonary injuries, has shown that no danger of pneumothorax follows the use of a small drainage tube, while there is still less risk by employment of a "cigarette-drain" (a cylinder of gauze or wick rolled in rubber tissue), as is used with great success in the abdomen in peritonitis by M'Cosh. Garré also confirms this statement.

Hoffmann's secondary drainage, which we have suggested chiefly when secondary sutures are employed, must also be mentioned. This consists in the introduction of a gauze drain wrung out of 5 per cent carbolic lotion covered with a protective antiseptic dressing. Only the superficial layers of this are changed. After a few days,

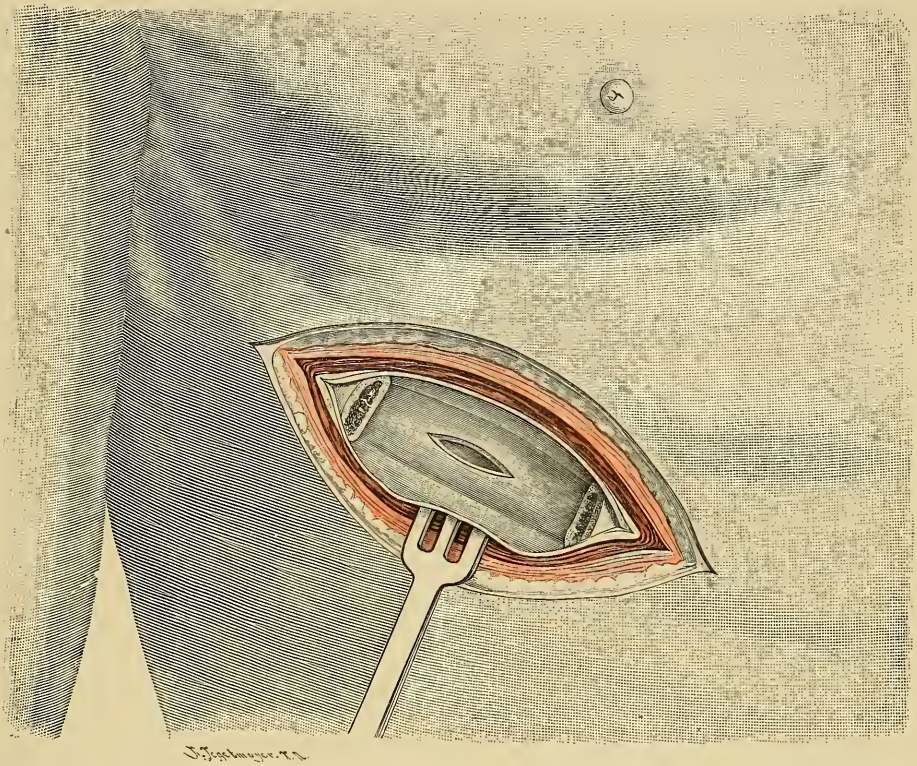

FIG. 303.—Simple resection of rib, to open the pleural cavity. 3 cm. of a rib has been removed. The periosteum covering it anteriorly has been detached, and the pleura opened through an incision in the posterior layer of periosteum.

when the lung has once more expanded, a short drainage tube is inserted, a method commended by Willems and Payr.

(e) Surgery of the Thoracic Wall

71. Resection of Ribs (Figs. 303 and 304). In a large number of cases, resection of the ribs has to be performed as a preliminary to further operative procedures, but it is also employed *per se* in the treatment of disease of the ribs. In tuberculous cases especially, excision, when performed opportunely, affords excellent results, so that we entirely disagree with the statements promulgated in text-books as to the "intractable nature" of this disease.

Other inflammatory conditions (*e.g.* typhoid, staphylococci) are of minor importance.

New growths of the ribs, chiefly primary, but occasionally secondary, are a not uncommon indication for excision, and in this connection it is necessary to be fully acquainted with the precautionary measures for opening the pleural cavity described in paragraph (*c*) of this section.

Resection of healthy ribs is frequently called for in order to restore the mobility



FIG. 304.—Resection of ribs to expose the surface of the liver. A portion of two ribs has been removed, the intercostal tissues being ligatured and excised. The costal and diaphragmatic pleura, along with the diaphragm and peritoneum have been incised, exposing the upper surface of the liver.

of the chest-wall in the case of a rigid empyema cavity, and again, to admit of full access for operations on the viscera. In the latter case an osteoplastic resection is performed. Finally, an osteoplastic transplantation of portions of the costal cartilages and ribs is occasionally indicated for the purpose of repairing parts of the larynx, trachea, clavicle, etc.

Technique.—The operation, which is a simple one if the removal of a large number of ribs is unnecessary, can be performed very satisfactorily under local anæsthesia. After anæsthetizing and dividing the skin, a 1 per cent solution of novocain with

adrenalin is injected into the muscles, and afterwards between the intercostal muscles along the upper and lower border of the rib, although Schleich uses a considerably weaker solution for more extensive operations.

An incision is carried through skin and muscle down to the bone, midway between the upper and lower borders of the rib, no large vessels or nerves being divided. The periosteum is incised and carefully separated with an elevator from the outer and inner surfaces of the rib, and the exposed portion is removed by means of a suitable pair of bone-forceps.

In children it is advisable to divide the rib first in front, as it can then be raised, and easily fractured posteriorly if an extensive portion has to be removed.

In detaching the intercostal muscles from the upper and lower borders of the rib, special care must be taken to keep close to the bone. The ends of the divided rib should be rounded off, as otherwise the vessels and nerves may be injured.

Behind the periosteum is the pleura, from which it is separated by the very thin intrathoracic fascia. These three layers are freely incised in the direction of the rib—in inflammatory cases, the presence of the exudate being previously ascertained by an exploratory puncture.

An incision in the groove from which the rib has been removed is absolutely safe and greatly facilitates the operation.

Very often resection of one rib is not sufficient. In this case a portion of the adjacent rib is removed through the same incision by drawing the skin edges well apart, the pleura being opened in the same axis as before to the resected bone. A threaded aneurysm needle is now introduced, first at the anterior and then at the posterior extremity of the lower opening, and is passed each time beneath the intervening tissues of the intercostal space and out again at the extremities of the upper pleural opening, so as to apply two ligatures to the vessels along with the pleura and muscles. The two pleural openings are now united by a vertical incision between the ligatures by excising the ligatured piece, thus making a horizontal H-shaped opening. The ligatures must be firmly applied if the bleeding from the intercostal arteries is to be thoroughly controlled. In this way the operation is performed without any hæmorrhage and is free from danger. Extensive portions of three or four ribs can be removed through the same skin incision.

72. Resection of Ribs for Tuberculosis. In the case of a tubercular rib, the disease may be completely eradicated by excision of the affected rib, provided that the abscess in connection with it is still of small extent and has a firm wall.

The soft parts and muscles are carefully separated from the thick abscess wall (under novocain anæsthesia), while the periosteum is incised in the direction of the rib and is detached along with the intercostal muscles. The rib is then divided with cutting-forceps. The periosteum on the deep surface of the rib must be separated with care on account of the close proximity of the pleura. The intercostal muscles are then detached above and below the abscess wall, and the diseased portion of rib, together with the unopened abscess, is removed like a tumour, after which the wound is sutured. A small caseous focus in the rib is often found communicating with the thick contents of the abscess.

This treatment should be regularly adopted when the disease is in an early stage, when the wound, after excision of the abscess along with the primary focus, will be healed in the course of a week. But when there is a large abscess, or when the abscess has burst and a sinus has formed, the procedure is much more complicated, because the sinuses often burrow along the intercostal spaces and give rise to peri-pleural abscesses, which render a complete removal of all the tuberculous tissues impossible. We have then to rely on thorough exposure of the disease, removal of the primary focus, as well as the carious bone, cauterization with strong alcoholic carbolic acid (10 per cent), and secondary suture after packing with iodoform gauze.

When the disease involves the costal cartilages, complete excision of the diseased cartilage, together with a piece of the sternum, is generally the only means of obtaining a cure.

73. Resection of Ribs for Tumour. The technique in excision of tumours of

the ribs differs from that of tuberculosis only as regards the extent of the operation. A long incision is made parallel to the ribs, if possible over the tumour, and the soft parts are dissected off. A flap incision with the base above and behind is, as a rule, only indicated when the tumour is adherent.

One has first to make sure of the rib with which the tumour is connected, and it will often be found that the attachment, even of a large tumour, is quite circumscribed, while most of the growth is unconnected with the ribs. The ribs that are adherent to the tumour, or that cannot be easily separated from it, are then removed as in tuberculosis, the rib or ribs being freed subperiosteally and divided in front and behind. The soft parts round the tumour are removed until a healthy rib is reached.

At this stage the essential difference between tuberculosis and new growths of the ribs becomes apparent, namely, the frequent involvement of the pleura, and one must be fully prepared for the possible dangers of a pneumothorax. If the apparatus for maintaining artificial respiration (high or low pressure) is not at hand, a preliminary pneumopexy may be performed, or the method which Keen successfully adopted in one case may be followed.[1] The chest-wall is rapidly divided with scissors (the ribs having been previously cut) and along with the tumour is removed in one piece, while the lung is immediately seized (the Murphy-Müller grip), pulled up and sutured round the wound with deep sutures.

When this has been accomplished, the rest of the pneumothorax can be removed by aspiration with Potain's apparatus, before the soft parts are replaced, and the wound closed. One or two drainage tubes are placed between the outer surface of the sutured lung and the overlying soft parts, but the pleural cavity need not be drained, for any bleeding from the cut edges of the thoracic wall is controlled by the sutures which fix the lung *in situ*. If necessary, however, a continuous suture may be inserted.

The method of opening the posterior mediastinum by the removal of a portion of the rib and its transverse process (costo-transversectomy) will be dealt with in the chapter on posterior mediastinotomy. The method of turning up an osteoplastic flap of the costal arch (Marwedel) will be considered under surgery of the stomach.

74. Resection of the Sternum. The results of this operation, as shown by the statistics collected by Rouillès[2] in 1888, are relatively satisfactory. Including Otis' statistics, Rouillès was able to collect 115 cases of resection of the sternum with 28 deaths, 42 complete and 45 partial recoveries. In 4 cases where complete resection was performed there was only 1 death. The following accidents were recorded :— injury of the internal mammary artery in 4 cases, of the jugular vein once, opening of the pericardium once, and opening of the pleura in only 2 cases. In König's case, moreover, where immediate plugging was adopted, no evil consequences resulted.

It must not be forgotten that these statistics include subperiosteal resections as well as those for which the prognosis is entirely different. When undertaken merely to evacuate an abscess behind the sternum or to remove a diseased portion of bone, the operation is not serious if the periosteum on the posterior surface can be preserved and only a limited resection performed.

On the other hand, it is a much more serious matter when large portions of the sternum have to be excised, either for chondroma, sarcoma and carcinoma, or when an osteoplastic resection has to be performed in order to remove a substernal tumour. The dangers are, firstly, bleeding from the internal mammary artery and its branches, as, for example, in new growths of the sternum where severe bleeding may occur from some of the greatly dilated veins, and secondly, the risk of injuring the pleuræ of both sides. The relations of the pleura to the sternum are well shown in Fig. 307.

Under normal conditions the pleura can be easily pushed aside, but when the anatomical relations are altered by adhesions, it is a somewhat difficult process, and in every case one must be prepared to immediately pack the opening in the pleura (with subsequent closure by suture) as described in Section C.

[1] *Therapeutic Gazette*, June 1901.

[2] Rouillès, *Thèse de Paris unter Leitung von Laboulbène and Le Dentu.*

Resection of the body and the lower half of the sternum is a relatively easy matter. It is pointed out in describing the method of exposing the pericardium that, when the ribs on one side have been excised, the soft tissues and the pleural reflexion can be easily separated from the posterior surface of the sternum. By dividing the sternum transversely above and below and fracturing the costal cartilages, the operator can turn it over to one or other side as an osteoplastic flap, in this way exposing the auricles and their great vessels. The method of making an osteoplastic flap of the sternum by means of a median section will be dealt with again in connection with anterior mediastinotomy.

A special description of resection of the manubrium sternum is, however, necessary, as the manubrium is not infrequently the primary seat of acute inflammatory processes (lower down the source of infection is generally from the ribs) and also of new growths. It is further a favourite site for metastatic deposits in malignant disease of the thyroid gland.

Gravitation abscesses are met with in the upper part of the anterior mediastinum as a sequel to inflammatory conditions of the thyroid or cervical glands, while tumours of the thyroid and thymus, dermoid cysts, aneurysm, and malignant tumours of lymphatic glands are also encountered in this region. We have shown in a series of successful operations that even the largest masses of tuberculous glands in the upper part of the thorax can be removed from the neck, without resection of the manubrium, provided they are movable.

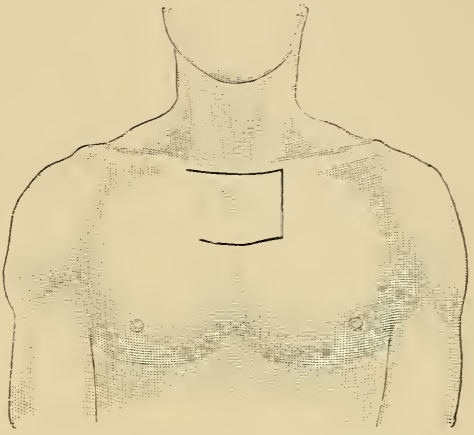

FIG. 305.—Incision for osteoplastic resection of the manubrium sterni.

From the results published to date, we may conclude that the manubrium, or even the whole sternum, can be removed subperiosteally without any great functional disturbance, and above all without embarrassment to respiration. No permanent inconvenience is reported either by Bardenheuer, who has had a comparatively large experience of the operation, or by Routizki or Rizzoli. The removal of the sternal ends of the clavicles along with the manubrium seems an advantage. The skin incision is shown in Fig. 305, and in Fig. 306 the manubrium is seen turned over to the right as an osteoplastic flap.

The upper part of the incision crosses the suprasternal notch transversely and is carried down to the bone, avoiding the communicating branch between the two anterior jugular veins, after which the periosteum on the anterior surface of the manubrium is stripped off the bone along with the capsular ligaments of both sterno-clavicular joints and the origins of both sterno-mastoid muscles. Posteriorly, the attachment of the cervical fascia and the origins of the sterno-hyoid and sterno-thyroid muscles are detached along with the periosteum, and the left sterno-clavicular articulation is freely opened by an incision down to the first costal cartilage. By incising the periosteum at the lateral margin of the manubrium the cartilage of the second rib is exposed, isolated and divided with bone-forceps, after which the perichondrium of the first rib is detached, the latter cut across, and the whole of the posterior attachment of the capsule exposed.

The manubrium can now be raised with a sharp hook so as to expose its posterior surface, and is sawn across at a level corresponding to the lower border of the second rib. By still further dragging the manubrium forwards, and carefully detaching the soft tissues, the costal cartilages on the right side are broken across and the manubrium is turned completely over to the right side. Fig. 306 shows the anterior mediastinum

exposed. On the right are seen the superior vena cava, innominate veins, internal mammary vein, ascending aorta and internal mammary artery, and on the left is observed the reflexion of the pleura.

This operation corresponds in most points with that described by Giordano and Auvray.

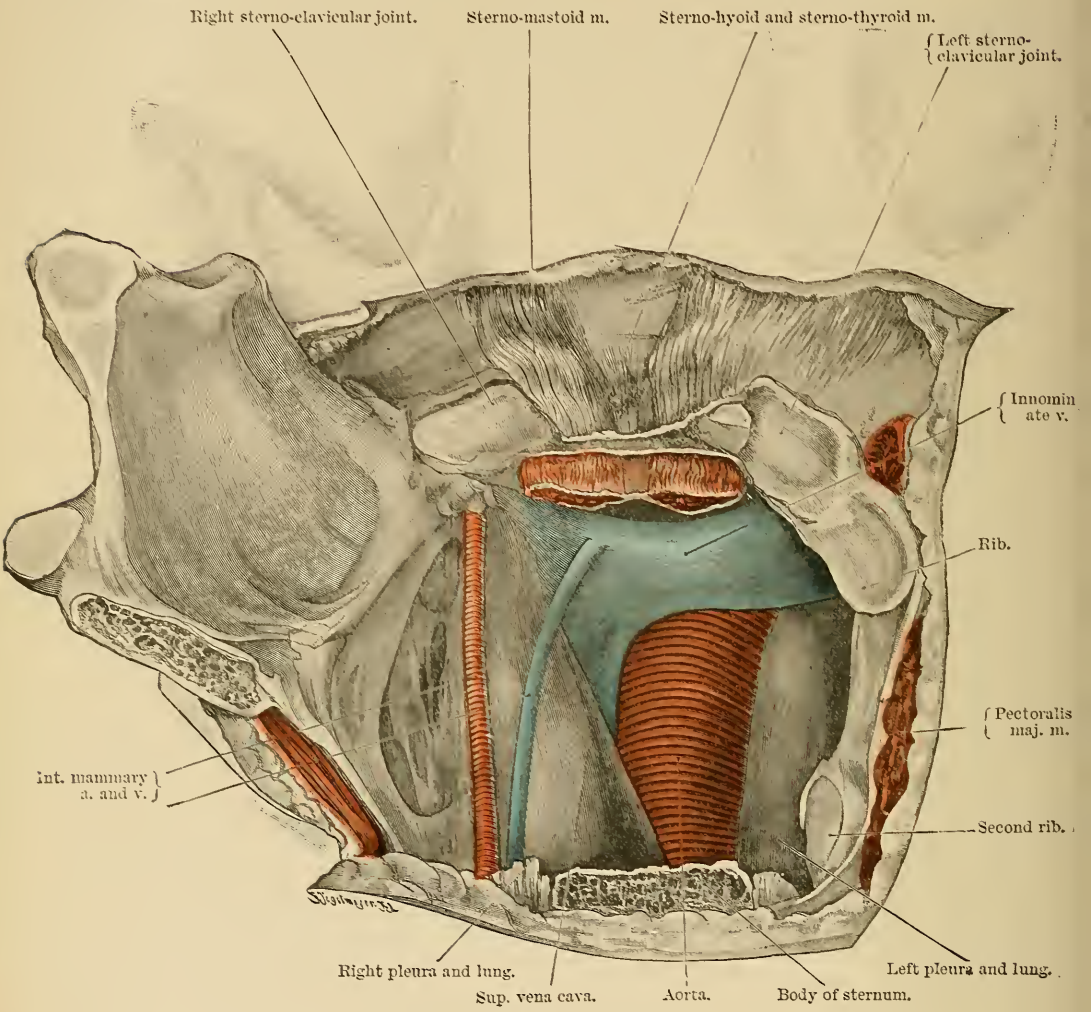

FIG. 306.—Osteoplastic resection of manubrium sterni. The sternum is turned over to the right side. The depressors of the larynx are seen detached from the back of the manubrium. The right and left pleuræ and lungs are exposed bounding the anterior mediastinum.

(f) Mediastinotomy

75. **Anterior Mediastinotomy.** Partial excision of the sternum has often been performed for the purpose of securing access to the anterior mediastinum and of exposing the innominate artery or the bronchi (Rushmore and Ricard after Loisin).

Access may be got to the upper part of the mediastinum by reflecting subperiosteally the manubrium, as described in paragraph 74 (osteoplastic resection of the manubrium). Poirier reaches the upper mediastinum by dividing the sternum transversely and

turning down the upper half as a flap. It would appear of more advantage to turn it upwards, after dividing it transversely below and cutting through the costal cartilages, as the attachments of the capsular ligaments to the clavicles would be partly preserved.

The lower half of the mediastinum can be exposed by the method described under pericardiotomy (*vide* the surgery of the circulatory system, page 83).

If it is desired to expose the anterior mediastinum in its entire length, Milton's method may be employed, in which the sternum is divided vertically in the middle line with a saw and bone-forceps. The ensiform cartilage must be removed. An interval 5 to 6 cm. (2 to $2\frac{1}{2}$ inches) broad is thus obtained, through which the reflexion of the pleura can be pushed aside, and the right auricle with its large veins exposed by splitting the pericardium. Milton has performed this operation with complete success in a case of tubercular disease in the mediastinum.

76. Posterior Mediastinotomy. Enderlen[1] has published a reliable and descriptive paper on posterior mediastinotomy in relation to disease of the œsophagus, but since the introduction of the œsophagoscope, it is seldom necessary to expose the œsophagus through the posterior mediastinum for the extraction of foreign bodies, while v. Hacker's method of continuous dilatation has still further restricted its use in the treatment of stricture. In the case of diverticula and new growths of the œsophagus, posterior mediastinotomy should be attempted as a radical excision is only possible when there are no adhesions present. Mediastinal abscesses, however, arising either from the œsophagus, glands, or the vertebræ are readily reached through the posterior mediastinum.

Stoganov (March 1899) collected fifteen cases of posterior mediastinotomy. The operation was performed twelve times for abscesses or spinal disease, twice to divide a stricture of the œsophagus and to excise a carcinoma of the œsophagus, and once for tuberculosis. In addition to this, Forgue performed it once for the removal of a foreign body from the œsophagus, and Leobet once for division of a stricture.

Stoganov describes the history of the operation, and ascribes its origin to Nassilow. Nassilow in 1880, after studying the surgical anatomy of the region on the cadaver, described the technique of the operation for exposing the œsophagus for foreign bodies and tumours. Quénu and Hartmann adopted his method in 1891. Obalinski opened a tuberculous abscess in the mediastinum after Böckel had previously recommended and described the operation; and Vincent, Auffret, and Schöffer had performed the same operation for spinal tuberculosis. Ziembicki advocated the operation in 1895. In 1897 we excised a mediastinal carcinoma of the œsophagus on the cadaver, and Rehn performed the same operation on the living subject.

Potarca published important studies on the technique in 1898. Nassilow recommended entrance on the left side for the upper part of the œsophagus and on the right side for the lower part. Potarca, in spite of the fact that the pleura dips deeper behind the œsophagus on the right side, preferred the right side only, because the aorta is too much in the way on the left.

Rehn followed Potarca's advice and went in on the right side, because the aorta greatly increased the difficulty on the left side. The incision is made vertically, midway between the spines of the vertebræ and the inner border of the scapula, and is carried down to the ribs. A few centimetres of the ends of three ribs (two to four according to Potarca) are resected subperiosteally. After dividing the intercostal muscles the intercostal vessels and nerves are isolated, the former being divided between two ligatures.

In passing down over the lateral aspects of the bodies of the vertebræ, great care must be taken to avoid the cord of the sympathetic. The azygos vein, which, together with the vagus, lies along the right side of the œsophagus, must be either pulled aside or ligatured. The œsophagus, which can now be pulled into the wound, may be incised when there is a foreign body or a stricture; if a neoplasm or a diverticulum exists a resection may be performed. Both ends must be drained, and the lower one, of course, used for feeding.

[1] *Deutsche Zeitschr. f. Chir.* Bd. 61.

Heidenhain (Langenbeck's *Arch.* Bd. lix.), as opposed to Quénu, Hartmann, and Rehn, prefers to reach the posterior mediastinum through a longitudinal skin incision close to the middle line (a transverse incision being made through the muscles), and to at once resect one or more transverse processes, together with the heads of the ribs. The removal of only one transverse process is sufficient in adults to allow of free access to the mediastinum. The soft parts are separated from the lateral and anterior aspects of the bodies of the vertebræ. Injury to the pleura is not a matter to cause anxiety.

If a periœsophageal abscess in the upper part of the mediastinum does not reach farther down than the third dorsal vertebra, it can easily be reached from the neck.

An incision is made over the clavicle, and the surgeon either passes down between the two heads of the sterno-mastoid, or, what is better, divides that muscle transversely immediately above the clavicle. The dissection is then continued to the left of the posterior aspect of the sterno-clavicular articulation, along the outer side of the common carotid and the internal jugular vein. In operating on the right side we pass down between these two vessels. By operating from above and from behind, Heidenhain succeeded in freeing the œsophagus as far as its middle. He, like Cavazzani, cured a periœsophageal abscess in this manner. Rasumowsky, by a similar procedure, cured an acute posterior mediastinitis.

In the dead subject we have exposed an œsophageal carcinoma situated immediately opposite the division of the trachea. We consider it necessary as a rule to resect more than four ribs—the second to the seventh, or the fourth to the ninth, according to the situation of the disease. The incision is made vertically over the angles of the ribs, a hand's-breadth from the middle line, through skin, trapezius, rhomboids, latissimus dorsi, and serratus posticus. The tendinous attachments of the iliocostalis and longissimus dorsi are divided and the muscles retracted inwards, and about 4 ins. of six ribs are carefully resected subperiosteally. The intercostal arteries and nerves are clearly exposed, the latter being divided between two ligatures.

The pleura, which is now exposed, can be readily separated as far as the anterior surface of the vertebral column. The œsophagus, along with the tumour, can now be felt to the right of the aorta, and, provided there are no adhesions to neighbouring organs, it can be pulled out. To separate an adherent tumour from the aorta seems rather a daring undertaking, although Farabœuf states that the aortic wall is very resistant. Bryant,[1] following Nassilow, only attacks the œsophagus from the left side, above the arch of the aorta; below this point he exposes it from the right side, while below the ninth dorsal vertebra he considers it altogether too difficult to reach. In the case of a foreign body in either bronchus, or in the œsophagus, Bryant forms a rectangular flap, with its base over the spines, and resects only one rib, but divides and retracts the neighbouring ribs above and below. He determined, in two adults, that the distance from the upper incisor teeth to the spine of the first dorsal vertebra was 203 mm. (8 ins.), to the second 219 mm. ($8\frac{3}{4}$ ins.), to the third 238 mm. ($9\frac{3}{4}$ ins.), to the fourth 257 mm. ($10\frac{1}{4}$ ins.), to the fifth 279 mm. (11 ins.), to the tenth 381 mm. ($15\frac{1}{2}$ ins.).

A review of the operative procedures which have up to the present time been adopted in dealing with diseases of the posterior mediastinum shows that a distinction must be drawn between cervical and dorsal mediastinotomy. Hacker has clearly defined this difference, and Ziembicki has shown that under certain circumstances it may be advantageous to combine the two methods, as has been done in a few cases.

(1) *Cervical mediastinotomy* has been performed by Ziembicki, Obalinski, Heidenhain, Rasumowsky, Lürmann, and Hacker. Heidenhain's advice on the method to be pursued has been given above. Hacker has published some interesting points regarding his cases. On one occasion he was able, by means of the Röntgen rays, after injecting iodoform emulsion through a rubber tube, to define the lower border of the abscess at the body of the fifth dorsal vertebra. Redness and the presence of gas

[1] *Transactions of the American Surgical Association*, 1895.

could be detected above one clavicle when the head was inclined downwards. Heidenhain also met with this sign. In the after-treatment Hacker placed the body on an incline, and in order to feed the patient properly (the œsophagus being perforated) he performed gastrostomy.

Hacker, unlike Heidenhain, made his dissection to the inner side of the large vessels. The position of the abscess in the neck should determine the route to be followed.

We have found that the cervical route is the easiest and least dangerous method of exposing the upper part of the posterior mediastinum for inflammatory affections, and these are practically the more important cases. The acute inflammatory affections which occur here are generally consequent upon œsophageal perforation (foreign bodies), and in these cases the surgeon can hardly decide on an operation too soon if the patient's life is to be saved.

(2) In *dorsal mediastinotomy* the credit of having shown how to avoid the chief danger, namely, injury to the pleura, belongs to Heidenhain. This accident has often occurred, and has caused death by secondary infection of the pleura. Heidenhain makes his incision close to the middle line of the back, and pushes the soft parts outwards from the laminæ till the transverse processes are exposed. The latter, along with the ends of the ribs, are resected. The deeper parts (to a depth of 4 ins.) can be reached with very little risk of injury by keeping to the lateral aspect of the bodies of the vertebræ. The pleura, along with the thin subpleural fascia, can be pushed to one side. The removal of only one transverse process is sufficient, according to Heidenhain, to enable the mediastinum to be reached, a point of special value in the case of abscesses.

For a detailed description of the method of dealing with abscesses in the posterior mediastinum, or if necessary of exposing the œsophagus, see paragraph 77, as well as the surgery of the thoracic portion of the œsophagus (page 503).

77. Costo-Transversectomy. This operation was described by Ménard in 1894, although it had been previously recommended and performed by Heidenhain. It may be employed with advantage in cases of spinal caries with abscess formation in the anterior or lateral regions of the bodies of the dorsal vertebræ. It gives excellent access, and allows of the abscess being opened with least injury to surrounding structures.

In describing the method of opening the pleural cavity, we emphasised the importance of cutting directly down on to a rib, removing a portion subperiosteally, and incising the pleura in the line of the rib, instead of in the intercostal space as was the former method, because the intercostal vessels and nerves are thus avoided and the only structures divided are the periosteum, pleura and endo-thoracic fascia. In exposing the posterior mediastinum it is equally advantageous to avoid the point of exit of the intercostal arteries and nerves, and to obtain access by removing the transverse process and the head and neck of the rib as far as the tubercle.

The incision, which we prefer to that used by Heidenhain, is begun over the most prominent dorsal spine, and is carried obliquely downwards and outwards along the rib which is to be resected. It must be remembered in excising the rib that the most diseased vertebra is the higher of the two with which the rib articulates. This, however, is easily determined by means of a radiograph.

After division of the skin and fascia, the latissimus dorsi and the long muscles of the back are divided in the same direction. No bad results follow the division of these muscles as they are richly supplied with nerves, and, moreover, the bleeding is much less than in Heidenhain's method, where the muscles are separated from their attachment to the spines and laminæ of the vertebræ. The smaller muscles of the back are then divided, and after the transverse process of the vertebra and its rib have been exposed, the former is divided at its root with bone-forceps. The periosteum is then peeled off the rib and the rib is divided just outside its tubercle. After carefully dividing the anterior surface of the periosteum of the rib, a finger can be passed into the posterior mediastinum, and if the diagnosis is correct, the abscess will be opened.

In a case on which we recently operated, where, in the absence of local indications,

the presence of an abscess was inferred from the late onset of paraplegic symptoms, we were able to remove a sequestrum from the body of the vertebra without difficulty. In cases of caries of the bodies of the vertebræ, it will be noticed that an abscess which emerges through the intervertebral foramen and compresses the nerve roots and the cord, can be much more satisfactorily drained by this method than by laminectomy, which is more troublesome to perform, and which exposes the posterior aspect of the cord rather than the real site of disease.

In our case the disease was completely cured, but the motor paralysis did not disappear, a result owing, no doubt, to pressure on the cord by the back of the body of the vertebra. Further treatment was refused.

This method can also be employed in the treatment of other abscesses in the posterior mediastinum, and if further space is required, more than one transverse process and rib may be excised.

(g') Pleurotomy

78. Indications for Pleurotomy. Fig. 308, after Spalteholz and Pansch, illustrates the relations of the lungs and pleura, showing where the pleura may be opened without injuring the lung, and also the formation of the pleural sinus by the reflection of the costal and diaphragmatic pleura.

Pleurotomy is performed as a preliminary step in pneumotomy, and we have already alluded to its efficacy in other operations connected with the treatment of pleural effusions. Its latest use, according to Murphy and Ratl, is to produce a therapeutic pneumothorax.

We have also pointed out in the introduction how the operative treatment of pleural effusions has been lately developed, and that now drainage of the pleural cavity is always combined with aspiration.

The same principle has, however, existed for a long time in the use of Potain's and Dieulafoy's aspirator. Revillod was one of the first to combine aspiration with permanent drainage, while Bülau demonstrated its practical use in cases where a single or repeated puncture was insufficient. Effusions of blood, lymph or serum, can be cured by a single aspiration, unless the presence of virulent organisms or new growths causes a return of the fluid.

On the other hand, when the condition is due to a progressive infective process, *e.g.* tuberculous effusion or empyema, drainage with aspiration must be continued till the infective source is either removed or destroyed.

79. Pleurotomy for Empyema. The following is the method most commonly employed in opening the pleura for the removal of purulent effusions. Having ascertained the presence of pus by exploratory puncture with Pravaz's syringe, we make an incision, 4 to 6 cm. in length, along a rib in the area of dullness, a method we have adopted under local anæsthesia even on children with very little discomfort.

The patient's skin is first prepared as for all other aseptic operations, while the usual precautions are taken against sepsis.

The edges of the incision are swabbed with an alcoholic solution of carbolic acid, and iodoform powder is rubbed into them in order to prevent infection of the freshly-cut surface. The periosteum is then carefully reflected and $1\frac{1}{2}$ to 2 in. of the rib is removed with Liston's or Lüer's forceps. The pleural cavity is then opened by incising the periosteum for a distance of $\frac{1}{2}$ in. and is thoroughly washed out with warm saline solution, after which a drain is inserted and antiseptic dressings are applied.

Empyemata, secondary to pneumonia, or following a traumatic pleurisy where suppuration has occurred in the effused blood, can be readily cured by this method, and with complete restoration of the pulmonary function; while the lung, owing to the suction action of the chest-wall, comes to the surface again, and the discharge disappears. There can be no doubt that the majority of physicians now advocate the early and complete evacuation of purulent exudates in the pleura.

It cannot be denied, however, that immediate healing does not occur in certain cases, owing to incomplete evacuation of the exudate, either because the opening in the pleura is too small or because it has not been suitably placed.

When the opening has been too small, much benefit will be derived from Bülau's method of syphon drainage or from permanent aspiration. In the former method a

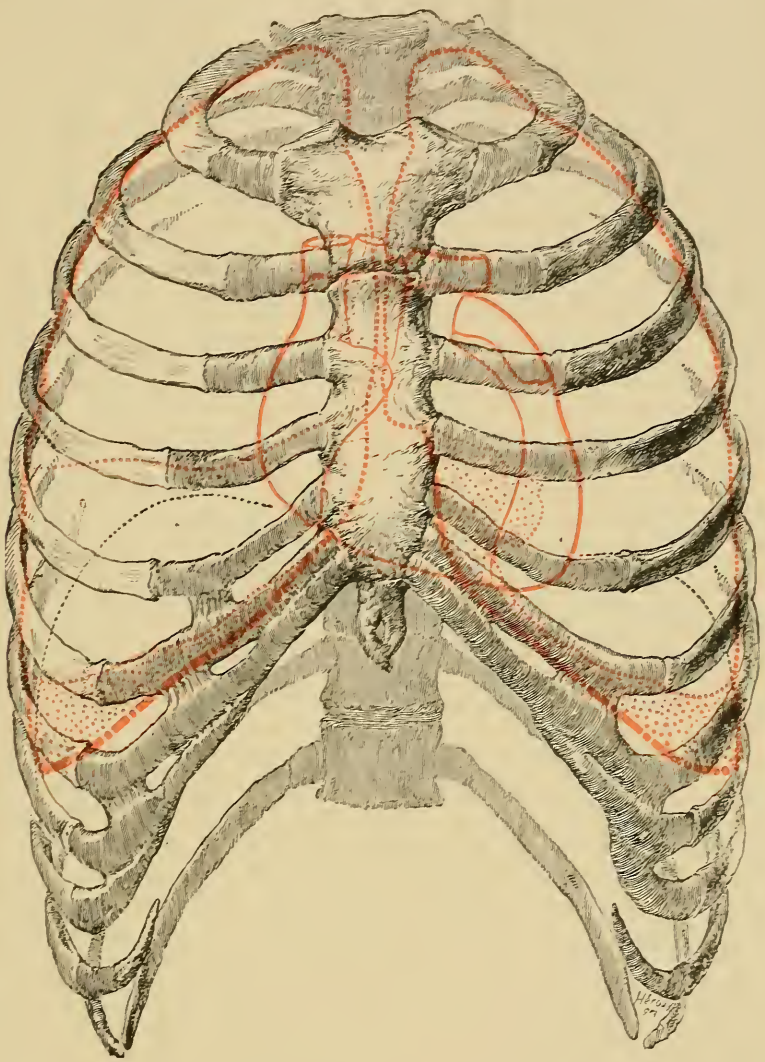

FIG. 307.—Combination of figures from Spalteholz and Merkel's *Anatomy*, showing the outlines of the heart (red line), lungs (thick dotted lines), and the pleuræ (thin dotted lines). The diaphragm is outlined in black.

rubber drainage tube is inserted down to the bottom of the cavity, a special opening through a rib being sometimes made for this purpose, and the contents are syphoned by bringing the tube over the bed and immersing its end in a vessel containing water (carbolic or sublimate solution). Or, as an equivalent, an aspiration apparatus may be applied similar to that used in producing congestion. In the first case, care must be taken to make the wound air-tight by packing antiseptic dressings all round the

drainage tube; but in the latter the aspiration apparatus secures sufficient closing of the wound. In either case the importance of preventing mixed infection cannot be overestimated. There is often a tendency to carelessness in dealing with suppurative cases, and we place more importance on ensuring a good outflow and avoiding mixed infection than on the production of hyperæmia. In our clinic we have for long emphasised the harmfulness from this point of view of large incisions, and believe

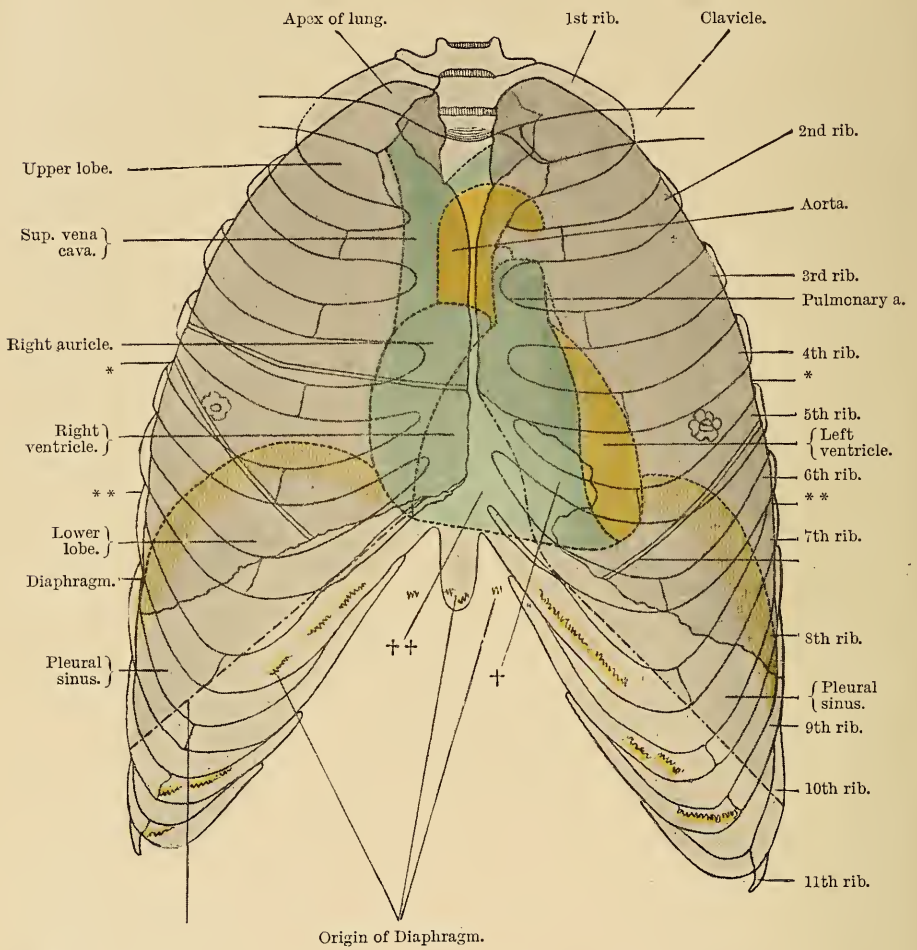

FIG. 308.—Relations of the thoracic viscera. The lungs are shaded dark and the pleuræ light grey. † The incisura cardiaca. †† The area of pericardium in direct contact with the chest-wall (no pleura intervening). (After Pansch.)

that Bier has rendered much greater service in teaching the profession how to make use of small incisions, than in making them think that treatment by hyperæmia is a cure for every evil.

It often happens, however, that the case is seen too late for the application of proper treatment, and mixed infection has been produced by lack of aseptic precautions in opening the pleura, in which neglected cases one must rely on free incision and open treatment of the wound.

80. Treatment of Neglected Empyema. Chronic empyemata need not be con-

sidered separately as they come under the category of neglected empyemata, *i.e.* they have not been opened at the proper time. There are cases, however, which, although not of old standing, have as a result of careless operation become chronic. Simple aspiration, or aspiration combined with drainage, is here quite insufficient, as such cases must be treated by an open wound. Chronic empyema, further, should no longer occur, as the majority of physicians and surgeons now realise that recovery can only be guaranteed by thorough evacuation at the proper time, in which case there is considerably less risk of an unfavourable result.

It is a common enough failing amongst practitioners to regard the opening of a recent empyema as a slight, or even trivial, proceeding, and from lack of proper care mixed infection occurs.

In order that the infective exudate may be thoroughly drained, the opening must be sufficiently large, and must be made at the most dependent part of the pleural cavity. This is effected by Walter, by means of posterior pleurotomy, and by Delagenière, by drainage of the costo-diaphragmatic sinus.

As Fig. 308 shows, the pleural cavity is opened by removing the cartilage of the sixth rib; in the lateral region the right pleura will still be opened by removing the ninth rib, and the left by removing the tenth rib; posteriorly in the scapular line (on both sides) by removing the twelfth rib. A preliminary puncture should never be made at these lowest limits, because the diaphragm may be immediately subjacent to the wall of the chest. It is better, as stated above, in the first instance to open the pleural cavity in the region where one is quite certain of finding fluid, *i.e.* where its presence has previously been ascertained by puncture, or by aspiration with an exploring syringe. After a free opening has been made, a probe or the finger is introduced to ascertain the deepest part of the cavity, over which a second opening may then be made by resecting a piece of rib. In this way provision is made for efficient drainage and for syringing out the cavity through two openings.

Schede is right in stating that the subsequent expansion of lung takes place best when the thorax is opened at its deepest and most posterior part. He advises resection of 6 cm. ($2\frac{1}{4}$ ins.) of the ninth and tenth ribs in the scapular line, thereby differing from König, who resects a portion of the sixth rib in the axillary line, but does not obtain such rapid healing. By following Schede's procedure the cavity may be at once washed out, a short and wide T-shaped tube being used to allow of the free escape of the fluid.

Repeated washing out of the cavity is, as a rule, to be avoided, as, according to Schede, it interferes with the adhesion of the pleura. Fœtid empyemata, however, should be washed out, and retention of pus must be prevented by efficient drainage.

We have never found any harm result from continued irrigation, and if sterile salt solution only is used and all aseptic precautions are taken, much benefit will be derived. The chief disadvantage is that it interferes with the antiseptic dressings, which consist chiefly of iodoform gauze and sublimated woodwool wrung out of carbolic. According to Schede's statistics, both as regards mortality and definite recoveries in neglected empyemata, resection of a rib is a far superior method to that of drainage with aspiration.

81. Treatment of Chronic Empyema (Fig. 309). We have already stated that all chronic empyemata may be classed as neglected, but it does not follow that all neglected cases are necessarily chronic. Owing to the long duration of the latter cases and the consequent changes in the parts, the surrounding tissues become so modified that it is impossible for the lung to expand and resume contact with the thoracic wall. The parietal, or visceral pleura, or both, become hard and indurated, and shrinkage of the abscess cavity is prevented or indefinitely retarded. The only advantage is, however, that the danger of a sudden displacement of the mediastinum and collapse of the lung is removed.

In these cases mobilization of the chest-wall or of the lung is of benefit, and may be accomplished in a variety of ways—by simply dividing and separating the indurated tissues from the ribs (Quénu), or by a more extensive resection of ribs, an operation first introduced by Simon, and developed by de Cerenville, but brought to

perfection by Estlander, whose name it bears, or finally by Delorme's operation, in which the indurated tissues are dissected off the lung.

Estlander, who further developed the procedure which Simon and Küster had previously adopted, makes a vertical incision, dissects back the soft parts, and resects a number of ribs subperiosteally: the skin is replaced, and the oval area of the chest-wall, no longer supported by the ribs, is able subsequently to sink in. Schede introduced a much more thorough and extensive operation. He makes a large curved incision which commences posteriorly between the vertebral column and the scapula, and is continued downwards to the lower border of the pleura. It is then curved forwards and upwards to the anterior axillary fold, ending immediately below the pectoralis major. The soft parts are reflected off the chest-wall and turned upwards, and all the ribs from the second downwards are then freed subperiosteally and divided at their costal cartilages and posteriorly. The intervening intercostal muscles with the thickened pleura are then removed, the latter being previously thoroughly opened. The visceral pleura is scraped with a sharp spoon, and the external soft parts are then replaced over it.

Schede's method, which placed the operative treatment of old-standing empyemata with contraction of the lung on a sound basis, has been improved by Depage, who, after merely dividing the ribs through the incision, turns the entire area of the chest-wall upwards as a flap, and then resects the ribs subperiosteally as far as necessary from the inner surface. This certainly is a far less severe method than that of Schede. For its success, however, it is essential that the pleura should not have become so inelastic as to prevent its coming into contact with the shrunken lung after the ribs have been removed.

Delorme has lately suggested a method (pneumoplasty) for bringing about the closure of old empyema cavities, a method which, when available, is better than the above operations. After opening the pleura he separates extensively its adhesions to the lung, and then performs, as far as is necessary, a decortication of the cicatrised tissue from the surface of the lung. Lardy and others have proved that this is the best means of causing the lungs to expand so that they may come in contact with the inner wall of the chest. On the other hand, Voswinkel affirms that the operation is more difficult to perform and the hæmorrhage is more severe.

The following is the procedure we adopt for old-standing large empyema cavities which will not heal on account of adhesions:—In order to ascertain the extent of the cavity one or two ribs are excised in the situation of the sinus. If there be no fistula, or if it be in a position unsuitable for exploration, an exploratory puncture is made in the axillary line to determine the lowest limit of the cavity, and one or two ribs are here resected.

An oblique incision is carried from the opening through the soft parts in an upward and backward direction between the scapula and the spine, as far up as the preliminary exploration has shown that the cavity extends. The ribs and intercostal spaces are divided seriatim along this incision, the periosteum of each rib being reflected, and 1 to 2 cm. of bone removed. The soft tissues of the intercostal spaces should be divided as far forward as possible, as the artery can be more easily ligatured in that situation. If the cavity reaches as high as the first rib it also must be resected.

The incision is then prolonged in a forward direction along the rib corresponding to the lower border of the cavity. This rib is resected subperiosteally, and the periosteum and indurated tissues are divided along the whole length of the wound. Lastly, the incision is continued upwards.

The anterior limits of the cavity are followed with the finger, and the skin, the soft parts of the intercostal spaces, and ribs (or the costal cartilages) are divided along this line. The flap so formed, consisting of the whole thickness of the chest-wall, can now be gradually thrown upwards *in toto*, and the position of the lung and state of the visceral pleura examined.

If, on dividing the pleural adhesions, it is found that the lung is still capable of expansion, and that the adhesions can be peeled off, nothing further requires to be

done, provided the lung expands to fill up the cavity. But if the lung does not expand sufficiently then Depage's operation must be resorted to, as many ribs as necessary being resected from the pleural surface of the raised flap, commencing with the lowest one. In order to make the flap thoroughly movable it may be necessary to resect even the first rib, but this is no easy matter. Owing to the firm adhesions

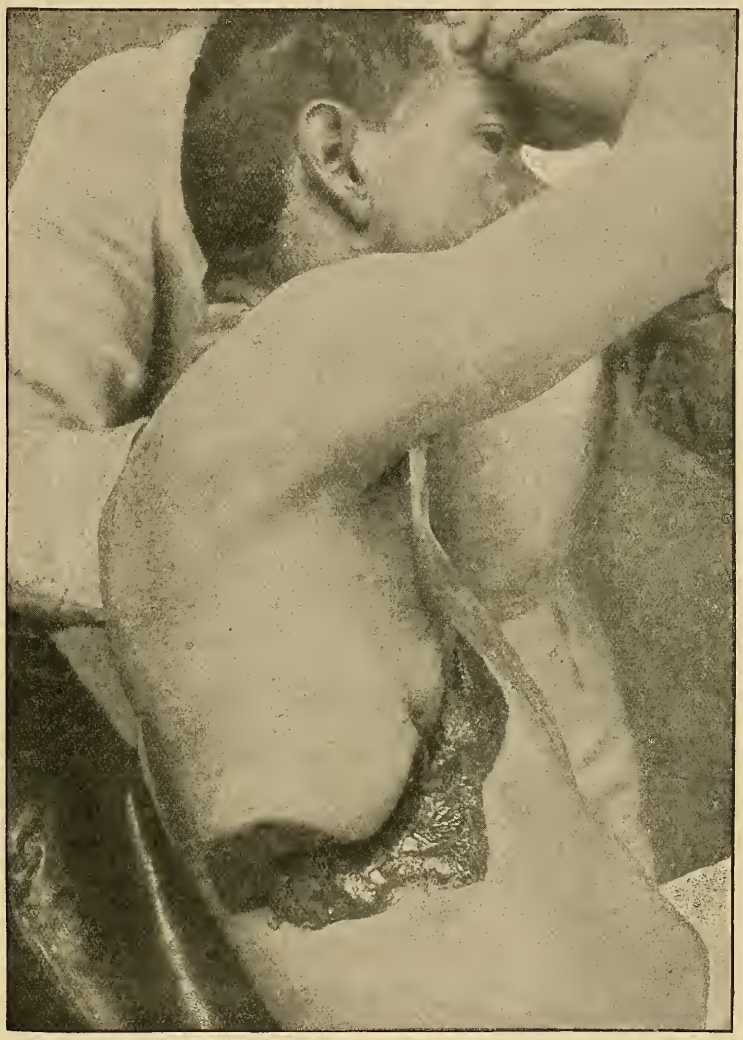

FIG. 309.—Thoracotomy with division of 9 ribs (3rd-11th) for fistula after empyema.

the subclavian vein may be torn, as happened to us recently notwithstanding every precaution. Stuffing and subsequent suture of the vein prevented any evil results.

If, after Depage's operation, it is found that the costal pleura is so dense that it is impossible for the chest-wall to fall in sufficiently to come in contact with the shrunken lung, the requisite area of thickened pleura must be removed from the inner surface of the flap.

When one has to deal with a more limited cavity, the flap methods of Schede, Keen, and Depage are not necessary. The ordinary Estlander operation is all that is

required, the portion of the ribs covering the cavity being resected subperiosteally by means of a simple longitudinal incision. But it must be borne in mind that frequently a large cavity is divided into two portions by a dense septum, so that the obliteration of only one of the cavities will not bring about a cure of the condition.

Fig. 309 shows the extent of the incision and the procedure to be adopted for a limited empyema.

If it be desired to perform an osteoplastic operation according to Delorme's method, *i.e.* to replace the flap that has been reflected, a small piece of each rib which overlies the posterior limit of the cavity may be resected through separate small incisions. The ribs having been already divided anteriorly, a portion of the thoracic wall can now be folded back like a door on its hinges. If prepared the ribs can also be broken across posteriorly. The dense and thickened visceral pleura covering the collapsed lung is incised and stripped forward and backward off the lung until it once more expands.

In advocating resection of the scapula, Sudeck has made a notable advance in the radical cure of large rigid empyema cavities, as the scapular muscles can be utilised to obliterate the hollow of the empty pleura. Ringel (1) has reported three severe cases in Kümmel's wards which were cured by this method. The difficulty connected with resecting the first and second ribs is avoided, as the flaps thus obtained are so thick. The subsequent limitation of movement of the arm is comparatively little.

Sudeck resects the ribs *seriatim* through parallel incisions, while on the other hand Ringel adopts Schede's U-shaped incision. Where the costal pleura is greatly indurated, and especially in tuberculous empyemata, besides the clearing out of the intercostal spaces, all the thickened adherent tissues should be dissected off the lung. If the U-shaped incision is made, it should overlap the edges of the cavity all round. Even the largest tuberculous empyemata may be cured by this operation, provided that the other lung is in a healthy condition.

Ssubbotin, following Ringel's suggestion, introduced in 1888 a wedge-shaped resection of ribs. Simon, Küster, and Estlander have exploited a complete subperiosteal operation, while Schede has gone so far as to remove the whole chest-wall in some cases where the adhesions were excessively rigid.

(h) Pneumotomy

The method of securing access to the lungs, and at the same time avoiding the dangers of pneumothorax and infection, has been described in detail in a previous part of this chapter. The treatment of special diseases will now be considered.

82. The Treatment of Pulmonary Suppuration. Although the surgery of the lung is no longer limited to the treatment of abscesses, it is in the latter condition that operative interference is most commonly required.

With the patient lying on his back or abdomen, not on the sound side, an incision is carried, under local anæsthesia, along the rib corresponding to the lowest limit of the abscess. The rib is exposed and resected subperiosteally, and by retracting the skin upwards all the other ribs in relation to the abscess are similarly exposed and resected. Garré advises caution in the region of the heart on account of subsequent adhesions of the pericardium. The lung is then fixed to the thoracic wall (Korte) by means of Roux's circular stitch already described. Garré states that in about 87 per cent of cases this is unnecessary as the lung over the abscess is already adherent, but it is often difficult to know this beforehand. The pleura is then incised, and if there is much dense cicatricial tissue covering the lung it should be divided with the knife and removed. After having localised the abscess by means of an exploring needle, the superficial part of the lung is opened with the thermo-cautery and the opening enlarged and deepened with a blunt instrument. In dealing with an acute abscess nothing more need be done, but in cases of chronic suppuration with induration of the surrounding lung tissue, Garré removes the thickened tissues, resecting still more ribs if necessary.

The abscess cavity is then stuffed with iodoform or xeroform gauze, and antiseptic dressings are applied. Abscesses of the lung should never be washed out for fear of spreading infection to other bronchi. In suitable cases, instead of employing packing, a drain may be inserted through a special opening in the skin, after which the wound is completely closed and a suction apparatus applied. This form of treatment, however, requires more supervision. The cavity closes by contraction of the adjacent lung tissue, and Garré states that bronchi as thick as a quill will close by cicatrisation.

Of four hundred cases operated on for suppurative conditions of the lung, including abscesses, gangrene, and bronchiectasis, Garré states that 75 per cent of cures was obtained.

83. Surgical Treatment of Tuberculosis and Actinomycosis of the Lung and their Sequelæ. Surgical treatment of tuberculous lesions in the lung, as elsewhere, does more harm than good if an incomplete operation is performed. Success can only be obtained by a complete removal of the diseased tissues. Tuffier and Lawson have extirpated tuberculous foci with success.

Simple incision only leads to mixed infection with staphylo- and streptococci, and consequent chronic suppuration.

The excision of a tuberculous focus in the lung is at the present time liable to failure, owing to the fact that in the first place it is not easy to diagnose an isolated focus with certainty at a sufficiently early stage, and secondly because it is even more difficult to determine whether the disease has not extended farther.

At present the surgical treatment of pulmonary phthisis can only effect the complete removal of localised foci by providing sufficient access, *i.e.* by resecting the ribs.

Resection of the ribs enables us to insert a needle into the lung without danger and to aspirate and examine the contents of cavities and caseous foci, while if mixed infection is present, with decomposition of the contents, fever, and other symptoms of chronic sepsis, it permits of a thorough opening being made and of appropriate cleansing with carbolic alcohol and plugging with iodoform gauze.

Even when a circumscribed cavity cannot be discovered, resection is still serviceable, for it provides an opportunity of injecting small quantities of carbolic and iodoform in glycerine to stimulate the cicatricial contraction of the focus.[1]

Garré also draws attention to the statement made by Freund and Schmorl, that in apical phthisis the first costal cartilage is frequently found to be shortened, and points out that the tuberculous process often originates in this portion of the lung, which has never become inflated. Just as Nature, according to Freund's observations, leads to a complete cure of a tuberculous focus by the formation of a false joint in the first costal cartilage, so similar results are possible from artificial increase of pressure.

Access is got by an incision along the first intercostal space, dividing the skin, fascia, pectoralis major and intercostal muscles, at the same time avoiding injury to the internal mammary artery and the axillary vein. The periosteum and perichondrium are incised along the lower border of the first rib, carefully reflected upwards, with the lower two-thirds of the rib and cartilage resected. The upper third protects the axillary vessels but may be subsequently divided if mobility is required.

By freeing the parietal pleura, according to Tuffier's method, sufficient room is secured to enable one to palpate the lung, but if necessary the second costal cartilage may be resected. If on exploratory puncture pus is found, a small incision is carried into the lung and the opening enlarged with forceps until the cavity is completely emptied, when it is packed with gauze.

In actinomycosis of the lung, when the disease has spread directly from the chest-wall to the lung and pleura, the localisation of the operation is much more definite. Garré has reported four cases which were cured by surgical interference. From our experience of actinomycosis of the superficial tissues—a disease which is by no means rare in Bern—it is not necessary, as Garré advises, "to cut out the whole disease

[1] We only mention in passing Murphy's research on the influence on pulmonary tubercle of "therapeutic pneumothorax" produced by introducing nitrogen into the pleural cavity. Lemke and Braun recommend the method. The results are far from convincing.

regardless of the tissues," for in the case of the lung as elsewhere, there is a risk of spreading the infection. But thorough opening of all sinuses and removal of masses of granulations, painting with tincture of iodine and subsequently packing every corner, and above all the administration at the same time of 60 to 90 grains of potassium iodide daily, are advisable.

Intractable sinuses, which fail to heal on account of the retraction and rigidity of the surrounding tissues, or which are more frequently associated with bronchiectasis from the traction of the cicatricial tissue, are amongst the most common sequelæ of pulmonary abscess.

In these cases, therefore, as soon as the primary condition has been cured, the mobility of the surrounding tissues should be restored by resecting the ribs, freeing the parietal pleura and dividing or excising all fibrous adherent cicatricial tissue in the manner already described for the treatment of chronic empyemata.

Garré believes that healing is accelerated by suturing healthy lung over the open bronchus after removing the fibrous and indurated tissues, and then closing the wound in the overlying soft parts. It is a condition which certainly calls for energetic treatment. To suture the lung and pleura securely, in one case Garré had to free the greater part of the lower lobe of the lung to such an extent that it could easily be pulled into the opening in the thoracic wall.

84. Surgery of Tumours of the Lung. In connection with tumours of the lung, the diagnosis is the most difficult problem the surgeon has to decide. Apart from hydatids, the treatment of new growths of the lung has achieved little success in cases other than those where the tumour growth has spread from the chest-wall to the lung, *e.g.* in sarcomata. Although an extensive operation is necessarily required, Rehn, Kronlein, W. Müller, Garré, Keen and others have obtained excellent results.

In these cases the site of the growth can be accurately determined, while the portion of the lung involved is already adherent to the thoracic wall. The risk of pneumothorax is therefore well under control, for once the tumour has been detached from the chest-wall it forms a useful handle by which the lung can be pulled forward.

This is also the reason why such brilliant results are obtained in the treatment of hydatid cysts with adhesions, the result of previous inflammation. Garré estimates the mortality at 10 per cent in cases which have been submitted to operation as against 64 per cent where the disease has been allowed to run its natural course.

In the treatment of hydatids, mere incision of the cyst, not excision, is all that is required. After a limited resection of ribs the lung tissue is incised (Garré) and the cyst emptied and packed. If the cyst is small, Borrow advocates its complete closure by suture.

The technique in cases of sarcoma (carcinoma) of the lung, the result of direct invasion from the chest-wall, differs, therefore, in that, after division of the parietes round the growth, the tumour has to be excised from the lung tissue and healthy lung has to be fixed to the edges of the wound in order to prevent collapse (as described in section (*c*)), the pneumothorax being subsequently evacuated by aspiration. A further difference between the excision of malignant tumours and the treatment of adherent hydatids is the presence of blood which collects in the pleural cavity.

Gerulanos maintains that by preventing the accumulation, better results are obtained if drainage of the pleural cavity is employed. The drain should be placed at the most dependent point. Aspiration-drainage (Willems) is, however, the best means of promoting the expansion of the lung, while, in addition, it diminishes the risk of secondary infection from without.

On the other hand, Rehn, who is one of the pioneers of thoracic surgery, closes the wound at once to avoid this risk and only employs drainage when necessary.

Tumours which are non-adherent to the chest-wall (certain forms of hydatids, dermoids, sarcoma, and carcinoma of the bronchi), are dealt with on the general lines laid down for the prevention of total pneumothorax. If the growth be localised by X-rays, and is superficial and not multiple, the opening in the pleura must be large enough to allow of the lung being palpated, pulled forward and sutured, while warm compresses may be used to prevent the entrance of air (Krause).

The thorax is thus simply opened to enable one to inspect and palpate thoroughly the lung. Sufficient space is obtained by resecting the greater part of one rib and incising freely the deep layer of periosteum (Mikulicz's intercostal incision does more injury to the parts), or by making an osteoplastic flap, as Posada advises for non-adherent hydatids (Garré). An extensive resection of the chest-wall is quite unnecessary.

After the tumour has been excised and the lung sutured [1] or stitched to the wound, the pleura should be aspirated, and if fluid tends to collect in it, it should also be drained.

Extensive resections, as are made, for example, in chronic empyema, are only necessary for excision of part of the lung, *e.g.* in Helferich's operation of pneumotomy. Helferich has gone so far as to excise the middle and lower lobes, ligaturing the vessels and larger bronchi, and afterwards covering the stump with the remaining lung tissue. In such a case, provision must be made for dealing with the large cavity, which cannot be immediately filled.

85. Surgery of Injuries of the Lung. Subcutaneous as well as penetrating wounds of the lung, even when complicated by severe hæmothorax or pneumothorax, generally heal without intervention, provided, firstly, that there are no abnormal conditions present to interfere with the arrest of hæmorrhage or to give rise to late hæmorrhage; secondly, that the large vessels at the root of the lung are not wounded, and finally, that septic infection is absent.

When there is no external wound, or if it is only a very small one, surgical interference for the arrest of hæmorrhage with suture or packing is only exceptionally indicated, according to Garré, *i.e.* when the hæmorrhage is profuse and repeated. It is often very difficult, however, to come to a decision regarding the severity of the bleeding. Garré also advises operation in cases of valvular pneumothorax, when air is being constantly sucked in and its exit prevented. In the latter case repeated aspiration may, however, be employed.

It is quite different when there is a large gaping wound in the thoracic wall. Here, the wound should be extended along an intercostal space, as Delagénière and Thiel advise, and the lung pulled up by inserting the hand into the pleural cavity. When the rent in the lung has been exposed, it must be firmly closed with deep sutures. If the hæmorrhage proceeds from the root of the lung, it is then so deeply placed that its arrest by suture or ligature is practically impossible. Garré has, however, reported three cases in which it was successfully controlled by packing.

To Rehn belongs the credit of demonstrating the advantages of immediate suture of the thoracic wound, even at the risk of having to employ secondary drainage in a few days. We much prefer to insert at once a drainage tube (cigarette) at the most dependent part of the pleural cavity, by cutting down on a pair of curved forceps pushed into the lowest intercostal space, as Sauerbruch recommends.

When the wound in the lung has to be packed, this dependent drain is indispensable. It is only when the lacerated portion of lung can be securely anchored in the region of the wound that the pleural cavity may be primarily closed (Rehn), after the air has been aspirated, and any blood-clots removed by flushing with saline solution.

In addition to hæmorrhage and valvular pneumothorax, there is another urgent indication for immediate operation, viz. bilateral pneumothorax. In such cases aspiration must be employed at once, and if it is associated with an open wound the collapsed lung must be immediately drawn up and anchored to the thoracic wall.

Injury to the diaphragm resulting in diaphragmatic hernia also calls for immediate opening of the thorax, preferably by an incision below the fifth rib or in the interspace above or below. After reduction of the hernia the tear in the diaphragm is to be closed.

Infection of the lung from a septic pleurisy is a further indication for immediate thoracotomy. This has, however, already been alluded to in a previous chapter.

Hernia of the lung is a fortunate occurrence inasmuch as it closes the wound in

[1] Tiegel found that sutures of the lung are considerably more reliable if the silk is taken directly from a solution of chloride of iron. He also employs supporting sutures.

the thoracic wall. When it persists it may be covered over by means of an osteoplastic flap obtained by division of the ribs and costal cartilage on one side in the manner recommended by Vulpius.

(i) Transpleural Operations.

Although every operation on the lung is necessarily performed through the pleura, the term "transpleural" is only applied to operations in which both layers of parietal pleura are traversed in order to reach certain structures in the abdomen or posterior mediastinum. In these circumstances it is most important to guard against the entrance into the pleural cavity of air, blood, or other secretions. The method by which the pleural cavity is shut off depends on whether the operation is performed through the costo-diaphragmatic sinus, where the parietal layers of the pleura are in contact, or through the pulmonary part where they are widely separate from one another.

86. Transpleural Laparotomy. The opening of the abdomen through the pleura and the diaphragm is chiefly performed in exposing the convex surface of the liver for the purpose of opening abscesses or hydatid cysts (transthoracic hepatotomy) (Figs. 310, 311).

The presence of an abscess having been ascertained by an exploratory puncture, an incision 4 in. long is made extending obliquely forwards from the anterior axillary line between the seventh and eighth ribs, or in the posterior axillary line between the eighth and ninth ribs. The fascia and the muscular fibres of the latissimus dorsi and external oblique are divided. The periosteum covering first the one and then the other rib is separated all round with a sharp raspatory, carefully avoiding the pleura, and at least 3 ins. of both ribs are excised. The pleura is now shut off with a continuous circular suture introduced so as to surround the area where the opening is to be made. According to Stiles, deep sutures should be introduced with a curved needle, first through the soft parts of the intercostal spaces, and then under the extremities of each of the periosteal troughs (after resecting portions of two ribs), so as to include both layers of the pleura (costal and diaphragmatic), and thus to shut off entirely the area of operation from the rest of the pleural cavity. A portion of costal pleura, at least 2 inches in diameter, can then be excised within the sutured area, and the glistening bluish upper surface of the diaphragm exposed. The diaphragm, which forms a somewhat thin layer of muscle between the pleura and peritoneum, is then incised.

If the peritoneum is not adherent to the upper surface of the liver a continuous circular suture must also be introduced between the parietal and visceral peritoneum. The liver abscess (or hydatid cyst) is then opened—with the thermo-cautery if deeply situated—and the cavity is then stuffed with iodoform gauze.

Perpleural Method of Opening Subphrenic Abscesses. Subphrenic abscess most commonly results from inflammatory processes round the cæcum. The temperature, which may have subsided as the primary exudate in the right iliac fossa undergoes resolution, either suddenly or gradually rises again and the patient's condition gets worse. There is pain in the loin and interference with respiration, while the liver dullness distinctly increases and may extend from the fifth rib above to several fingers'-breadths below the costal margin. There is also tenderness on pressure in the loin and along the costal margin, with increased resistance, while there may be a characteristic metallic resonance at the highest point of the dull area.

A long exploring-needle should be first inserted to determine whether the abscess can be reached from the costal margin. If no pus is found, portions, $2\frac{1}{2}$ ins. in length, of the ninth or tenth ribs should be resected subperiosteally over the area of maximum dullness and tenderness. The needle is then inserted through the posterior layer of periosteum, pleura and diaphragm, to ascertain the proper place in which to incise the pleura.

As the patient lies on his back, the pressure of the diaphragm against the chest-wall in this position prevents the entrance of air when the pleura is opened. The

costal and diaphragmatic pleural are then sutured together with a continuous circular catgut stitch, after which the diaphragmatic pleura is divided in the centre of this area, and by separating the muscular fibres of the diaphragm the abscess is entered. It is then drained, thoroughly irrigated with saline lotion, and a warm salicylic fomentation is applied.

87. Surgery of the Thoracic Portion of the Œsophagus. The method of exposing the œsophagus and the structures adjacent to it through the posterior mediastinum has



FIG. 310.—Resection of ribs to expose the surface of the liver. A portion of two ribs has been removed, and the intercostal tissues have been ligatured and excised. The costal and diaphragmatic pleura, along with the diaphragm and peritoneum, have been incised, exposing the upper surface of the liver.

already been considered in a previous chapter, where we pointed out that posterior mediastinotomy is chiefly employed for minor conditions, such as opening a peri-œsophageal abscess, or removing a foreign body.

The extensive resection of ribs which Quénu, Hartmann and Levy have recommended for the excision of mediastinal tumours, and which has been carried out by Rehn and Faure, the latter of whom even excised the first rib, has not proved satisfactory. Better results can be secured by other methods. Jaboulay has chosen the most direct and daring line. He exposes the pericardium from the front, divides it in its

whole length, pushes the heart aside and reaches the œsophagus by incising the posterior wall of the pericardium.

Experiments, however, have shown that the transpleural route affords the best access, and we owe much to Sauerbruch for his excellent investigations on the surgery of the thoracic portion of the œsophagus. Through the kindness of Herr Sauerbruch and Professor Borchard, we had opportunities in the late v. Bergmann's clinic of witnessing operations of this nature, both under reduced pressure (10 mm. mercury) and under high pressure with Engelken's apparatus (at about 10-18 mm. water). We are convinced of the perfect applicability of the method. The anæsthetic employed was oxygen and chloroform given with the Roth-Drager apparatus.

Sauerbruch only obtained good results in resection of the œsophagus when he employed the anterior transpleural operation introduced by Mikulicz and Dombromysslow. Later, he adopted Mikulicz and Anschutz's modification, in which the line of suture comes to lie inside the abdomen, either by drawing up the œsophageal foramen

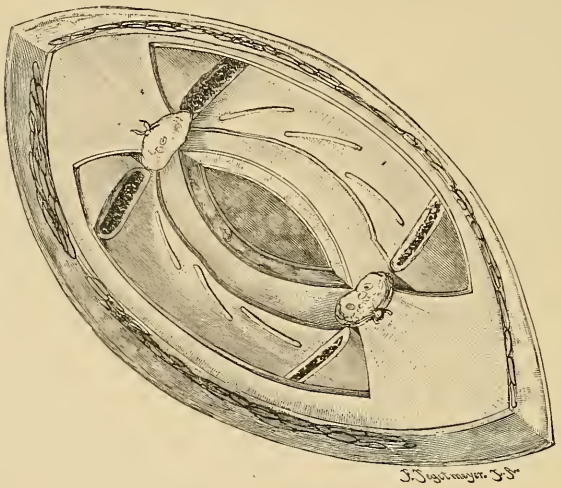

Fig. 311.—Transpleural exposure of the convex surface of the liver. The soft tissues of the intercostal space have been ligatured at the extremities of the divided ribs; the part between the ligatures has been cut away. The costal and diaphragmatic pleura are stitched together with a deep suture which shuts off the rest of the pleural cavity; the two layers of the pleura, the diaphragm, and the peritoneum have been incised, and the upper surface of the liver is exposed.

and stitching it to the cut end of the œsophagus, or by pulling up a portion of the stomach into the thorax. Lately he has used a Murphy's button with much success in performing the anastomosis. He has demonstrated by careful observations on the cadaver, which Mikulicz has confirmed on the living subject, that it is possible to isolate and preserve the vagus nerves in resecting the œsophagus, and that after division of the pleura and the peritoneum at the diaphragmatic foramen the stomach can be pulled up as far as the hilum of the lung.

He recommends his low pressure chamber manufactured by the firm of Trelenberg in Breslau. The operation is performed with a reduction of air pressure corresponding to about 7 to 9 mm. Hg., closing the wound under 14 to 15 mm. Hg. The modified high-pressure chambers by himself and Engelken are also to be recommended. For operation on animals the anæsthetic used was morphia and ether.

88. Transpleural Œsophagotomy. Sauerbruch employs an incision through the third right intercostal space exclusively, and reaches the œsophagus on the right side above the root of the lung, and as low as the azygos vein. The lower part of the œsophagus is reached through the fourth or fifth left intercostal space.

In urgent cases the intercostal incision in our opinion gives the quickest access to the pleura and pericardium in dealing with injuries of the lungs and heart, but in ordinary circumstances the subcostal incision is to be preferred. An incision of the desired length is made by sliding up the skin, and cutting firmly down on to the rib and cartilage. A portion of the rib is then excised subperiosteally, and the underlying periosteum, endothoracic fascia, triangularis sterni and pleura are incised, without appreciable bleeding, and without the risk of entering the pleural cavity too soon. When operating without an air chamber, a preliminary pneumopexy is advisable.

By forcibly separating the ribs (Mikulicz's rib-retractors being serviceable for this purpose), the lung can be pushed aside with a special spatula and the œsophagus identified by the introduction of a bougie. The pleura covering it is then incised, and the whole thickness of the œsophagus, from which the nerves and vessels have been freed, is grasped with forceps and pulled forward. Having packed off the surrounding parts with gauze, the œsophagus may then be opened in its long axis, after which the mucous membrane is seized with Kocher's forceps, so that it may be subsequently recognised and invaginated with Lembert's sutures. The muscular coat of the œsophagus is sutured with silk and the wound closed or, if necessary, drained as described in section (*d*). Sauerbruch plugs the œsophagus with a tampon, which later on is passed into the stomach.

89. Transpleural Œsophago-gastrostomy (Biondi and Sauerbruch). Sauerbruch regards this operation as suitable for short-circuiting the lower part of the œsophagus in cases of diverticulum, stricture, and possibly carcinoma.

The pleura is opened and the œsophagus exposed as described above, but the posterior layer of the parietal pleura is not divided. The diaphragm is displaced downwards and the lowest part of the œsophagus grasped with forceps and pulled up, taking care not to include the vagi. The part of the diaphragm covered by pleura and peritoneum is seen (in the dog) as a greyish-white area about 2 to 3 cm. wide. A fold of the pleura is now incised, and after the edges of the diaphragm have been grasped the incision is enlarged and the stomach pulled up.

Sauerbruch performs the anastomosis with Murphy's button in the following simple and ingenious manner: The female portion of the button is first passed down the œsophagus by means of an œsophageal bougie, and, guided by the finger and thumb, is conducted into the part of the fundus of the stomach which has been pulled up, and is there provisionally fixed.[1] The male half (plugged with gauze) is then passed from above and tied into the œsophagus. Then, without detaching the pleura, it is made to project against the anterior wall of the œsophagus while an assistant makes an opening large enough to allow it to protrude. The same method is adopted with the half in the stomach, which is closed by the finger of the operator, and the two halves are pressed into one another.[2] The fundus of the stomach is thus anastomosed with the œsophagus. The diaphragm is carefully stitched round the stomach, so that no hernia of the latter may occur.

90. Transpleural Resection of the Œsophagus (after Sauerbruch). In this operation Sauerbruch adopts one of two methods depending on whether the disease is situated high up or low down in the œsophagus. In the former case :—

(*a*) *The Invagination Method.* The œsophagus is exposed as above, but the posterior layer of pleura is divided, the œsophagus isolated, and the vagi are freed, so that they may not be invaginated with the œsophagus. The portion of the œsophagus to be excised is then raised up by passing a piece of gauze behind it.

The diaphragmatic pleura, the diaphragm and peritoneum are incised at the œsophageal opening and the fundus of the stomach is pulled up, in the manner described above. The portion of the œsophagus to be resected is now invaginated into the stomach as completely as possible (without the vagi), uniting the muscular wall of

[1] If a stricture prevents the passage of the button down the œsophagus, the button must of course be inserted through a direct incision into the stomach, where it is to be fixed with a purse-string suture.

[2] Sauerbruch smears the edges with Lugol's solution, for the same reason as Tiegel soaks his sutures in chloride of iron, viz. to produce stronger adhesions between the serous surfaces.

the former to the serous and muscular coats of the stomach with a circular suture, after which the cone of stomach is fixed all round the opening in the diaphragm, and the external wound is closed.

After ten to fourteen days the abdomen is opened, the stomach drawn out and opened, and the conical mass inside cut off with "Cooper's scissors."

(*b*) When a higher resection is required, the œsophagus is exposed, the vagi are isolated and the stomach is pulled up into the thorax as before. The œsophagus above and below the tumour is crushed with crushing-forceps, ligatured in the grooves thus produced, and the portion containing the tumour is cut away, care being taken to pack off the surrounding parts with gauze pads and to avoid injuring the vagi. The mucous membrane is cut away, and in the case of the upper end, the muscular coat of the œsophagus is stitched over the stump, while the lower end is invaginated into the stomach and a layer of sutures superimposed.

The female half of a Murphy's button is then fixed into the summit of the stomach cone, while the male portion is passed down the œsophagus and the anastomosis made at a point on the anterior wall of the œsophagus, *which is still covered by pleura*, in exactly the same way as was described in œsophago-gastrostomy.

91. Contraindications to Transpleural Œsophagectomy. Resection of the œsophagus with anastomosis to the stomach can only be performed when the part of the tube excised is situated below the hilum of the lung. Malignant disease, according to Schmid and Sauerbruch, is most frequently met with in this situation (70 per cent) and the latter author points out that in 35 per cent of these cases no metastatic growths could be discovered at the autopsy.

When a carcinoma involves the upper part of the œsophagus or the vicinity of the root of the lung, no surgical interference should be considered; at the most, posterior mediastinotomy may be performed. In the latter case, the method advocated by Quènu, Hartmann, Tuffier, and Faure gives ample room. It entails the resection of the posterior ends of the first five or six ribs.

End-to-end union of the œsophagus with sutures should never be attempted from in front as it is invariably unsuccessful. The operation of œsophagoplasty, devised by Mikulicz and Sauerbruch, is more deserving of consideration. Here, the divided ends of the œsophagus are brought to the surface some distance apart, sutured to the skin at convenient spots, and the wound is closed. When the wound is healed, two skin flaps are dissected up and turned inwards like a folding door so as to form a tube lined by epidermis. Finally the mucous membrane of each open end is freed along with a collar of skin and sutured to both ends of this newly formed œsophagus. Later on the tube can be replaced inside the mediastinum by bringing the soft parts over it. Roux has suggested an even more ingenious plan of manufacturing a new œsophagus out of a portion of intestine.[1]

D. ABDOMINAL SURGERY

(a) Laparotomy

92. Indications and Conditions necessary for Success. Operations on the abdomen have become the most brilliant field of operative surgery. There is no longer any organ in the abdomen which is not accessible to surgical treatment. Where expectant treatment in acute affections (ileus, inflammations, etc.) may be fraught with danger or result in a chronic condition, early surgical interference may save life and bring about a rapid cure. In chronic affections (adhesions, dilatation of the stomach, gall-stones, etc.), where months are required before medical treatment results in any success, an operation may immediately and permanently remove the whole trouble.

[1] *Semaine médicale*, 1907.

It is every day becoming a more pressing necessity that practitioners should recognise the almost absolute safety of opening the abdomen. We should then no longer have to complain that so many valuable lives are lost from appendicitis, that cases of ileus are recommended for operation only after ulceration of the gut has set in, and that cases of carcinoma of the stomach and intestines are not sent for surgical treatment until the presence of innumerable diseased glands renders radical operation impossible. We do not at all desire to see the practice of diagnostic exploratory laparotomies extended. At the present time, especially amongst the younger generation, there are only too many doctors who prefer to save themselves the trouble of making an exact diagnosis by opening the abdomen in order to obtain information as to the indications for, and contraindications to, operative interference.

But when it is a question of imminent danger to life, or when an apparently definite diagnosis has been arrived at (*e.g.* perforation of the stomach and intestine, acute circumscribed peritonitis and all cases of ileus), or where there is a suspicion of a malignant growth in the stomach or intestines, procrastination on the part of the practitioner is, in the present state of abdominal surgery, culpable. The patient should not be allowed to pass through months of medical treatment without showing any material improvement, or without the physician being able to hold out the assurance of a satisfactory result by non-operative treatment.

Were the advantages of early operation more fully recognised, surgeons would not be called upon to operate on so many cases in which peritonitis and sepsis have practically precluded all chance of recovery.

It is not necessary that all medical men in practice should undertake the surgical treatment required, but it is essential that they should be thoroughly acquainted with what surgery can accomplish. A proper surgical knowledge enables one to recognise the indications which call for energetic measures, and makes one feel the responsibility of inactivity. A hundred times more harm is done even now by delay than by operative faults.

To open into the peritoneal cavity was looked upon till recently as a procedure fraught with danger on account of the risk of setting up inflammation. Now, however, it has become quite evident that the peritoneum, as long as it is healthy, is possessed of a far greater tolerance of infection than the majority of the tissues. When the surgeon sees that injuries of the abdomen, attended with prolapse of coils of intestine for hours, may result in uninterrupted recovery, he loses his fear of opening into the abdominal cavity in healthy individuals, even though the procedure should involve the pulling out of the intestines. In contusions, in perforating injuries of the abdomen, and in cases of ileus, early laparotomy and examination of the viscera proves often the best and most speedy mode of bringing about recovery, provided that the principal part of the operation is performed on healthy peritoneum. Early operation in acute appendicitis has, moreover, shown how confidently recovery can be expected when inflammation is localised.

To open the peritoneal cavity exposes the patient to serious danger only when the peritoneum is the seat of a diffuse infective condition, or when other organs in the body are sympathetically involved owing to toxic influences. The surgeon even yet finds himself much too frequently forced to operate after diffuse peritonitis (which might have been avoided by earlier interference) has set in. In such cases an operation must perforce be performed, to remove, if possible, the immediate dangers, but the unsatisfactory results which follow in these cases should in no way be regarded as a measure of the success nor of the indications for laparotomy in suitable cases, but should be considered in a different category.

We must now consider a few of the secrets of success in laparotomy.

(1) Special stress must be laid on the preparation of the patient (*vide* General Introduction), and the advisability of emptying the gastro-intestinal tract two days before operation and of maintaining this condition by suitable diet (free administration of fluids and limitation of solids) is of the utmost importance. The prophylaxis of aspiration-pneumonia and the necessity of raising the blood-pressure (by stimulants or possibly saline infusion, or [according to Kümmel] by transfusion) have also to be

carefully considered. In the case of an alcoholic patient, Kümmel allows half a glass of brandy before the operation.

(2) Elevation of the pelvis. This is easily provided for in operations in the region of the hypogastrium and pelvis by means of the "Trendelenburg" position, but for operations in the mesogastrium or epigastric regions, *e.g.* stomach, gall-bladder, and kidney, local elevation of the back can be employed with advantage. It is essential that a heated table should be used to keep the body warm.[1]

(3) In all cases where it is not certain that the organ to be operated on can be as easily drawn out of the abdominal cavity as, *e.g.*, a movable appendix, an ovarian tumour, a movable tumour of the intestine, or the gall-bladder, etc., the incision must be made sufficiently large to allow of the organ being freed and delivered and the surrounding parts packed off.

(4) As soon as the abdominal cavity is opened, the healthy regions of the abdomen should be packed off from the field of operation with gauze swabs. When the disease is in an organ that can be brought out of the wound this can be easily accomplished, but it is of even greater importance to pack thoroughly all round when the disease is deeply placed. Warm sterile soft gauze compresses wrung out of ·75 per cent salt solution should be used to isolate the field of operation, as they will absorb any escaping fluid such as blood, gastric contents, bile, urine, or exudates.

(5) Avoidance of any antiseptic, and of any possibility of injury to the peritoneum by cooling and evaporation. No small praise is due to Tavel and his pupils for having demonstrated experimentally the nature of this deleterious action, and for having rendered its avoidance possible. On the basis of their researches we were probably the first to employ (chiefly in laparotomies) only physiological salt solution at the body temperature, and to keep all exposed peritoneal surfaces constantly moist and warm by the application of compresses covered with gutta-percha tissue.

(6) Thorough removal of every source of infection,[2] and drainage of infected areas, combined with their isolation by tampons in the form of gauze strips impregnated with a fixed antiseptic, as recommended by Mikulicz. As iodoform has so strong a toxic action on the peritoneum, xeroform or vioform is to be preferred. Special care should also be taken that any gauze not lifted straight from the steriliser be wrung out of carbolic lotion so as to remove any possible surface infection.

(7) Prevention of any collection of blood or effusion in the wound by careful arrest of hæmorrhage, for as long a period as is necessary, and by suture of every injured peritoneal surface. In some exceptional circumstances a raw peritoneal surface may have to be left, and this may give rise to an accumulation of blood or serum; when this occurs a tube should be passed down to the place and the fluid removed by suction. This is an important point, and it was only when attention was paid to it that the intraperitoneal treatment of a uterine stump was rendered safe.

Tietze showed by his excellent experiments that the omentum could be safely employed for covering over necrotic areas in the stomach or intestinal wall. Braun and Bennet even closed defects in the stomach with omentum only, which formed firm adhesions to the surrounding serous membrane. The inner surface of the omentum gradually becomes covered over with epithelium which grows in from the edges of the opening.

(8) Careful suture of every cut or tear in the peritoneum, and complete closure of the main wound, except where an opening is left for drainage. A "cigarette drain" keeps the opening patent, while the wrapping of rubber tissue protects the surrounding structures and the contained xeroform gauze absorbs the secretion; or a drainage tube may be employed, to which a suction apparatus, like a large cupping-glass, is attached. (*Vide* von Kelling on the "Technique of Abdominal Surgery," *Centralbl. f. Chir.* Bd. 4, 1904.)

(9) In the after-treatment of a laparotomy, free respiratory movements are to be

[1] Henle has shown by the statistics of a large number of authenticated cases how frequently pneumonia follows laparotomy, and he has come to the conclusion that a chill during the operation in the presence of a small source of infection is chiefly responsible for such a mishap.

[2] See remarks on previous page.

encouraged by breathing exercises (morphia, by reducing the pain, has a beneficial action); the passage of flatus is procured by stimulating peristalsis by means of an intestinal tube and glycerine suppositories, while the blood-pressure is sustained by subcutaneous saline injections.

93. Position of Incisions and Methods of Suture in Laparotomy.—The only incisions in the abdomen which can be regarded as normal are the median, the transverse in the upper part of the abdomen, and the oblique incision passing from above downwards and inwards in the lower part of the abdomen, because these incisions do not damage the muscles of the abdominal wall through their nerve-supply, and are in accordance with the principles which have been already laid down for all the normal incisions of the body. The above normal incisions can be very well used in combination, as, for instance, in splenectomy, or for carcinoma of the lowest part of the sigmoid flexure when to the median incision a transverse incision may be added, varying in length according to the requirements. Assmy, at Czerny's instigation, showed that the longitudinal incisions through the middle of the rectus, which are preferred by many surgeons, cause atrophy of the median portion of the rectus if its motor nerves be interfered with.[1]

Why is a substitute for the median incision constantly being sought? The chief reason is that it is regarded as pre-eminently predisposing to ventral hernia, while cosmetic considerations supply another reason. Since laparotomy is nowadays so very common (specially in gynæcological cases), a desire has manifested itself to hide the scar on the abdomen. Küstner and Pfannenstiel, in cases where a large incision is unnecessary, have endeavoured to avoid both disadvantages by the "transverse incision above the symphysis." They make the incision close to the pubis so that the scar is hidden by the hair, just as surgeons have long been accustomed to do to reach the bladder. But the chief value which Küstner, in opposition to Pfannenstiel, attaches to his procedure is that he not only divides the skin and superficial fascia transversely, but also the aponeurosis of the abdominal muscles along with the linea alba. Pfannenstiel has pointed out that below the semilunar fold of Douglas all three abdominal muscles unite in front of the rectus, and that posterior to it there is only the fascia transversalis. For this reason the aponeurosis in front of the recti, along with the linea alba, can be separated upwards in the form of a flap with lateral attachments. The abdomen can then be opened by separating the recti and dividing the fascia transversalis and peritoneum by a median longitudinal incision. The separated aponeurosis is afterwards sutured above the symphysis, thus forming a protection against hernia.

This question of ventral hernia is closely associated with asepsis and suturing. If a surgeon cannot use buried sutures without the fear of stitch abscesses (Jonnesco), then he must certainly take special precautions to give firmness to the scar when the temporary sutures are removed. Those who are not sufficiently certain of their asepsis to bring themselves to employ permanent sutures, but who rely on absorbable catgut for buried sutures, can never hope to obtain as firm a closure of a wound as can be got with a buried organic non-absorbable suture. Herein lies the secret for preventing ventral hernia. We must confess that to us it is an anachronism to hear the gynæcologist's constantly reiterated complaint of suppuration in buried sutures, and of ventral hernia from the giving way of sutures, the latter accident occurring only with catgut. Will surgeons not be influenced by Madelung's report at the last surgical Congress in Berlin on a hundred and one cases where sutures in the abdominal wall had given way, and desist from using catgut?

We always use silk for the sutures, because it gives a more durable mechanical support. This may appear to be unnecessary as far as the peritoneum is concerned, since it adheres and heals quickly and easily; and it might even be contended that permanent foreign bodies tend rather to predispose to the formation of adhesive tissue. For suturing the peritoneum alone catgut or silk may be used. Below the level of the umbilicus we do not consider it desirable to suture the peritoneum alone: the

[1] Blair has made extensive investigations with regard to the best means of sparing the abdominal nerves.

fascia transversalis should always be included with it, as it is not worth stitching the latter separately. In the region of the navel the peritoneum is so intimately blended with the linea alba and the cicatricial tissue round it that it is much better to include it along with the aponeurosis of the linea alba.

For suture of the principal aponeurosis (linea alba) a non-absorbable material is required. This aponeurosis (which forms the chief support to the abdominal wall against hernia) must be firmly united with permanent sutures—either silk or metal. To most people metal sutures left in permanently are very unpleasant, although Witzel and, following him, Goepel have even used buried meshes of silver wire to strengthen the line of suture. Even that excellent invention, aluminium bronze wire (Socin),[1] gives a very unpleasant sensation of a foreign body. Silk is therefore the only desirable material. We have no experience of the new collodion-thread introduced by Witzel and Wederhake.

We hold that absolutely sterile silk cannot be any guarantee against the subsequent formation of a stitch abscess. The difficulty is rather to keep sterilised silk sterile till the wound is healed. It is so easily infected anew by the hands, by the patient's skin, and by bacteria from the wound. The result of this is the formation of stitch abscesses, but nothing more. In the chapter on "Wound Treatment" we have explained why we always use antiseptic silk. This suture material is quite sufficient, even in an incision in the linea alba, if a carefully applied continuous suture be inserted to prevent gaping and hernia formation. The only occasion when exception may be made is when the fascia, before operation, is stretched and thin, with separation of the recti. Such cases are very suitable for overlapping the recti. The deep silver sutures, recently recommended by Küstner, may also be employed. Even though the suturing be perfect, the occurrence of suppuration renders it uncertain as to whether a ventral hernia will or will not form, but the chances are in favour of the hernia resulting.

In spite of this decided opinion—which materially simplifies the question of the best abdominal incision—we consider it justifiable to attempt to obtain increased firmness along the line of suture. A very good plan is to make the incision through the sheath of one rectus, and displace the entire muscle outwards. The rectus should not be split, as Howitz proposes, as this of necessity causes atrophy of the internal part which is cut off from its motor nerve-supply. The method which Lennander and Wolkowitsch recommend is better, namely, to divide the anterior wall of the sheath of the rectus muscle, to draw the rectus *in toto* to one side, and then to open the abdomen through the posterior wall of the sheath. This posterior wall is thin, and offers little resistance in the lower part of the abdomen. When the operation is concluded, the posterior wall of the sheath is first closed, the rectus replaced and sutured along its inner border, and then the anterior wall of the sheath is closed. This method of suturing the abdominal wall we have already recommended in gastrostomy.

We consider that Lennander's incision is specially indicated in place of the mesial incision where there is marked separation of the recti, as the latter depends entirely for its strength on the firm closure of the separated muscles.

In lateral ventral hernia Carl Beck has also employed this method of strengthening the abdominal wall by means of a plastic operation on the muscle. He divides the rectus muscle in the frontal plane and folds over the anterior layer into the gap with its nerve-supply intact.

In employing this method of displacing the rectus muscle, we have solved the difficulty of how to strengthen the scar by making use of muscular tissue whose nerve-supply is not damaged. In dealing with the choice of incisions in general, we drew attention to the progress made in this direction by non-division of the muscles, even though the skin incision be at right angles to the course of their fibres, but by simply splitting the muscular bundles and pulling them forcibly apart. In this manner injury to the nerves can be avoided with certainty, and it is unnecessary to divide the muscles in a direction opposed to the course of their fibres. It is possible to expose a large area of peritoneum by separating the muscular fibres of the

[1] Pfannenstiel declares that the "French" introduced this substance. It was Socin, in conjunction with Hägler, who introduced it into practice.

internal oblique and transversalis muscles through an incision parallel to the fibres of the external oblique. In this way, also, incisions may be carried obliquely upwards and inwards, as well as paramesially. Transverse division of the rectus need not be feared as the rectus has a metameric nerve supply in successive segments.

If Minxewitsch is right in saying that a suture which traverses the whole thickness of the abdominal wall is firmer than an "Etagenaht" (suturing in layers), then the method proposed by Pozzi, recommended by Depage, and frequently used by others, should receive some consideration. It combines the advantages of both, and should be particularly suited to the advocates of catgut. The peritoneum alone (or peritoneum and transversalis fascia) is sutured, and then silver wire or aluminium bronze sutures are passed through the whole of the remaining thickness of the abdominal wall and tied, after the aponeurosis (linea alba) has been separately united by buried sutures. Minxewitsch speaks in favour of the method we have recommended above, as he finds that the union is most satisfactory when the incision has been made in the middle line, and when silk has been used for the sutures.

With regard to incisions in the lateral regions of the abdomen, it is only rational that they should be parallel to the course of the nerves in the abdominal wall. When more room is desired, a mesial incision may be added so as to form a flap. It is sometimes necessary to incise the soft parts across the line of the nerves in order to obtain better access, and in these cases any nerves lying on the transversalis must be hooked upwards and downwards, as Blair has so clearly illustrated. For the less serious cases of appendicitis requiring operation, Lennander prefers the vertical incision through the sheath of the rectus. He draws the nerves of supply upwards and downwards, while the outer border of the rectus is drawn towards the middle line.

94. Complications after Laparotomy.—Next in importance to peritonitis, which is the most common complication of laparotomy, we must consider paralysis of the stomach and intestines, and pneumonia. Thrombosis and embolism, and hæmorrhage from the stomach or intestine, are also serious post-operative complications, but depend more on the nature of the interference with the special viscera.

Acute dilatation of the stomach is an exceedingly grave symptom, unless recognised early and relieved by passing the stomach tube. Its origin is, however, not quite clear. Kelling found, from experiments on animals, that dilatation of the stomach may follow the establishment of a gastric fistula under chloroform, and Braun produced the same condition by section of the vagus nerves. Injury to the muscular wall of the stomach seems to have an important bearing in its production, while it may also be caused by reflex disturbance of the circulation. Lastly, obstruction of the duodenum by the superior mesenteric artery must not be forgotten. Further light on the question can, however, only be obtained by experimental research. Suffice it to say that in the after-treatment of abdominal operations the possibility of the distension being due to dilatation of the stomach should always be kept in mind, and steps should at once be taken to empty the stomach.

Distension of the intestines is also frequent after laparotomy, and is generally due to the fact that flatus is not passed. According to careful observations made by Pankow (Jena), in the majority of cases no flatus is passed on the first day after operation, and only by a few on the second. This cannot be wholly explained on the ground of inflammatory reaction; further knowledge can only be gained by accurate observation and experiments.

It is also well known that interference with the circulation or injury to the nerves of the intestine may give rise to paralytic distension, but remedies applied in this direction, *e.g.* physostigmin or eserin, only produce definite results in a certain number of cases. Along with Vogel[1] we have seen remarkable results follow the administration of physostigmin or eserin in non-inflammatory cases in which all other treatment had failed.

Pankow, on the other hand, maintains that he could not prove that 1 mg. ($\frac{1}{64}$ gr.) of eserin sulphate caused any passage of flatus, but in our experience we have almost always been able to observe, in half an hour, the effect on the intestines

[1] *Deutsche Zeitschr. f. Chir.* Bd. 63, 1902.

of a decimilligramme of physostigmin ($\frac{1}{600}$ gr.) given once or twice daily. Colicy pain and definite peristalsis are produced.

While we are as yet more or less ignorant of the real primary causes of the after-effects of abdominal operations, from the practical point of view, we do know the conditions which favour so-called paralysis of the gut, and can avail ourselves of measures to prevent it.

Active decomposition of the intestinal contents further contributes to abdominal distension, but this only occurs when the contents of the bowel become stagnant. It is generally admitted that steps must be taken to prevent the possibility of decomposition occurring either before or after operation, by the use of the rectal tube, glycerine suppositories, and aperients such as magnesium sulphate.

We must remember that as an immediate consequence of diarrhœa there is an increase in the number of bacteria in the intestine, and a diminution again when the intestine is thoroughly emptied.

We agree with Pankow that it is a mistake to give an aperient the day before operation and *a fortiori* on the morning of operation, for the operation is then performed at the period when the bacterial activity of the intestine is at its height. We do not, however, like Pankow, omit preliminary purgation on this account, but we ensure evacuation of the bowel two days in advance. On the evening before operation we administer an enema, followed by frequent small doses of bismuth to diminish the production of gas by restricting the development of intestinal organisms.

We do not starve our patients, but allow solid food in the form of meat and a free supply of fluids up to the last day. Diet likely to cause flatulence is avoided.

Hæmorrhage from the stomach or intestines after laparotomy is rare, but has been observed and reported in several cases since v. Eiselsberg first drew attention to it.

The source of the bleeding in some cases, but not in all, can undoubtedly be traced to erosions or ulcerations of the mucous membrane, and v. Eiselsberg regards them as retrograde embolisms from veins, although it is still undecided how often this is the case.

To prevent the occurrence of these ulcers it is important that the circulation of the intestine should be interfered with as little as possible, by avoiding all unnecessary bruising, handling, or constriction by clamps. We regard the use of clamps as directly responsible for thrombosis and embolism, though they are convenient from other points of view. More attention than hitherto should be paid to this question in investigating the causes of post-operative hæmorrhage.

Obstructive distension, due to impairment of the heart's action caused by the operation, must also be mentioned. The extreme Trendelenburg position, so much employed by gynæcologists, must be regarded as a factor in impairing the circulation in prolonged operation, and should be avoided.

Finally there is the question of poisoning. We believe that the preliminary preparation of the patient with corrosive sublimate, which, though superfluous, many surgeons will not abandon, is really the prime agent in the production of erosions of the mucous membrane of the stomach and intestines.

Pneumonia and other pulmonary complications have already been mentioned, as post-operative sequelæ. They are very frequently met with after abdominal operations, and especially after operations on the upper part of the abdominal cavity, as in the latter breathing is more seriously interfered with, owing to the pain caused by contractions of the diaphragm.

Aspiration pneumonia is the commonest form, and is due to aspiration while under the anæsthetic, or to the fact that pain renders deep breathing or coughing impossible.

This form of pneumonia can be considerably influenced by treatment, and Kümmel and Rotter have diminished its frequency by the use of scopolamin and morphia. Morphia after the operation, according to Friedrich, has a beneficial effect on respiration. Hypostatic pneumonia is less common, and is due to disturbances of circulation resulting from the position of the patient and interference with respira-

tion. In this connection Kraske justly emphasises the disadvantages of exaggerated elevation of the pelvis.

The second variety, according to Kelling, is infective pneumonia. Payr has shown that even slight infection may readily cause the entrance of organisms into the lymphatics of the thorax. Embolism is of no less importance, and is all the more certain to give rise to inflammation if of an infective character.

Payr has drawn attention to the fact that the onset of thrombosis in the omental or mesenteric veins can occasionally be recognised even during the operation by a bluish discoloration of the intestine as well as of the omentum. Its results (bleeding from the stomach and intestines due to retrograde embolism) can be prevented by free resection.

Payr has given histological proofs that a number of these thromboses do not originate in purely mechanical causes but are due to an inflammatory infiltration round the veins, as, for example, occurs when the omentum is adherent to the appendix in cases of acute perityphlitis. Kelling believes that when there is lymphangitis of the mesentery the inflammation spreads by retroperitoneal veins, and gives rise to thrombosis and embolism in the systemic circulation. Gebele,[1] who affirms that aspiration-pneumonia occurs in 6·3 per cent of all abdominal operations, states that embolism in the liver is exceptional, owing probably to anastomoses between the portal system and the vena cava.

95. Laparotomy in Cases of Peritonitis.[2] Removal of the cause should be the first object in operating for peritonitis. The following general remarks, however, are directed specially to those cases where the cause cannot be removed or discovered, and where the peritonitis has to be treated *per se*.

Like other acute inflammatory conditions, peritonitis is at first usually localised (peritonitis circumscripta), although sometimes it originates simultaneously in more than one situation. Lennander has rightly observed that the exudate may be limited by adhesions or be free. If a localised collection of pus is not removed thoroughly or at an early stage it will extend and set up a diffuse peritonitis.

Whenever, therefore, a circumscribed exudate is diagnosed or suspected, steps should be at once taken to remove it. Acute appendicitis is always systematically treated on this principle, and the brilliant results are attributed to the removal of the diseased appendix before definite abscess formation has occurred.

How is this first rule to be satisfactorily carried out? The suppurative focus must be reached with a minimum of injury, and since Lennander's investigations on the insensibility of the intra-abdominal organs we have successfully employed local anæsthesia for this purpose. The position of the abscess having been determined by the dullness and tenderness on pressure, a small incision is made over it through skin and fascia, after which the muscles are split by M'Burney's method, and retracted. The parietal peritoneum is then picked up with forceps and a small incision, which is subsequently enlarged with a pair of artery-forceps, is made into it.

A glass tube is inserted down to the bottom of the cavity, and aspiration-drainage is established by attaching a suction apparatus to it. When aspiration is not practicable, a cigarette drain (M'Cosh), which consists of a central wick of xeroform gauze disinfected with carbolic lotion and wrapped in a cylinder of guttapercha tissue,[3] may be used after carefully washing out the cavity with normal saline solution. When the drain is removed, iodoform and glycerine should be dropped into the cavity.

What further treatment is necessary when the local process has spread and given rise to diffuse peritonitis (peritonitis diffusa)?[4] Here different types must be distinguished :—

[1] *Beitrag z. klin. Chir.* Bd. 43.

[2] See the latest publication on the treatment of peritonitis read at the International Congress of Surgeons at Brussels, 1905, with Reports from Friedrich, Krogius, Lennander, Lejars, M'Cosh, and De Isla.

[3] Similar forms of drainage may be employed, *e.g.* Lennander's thick wood-wool wick, wrapped in guttapercha, and Drensmann's glass drain. The latter has no terminal opening, but is perforated at the sides and contains a strip of gauze.

[4] The terms "diffusa" and "circumscripta," used in contradistinction to each other, are in common use and are quite intelligible.

(1) When there are numerous small foci of pus scattered throughout the abdomen but individually shut off (peritonitis diffusa saccata), the treatment is similar. Each focus must be dealt with through a separate incision and drained as described.

Whenever, in addition to general symptoms of peritonitis, a suppurative focus can be diagnosed by pain and dullness, it must be immediately opened through a small incision and drained in the manner described above.

(2) The second form is that in which there is diffuse peritonitis with a progressive effusion which extends so as to invade successive regions of the abdominal cavity (peritonitis diffusa libera). This is found, especially in pneumococcal peritonitis of children, in cases where there is infection with bacillus coli, and after rupture of certain abscesses (cholecystitis).

In these circumstances the first and most important indication is to evacuate the pus at all points where its presence can be proved. Multiple small incisions should be made, and drainage tubes inserted into the pouch of Douglas, in each lumbar region, just above Poupart's ligament, and in both the subphrenic spaces below the costal margin.

Only prompt and vigorous measures can avert disaster. We have successfully dealt with cases of acute suppurative general peritonitis following high excision of the rectum by inserting drainage tubes above both groins and below the costal margins.

It is essential to know how the different regions of the abdomen can be most advantageously drained.

In women the pouch of Douglas is best drained through the posterior fornix of the vagina. The vagina should be purified in the same way as the skin, after which the abscess is punctured, the mucous membrane incised, the opening enlarged with forceps, and a glass drain inserted. A long rubber tube is then attached to this and led into a vessel containing carbolic lotion. Syphon action is thus obtained, or an aspiration apparatus may be attached to the rubber tubes. The glass tube is kept in position by plugs of iodoform gauze.

In men the recto-vesical pouch is drained by an incision immediately above the symphysis pubis (the bladder having been emptied), and through this a glass drain is passed down to the bottom of the pouch, with aspiration drainage.

The iliac fossæ and the regions of the ascending and descending colon are drained by an incision similar to that used for typhlitis (*q.v.*), *i.e.* by an incision two fingers'-breadth above the outer part of Poupart's ligament, into which glass tubes are inserted obliquely, one towards the middle line and the other directly upwards, followed by aspiration drainage.

Drainage of the recess under the diaphragm, liver, and spleen is discussed under the treatment of subphrenic abscesses. An incision is made in the posterior axillary line, just below the costal margin, and glass tubes are inserted, one directed upwards between the liver (or spleen) and the diaphragm, and the other directed inwards above the colon under the liver and spleen. In many cases we reach a subphrenic abscess more easily from the front by an incision near the outer border of the rectus, 1 cm. from the costal margin, splitting the fibres of the external oblique and transversalis and their fasciæ.

A cigarette drain may be substituted for a glass tube if the latter is likely to prove harmful.

When there is a collection of pus in the region of the pancreas above and below the stomach, a mesial incision should be made above the umbilicus and two drainage tubes inserted one above and one below the stomach, the latter being passed through the gastro-colic omentum.

When several incisions have to be made, if the general condition of the patient is satisfactory, an injection of morphia should first be given, followed by light ether anæsthesia assisted by local anæsthesia.

(3) The third form is when the peritonitis is diffuse, but nowhere has the fluid collected in sufficient amount to be recognised clinically and evacuated.

Lennander draws special attention to the fact that the absence of all pain makes the diagnosis of "central" peritonitis very difficult. The term "peritonitis diffusa

sicca" might be applied to this form, but it is already employed in reference to a class of cases of a less serious nature.

The treatment of this variety of peritonitis is the same as that of the preceding ones (1) and (2). If drainage of the septic fluid in the abdominal cavity is not effective, the important question must be considered of relieving the toxæmia from the decomposing intestinal contents by emptying the bowel.

Enterotomy and enterostomy are new departures in the treatment of peritonitis, and are based on the theory that the distension is due to an increased bacterial activity inside the bowel associated with decomposition of the contents, the toxines of which are absorbed by the lymphatics, thereby causing infection of the peritoneum. The latter condition is often strikingly demonstrated by the occurrence of fæcal vomiting.

According to Lennander, distension of the gut is chiefly due to the action of the toxins on the plexus of Auerbach (between the longitudinal and circular coats), which paralyses the muscular coats of the bowel and permits the toxines to penetrate through the lymphatics of the serous coat.[1] Even apart from the toxic action on the nervous mechanism, it is obvious that the peristaltic action of the muscular coats must be greatly interfered with by infiltration and œdema.

Besides "primary" paralysis of the intestine, which, like peritonitis diffusa sicca, depends on the absorptive power of the serous coat, we must take note of the distension that occurs from a mechanical obstruction at a point where inflammatory exudate and adhesions have been found. This is frequently observed by post-mortem examination, and along with Mikulicz we have often seen it occur in living subjects. The distension in such cases has therefore the same origin as mechanical ileus.

Stercoræmia (the term applied by Lennander to the toxæmia due to absorption of the contents of the bowel), must be treated by thorough removal of the intestinal contents, and in frequent lavage of the stomach we have a method the value of which is not sufficiently appreciated. On several occasions we have seen serious toxic conditions disappear very rapidly after washing out the stomach. A rectal tube should also be passed, and if this fails to procure a passage of flatus, the rectum and colon should be irrigated (through a T tube) with warm saline. If there is still no result, and a kink in the large intestine is present, Lennander advises making a fæcal fistula at once in the cæcum according to Witzel's method. The opening can also be used for feeding the patient.

The timely administration of suitable aperients has already been alluded to, but they are usually given too late, and, as Heidenhain has shown, they are only of use when there is no obstruction present. All parts of the intestine which cannot be reached from the natural orifices should be emptied, either by puncture or incision.

After the abdomen has been opened, an incision, ½ to 1 cm. in length, should be made in the transverse axis of the intestine (to avoid the blood-vessels). The edges are then grasped with Kocher's artery-forceps, while the intestine is gently "milked" between the index and middle fingers of the hand, protected by a rubber glove. The entire length of intestine may be emptied in this manner, for which purpose Dahlgren has devised a double spring roller. When the bowel is emptied the small wound in the intestine may be closed if no further accumulation is expected. In this connection it is, of course, taken for granted that no food is administered by the mouth.

This should be the routine procedure in all cases in which the abdomen has been opened for the treatment of peritonitic obstruction of the bowel. When, however, the source of the peritonitis cannot be removed, few surgeons will carry out the principle so far, in case the patient cannot bear the shock of so severe an operation.

Every surgeon has had the melancholy experience of seeing patients who have been handed over to him in a state of collapse rapidly sink after "correct" treatment, by freely opening the abdomen and removal of the original cause as well as the exudate and decomposing intestinal contents.

When "inflammatory obstruction," as it has been called by Heidenhain, occurs in a patient with advanced cardiac weakness of septic origin, a temporary enterostomy should be made instead of enterotomy, as is done in similar circumstances in mechanical ileus.

[1] For this assumption Lennander refers to statements of Askanazy, Waldeyer, and Magnus.

Enterostomy, *i.e.* the production of a fæcal fistula, can be rapidly performed in one or more places under local anæsthesia. We refer to it in the chapter on intestinal surgery.

Escher [1] was the first to demonstrate the advantage of enterostomy in severe cases of typhoid peritonitis. Haffter [2] and Heidenhain [3] have established the procedure, and Greenough [4] has collected a mass of material to illustrate its value and demonstrate its technique. That eminent surgeon Lennander advocates enterostomy in three places (above, below, and in the region of the injured gut) in all cases of extensive injury of the bowel. M'Cosh, on the other hand, holds that a temporary enterostomy is seldom beneficial. Why is there this difference of opinion? Because the same class of cases is not compared, and similar technique is not employed. Enterostomy in peritonitis has as its object the removal of the septic contents of the bowel when they cannot be removed otherwise, and is only performed when the absorption is severe and threatens life. In the worst cases evacuation of the intestines is of vital importance, and a series of recent excellent results we attribute to the combined removal of peritoneal and intestinal infection.

The question whether it is better to freely open the abdomen and perform an enterotomy with subsequent closure or drainage of the wound, or to make several small incisions in the intestine, depends firstly on the condition of the patient, and secondly on the prospect of being able to remove simultaneously the cause of the peritonitis and the peritoneal foci of infection.

Technique.—The simplest method consists in making a small incision in the abdominal wall, and fixing a loop of bowel to the parietal peritoneum and fascia transversalis. After the loop has been incised a rubber tube may be inserted and xeroform gauze packed round it. By this method, however, it is difficult to avoid soiling the wound, and it is therefore better to conduct the contents away by fixing a drainage tube into the intestine, according to Witzel's method, and suturing the tube to the abdominal wall; or a glass tube may be fixed into the bowel by means of a purse-string suture, including the parietal peritoneum and deep fascia (*vide* chapter on "Fæcal Fistula," Greenough's use of the Mixter tube). For the small intestine the lumen of the tube adopted need not be greater than $2\frac{1}{2}$ to 3 mm.; for the large intestine it must be 5 mm. thicker, and stronger.

After-treatment.—All food must be withheld as long as the bowels do not act freely, and the practice of giving milk and pieces of ice is to be condemned as injurious. Water should be freely administered under the skin (2 to 4 litres per day of physiological saline: if there is much collapse, it may be given intravenously).

Nothing combats the danger of inanition, heart weakness, or toxæmia so effectively as the free administration of water, and in this connection Sahli has drawn special attention to the benefit derived from "washing out the body." Friedrich's subcutaneous feeding by injections of oil (up to 200 g.) and grape sugar (5 per cent in physiological saline) is only to be resorted to when the condition is protracted and the evacuation of the intestine is delayed. Enterostomy openings may be employed for the injection of fluid nourishment after twenty-four hours.

When the inflammatory and obstructive stages have been overcome, a severe form of diarrhœa (spreading ulceration) occasionally occurs, a condition which, according to Lennander, is best treated through the enterostomy openings.

Fowler considers that the position of the patient is of the utmost importance in the treatment of peritonitis, especially after drainage, and he advocates the adoption of a more or less sitting posture with the thighs flexed, so that the pus may gravitate to the bottom of the peritoneal pouch.

96. Laparotomy in Abdominal Tuberculosis. In opening the abdomen for the treatment of tuberculous peritonitis, our object is not merely to remove the exudate, but also to discover the organ from which the peritoneum has become secondarily infected. Indeed, the onset of tuberculous peritonitis is a favourable occurrence in that it draws attention comparatively early to the presence of a tubercular process which is limited

[1] *Grenzgebiete*, Bd. 11, 1903.
[2] Gebhard, *D. Zeitschr. f. Chir.* Bd. 74.
[3] Busch, *D. Zeitschr. f. Chir.*, 1902.
[4] Harvard University, September 1904.

to one of the abdominal organs, and affords an opportunity of removing it at the proper time.

The Fallopian tubes are the organs from which most commonly tuberculous peritonitis originates. But the primary source of infection may be found in the intestine or the vermiform appendix.

Operation, therefore, has the definite object of removing the primarily-diseased organ, even if there is uncertainty in the diagnosis as to which organ is diseased.

It takes the form of a large median exploratory incision, with evacuation of the exudate, and thorough irrigation with 0·8 per cent salt solution at the body temperature.

The abdominal organs are next examined as far as the adhesions, which are often numerous and strong, will allow, and the source of infection, be it in the Fallopian tubes, intestine, or appendix, should be removed by excision of the entire organ.

It is of the utmost importance to avoid the slightest chance of introducing sepsis, for no greater disaster can befall the patient than the occurrence of mixed infection with staphylo- or strepto-cocci. The strictest aseptic precautions must be taken, and the use of sterilized rubber gloves is absolutely indicated.

Drainage is not desirable as it may lead to secondary infection. It is occasionally necessary, however, to pack the wound after the fluid is removed, in order to prevent any oozing that may occur from accumulation, but we must be very certain that the iodoform or vioform gauze used is thoroughly disinfected (*e.g.* in 5 per cent carbolic). It should be removed as soon as possible, and the antiseptic dressings should be frequently changed to prevent infection during the period of drainage.

The cavity may with advantage be swabbed out with iodoform and glycerine (2 to 5 per cent), or it may be filled with the mixture, using 50 to 100 g. Vioform has also been found of use in promoting the disappearance of peritoneal tubercles.

Extensive cases, in which the parietal peritoneum and the intestines generally are thickly studded with tubercles, can be completely cured by laparotomy and removal of the primary focus. Lauper has successfully cured cases of this nature in our clinic.

97. Laparotomy for Peritoneal Adhesions. Lauenstein emphasised the excellent results which can often be obtained in cases of severe pain and spasms in the region of the digestive tract by opening the abdomen and simply separating adhesions which fix the viscera to some particular spot on the abdominal wall, or which link or bind them together. The importance of this condition has not been fully appreciated. The results of such an operation are often striking and immediate, and relief may be given to suffering which has been endured for years.

We recently operated on a patient who suffered from attacks of pain, attended with so much collapse that the question of perforation was considered, more especially as there was a history of previous ulceration. Laparotomy was performed, and a strong adhesion to the lateral aspect of the abdominal wall divided. The whole of the symptoms disappeared. The agony had been so intense that the patient dreaded taking food, and in consequence was very much emaciated.

No directions for operation suitable for every case can be given. The adhesions must be completely divided in order to ensure perfect freedom of movement of the viscera, and, where possible, large raw areas must be covered over with healthy peritoneum. If it is the case that silk, being a permanent foreign body, is more liable to cause adhesions, preference must be given to catgut, which is easily absorbed.

Tavel has recently described cases where troublesome symptoms, due to adhesions in the region of the colon after appendicitis, at once disappeared on dividing the adherent bands. We have frequently observed similar cases where persistent pain has been removed by dividing adhesions, which are often as thin as a thread, between the intestinal coils or between the intestines and the abdominal wall or neighbouring organs.

(b) Operations for Hernia (Herniotomy)

98. Radical Cure of Inguinal Hernia. (*a*) *Radical Operation in Uncomplicated Inguinal Hernia.* Since the last edition we have had our list of hernia operations revised and brought up to date, with the object of obtaining a correct estimate of the efficiency of our method of performing radical cure [1]; as these observations extend over a period of five years, we consider we are justified in referring to them as permanent cures.

The results are highly satisfactory. In his comprehensive work on radical cure of inguinal hernia, Pott [2] states that Kocher's method gives the best percentage of permanent cures (92·5 per cent), while of the others, Bassini's is next with 89·8 per cent. Brenner has investigated 1073 cases in which radical cure was performed and found that Kocher's method showed 92·5 per cent of cures compared with 90·1 per cent by Bassini's. Daiches, from a total of 508 cases operated on between 1895 and 1900, states that the percentage of permanent cures by the lateral transposition method is 95·5; while in our own clinic at Berne we obtained 97·7 per cent of cures in 173 cases between the years 1896-1900 with the transposition-invagination method.

These figures, which refer to the operation in the adult, are distinctly better than those obtained from other methods. The results of radical cure in children should not be regarded in the same light as those in adults, for at the present time a large number of children are submitted to early operation in order to avoid the necessary supervision and the inconvenience of a truss, although the hernia would probably be cured without operation. In children, therefore, the proportion of cures is very large, but the mortality is relatively high. Campbell calculates the mortality at about 3 per cent, while, according to Buhlmann, out of 117 radical cures in children, Tavel had eight deaths, of which only one, however, was directly due to the operation.

Our patients have been almost exclusively adults, and, unlike a number of other surgeons, we undertake the radical cure at an advanced age, *e.g.* seventy, if the patient is in other respects a healthy subject. The tendency to complications is naturally greater in elderly people, *e.g.* embolism, etc.

The high standard of our results must not be attributed to the fact that, being the originator of the method, we have devoted personal attention to the subject: indeed, the majority of the operations in our clinic are performed by temporary assistants or by practitioners who have been taught the exact technique of our method. Equally satisfactory results are obtained by surgeons elsewhere. Deanesly [3] reports 95 per cent of permanent cures after two years' observation in 142 patients at all ages by Kocher's method. Hahn [4] published the results of radical operation in 221 cases of inguinal hernia in Rydygier's clinic; 7·8 per cent of recurrences occurred after the Bassini-Postempsky method, and only 4·9 per cent after Kocher's method. Grosse,[5] in Landerer's clinic, has observed very little suppuration after Kocher's operation, and no recurrences, while a relatively large number of recurrences were noticed with Bassini's method. Even the most flattering statistics [Franz and Rotter (689 cases)] give only 95·6 per cent of radical cures by Bassini's method, while Carle (Galeazzi) out of 601 operations had 5·99 per cent of recurrences by Bassini's method and 5·02 per cent by Kocher's. Angerer and Trzebicky also publish excellent results.

On the ground, therefore, of our long personal experience and the evidence furnished by the results of others, we can justly claim for our transposition method that it gives the best results as regards permanency of cure in uncomplicated inguinal hernia, that it is easily and quickly performed and is devoid of danger.

The operation may be performed under local anæsthesia (Cushing), with or without the administration of ether.

[1] Inaugural Dissertation von P. Daiches, Leipzig, 1904.
[2] Pott, "Sammelstatistik von 23,519 Radikaloperationen," *Deutsche Zeitschr. f. Chir.* Bd. 70, 1903.
[3] *Brit. Med. Journ.*, June 1905.
[4] *Deutsch. med. Wochenschr.*, 1904, No. 8.
[5] *Deutsch. Zeitschr. f. Chir.* Bd. 57.

An incision,[1] $2\frac{1}{2}$ to 3 inches long, dividing the skin and superficial fascia, is made in the groin from a point a finger's-breadth above the centre of Poupart's ligament to a point one inch internal to the external abdominal ring. In the centre of the wound the superficial epigastric artery is divided and a vein at the inner angle of the wound is also ligatured (Fig. 312).[2]

The pillars of the ring are defined by blunt dissection, and the thin prolongation of the external oblique on to the cord, viz. the external spermatic or Cooper's fascia, is incised in a downward direction, exposing underneath it the cremasteric and the infundibuliform (transversalis) fascia.[3] The latter coverings are also incised, care being taken to avoid injuring the spermatic vessels and nerves.

When the infundibuliform fascia is divided, the hernial sac can be isolated from the constituents of the cord[4] from the external ring downwards; the fundus is then

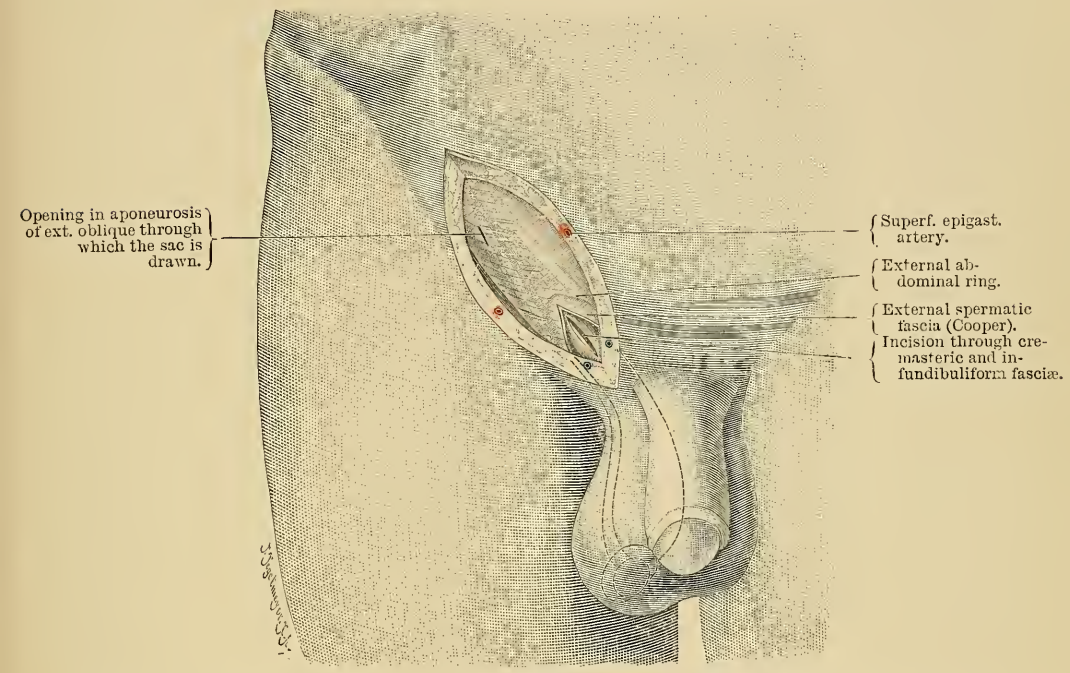

FIG. 312.—Incision over inner half of Poupart's ligament, exposing in the subcutaneous fat the divided superficial epigastric artery and a constant vein. The aponeurosis of the external oblique and the pillars of the ring are exposed, the external spermatic fascia (Cooper) has been divided, and a vertical incision has been made through the cremastric and infundibuliform fasciæ down to the spermatic cord.

grasped and forcibly pulled downwards, exposing the highest part of the sac, off which the cord is stripped with gauze dissection.[5]

[1] In previous editions we described an inguinal incision which was also used for castration and the treatment of hydrocele and varicocele, etc. Separate incisions are now described.

[2] It is quite unnecessary to prolong the incision upwards over the internal abdominal ring.

[3] If local anæsthesia by Cushing's method is employed, a second injection of novocain is now given, the needle being passed from the external ring up the inguinal canal and downwards into the coverings of the cord.

[4] By holding the cord up to the light, the sac can be easily recognized.

[5] If the funicular process is continuous with the tunica vaginalis testis, *i.e.* vaginal hernia, the sac should be ligatured and divided, the lower part being returned into the scrotum. In the female the operation is more simple: the round ligament should not be divided as in Bassini's method, but should be separated from the sac and preserved in the same way as the spermatic cord.

The next step depends on whether or no the sac can be easily invaginated into itself from below. In the former case[1] the sac is treated by transposition and invagination; in the latter[2] by simple lateral transposition. It is first necessary, however, to reduce the contents of the sac.

Transposition by Invagination.—The Transposition-Invagination Method (*vide* Figs. 313, 314, 315) is the most effective. The fundus of the sac is grasped by a pair of curved narrow dressing-forceps (with toothed ends similar to Kocher's artery-forceps) and invaginated backwards through the inguinal canal, keeping the points

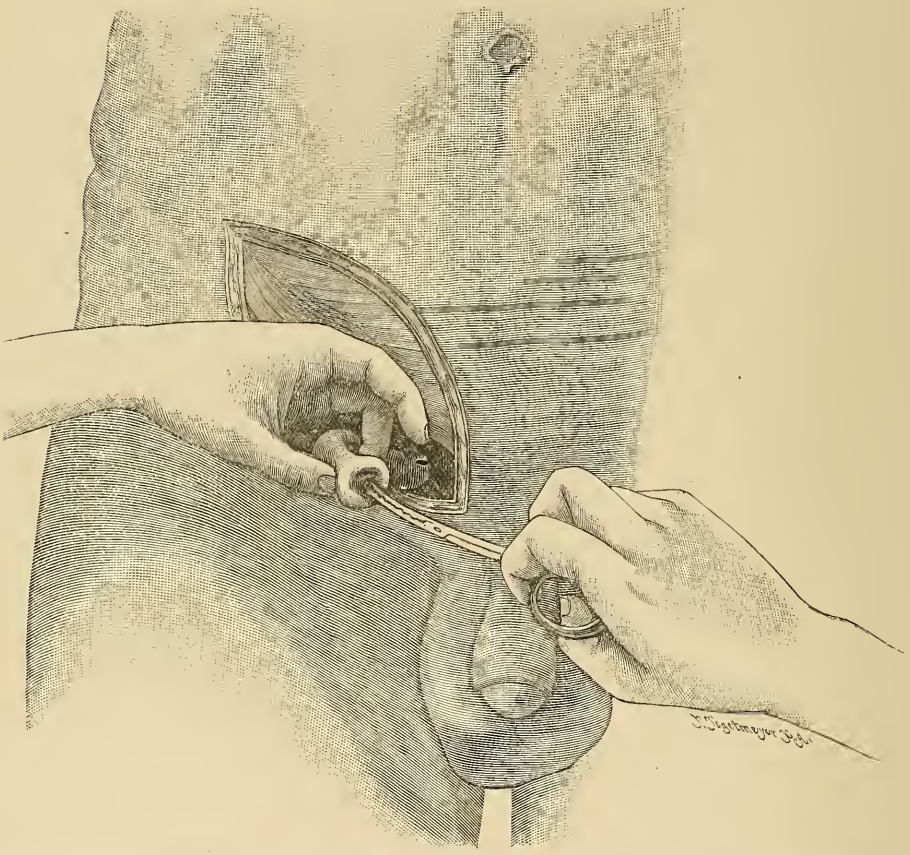

FIG. 313.—Radical operation for external inguinal hernia by invagination-transposition. The isolated hernial sac is seized at its apex with curved forceps and invaginated into itself as far as the posterior end of the inguinal canal.

of the forceps close behind the anterior wall until they reach the internal abdominal ring, where they are caused to project forwards.[3]

A small incision is made through the external oblique aponeurosis at this point and the nose of the forceps pushed through, covered by the parietal peritoneum, which is then incised, the edges being caught in artery-forceps. The apex of the

[1] In an ordinary uncomplicated adult hernia this is practically always possible.

[2] In children invagination is often difficult, as the sac is sometimes very short and thin.

[3] The most common mistake is that the forceps are not kept close enough to the anterior wall of the canal, and that they are pushed too high up towards the anterior superior spine of the ilium. It is only by a gross mistake of this sort that it is possible to injure the intestine or to nip it between the invaginated sac and the parietal peritoneum.

sac is now seized with artery-forceps and the curved dressing-forceps are loosened and withdrawn from the canal. The whole length of the inverted sac, the serous surface of which is turned outwards, is forcibly drawn up (Fig. 315), its neck

Fig. 314. Fig. 314*a*.

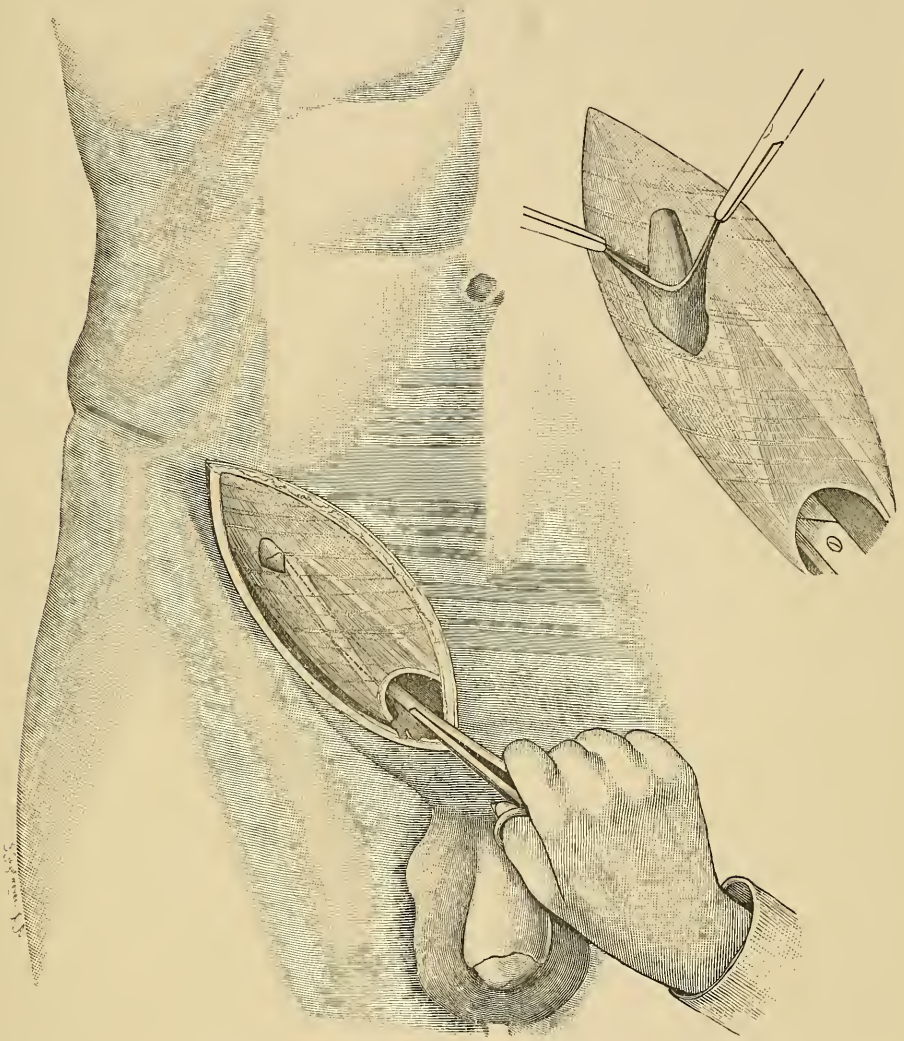

Fig. 314.—The invagination-transposition method. The point of the forceps forces the apex of the invaginated sac directly outwards from the internal inguinal ring towards the anterior abdominal wall. A small incision is made over the prominence so caused through the external oblique aponeurosis and the deep abdominal muscles.

Fig. 314*a*.—The parietal peritoneum is shown divided, its margins held apart, and the inverted hernial sac pushed through.

transfixed, and firmly ligatured at the opening in the aponeurosis and divided, the stump being allowed to slip back. The small opening in the parietal peritoneum and in the aponeurosis is then closed with a stitch and the canal sutured (*vide infra*).

Lateral Transposition.—When the sac cannot be invaginated either from its

shortness, tension, or thinness, or because it is advisable to remove it entirely, the apex of the sac is simply grasped with curved forceps and pushed up the inguinal canal immediately behind its anterior wall as far as the internal abdominal ring, where, as described above, it is protruded through a small opening in the aponeurosis and forcibly pulled out.

As the sac has not been invaginated, the parietal peritoneum in this case is not opened. The neck of the sac is ligatured with strong thread close to the slit in the aponeurosis, the sac itself is cut off, and the stump allowed to retract inside the abdomen. The small opening in the aponeurosis is then closed, and finally the canal is sutured.

The inguinal canal is closed in the following manner:—A series of interrupted

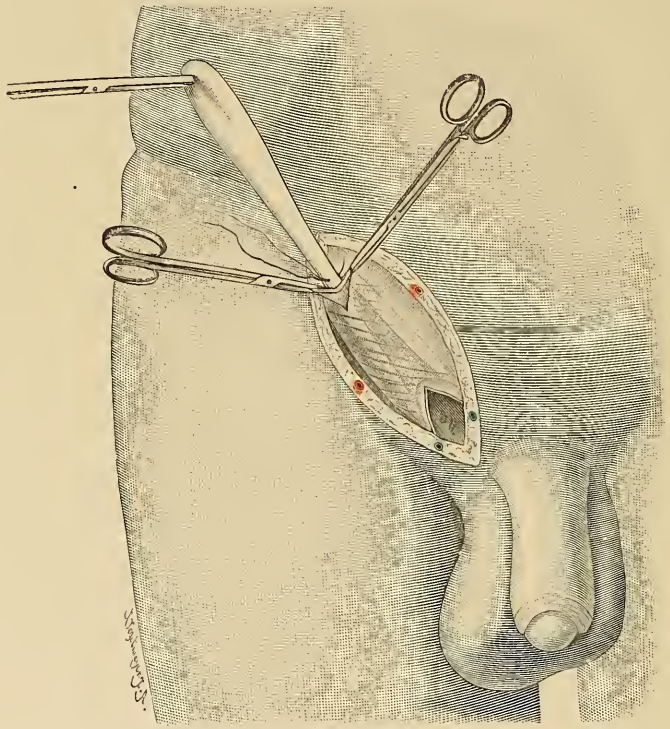

FIG. 315.—The transposition-invagination method. The sac has been invaginated and pulled out through a small opening in the aponeurosis of the external oblique muscle, close to the internal abdominal ring. The edges of the parietal peritoneum are seen held apart with two pairs of artery-forceps, while the base of the sac has been transfixed with a needle, preparatory to ligaturing and cutting it across.

sutures is introduced beneath the aponeurosis of the external oblique where it forms the anterior wall of the inguinal canal, and the portion thus in the grasp of the suture is then depressed with the finger, so that when the sutures are tied two parallel folds are approximated as seen in Fig. 317. Two to four sutures are then inserted so as to bring together the pillars of the ring, care being taken that when they are tied the circulation in the cord is not interfered with.

We always place a strip of gauze in the wound before inserting the continuous suture in the skin and only remove it when the last stitch is being inserted. The gauze prevents the accumulation of blood in the wound. Drainage is quite unnecessary and may even prove injurious.

We cannot conceive why, in face of the excellent results obtained with the transposition method, surgeons should employ methods which are less reliable and more complicated.[1]

Recurrence is due either to a fault which ought to be overcome, or, as we have already mentioned, to the fact that catgut is used for the sutures. The sutures should always consist of a non-absorbable material and the best of all is good silk. Those who are continually looking for a substitute to take the place of silk know that no material can give as good a guarantee for asepsis; and further, a fair comparison can only be made between the methods in which non-absorbable sutures are used.

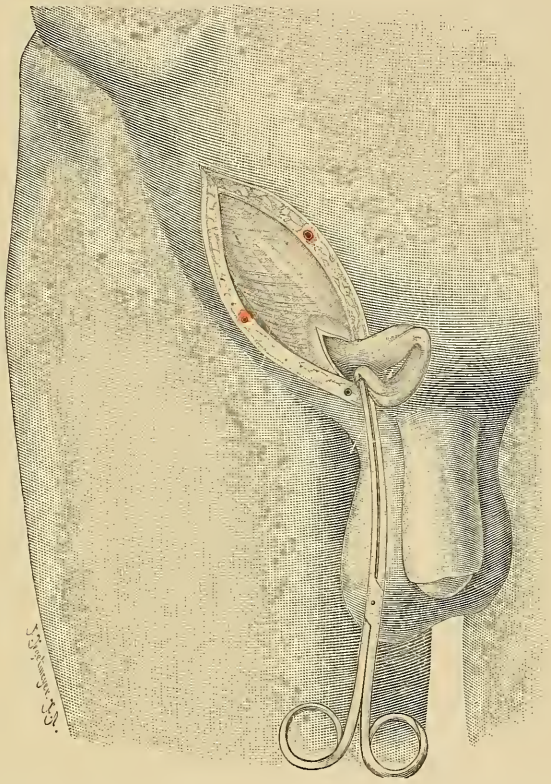

FIG. 316.—The lateral transposition method. The sac is here shown isolated and seized with curved forceps, preparatory to being pushed up the inguinal canal and brought out through a small opening in the aponeurosis of the external oblique, close to the internal abdominal ring.

(*b*) *Complicated Inguinal Hernia.*—Strangulation and inflammation without strangulation are the conditions which most usually complicate the operation of radical cure. In a strangulated hernia the sac must be opened and the contents examined: this must also be done when chronic inflammatory adhesions have formed between the sac and its contents, as, *e.g.*, in an old-standing omental hernia. In addition the sac itself may have undergone changes which may necessitate its removal, *e.g.* in a strangulated hernia, or when chronic inflammatory thickening and adhesions have made transposition impossible. In these circumstances one cannot do better than have recourse to the operation which we are accustomed to record in our registers

[1] From an investigation of a series of cases in Madelung's clinic P. Bernhard concludes that Kocher's method is the one most suited for uncomplicated inguinal herniæ which are not of long standing. Baratynski is of the same opinion.

as the "old method," since it is the method on which the radical operation was first based. Lucas-Championnière has made extensive use of this method, while Czerny and Socin have done excellent service in bringing it to its present state of perfection.

The Old Operation.—This consists in isolating the neck of the sac, ligaturing it as high as possible and dividing it, with subsequent closure of the canal. As already mentioned, it gives as good results as any other method in an uncomplicated case, and is, moreover, very simply performed.

Its simplicity is a strong argument for its use in children, and it may even be employed instead of the transposition method. There is certainly no advantage in Bassini's more complicated method, which Coley and others advocate for children, for admirable results are obtained with this simple process by Tavel and Stiles. Klemm finds it difficult in many cases to separate the sac on account of its close connection with the spermatic cord, and prefers not to remove the sac, but to open and evaginate it, subsequently fixing it to the cord.

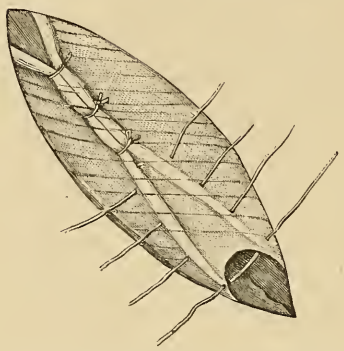

FIG. 317.—Strengthening sutures for the anterior wall of the canal in position and partly tied.

In infants the simplest form of operation is the best. This consists in freeing the sac right up to the external ring, after dividing the infundibuliform fascia, and applying a silk ligature as high as possible by pulling the sac forcibly downwards. The canal is subsequently closed, or the pillars of the external ring may be simply sutured together (Tavel). We do not doubt for a moment that in children as brilliant results can be obtained by this operation as by Bassini's method and its modifications.

Bassini's Method and its Modifications.—The chief feature to which Bassini's operation owes its popularity is the fact that the whole length of the inguinal canal is laid open by dividing the aponeurosis, or even the muscular fibres of the external oblique muscle, as is done in the treatment of an incarcerated hernia.

By slitting up the canal in this way the relations of the sac are at once made clear, and by pulling on it the highest part of the neck can be readily exposed and ligatured. It is the most convenient routine method, and its use avoids the necessity of considering special treatment of individual cases.

For strangulated hernia, and hernia complicated by inflammatory thickening or adhesions, it must be admitted that Bassini's operation is the one to be preferred. For, by splitting up the sac and the entire anterior wall of the canal as far as the internal ring, omental adhesions can be easily separated, and the sac exposed at a point beyond where the adhesions or thickening exist.

It is quite another question whether, instead of fortifying the anterior wall of the canal by sutures in the simple manner we have described, it is necessary to strengthen the deeper layers of the canal as Bassini does, and at the same time displace the cord. The answer is furnished by statistics. If an operation such as our transposition method, in which the aponeurosis is not divided and in which the anterior wall only is strengthened by sutures, gives results which are not only as good as but better than those obtained by the disciples of Bassini, the obvious conclusion is, that *suture of the deep layers is not necessary for the radical cure of an ordinary inguinal hernia.*

We therefore consider it a matter of indifference as to the method by which the deep strengthening sutures are applied. In Bassini's[1] method the spermatic cord is laid upon the sutured canal and lies immediately under the aponeurosis of the external oblique muscle. Ferguson[2] attributes the cause of the hernia to an imperfect

[1] Langenbeck's *Archiv*, 1890.

[2] *Centralbl. f. Chir.*, 1904, No. 13, and *Jour. of Amer. Med. Assoc.*, July 1899.

attachment of the broad deep abdominal muscles to Poupart's ligament. He therefore first of all stitches the fascia transversalis round the cord, and then sutures the internal oblique and transversalis muscles to Poupart's ligament *in front of* the cord.

Hoffmann[1] applies a purse-string suture round the neck of the sac at the internal ring and stitches the internal oblique and transversalis muscles to Poupart's ligament with silver wire (Drahtnetz-Ringnaht), without further closing the canal. He believes "that merely obliterating the sac is sufficient to cure a hernia." Wölfler employs Ferguson's modification of Bassini's operation and in addition overlaps the external oblique aponeurosis.[2] Polya (Herczel) turns down a flap from the anterior sheath of the rectus, and uses it to strengthen the canal posteriorly.

Fergusson and Hoffmann in their modifications of Bassini's method do not consider it essential for success to follow Bassini's original treatment of the posterior wall of the inguinal canal, for it is quite certain that suture of the united aponeurosis of the internal oblique and transversalis, and the portion, which Bassini describes as fascia verticalis Cooperi, to Poupart's ligament is not always so easily accomplished, and that sutures inserted too deeply may lead to complications (*e.g.* thrombosis of, or even hæmorrhage from, the femoral vein).

We therefore only employ Bassini's method when there is strangulation, when the sac is much thickened, or when the contents are adherent to the sac: it is also suitable for a direct hernia, and for a hernia of very large size. Clinically, the latter, up to a certain stage, may be regarded as a direct hernia.

The essential points of Bassini's operation are: (1) The aponeurosis of the external oblique is divided throughout the entire length of the inguinal canal and the neck of the sac defined, the sac itself being also slit up when the hernia is strangulated, when there are adhesions at the neck, or when the hernia is direct. (2) The contents are reduced[3] and the sac is transfixed, ligatured, and cut off. (3) The spermatic cord is displaced upwards, while the internal oblique and transversalis muscles with the transversalis fascia are sutured to Poupart's ligament as high up as the internal abdominal ring. (4) The cord is then replaced and the aponeurosis of the external oblique sutured over it.

(*c*) *The Radical Cure of very large Herniæ.* Madelung[4] has drawn attention to the difficulty in treating very large herniæ. They cannot be classified with uncomplicated herniæ in respect to prognosis. A hernia larger than a man's head, whether scrotal or omental (specially following laparotomy) possesses peculiar features. The contents are irreducible and the intestines are often so matted together that they either cannot be separated from the sac except with the knife, or the adhesions between the coils cannot possibly be detached, while the prolapsed portion of intestine may be so large that it is impossible to find room for it in the abdomen.

If there is a choice, it is often best to avoid operation, and to rest satisfied with the relief afforded by a suspensory apparatus. When any one has let his hernia grow to such dimensions, he may be allowed to keep it. Often, however, no choice is left, as more or less acute symptoms of strangulation have driven the patient to seek advice. These cases may result in death with extraordinary rapidity, and we have seen one patient with a very large hernia die four hours after the first symptom of obstruction.

Operation must be undertaken without delay and should take the form of a hernio-laparotomy. The sac and its coverings are freely slit up and the nature of the adhesions or constrictions, especially about the neck, is determined. Often the neck has to be slit open to allow of reposition of the intestines.

Constrictions or kinks in the prolapsed intestine should be freed, and all omental

[1] *Centralbl. f. Chir.*, 1904, No. 19.

[2] Slajmer has published 1202 of Wölfler's cases. There were no deaths, but we are unable to find the number of radical cures stated in reports which we have been able to examine.

[3] Ball twists the neck of the sac before removal just as Wood and Macewen endeavoured to obtain a resistant cushion by plicating the sac. Bassini occasionally employs torsion. Jaklin has used torsion as a modification of our transposition method. We do not consider it necessary, and it may even cause necrosis of the stump.

[4] Langenbeck's *Archiv*, Bd. 74, 1904.

bands or adhesions divided; or, when this is impossible, and the patient's condition will allow, the question of performing an enteroanastomosis inside the sac, or resecting the mass, has to be considered.

When the bowel has been freed as much as possible an attempt may then be made to reduce the hernia *en masse*, the ring at the same time being enlarged. If this proves successful, the bowel may be kept in place with gauze pads until the radical cure is completed. When, however, the intestinal coils cannot be reduced, they should be protected by suturing the soft parts, the sac and its coverings over them.

Closure of the ring in the ordinary way is frequently impossible when the hernia is a very large one. A plastic operation must then be employed, and flaps consisting of muscle, fascia, or periosteum must be utilised for closing the ring. A suitable flap can be secured from flaps composed of the rectus muscle and the anterior wall of the sheath. Half the thickness of the rectus is divided transversely a hand's-breadth above its origin from the symphysis pubis and turned down along with the sheath, and fixed with sutures in the hernial aperture.

It is often better, in very large herniæ, to sacrifice the testicle in order to get a more secure closure of the hernial opening, or, according to Bernhard, the testicle may be reduced along with the herniated gut.

No single operation, however, can be regarded as a routine safe procedure. The skilful surgeon should be able to modify the operation to suit special cases and should not rely on any one method for every case.

99. Radical Cure of Femoral Herniæ. In his review on 23,519 cases of femoral hernia, Pott states that the best results are obtained with the old Czerny-Socin operation (already described under Inguinal Hernia), which consists in ligature and removal of the sac with suture of the ring. The percentage of radical cures, however, is only 71·6. It is obvious, therefore, that the conditions of femoral hernia and inguinal hernia are not analogous. The smaller percentage of radical cures, compared with inguinal hernia, teaches us that it is absolutely necessary to divide the sac high up, and that we should utilise all the coverings to strengthen the cure and not, as Hoffmann advises in inguinal hernia, remove them.

In the case of femoral hernia, one can only obtain this support to a very limited extent, while in the inguinal region a broad supporting wall can be produced by extensive closure of the canal. In femoral hernia everything depends on the closure of the hernial aperture after high removal of the sac, an easy process on account of the shortness of the crural canal. The femoral ring, through which the hernia is transmitted, is bounded by the femoral vein externally and by Gimbernat's ligament internally. The former of these structures must not be compressed or in any way narrowed. We have therefore to endeavour, as it were, to prolong Gimbernat's ligament artificially as far as the vein, and to make it as resistant as the natural ligament. Here, again, it is in our opinion absurd to treat all cases indiscriminately by one method. While simple suture is all that is required in the case of a small hernia, more complicated methods are necessary when the rupture is of large size.

(*a*) *Radical Cure of ordinary small and medium-sized Femoral Herniæ.* The incision corresponds to the inner third of Poupart's ligament, and divides the skin, superficial fascia, and the portion of fascia lata which covers the saphenous opening, namely the cribriform fascia. The sac, together with the fat covering it, is then freed by blunt dissection.

By stripping the fat off the sac, the latter can be readily isolated up to the crural ring, through which it has emerged, having pierced or pushed forward the septum crurale and the fascia transversalis which is situated between the femoral vein and the sharp outer border of Gimbernat's ligament. After reducing the contents, the sac is ligatured as high up as possible and removed.

When the sac cannot be freed high enough up, it is best dealt with by transposition and invagination. The contents having been reduced, the apex of the sac is seized with curved "transposition-forceps" and invaginated, the point of the forceps being passed upwards immediately behind Poupart's ligament on to the anterior abdominal wall, and made to project through an incision (4 mm. long) in the outer

pillar of the external abdominal ring. The sac is then forcibly pulled out with artery-forceps, transfixed at its base, ligatured, and removed in the same manner as was described in inguinal hernia. The stump is buried (*vide* Fig. 318), and the small opening in the aponeurosis closed with a suture.

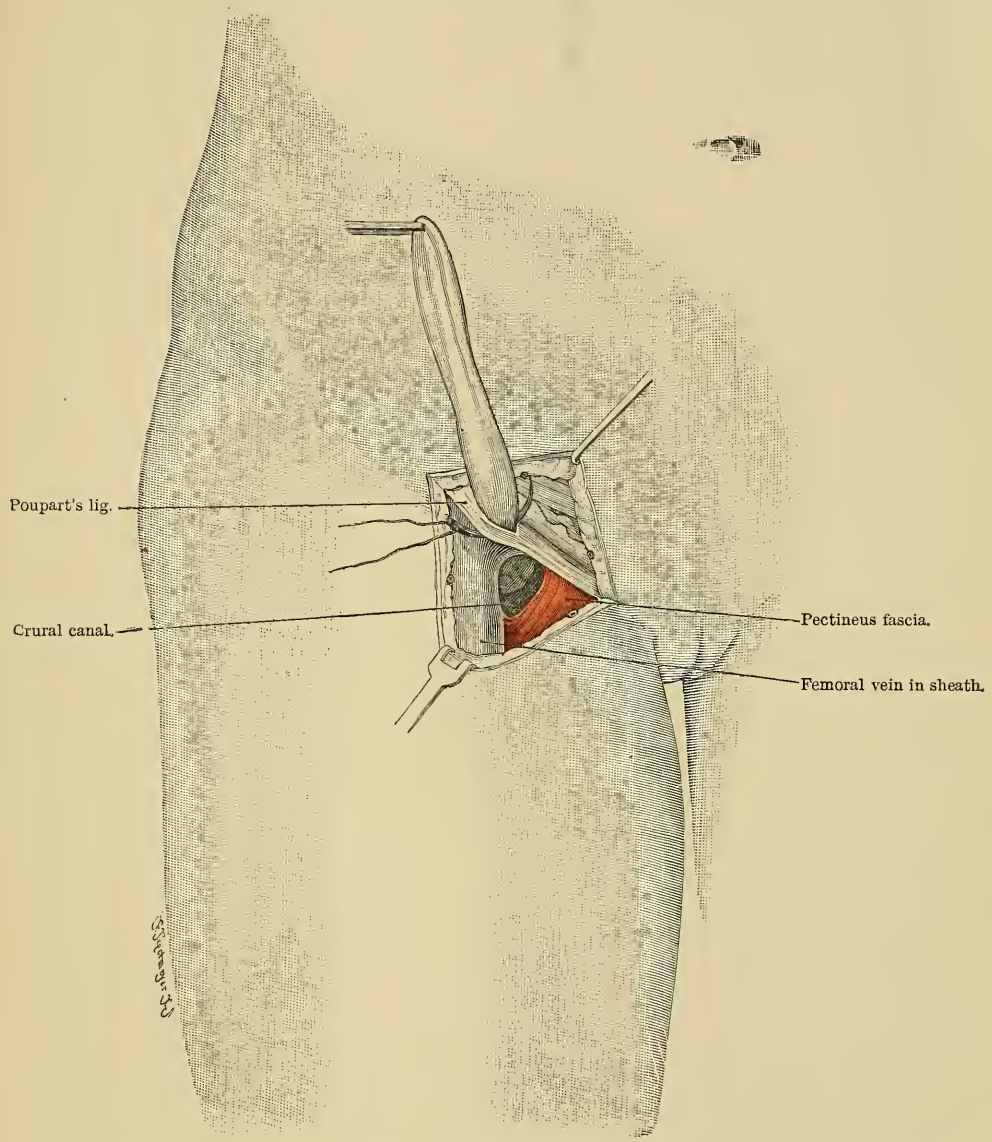

FIG. 318.—Transposition method in radical cure of femoral hernia. The sac is pulled upwards and outwards through the outer pillar of the external abdominal ring. The needle is incorrectly represented passing through Poupart's ligament. This may be seen more correctly by referring to Fig. 315, representing inguinal hernia.

Closure of the ring is the next step. Having defined the inner border of the femoral vein so as to avoid injuring it, a short stout curved needle threaded with strong silk is passed down to the pectineal eminence so as to include the pectineal

fascia and the deep crural arch (ligament of Cooper), *i.e.* a strong layer of fascia which is prolonged outwards from Gimbernat's ligament. By pulling on this stitch one ascertains if it is holding firmly, and if a second suture is necessary, it should also be passed right down to the bone before the first suture is tied.

The needle is then passed upwards through Poupart's ligament, and the suture or sutures firmly tied. In this way the innermost portion of Poupart's ligament is fixed to the pectineal fascia and the femoral ring securely closed, Roux employing a staple for this purpose and driving it through Poupart's ligament into the pubis. We have always found that pins driven into bone eventually tend to become loose, but experience alone must decide whether by the time it is loose, the soft parts are sufficiently firmly united.

(*b*) *Radical Cure of large Femoral Herniæ.* When the hernia is of large size, a plastic operation is required to close the crural canal.

Bonsdorff divides Poupart's ligament at a point opposite the femoral vessels, and turns down a pointed flap consisting of the muscles and fascia of the abdominal wall, which he sutures to the fascia covering the horizontal ramus of the pubis. This method is, however, only applicable to women, where the round ligament may be divided.

Goebel employs a method originally introduced by Mikulicz, in which an incision is made down on to the bone from the pubic spine internally to the femoral vessels externally. The periosteum is then detached and reflected upwards and downwards in the form of flaps, which are sutured to the anterior and posterior borders of Poupart's ligament.

Sprengel goes still further and closes the crural canal from its abdominal aspect through a laparotomy wound. The apex of the sac is grasped with forceps passed from within, instead of from outside as in our method, and the sac is invaginated, coiled up, and stitched along with the round ligament to the abdominal surface of the crural ring.

Polya also uses a plastic operation and closes the crural canal with a portion of the sartorius, over which he stitches a three-cornered flap of the fascia lata (sartorius fascia). The simplest method, however, must always be regarded as the best. When it is impossible to suture Poupart's ligament to the pectineal fascia and periosteum, we would suggest detaching Poupart's ligament from the pubic spine and Gimbernat's ligament from the ilio-pectineal line subperiosteally and displacing them outwards, so that the sutures can be easily introduced and the canal securely closed as far out as the vein.

100. Radical Operation for Umbilical and Ventral Herniae.—(*a*) *Radical Cure of ordinary non-adherent small and medium-sized Umbilical Herniæ.* A transverse incision is made as a rule above the umbilicus, as the skin at the lower border of the umbilicus is more difficult to separate owing to its intimate connection with the urachus and obliterated hypogastric arteries than at the upper border where the obliterated umbilical vein (ligamentum teres) is transmitted.

After dividing the skin and subcutaneous fat, which is often very plentiful, the edges of the ring should be at once exposed. The upper edge is first defined, in order to divide the fibrous prolongation on to the sac, which, as Tavel[1] correctly points out, is here not adherent to the sac, as it is in the neighbourhood of the umbilical cicatrix.

When this thin layer of fascia, which is analogous to the infundibuliform fascia in the inguinal region, is carefully divided the sac is exposed, and should be thoroughly separated all round by further dividing this fascial covering. The hernial sac can now be pulled forward, covered by fascia and soft parts, which Tavel aptly describes as forming a sort of hood: the peritoneum in the region of the ring is movable and must be isolated from its surroundings after the gut is reduced.

After the sac has been emptied and the contents have been returned inside the abdomen, it may be removed without opening it, as Tavel does in the case of children. Considerable force is often required to separate the sac from the skin in the neighbourhood of the umbilical cicatrix.

[1] Tavel, *Revue méd. de la Suisse romande*, August 1904.

If the sac is too intimately connected with the skin, it may be simply cut across with scissors and left behind. When there is a narrow neck, it should be transfixed and ligatured, and the sac removed unopened as in inguinal and femoral herniæ; but when the neck is of a wide nature, the sac should be opened in order to make sure that no intestine is included when the ligature is tied.

A gauze pad is inserted to keep the intestines out of the way, and the sac is divided about 1 cm. from the umbilical ring. The peritoneal edges are caught on either side with artery-forceps and sutured in the transverse axis with fine continuous silk.

The ring is also sutured transversely, in imitation of the natural method of closure of the umbilicus since the fibres of the transversalis fascia, which strengthen the umbilical ring, *i.e.* the fascia umbilicalis (Richet), run transversely above and below the opening.

The stump of the sac is kept back with a gauze swab, while the firm edges of the ring, which should not be rawed,[1] are brought together in a transverse direction with a continuous silk suture. We regard the use of silk as imperative since it holds the edges in contact for a longer time.

Excision of the umbilicus in uncomplicated cases is an unnecessary disfigurement.

(*b*) *The Radical Cure of large Umbilical and Ventral Herniæ.* Except when there are distinct or urgent indications for operating, it is often best to leave elderly people with large long-standing umbilical herniæ alone, as the risk of thrombosis occurring in the omental or mesenteric veins, with consequent interference with the blood supply of the bowel, embolism and pneumonia, makes the operation not always free from danger.

These patients, as a rule, only seek advice when symptoms of strangulation or inflammation call for surgical interference.

The radical operation, including the slight modifications necessary in strangulated cases, may be performed by a transverse incision either above or below the umbilicus, according to its relation to the hernia. The incision, which should be as close as possible to the ring, should be made cautiously, as the skin is thin and the hernial sac lies immediately subjacent to it. The summit of the hernia is often closely adherent to the skin (especially around the site of the umbilical scar), in which case an incision must be made beyond the adherent part of the skin, which must be removed along with the sac.

When there are no adhesions to the skin the sac can easily be freed as far as the ring by dissecting back the soft parts. After the neck of the sac has been isolated and the ring freely exposed on all sides, the sac is carefully opened, because, especially in elderly subjects, large masses of omental tissue lie in the hernia and are attached by broad adhesions to the sac, especially at its neck.

The separation of matted omentum is always a difficult matter, and if the part removed be more than merely the periphery, the point of division comes very close to the transverse colon, and here large vessels may require ligature. Ligaturing *en masse* may lead to thrombosis and cause necrosis in the region of the stump. This must always be considered in old people on account of their predisposition to pneumonia. It is well, therefore, to carefully isolate small parts of the omentum, which is generally very friable, and to tie it as near the periphery as possible, or, if necessary, rather to cut round it and replace a part of the hernial sac along with the omentum. If the hernia be large and composed of intestine (in old people generally the transverse colon) and large masses of fatty omentum, it may be necessary to increase the size of the ring by notching it upwards in the middle line so as to avoid too much crushing and pressure when returning the contents. Eiselsberg's experience is that intestinal hæmorrhages are easily caused, and it is within our own experience that sloughs of the intestinal mucosa may occur within a short space of time.

When the contents have been successfully replaced, it is most desirable, in the

[1] It is quite unnecessary to excise or raw the edges of the hernial ring, for it has no epithelial covering to prevent union; and besides it is sufficiently rawed by dividing the process of fascia which covers the sac.

case of omental herniæ of long standing, not to place a ligature around the neck of the sac, as is usually done in inguinal and femoral herniæ, but to remove the sac close up to the ring, which is often very rigid and thickened, and to introduce deep sutures simultaneously through the aponeurosis (linea alba) and peritoneum (neck of the sac). It is best to use interrupted sutures at intervals of not more than 1 cm., and to apply them in such a way that the umbilical opening is firmly closed in a transverse direction. To prevent the peritoneum retracting, if it be tense, it is cut away 1 to 2 cm. outside the ring, and the redundant portion is pulled forwards with forceps so as to enclose a broad surface in the suture. A broad margin of the umbilical ring must be included in the suture, as it forms the only structure which can be relied on not to stretch.

Special difficulties are frequently encountered in connection with very large ventral herniæ, as for example occur after using interrupted catgut sutures for closing a laparotomy wound, a practice which is still popular with some gynæcologists. Not only does the sac contain masses of large and small intestine, but the coils are often extensively adherent to the inner surface of the sac, while strong bands are often found stretching across the bowel and mesentery which cannot be detached.

In such cases all cicatrices should be cut away so as to free the skin as far as the base of the hernia, while large portions of the sac may have to be left adherent to the intestines before the adherent coils of bowel can be returned inside the abdomen. It is always essential to see that the peritoneum is quite free before closing it with a continuous silk suture. While this is being done the coils of intestine must be kept back (often forcibly) with gauze compresses.

The fascial covering is next closed. For this purpose good silk is used and the sutures must be passed in the neighbourhood of the base of the hernia only through parts of the fascia which are sufficiently resistent. In order to avoid tension, "Relaxation-incisions" (Karewski) may have to be made before the fascia or even muscles can be drawn together with sutures. Approximation of the recti introduced by Gersuny is very useful for herniæ in the middle line.

Graser, following Pfannenstiel and Menge, employs a transverse incision. He incises the fascia covering the hernia transversely, turns it upwards and downwards along with the anterior sheath of the rectus in the form of two broad flaps, and detaches the recti from the posterior layer of the sheath. He then divides the deep fascia and the peritoneum at the base of the hernia and sutures their edges vertically. The recti are then approximated by sutures and the flaps containing the fascia and the anterior sheath of the rectus are sutured transversely.

(c) Surgery of the Gall-Bladder and Bile Ducts

101. Summary and Development. Marion Sims, Blodgett, and Brown were the first to deliberately open the gall-bladder. In each case the operation was undertaken for empyema of the gall-bladder and the patients died. Cholecystostomy was then performed by Bobbs, in a case in which no diagnosis had been made beforehand. In 1878 we published the first case in which, on the strength of the diagnosis, the gall-bladder was opened, thirty-two gall-stones being removed. The ideal operation of cholecystotomy was instituted by Spencer Wells, but the success that now attends operations on the bile passages is largely due to Langenbuch's enterprise in excising the gall-bladder (1882) and to steady improvement in operative technique. Thanks to his lead, the position of biliary surgery is now most satisfactory, and this is proved by the fact that good results are obtained at the hands of general surgeons as well as by such specialists as Kehr, Mayo Robson, the brothers Mayo of Rochester, Körte, Courvoisier, Riedel, and others, who count their operations by hundreds and thousands.

The gradual development of the surgery of the liver and bile passages forms an interesting retrospect. In the early cases (Bobbs and Kocher), the gall-bladder was simply incised (cholecystostomy), Langenbuch then removed it altogether (cholecystectomy). An attempt was next made in suitable cases to limit the operation to cholecystostomy, *i.e.* by opening the gall-bladder and removing its contents

with subsequent suture. A little later the removal of stones and other obstructions in the bile duct was undertaken. Lawson Tait, Langenbuch, Credé, and ourselves (1889) were the first to perform cholelithothripsy. Later, we learned how to expose the retro- and intraduodenal portions of the bile duct (*vide* our publication on Internal Choledocho-Duodenostomy, 1890). Cholecystenterostomy was then introduced by Winiwarter, Monastyrski, Kappeler, and Socin, for cases where separation and exposure of the common duct were impossible. More recently Kehr's operation of hepaticotomy for the removal of an obstruction situated in the peritoneal portion of the hepatic duct combined with drainage of the hepatic duct and hepatico-enterostomy have been introduced. Lastly, Kehr and Enderlen have perfected the idea of direct hepato-cholangiostomy, which we first attempted in 1888 and have extended it in the direction of cholangio-duodenostomy.

Although the removal of gall-stones may be regarded as a perfectly safe operation, provided the technique is good, it is not always possible to prevent the spread of sepsis when the bile passages are the seat of acute infective changes. Deaths from this cause occasionally take place after operations for cholelithiasis, but as the prognosis in such cases is always unfavourable, the operation cannot be held responsible for the results.

As it has always been our endeavour to describe only those methods which are thoroughly approved, we refer the reader to the works of Kehr, Riedel, Körte, Courvoisier, Mayo Robson, the brothers Mayo, and others, for a detailed description of the rarer and more difficult operations. Our present first assistant, Dr Matti, has recently made a careful analysis of 100 of our operations on the bile passages,[1] and has shown that our mortality is less than that of Kehr and Mayo Robson. We feel, therefore, we are justified in recommending the methods we have tried.

In these 100 cases, which included many complicated conditions, with the exception of liver abscess, we had only two deaths, both after cholecystectomy (2 per cent). One was due to embolism, the other to peritonitis, the result of the ligature on the stump of the gall-bladder having slipped. In this case, death might possibly have been prevented if we had passed a drainage tube down to the stump of the gall-bladder. With these two exceptions all the others recovered, amongst which were cases of choledochotomy and many other conditions associated with severe inflammatory complications.

We attribute our good results to the fact that in every case we try to arrive at an accurate diagnosis, specially during the operation, and then adopt the simplest measures. We have not drained the common bile duct or the hepatic duct in a single case, even when they were the seat of inflammation, notwithstanding the fact that Kehr and Körte attribute their success to having employed drainage. Our own statistics, as well as Mayo Robson's 1500 cases, show that drainage is not necessary, and we have never had occasion to change our belief. We have also gone a step further than other surgeons in the conservative treatment of the gall-bladder, only a few patients having had recurrence (3 cases), while the mortality has been diminished.

102. Indications for Operation, and General Remarks on Technique. Surgery of the bile passages, which originated in the treatment of suppurative conditions of the gall-bladder, has reached its greatest development in the treatment of gall-stones. It is the greatest advance modern surgery has made, to afford aid in the frequent combination of both conditions and in acute primary infections of the bile passages.

The treatment of new growths is still limited and forms a group by itself, while the operations on the bile ducts for the treatment of pancreatitis closely follow those for infective cholangitis.

The indications for surgical interference are, as a rule, twofold:

(1) To relieve mechanical obstruction in the course of the bile stream and the conditions associated with it (gall-stones, new growths, and cicatricial contractions).

(2) To provide escape for bile containing bacteria and toxins in all infective cases. These two classes of cases should be clearly distinguished before we decide the form the operation is to take, but it often happens that both conditions occur together.

[1] "Festschrift" für v. Bergmann, 1906, in Langenbeck's *Archiv*.

Had this principle been followed out in the past, the treatment would not have undergone the fluctuations that it has from one to the other extreme. While Lawson Tait and other experienced surgeons employed cholecystostomy almost exclusively,[1] and sacrificed all other considerations for drainage, many surgeons nowadays insist on nothing less than an almost routine removal of the gall-bladder, combined with drainage of the deep bile passages (common bile or hepatic ducts).

As we recorded the first successful cholecystostomy and were among the first to perform cholecystectomy, we can speak with experience on the relative merits of both operations.

Surgeons should realise that it is their duty to the patient to pull him through his illness and not to perform an operation regarded as classic. This object cannot be attained by any routine operation, whether based on old or on the most modern theories. Operations which are theoretically excellent, when put in practice may often cause the death of the patient because his individual needs are not taken into consideration.

In operating for peritonitis, experience has taught us not to attempt too much but to be content only with measures which are of vital importance. Unless we bear this in mind we cannot get beyond the point of view, to which Körte, a surgeon of experience, resigns himself, that in suppurative conditions we must be prepared to lose one case in ten. It is often far better merely to avert the danger to life for the time being and reserve a radical operation for a future occasion, for, with the improved conditions, operation is then more favourable (*vide* our statistics with those of Körte), and may be often not even required. From these considerations we proceed to the choice of operative technique.

Two distinct types of cases must be considered—(1) those in which the inflammatory process has already gone on to phlegmonous pericystitis, and (2) those in which mechanical difficulties are prominent (gall-stones without clinical signs of inflammation).

(1) When the case is an inflammatory one, and the gall-bladder is adherent to the abdominal wall and surrounding structures, with superficial tenderness, or even infiltration of the skin, cholecystostomy is all that is required at first. The incision should not be so large as that used for a radical operation, and should be made at a point where the adhesions are present. If the condition is not cured by opening and draining the gall-bladder, a radical operation may be undertaken later under better conditions.

(2) The treatment of a typical case of biliary colic, uncomplicated by intense inflammatory manifestations,[2] is equally definite.

Here, again, we follow out the principle of first dealing with the mechanical considerations and only thoroughly remove the gall-stones, nothing more, and our results show that our patients have not suffered in consequence. Cholecystotomy, *i.e.* when the gall-bladder is opened, sutured, and replaced without drainage, is the ideal operation when the cystic, hepatic, and common bile ducts are all free and patent. If one of these ducts is obstructed by a stone, the stone should be removed, and the incision in the duct closed by suture.

When the gall-bladder is healthy, no good can be done by removing it, and the results of those surgeons who advocate cholecystectomy *à tout prix* bear this out. It is quite true that gall-stones may develop again in a gall-bladder which has been

[1] Riedel only mentions cholecystostomy, while Mayo Robson has performed 319 cholecystectomies and 845 cholecystostomies.

[2] In the previous edition of this work, we stated that the removal of stones in the gall-bladder, as in other organs, can only be accomplished rapidly and with certainty by surgical measures. We will not go so far as to say that gall-stones "belong" to the surgeon. They belong first of all to the patient, and if he prefers to keep them, and drink Karlsbad waters besides, he has a perfect right to do so. Surgeons, who in the case of their patients are firm advocates of operation, are well known, when they themselves get gall-stones, to adopt this point of view. And if a patient comes to the point of wishing to allow his gall-stones to struggle *per vias naturales* with pain and anguish, that is his own business. On the other hand, a surgeon has certainly the right to say to his patient that he will be more quickly and surely cured of his illness by operation before subsequent dangers arise than by any other treatment.

retained, but this fear—so far as it is not based on inaccurate reasoning—is certainly much more theoretical than founded on practice, and it is quite incorrect to consider the gall-bladder analogous to the appendix.[1]

If the gall-bladder is removed and there is a recurrence of the gall-stones (*vide infra*), any further operative treatment is rendered infinitely more difficult, and, notwithstanding what may be said to the contrary, this is borne out by the reports of the cases in which a second operation was required. For, if the common bile duct becomes obstructed later on, we can no longer avail ourselves of simple measures such as cholecystostomy or cholecystenterostomy, but must perforce undertake some much more radical procedure.

It is well known that the prolonged presence of gall-stones predisposes to malignant disease in the gall-bladder. We are familiar with the frequency of this occurrence in cases of gall-stones which have not been removed or where disease had already occurred before their removal. We do not know of any case in which a more or less healthy gall-bladder has developed cancer after the removal of stones.

(3) In view of the signs of associated general infection, the indications are also clear in dealing with extensive cholangitis where the inflammation has spread right up to the liver. According to Kehr, the first and only thing to do is to provide for thorough drainage of the common bile duct and hepatic ducts, and to drain off the bile as quickly and with as little surgical interference as possible (cholecystostomy, etc.). After the gall-bladder has been opened, the way must be made free as far as the hepatic duct, if necessary, by slitting open the gall-bladder and cystic duct up to the common bile duct, so that thorough drainage of the infective bile from the liver and hepatic duct may be established.

(4) Treatment of long-standing biliary obstruction with symptoms of cholæmia is equally definite. These patients who are suffering from toxæmia should not be interfered with more than to relieve the urgent symptoms. It is sufficient to open the gall-bladder and make sure that the bile escapes freely.

In spite of these clear indications in both early and late stages there remain a large number of affections of the bile passages in which it is only during the operation that the surgeon can first decide which method will best secure a permanent recovery. In such cases we are in complete agreement with the modern opinion that the bile passages must be made freely accessible in their whole extent to allow of a thorough examination being made during the operation.

The abdominal incision must be long enough to permit of inspection and palpation of the parts, and the best incision is the one which inflicts least injury, *i.e.* which avoids the vessels and nerves, and which can be easily closed without danger of subsequent trouble or the formation of a hernia. It is impossible for one incision to fit the requirements of every case. In a patient with a long narrow chest and a prominent costal margin the incision is quite different from that for a patient with a broad chest and a more horizontal costal margin, while stout people require a longer incision than that made on patients who are thin.

We employ the oblique incision described and illustrated in Fig. 319. We prefer it to the vertical and the "wave" incisions through the rectus recommended by Lawson Tait, Langenbeck, Robson, Riedel, and Kehr. Our incision is carried in a straight line obliquely from the tip of the ensiform process, two fingers'-breadth below and at first parallel to the costal margin, after which it descends as far as the muscular fibres of the external oblique, which may be slightly incised. The rectus is divided across its whole breadth, and the nerves supplying it, which run obliquely from without downwards and inwards on the transversalis, are drawn aside. A few branches of the superior epigastric artery (int. mammary) are tied in the muscle.

Körte employs practically the same incision. When required, it can be easily enlarged so that even a gall-bladder lying far to the right can be reached. Hernia is very exceptional, as in 100 of our cases it has only occurred once. In a second case, where we employed a long mesial incision and removed at the same time an ovarian tumour, a hernia resulted.

[1] Article by Albert Kocher, *Korrbl. für Schweizer Ärzte*, April 1900.

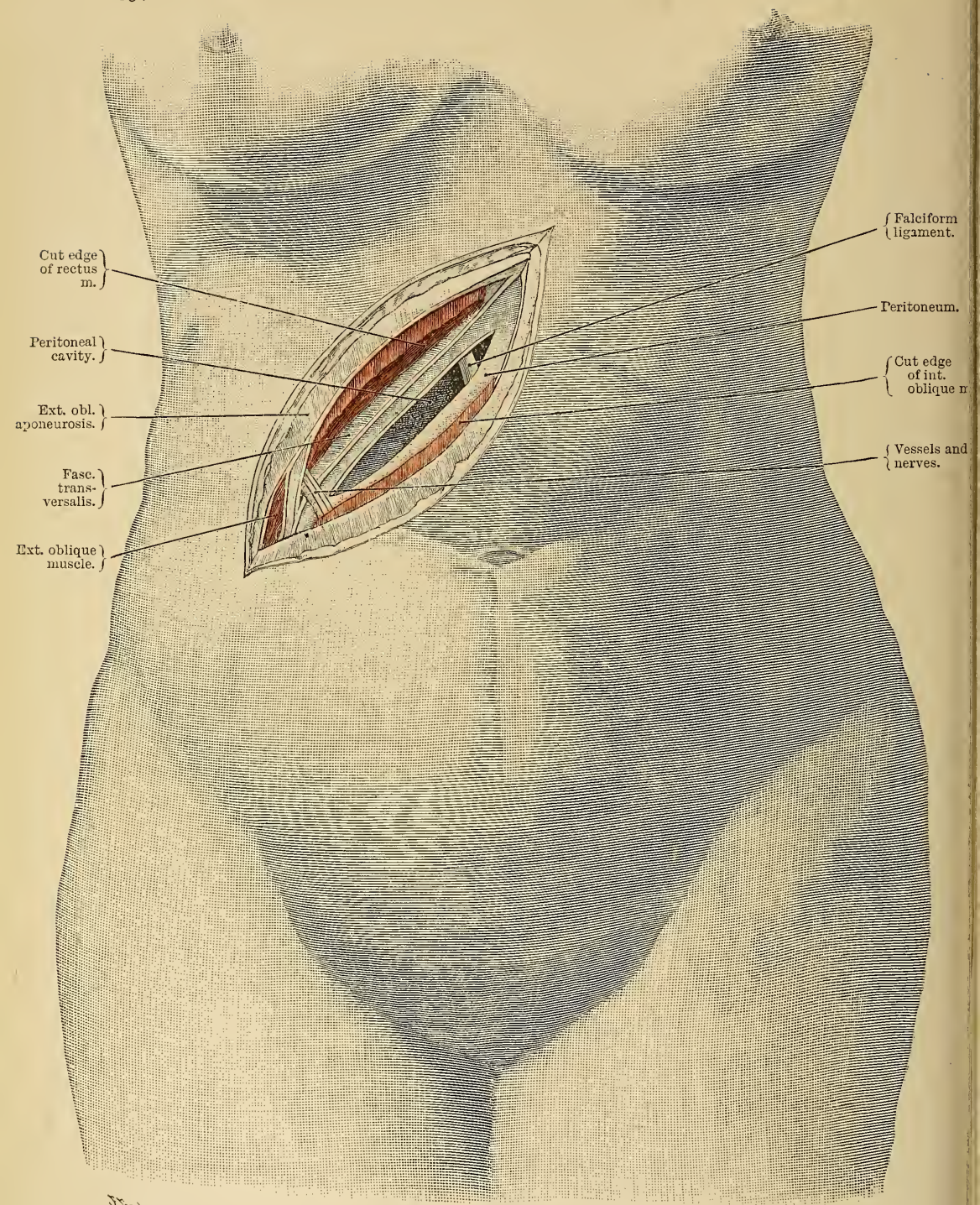

FIG. 319.—Incision to expose the gall-bladder and bile ducts. The sheath of the rectus has been opened and the muscle cut across; the broad abdominal muscles (ext. and int. oblique) are merely nicked; the transversalis fascia and its muscular fibres are completely divided.

By raising up the liver (the incision is parallel to its lower border), it can often be dislocated upwards so that an enlarged gall-bladder can be brought outside the abdomen while at the same time access is got to the bile ducts. Mayo Robson and Witzel attach great importance to this procedure, and the former lays special stress on the fact that by dislocating the liver in this way the gall-bladder, cystic duct, and common bile duct can be brought into a straight line down to the duodenum and head of the pancreas. At the same time the intestines, omentum, colon, and stomach should be packed off with moist gauze pads and pushed downwards, and to the left, with broad retractors. A gauze swab is also placed over the retracted liver and the latter kept rotated upwards.

By retracting the liver and dragging the gall-bladder upwards and the duodenum downwards, we get good access to the structures in the free border of the gastro-hepatic omentum (hepato-duodenal ligament), while at the same time the general peritoneal cavity is shut off. The anterior surface of the kidney covered by peritoneum is exposed with the second portion of the duodenum lying internal to it, while, higher up, the gastro-hepatic omentum is recognised with the bile duct in front and the portal vein and hepatic artery behind. Great assistance is afforded by placing a large sandbag in the lower dorsal region of the patient so as to produce a marked lordosis.

Lastly, the duodenum may be mobilised in the manner we recommended in 1903[1] by dividing the peritoneum covering the right kidney along a line one or two fingers'-breadth outside the vertical part of the duodenum. This enables one to free the common bile duct down to the head of the pancreas and its termination in the posterior wall of the duodenum without, as Berg, Lorenz,[2] Payr, de Quervain, and others have shown, causing any harm. By enlarging the opening in the parietal peritoneum upwards and separating the peritoneum of the gastro-hepatic omentum by blunt dissection the intraperitoneal part of the hepatic duct can be exposed.

Many surgeons employ Kehr's "wave cut" through the rectus, or Robson and Körte's curved incision, which follows the costal margin above and is then carried downwards along the outer border of the rectus.

The best and most rational substitute for the oblique incision, when the latter is unsuitable, is the hooked incision recommended by Czerny. It is made in the middle line, and its lower end is carried transversely outwards and slightly upwards (*vide* Fig. 320). It is the best of all as regards the motor nerves to the rectus, as the latter are all avoided, and at the same time excellent access is obtained. As far as the preservation of nerves and the direction of the skin incision are concerned, it is, in our opinion, a normal incision, although it involves rather difficult suturing and is consequently rather complicated. A vertical incision at the outer border of the rectus is not so satisfactory since it gives too little room. Mayo Robson makes a longitudinal incision over the middle of the rectus, splits the muscle, and prolongs the wound up to the ensiform process so that he may be able to rotate the liver well upwards. The access got by this method is, in our experience, more cramped than that by the oblique or the angled incision.

Hernia can only be prevented by suturing the wound in layers, not with catgut, but with silk prepared in the manner we have described. Despite the fact that in our oblique incision the rectus is cut across, a hernia has only occurred once, and that was in a case which suppurated. The first continuous suture unites the peritoneum, the posterior layer of the sheath, and the edges of the muscle, while the skin is closed with a second continuous suture.

103. Cholecystostomy. This was at one time the most universally employed of the operations on the gall-bladder. As it is the simplest, and is regarded yet by some surgeons of eminence as the most reliable, we shall consider it first. It was originally performed in two stages by Blodgett and ourselves (ours was the first successful case), and up till now Mayo and Riedel have been its strongest supporters.

Lawson Tait introduced the one-stage operation, which at the hands of Riedel,

[1] *Centralbl. f. Chir.*, 1903, and *Deutsch. Zeitschr. f. Chir.* Bd. 79.
[2] Lorenz, *Deutsch. Zeitschr. f. Chir.* Bd. 79.

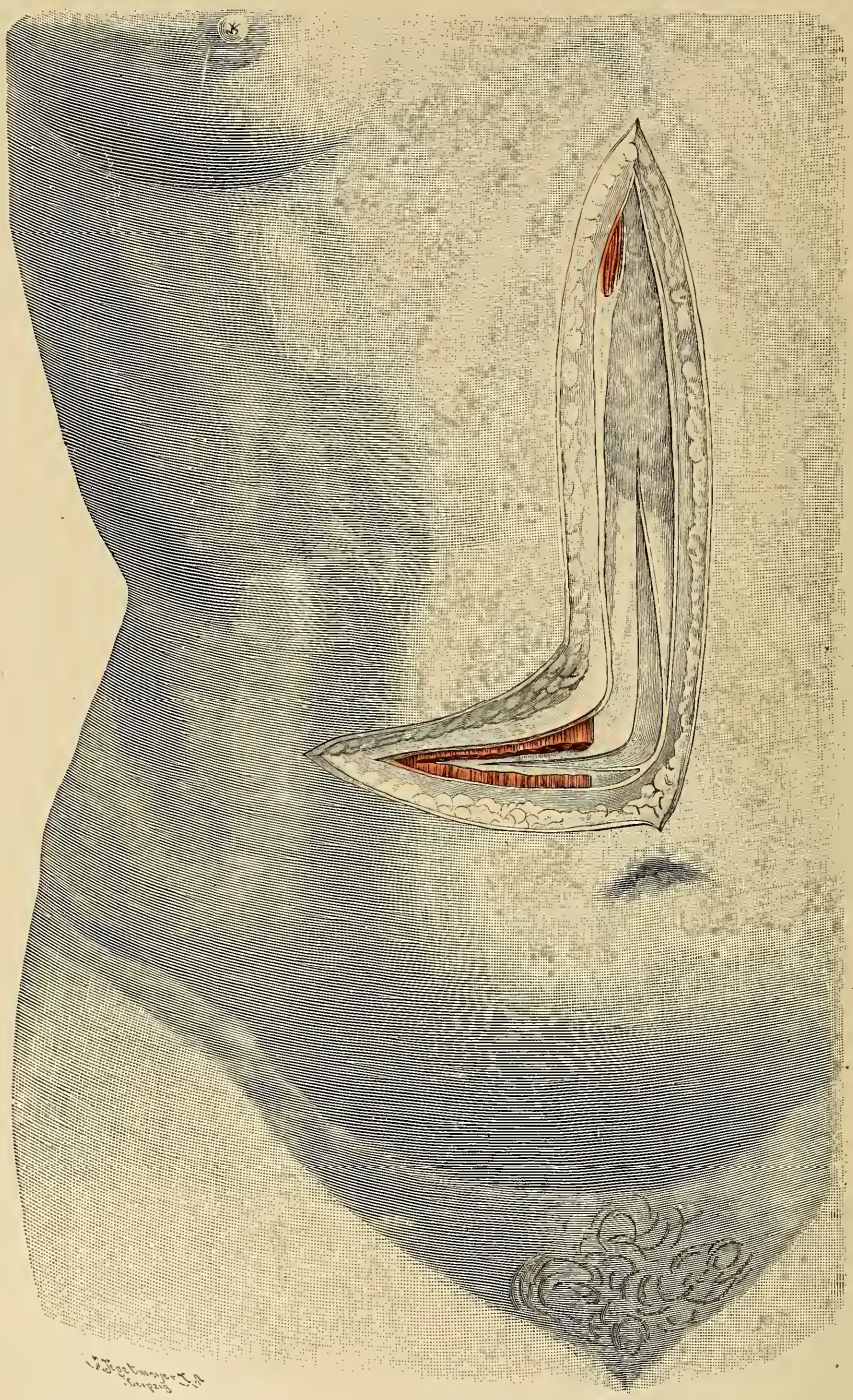

FIG. 320.—Hooked incision for the exposure of the bile passages in difficult cases. The anterior and posterior walls of the rectus sheath are opened and the muscle is cut across.

and more especially Mayo Robson, has now achieved great success, while Richardson has done much to establish its claim as the premier method in the treatment of gall-stones and their sequelæ. Robson has performed cholecystectomy 319 times, cholecystostomy 845 times.

It is the simplest method by which the gall-bladder can be emptied and drained, and Robson's statistics bear this out with the low mortality of 2·1 per cent.

It is indicated when temporary drainage of the gall-bladder and bile passages is required—as, for example, in suppurative conditions. Two types of cases should, however, be distinguished:—First, those in which the inflammatory process has already involved the abdominal wall: here (empyema) cholecystostomy is obviously the correct treatment. More commonly, however, the gall-bladder is only slightly adherent to the omentum or intestines and can be easily separated. In these circumstances the question of removing it altogether has to be considered as well. If cholecystostomy is decided on, the steps of the operation are somewhat different from those required for the former class of cases.

There is as little justification for being content with performing cholecystostomy in the treatment of cholelithiasis merely because it fulfils the mechanical indications for the removal of gall-stones, as there is (and this was the case formerly) reason for regarding it as the normal operation in the case of a mechanical obstruction, *e.g.* of the common bile duct when it merely provides an escape for the bile externally. Cholecystostomy is always indicated when the patient's general condition will not allow of a severe operation, such as finding and removing the obstruction, and when there is cholæmia and general infection. Simple cholecystostomy, under local anæsthesia, is often the only operation the patient can undergo without risk. Robson, with his large experience, lays special emphasis on the employment of this simple treatment of obstruction of the bile duct in critical cases.

(*a*) *Technique of Cholecystostomy, when there is Pericystitis, with Adhesions to the Abdominal Wall.* An incision is made over the point of greatest tenderness with possibly redness and œdema, this corresponding usually to the outer border of the rectus. The incision should not be more than $2\frac{1}{2}$ inches long, and is carried right down to the parietal peritoneum, which is carefully opened, and if the gall-bladder is adherent all round, the latter is simply incised and the hæmorrhage from its cut edges controlled by sutures (catgut) uniting it to the deep fascia. The interior of the gall-bladder is then washed out with warm saline, a glass drain inserted, and the wound packed with xeroform gauze. The gall-bladder need only be packed to arrest hæmorrhage from its internal surface, or as a means of applying antiseptics directly to necrotic patches in its wall.

If the incision opens up the abdominal cavity at a point where the latter is not adherent to the gall-bladder, that part of the wound should be closed with catgut stitches, and the gall-bladder sutured to the abdominal wall, after which the incision is prolonged in one or other direction.

(*b*) *Cholecystostomy when the Gall-bladder is free or easily isolated.* When the gall-bladder is free or only slightly adherent to the abdominal wall, the steps of the operation are different. In the conditions described above (*a*) the adhesions to the abdominal wall persist and may give rise to subsequent trouble, while there is also a risk of a persistent fistula forming. Lastly, there is always the difficulty, unless one can palpate the gall-bladder from outside, of being certain that all the stones have been removed.

A larger exploratory incision is required when the gall-bladder is free, but it may be necessary to reduce operative interference to a minimum on account of the serious state of the general health of the patient. In these cases it suffices to make an incision sufficiently large to allow the gall-bladder to be pulled into the wound and the surrounding parts to be packed off with gauze wrung out of saline solution. After the abdominal cavity has been shut off, the gall-bladder is opened, emptied, and the edges grasped with forceps. It is then temporarily plugged in order to prevent escape from the bile ducts. Mayo Robson lays great stress on washing out the gall-bladder and ducts with warm 5 per cent solution of sapo animalis or olive oil.

Now comes the peculiar difference from the simple incision described in case (*a*). The edges are first tucked in, and a rubber drainage tube is fixed into the gall-bladder by means of a catgut suture which includes the whole thickness of the wall, and at the same time invaginates the edges all round when pulled taut. When a small opening has been made, a purse-string suture may be employed as in gastrostomy by Kader's method. Over this a fine silk serous suture is inserted. By this water-tight method of inserting the drainage tube (Poppert and Kehr) union between the wall of the gall-bladder and the skin is avoided, and the danger of a permanent fistula is prevented.

The end of the serous suture on both sides of the drain is fixed to the parietal peritoneum and fascia transversalis on the under surface of the abdominal wall. As a further precaution against the formation of firm adhesions, one can even, when it is very important that the tube should be removed early and the fistula allowed to heal, follow Kehr and Körte and do away with all retaining sutures, and merely leave in the drainage tube surrounded with gauze. In 189 of Mayo Robson's cases of cholecystostomy, a persistent fistula occurred on fourteen occasions. It is certainly worth while to obviate the possibility of such an occurrence.

There is a further advantage in inserting the drainage tube in this water-tight manner, for if the tube is left long the bile can be drained off directly into a vessel and soiling of the dressings avoided.

When, however, one has to deal with a patient who is strong enough for a systematic operation, it should be a rule always to examine thoroughly not only the gall-bladder but also the ducts for the presence of gall-stones by means of a probe inside controlled by a finger outside. This has a great advantage over the more simple method of merely opening the gall-bladder in urgent cases of empyema. Lennander[1] declares that most cases of cholelithiasis can be properly treated by cystostomy in one stage.

As regards mortality, the results of cystostomy come next to those of cystotomy. Körte had 5 deaths in 99 suppurative cases, and 3 deaths in 36 simple ones. Kehr's mortality is 1·8 per cent, and Mayo Robson's 2·1 per cent (in 845 cases). We have had no fatality after cystostomy.

104. Cholecystotomy. The operation of simple cholecystotomy, which consists in the removal of the gall-stones, with immediate suture and reposition of the gall-bladder, was first performed, in 1883 and 1884, by Meredith and Courvoisier. The latter author described it under the name of cholecystendysis. Much has recently been written regarding the relative value of cholecystostomy and cholecystectomy, while little or nothing is said about simple cholecystotomy. It is indeed astonishing that so little attention is given to this operation, which undoubtedly affords the quickest and safest cure, and at the same time gives the least trouble from adhesions. It is regarded as being more dangerous, but such a statement is quite without foundation. The opening in the gall-bladder can be closed with absolute safety if the proper sort of case has been selected and if fine silk is used for the peritoneal stitches. In none of the cases where we have adopted it have we had the least trouble.

Another argument urged against it is that it does not prevent recurrence. Recurrence undoubtedly has been observed after cholecystendysis, and we have had personal experience of it in three cases; but after all the question is, whether its advantages do not more than counterbalance this disadvantage. From the point of view of possible recurrence one must first of all recognise that there are certain conditions which must be regarded as contraindicating the operation. Cholecystectomy does not exclude the possibility of another stone forming in the ducts, if the original causes still persist, and it must not be forgotten that should recurrence take place in the ducts, the mere presence of the gall-bladder is an advantage. Every surgeon of experience will admit that although operations for recurrent gall-stones after removal of the gall-bladder are not, as Körte says, "unsurmountable," yet they are attended with very great difficulty. Körte himself on three occasions has had to supplement an earlier choledochotomy with cholecystoduodenostomy.

[1] Langenbeck's *Archiv*, Bd. 45.

It is essential to make plain the indications for and against the operation of cholecystotomy.

(1) In the first place we must be absolutely sure that the bile ducts are patent, and just as in all the other operations for gall-stones, we must be certain that no stone is overlooked.

Since careful attention is nowadays paid to this, the results have become correspondingly better. As a general rule, we can determine the presence of a calculus in the hepatic or common bile duct beforehand, if we take the trouble to make a careful diagnosis, but at the operation we can, and must, make sure of this point. Robson determines whether the ducts are patent by forcible injections of warm sterile saline lotion. A mere catarrhal inflammation of the ducts is not a sufficient contraindication. There is a cause for the catarrh. It is kept up either by the presence of stones, by the spread of inflammation from below, or by biliary engorgement. If the ducts are patent and the stones are thoroughly removed the catarrh disappears without external drainage. The natural drainage into the bowel is amply sufficient, and may be relied upon to a far greater extent than most surgeons suppose. Robson removes the drainage tube in a cholecystostomy in a few days and then relies entirely on the internal drainage.

(2) The second contraindication to simple cholecystotomy is the presence of more profound inflammatory changes in the wall of the gall-bladder. The presence of a few bacillus coli in the contents of the gall-bladder should not influence us against the operation. Such a condition is by no means uncommon, and leads to no further consequences as soon as its cause, gall-stones, is removed. If the walls of the gall-bladder have become seriously altered as a result of an acute or chronic suppurative process, it is better to perform cholecystectomy, or if there are serious objections to this, cholecystostomy, for it is in these cases especially that there is a tendency to recurrence.

(3) Impaction of a stone in the cystic duct with thickening of its walls is another contraindication to simple cholecystotomy, for here the patency of the duct is interfered with. If these principles are followed, the dread of cancer subsequently developing in the gall-bladder is considerably lessened.

Cancer is certainly a sequel to cholelithiasis in not a few cases, but why? Because the gall-stones have either not been removed or have been removed too late. It has never been proved that there is a tendency to cancer after cholecystotomy. With the removal of chronic inflammatory contents there is no reason left for atypical epithelial growth. Mayo Robson only knows of two cases in which cancer developed after cystotomy and cystostomy.

We consider that what Bernays calls ideal cholecystotomy and Courvoisier cholecystendysis is a very simple and safe operation for an early case of gall-stones. Cholelithiasis cannot be cured by internal medication, as we have no means of dissolving the stones. The object in treating a case medically is to mitigate the pain till such time as nature may manage to push and force the stones through the narrow bile ducts into the intestine. This operative treatment may, therefore, be very well termed ideal for the early stage of cholelithiasis, since by this means the patient is freed of all his trouble at one stroke without any permanent injury or disability. Primary union can be guaranteed in eight days, and no adhesions to the abdominal wall are formed.

An oblique incision is made 10 cm. (4 in.) long and 4 to 6 cm. below the costal margin. It need not be made so long to begin with, as it can be lengthened subsequently. It should begin over the most prominent part of the rectus abdominis, and should divide skin, superficial fascia, and the aponeurosis of the external oblique, which, in front of the rectus, is united with that of the internal oblique. The rectus muscle is then defined and its outer border notched; the superior epigastric artery, which lies a little internal to it, is ligatured, as are also some muscular branches. The fibres of the external and internal oblique muscles are divided at the outer part of the wound. The intercostal nerves, which pass inwards towards the rectus beneath the internal oblique, should be preserved, since their division results in

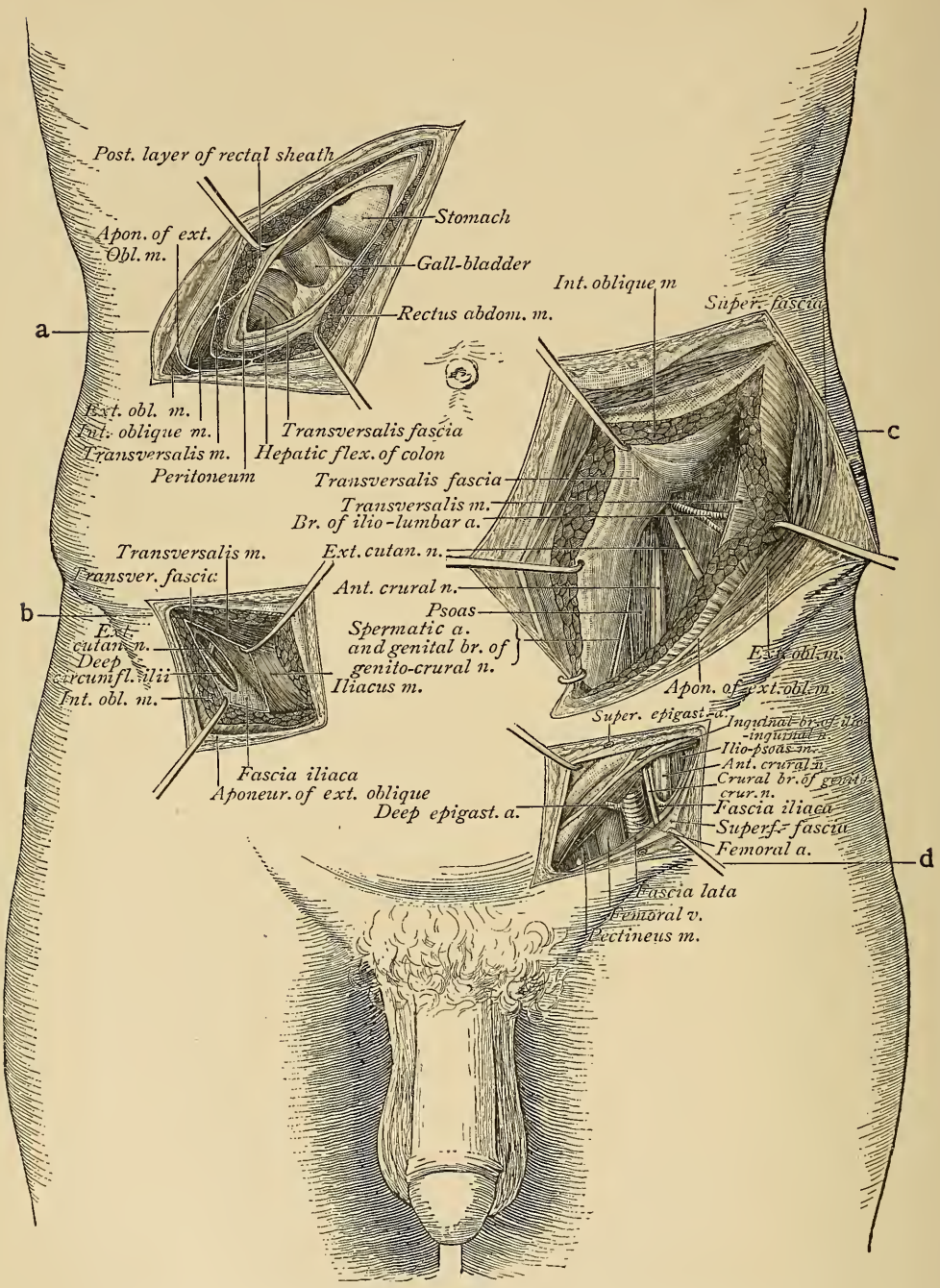

FIG. 321.—(*a*) Cholecystotomy. (*b*) Ligature of the deep circumflex iliac artery. (*c*) Ligature of the common iliac artery. (*d*) Ligature of the common femoral artery.

local paralysis of the rectus. The elasticity of the nerves readily admits of their retraction upwards or downwards. The muscular fibres of the transversalis extend beneath the edge of the rectus to end in an aponeurosis which, having united with the deep layer of the internal oblique, passes inwards behind the rectus to the linea alba. Beneath this, again, are the transverse fibres of the tranversalis fascia, on division of which the peritoneum is exposed.

After the peritoneum is divided, the gall-bladder, if elongated and enlarged, can be seen and drawn forward. Upon its inner side is the pyloric portion of the stomach, upon its outer side the colon. The omentum often lies in front of it, and must be pushed downwards and to the left: it is frequently adherent to the gall-bladder.

The gall-bladder is now pulled into the wound, and held there with fine clamp forceps, while the adjoining structures are packed off with gauze, and the escape of bile into the peritoneal cavity is prevented. The gall-bladder is fixed at its fundus with two of our hooked artery forceps, so that it may be safely emptied, and afterwards stitched, without allowing bile to escape into the peritoneal cavity. The fundus is incised, the fluid contents are evacuated, and then the calculi removed by means of a scoop and forceps. In doing this, we must be careful not to miss stones hidden behind folds in the cystic duct. Occasionally it is necessary to pass the forceps far in to reach stones which are deeply situated. Long, blunt, angled spoons are sometimes very useful in effecting extraction. After extraction of the stones the wound in the gall-bladder is closed by a double row of sutures as in suture of the intestine. The deep layer, which should be catgut, includes the whole thickness of the wall, whereas the superficial row (fine silk) unites the serous surfaces only. The gall-bladder is then replaced. The sutures cut through the mucous membrane and remain *in situ* without injury to the serous layer. The wound is completely closed without any drain. In the case of one of our colleagues, whose gall-bladder was hardly as large as one's thumb, and only projected about 4 cm. beyond the margin of the liver, we recently extracted forty-three medium-sized stones, lying like a rosary one against the other up to the very end of the cystic duct to a depth of $5\frac{1}{2}$ ins.

We have never found much difficulty in finding and removing stones from the gall-bladder and the cystic duct. The work is controlled by a finger outside and a probe inside the duct. It often takes time to remove the last stone, but the necessary time must be given to it. Irrigation assists the removal of stones.

It may happen that one is not certain that the gall-bladder and the cystic duct are quite empty. In these circumstances we do not hesitate to lay the entire track open to the common duct, and then either excise the gall-bladder or perform cholecystostomy.

Cholecystotomy should not be performed unless one is sure that the cystic, hepatic, and common ducts are patent, *i.e.* that there is no obstruction either of an inflammatory nature or due to a stone.

The operation is therefore only suitable for cases in which there have been repeated attacks of biliary colic, without definite inflammatory complications, and for the earlier stages of cholelithiasis. It is stated by some that it is unnecessary to operate on these cases, for the gall-stones may become "latent" under other treatment, and as they are generally of small size may be passed spontaneously. Any one who has endured a genuine attack of gall-stone colic more than once will gladly submit to operative treatment, which affords a prospect of certain cure in one or two weeks, and more especially when the gall-bladder contains hundreds of gall-stones which may be the source of as many attacks of colic.

Technique.—If simple cholecystotomy is decided on, the incision need not be so large as that required for exploring the whole length of the bile passages, an advantage common in many cases to it and to cholecystostomy. A slightly shorter incision than that shown in Fig. 321 dividing the outer half of the rectus and carried into the fibres of the external and internal oblique muscles will suffice to expose the gall-bladder. The oblique incision has the great advantage that it can be easily enlarged if necessary.

The gall-bladder is pulled forward, the fundus held up with two pairs of forceps or

silk stays, and well packed off with gauze after careful examination of the cystic duct as far back as the common bile duct. The fundus is then incised and the contents are evacuated into a suitable vessel. Hundreds of small stones have sometimes to be removed with a blunt scoop before one is satisfied (by examining with a finger and probe) that the gall-bladder is empty and (by irrigation) that the cystic and common bile ducts are quite patent.

The wound in the gall-bladder is closed with fine catgut sutures, which include all the layers, and over this a serous stitch is inserted. There is no object in stitching the gall-bladder to the abdominal wall, as it only gives rise to painful adhesions, while, as there has been no infection, drainage is also unnecessary. In contrast to the cystic or common bile ducts, the gall-bladder may be safely sutured, and the wound is healed in eight days.

Note.—Cysticotomy. Lindner, Hochenegg, and Küster were the first to remove impacted calculi in the cystic duct by direct incision. As a rule cysticotomy is performed along with cystotomy, if the stone in the cystic duct cannot be forced into the gall-bladder. Körte has performed internal cysticotomy for the removal of stones.

105. Cholecystectomy. At the present time there are numerous surgeons, especially in America, who advocate removal of the gall-bladder in nearly every case of cholelithiasis. This we regard as an extreme view, although in the beginning of the year 1890 we drew attention to the good results we had obtained with cholecystectomy. Scudder and Wilson have compared the relative merits of cholecystostomy and cholecystectomy, and have shown that with the former the results are less satisfactory on account of the not infrequent occurrence of persistent biliary fistula, while with cholecystectomy permanent relief is obtained.

There are, however, contraindications to, as well as indications for, cholecystectomy, and although we have helped to show that the absence of the gall-bladder does not in any way interfere with health, we believe it is often a disadvantage to remove the gall-bladder, while in many cases its removal is difficult and entails additional risk.

(1) Cholecystectomy is clearly indicated when the gall-bladder is the seat of malignant disease and when malignant disease is suspected. It not infrequently happens that one finds small carcinomatous nodules, or even a diffuse carcinoma, embedded in the wall of the gall-bladder, which is apparently thickened and indurated as a result of chronic inflammation. In all cases, therefore, where there is even a suspicion of new growth formation the gall-bladder should be excised.

(2) It is, however, much more frequently in connection with inflammatory conditions that the question of cholecystectomy arises, and here a distinction must be made between the changes due to acute and chronic inflammation. We regard an acute inflammation of the gall-bladder in the same light as an acute appendicitis. So long as the inflammation is limited to the gall-bladder and has not already reached the stage of phlegmonous pericystitis, excision is the safest procedure and gives the most rapid cure. It is not uncommon to find, on examination of the gall-bladder after excision in these cases, that there is extensive gangrene of the mucosa involving the whole thickness of the wall and even threatening perforation. Early cholecystectomy is therefore clearly indicated and is to be recommended in acute cholecystitis.

When the walls are much thickened from chronic catarrh, with or without ulceration, cholecystectomy is also indicated, whether the organ is shrivelled, or distended with pus (empyema or hydrops), for in either case the gall-bladder has lost its physiological function as a receptacle for bile and its presence is only harmful.

(3) Excision is further indicated when the cystic duct has become altered, either as a result of impaction of a calculus or chronic inflammation, for the function of the gall-bladder depends on the duct being patent. Attention must here be drawn to the fact emphasised by Robson, that a duct will often appear at first sight to be impermeable, while at the end of the operation, or if an external fistula is established after some hours or days, the bile begins to flow quite freely. Catarrhal swelling must not be mistaken for absolute obstruction.

The indications for excision are therefore numerous, but in our opinion it is quite unjustifiable to go so far as to sacrifice every gall-bladder on purely theoretical

grounds, in order to save the trouble of making a definite diagnosis based on an examination of each individual case. Apart from slight digestive disturbances, and a tendency to diarrhœa, which according to Mayo Robson's experience may follow removal of the gall-bladder, the fact remains that if a second operation has to be undertaken for recurrence, it is attended with far greater difficulties if the gall-bladder has been previously excised. It is much easier to make a thorough examination when the gall-bladder is present, and at the same time one has an opportunity of performing a cholecystenterostomy.

Further, by following the policy of excision *à tout prix*, we find complications not infrequently arise, which would not be encountered with cholecystostomy or simple cholecystotomy.

Separation of the gall-bladder from the liver is often difficult and dangerous when the walls are much thickened and there are many adhesions. Severe bleeding may arise from tearing of the exceedingly friable liver tissue, and if a gall-bladder with infective contents is torn or cut into deep down in the wound, infection is easily set up which retards the healing and leaves dense adhesions. It is sometimes by no means an easy matter to isolate the cystic artery, and if it is included in a mass of dense tissue, the ligature does not hold well: severe bleeding may occur, or the stump may necrose, and so delay the healing. We have experienced such an accident and have had occasion to regret that we had not been content with cholecystostomy. William J. Mayo has occasionally found good results follow the mere excision of the diseased mucous membrane and drainage through the cystic duct.

If the gall-bladder is not much altered, its removal is a comparatively simple matter, provided it is done subperitoneally by incising the peritoneum at its fundus in the manner described in the former editions. Witzel has lately strongly recommended this subserous method of shelling out the gall-bladder with blunt dissection, and the operation is now practised by most surgeons. It can only be done, however, when the subperitoneal tissues are loose, but, when there is little alteration of the walls, in our opinion it is doubtful whether a simple cholecystotomy should not be preferred.

Technique.—The oblique incision already described is made below the costal margin. By tilting the liver well upwards, good access is got to the cystic duct, and if the latter is found to be free, it is as well to clamp it at once at its lower end (together with the cystic artery) with two pairs of Kocher's forceps, placed 1 cm. apart, in the manner advocated by Robson and Mayo. The duct is then divided between the forceps and the gall-bladder stripped backwards towards the fundus. The separation should be carried out as far as possible subperitoneally with Kocher's blunt dissector. The cystic artery is ligatured, then the cystic duct and the peritoneum is sutured over it.

When one is sure that the bile passages are free, the cystic duct may be at once raised on an aneurysm needle, ligatured, and the gall-bladder separated. In this way the hæmorrhage is greatly diminished.

When good access to the cystic duct cannot be got, it is better to divide the peritoneum around the fundus and strip the gall-bladder from the liver up towards the cystic duct, with preservation at the same time of as much of the peritoneum as possible. The gall-bladder can then be utilised as a handle, which facilitates the isolation and division of the cystic duct (and ligature of the cystic artery). In either case the peritoneum must be carefully stitched over the stump with fine silk sutures, after the mucous membrane has been touched with the thermo-cautery, excised, or disinfected with carbolic alcohol. The raw surface left on the liver should be covered over as completely as possible with peritoneum, or should at least be closed with sutures.

Very often it is impossible to strip up the gall-bladder by subperitoneal blunt dissection, as the peritoneum is firmly adherent to the thickened wall. In these cases[1] the gall-bladder must be dissected off the liver with the knife. After removal

[1] We agree with Kehr, Körte, and Robson that complications are best avoided after excision by employing packing and drainage.

of the gall-bladder a gauze drain is inserted down to the raw surface on the liver and the stump of the duct, and it should be made a rule to drain the deeper parts of the wound with a tube. One of our two fatalities was caused by a sudden gush of infected bile in a case where we had trusted to the closure of the cystic duct and had omitted to drain the abdomen. On the other hand we think that a drain down to the point where the cystic duct is tied is amply sufficient.

If the condition of the ducts has not been determined clinically or before opening the gall-bladder, or if, on the other hand, they are the seat of disease, the steps of the operation are different. The gall-bladder should be opened by an incision at the fundus, emptied, cleansed, and packed with gauze. It is then palpated either with a probe or by injecting fluids one ascertains if the deeper bile-ducts are patent. Should nothing definite be found by these means, the gall-bladder and cystic duct are slit open up to the common duct. But if, on the other hand, it is found desirable to drain the hepatic and bile-ducts, and the alteration of the walls of the gall-bladder makes its removal necessary, a rubber tube is passed into the common duct up towards the hepatic duct and fixed in position with a stitch. The cystic duct is then isolated, ligatured, and the gall-bladder removed. If, however, removal of the gall-bladder is not definitely indicated, it is preferable in affections of the large bile passages to leave it and perform cholecystostomy, with drainage of the hepatic duct.

The tube is brought out through the wound and xeroform gauze is inserted down to the site of the sutures and to the raw surface of the liver. Where the gauze is in contact with intact peritoneum and with the edges of the wound it should be covered with gutta-percha tissue, after the fashion of M'Cosh's cigarette drain. The gauze is removed after two days, if there is no more blood-stained discharge, while the tube is taken out a day or two later. Drainage of the wound is only stopped when the bile resumes its natural course through the common bile duct and the cholangitis has disappeared.[1]

As a general rule, drainage of the hepatic duct after cholecystectomy is not necessary: the wound heals quicker and drains as well when the tube is only inserted down to the stump of the gall-bladder. It need only be resorted to when the inflammatory process has spread up the duct into the liver itself.

Note.—Of the surgeons who are opposed to the routine removal of the gall-bladder in disease of the ducts, Mayo Robson,[2] from experience of 3000 cases, declares that recurrence [3] after cholecystotomy or cholecystostomy is exceedingly rare, while, on the other hand, he has found recurrence in and dilatation of the bile-duct after excision.[4] He even holds that cirrhosis of the liver may be set up by regurgitation in the dilated ducts after the reservoir of the bile has been removed, a statement which is not to be disregarded. On the other hand, in only two cases has cancer of the gall-bladder developed after cholecystostomy (Slade considers the combination frequent).

In the same number of the *New York and Philadelphia Medical Journal*, Feb. 1906, Erdmann advises more frequent excision of the gall-bladder as a useless organ, while Carr points out the importance of having the gall-bladder in reserve for subsequent cholecystenterostomy.

To sum up: Our statistics, as well as those of other surgeons, prove without doubt that there are fewer cases of recurrence after cholecystectomy than after cholecystostomy, and still less than after the ideal cholecystotomy. This is explained by the fact that the gall-bladder is the favourite situation for the formation of stones.

Cholecystectomy, even in the hands of the most accomplished surgeons, has still a mortality of 3·2 per cent (Kehr), 3·4 per cent (Mayo), while that of cholecystostomy is 1·8 per cent and 2·8 per cent. Our mortality both for the ideal cholecystotomy

[1] It is much easier to know when to remove the tube, when the latter only goes down to the duct and not into it.

[2] *Indications and Contraindications for Removal of the Gall-bladder*, London, 1906.

[3] Cf. "On Recurrence," H. Mohr., *Klin. Vorträge v. Bergmann-Müller-v. Winkel*, No. 309, 1901.

[4] Halsted in his highly interesting contribution to the Surgery of the Bile Ducts (*Johns Hopkins Bull.*, Jan. 1900), mentions a case of this sort, and reference will be found in an article of ours in Langenbeck's *Archiv*, 1906, to a case where a stone formed in the common bile duct after cholecystectomy.

and cholecystostomy is nil, and on the strength of this we think it is justifiable to take the risk of recurrence.[1]

Further, as regards the question of mortality, we must also repeat that recurrence after cholecystectomy is a much more serious affair, and the prognosis of a second operation is not nearly so satisfactory as when there is recurrence after cholecystotomy or cholecystostomy.

Provided the ducts are thoroughly examined, and care is taken at the time not to leave any stone behind, cholecystotomy may be undertaken without any hesitation, for it involves less risk to life, if the gall-bladder is normal or the seat of catarrhal changes only. Kehr overlooked stones in 4 per cent of his earlier cases and 2·5 per cent of his recent cases. On the other hand whenever the gall-bladder is profoundly diseased, when it is shrunken, when the cystic duct is obliterated, or when there is the least suspicion of malignancy, excision is the correct treatment. If, however, it entails a difficult and prolonged operation and the patient's general condition is not favourable, cholecystostomy should be resorted to.

While we do not deny that infection exists in every case of cholelithiasis which gives rise to clinical signs, we are convinced that in mild cases removal of the stones causes the inflammation to subside whenever free discharge is established into the intestine and without external drainage. External drainage is absolutely necessary only in cases of severe suppurative or phlegmonous cholecystitis.

Appendix. There is, lastly, an alternative method, which Mayo recommends in cases where excision of the gall-bladder is difficult, namely excision of the mucosa only. E. Ries[2] has brought forward arguments against it to the effect that it is difficult to remove the mucosa *in toto*, and especially the glands which penetrate the muscular coat.

It should be borne in mind, however, that in very adherent cases good results may be obtained by slitting open the gall-bladder and cystic duct, by avoiding incising the liver during the separation, but rather by leaving behind the thickened fibrous subserous layer.

106. Cholecystenterostomy. This operation was first performed by Winiwarter, Kappeler, and Mayo Robson. It differs from the operations already described in that it does not remove the obstruction, but provides a channel by which the bile can pass round it. It is, therefore, chiefly employed in cases where the obstruction cannot be removed, *e.g.*, in extensive new growth in the head of the pancreas, or when a considerable extent of the lumen of the common bile-duct has become obliterated. It can also be employed simultaneously with a radical operation for the removal of the obstruction.

Cholecystenterostomy, like cholecystostomy, provides for the escape of bile when its normal passage is blocked, but it differs from cholecystostomy in two essentials which modify the indications for its use. When the bile escapes into the intestine, its function in digestion as a disinfectant and enzyme is not lost; but, on the other hand, there is no reason why one should undertake an anastomosis with the intestine, where it is not required as a permanency.

Indications.—(1) The operation is indicated when the obstruction is situated in the region of the common bile-duct and cannot be removed. This may be due to extensive cicatrization or to the presence of a new growth about the head of the pancreas. In special cases, however, one should consider the question of resecting the common duct with subsequent duodenoneostomy.

(2) It is indicated in cases of temporary obstruction when there is a risk that the loss of so much fluid by external drainage may prove fatal to the patient, especially if he is in a low state (*e.g.* cholæmia, Lennander). Further, when the obstruction can be removed, but when its removal does not offer a permanent suitable escape for the bile through the normal passages (*e.g.* after resection of a tumour of the bile-ducts), an internal biliary fistula may be established with advantage.

(3) In a persistent biliary fistula following cholecystostomy. These are important cases, and the employment of internal drainage ensures a certain cure.

[1] A revision of replies to subsequent inquiries (deducting those that have died in the interval) gives 69 radical cures out of 76 still living = 90 per cent of radical cures (*l.c.*).

[2] *Annals of Surgery*, Oct. 1902.

The anastomosis should be made with the duodenum when the latter is at all accessible, and since the introduction of mobilization of the duodenum, the risks of this operation have been considerably reduced. The anastomosis with the gall-bladder is now as easily made with the second part of the duodenum as with the jejunum, even when the gall-bladder is small and contracted,—in fact it may be made with the cystic duct itself. We recently performed cystico-duodenostomy without any difficulty in a case of persistent biliary fistula. Cysto-duodenostomy is the preferable method in making an internal biliary fistula. At the same time, if the presence of cicatrices or displacement of the viscera make the performance of the operation too difficult, one must then be content with utilising the jejunum, the large intestine, or even the stomach, though the latter is, of course, the least desirable method of procedure.

Once more let us repeat, for the benefit of those who advise excising the gall-bladder as a routine procedure, that in those cases where an internal fistula is indicated, one is fortunate if cholecystectomy has been avoided at a former operation, as a cholecystenterostomosis is much easier to perform than a cholangiostomosis. One condition, however, that is essential for the former operation, but not for the latter, is that the cystic duct must be permeable: if it is not, cholecystenterostomy is out of the question.

Comparison of an Internal Biliary Fistula with External Cholecystostomy.—The last-mentioned consideration also represents the advantage of cholecystostomy, *i.e.* an external fistula over an internal one. As already mentioned, Lennander[1] has pointed out that the cystic duct may appear to be obliterated at the time of the operation, and yet becomes permeable after some hours or days when the tension in the gall-bladder has abated. In cholecystostomy this point is easily and definitely settled

An external fistula is much more easily made. It can be rapidly performed through a small incision, and is therefore to be recommended in feeble patients. Further, if the cystic duct is patent, and the gall-bladder thick and shrunken, the latter can often be utilised for an external fistula when the immediate result of an internal fistula would be uncertain.

Lastly, the advantage of draining infected bile externally must not be forgotten. This, however, is important only when the infection is severe, with pus or decomposed material in the ducts, for then the exudate must be removed as quickly and thoroughly as possible, with the help, if necessary, of antiseptic irrigation in the most direct manner possible by inserting a drain into the hepatic duct (Kehr's hepatic drainage). On the other hand, a merely catarrhal inflammation immediately subsides and the congestion is relieved by making an internal fistula.

Radziewsky[2] has made experiments to test the truth of the view held by Kehr, Dujardin, and others, that when the retention of bile has gone so far as to produce cholæmia, internal drainage exposes the patient to the danger of ascending suppurative cholangitis. He concludes that further observations are required with regard to the ill effects in man. In this respect, cholecystostomy would therefore seem to possess greater advantage.

Technique.—The long oblique incision, or, in difficult cases, the angled incision described for choledochotomy should be employed. The liver is dislocated upwards, and the duodenum mobilized as described above.

The gall-bladder is opened by an incision at the fundus large enough to admit a finger. It is then emptied, and the patency of the cystic duct determined with a probe (*vide* Cystotomy). The gall-bladder is then packed with gauze. The duodenum (which has been mobilized) is now applied to the gall-bladder without causing any tension, and the posterior serous suture inserted, after which the bowel is lightly clamped with a curved pair of intestinal clamps. The gall-bladder and duodenum are then incised and the edges sutured all round, taking up the whole thickness, after which the anterior serous layer is inserted and the anastomosis completed. A drainage tube is stitched into the gall-bladder according to the method of Poppert

[1] *Wiener Klin. Wochenschr.*, 1893, No. 37. [2] *Grenzgebiete*, Bd. 9.

and Kehr, and the latter is fixed to the parietal peritoneum round the tube. The use of a tube to drain the bile externally is essential for the security of the anastomosis.

The anastomosis is often made with a small Murphy's button or Robson's bone bobbin, and there is no doubt that such artificial aids simplify the operation. Their use is indicated when there is difficulty in approximating the intestine and the gall-bladder. The button, however, should only be employed when the gall-bladder is not much thickened: otherwise it does not hold well. Mayo Robson is strongly in favour of the button.

107. Choledochotomy. The common bile-duct is rarely the seat of primary disease, but is relatively often involved secondary to disease in the gall-bladder. The immediate risks are much greater and the indications for operative interference are more urgent. Since the year 1889, when the first choledochotomy was performed by Kümmel, followed by Thomson, Heussner, and Courvoisier, the surgery of the common bile-duct has been greatly advanced and has now reached a stage at which success can be confidently expected. Obstruction and inflammation of the common duct possess a special importance, for it is from these conditions that disease in the hepatic ducts, the smaller bile passages, the liver itself, and also the pancreas originates. It is manifest, therefore, that in the treatment of certain diseases of the liver and pancreas curative measures must be directed to the common duct.

Most commonly it is because of an impacted stone that surgical interference is required. The obstruction is most easily diagnosed by the presence of persistent icterus coming on after a previous attack of biliary colic, especially if, in addition, the gall-bladder is not distended (Courvoisier). The great risk of prolonged icterus is well known, and the serious results of cholæmia from this cause are recognised by the surgeon from the great tendency to hæmorrhage, which may even prove fatal, notwithstanding the fact that the operation has been properly performed. Radical operation has often to be postponed until the dangers of cholæmia have been overcome by performing either a cholecystostomy (*q.v.*) or cholecystenterostomy. According to Lennander, the latter operation is to be preferred, as it does not interfere with the digestive functions of the bile.

Mayo Robson regards calcium chloride, introduced by Wright, as a good prophylactic against the hæmorrhage of cholæmia. It is administered in doses of 45 gr. per twenty-four hours up to 25 gr. four-hourly by the mouth or in enemata, or, still better, subcutaneously. Mayo Robson gives it during the day before and the day after operation. Kehr also speaks very favourably of the action of this drug.

The difficulties of choledochotomy depend largely on whether the stone is impacted in the free portion of the duct, *i.e.* where it lies in the gastro-hepatic omentum, or whether it is situated in the retroduodenal portion (*i.e.* para- or intra-pancreatic) which is a not infrequent position. When the stone is in the latter position an attempt should always be made to push it upwards into the free portion of the duct, and this manœuvre is greatly facilitated by mobilizing the duodenum in the manner we have described. Mobilization of the duodenum must be regarded as a great help in all operations on the common duct, and Lorenz,[1] Payr,[2] Berg,[3] de Quervain,[4] and Sprengel (Ohl) are of the same opinion.

(a) Choledochotomy in the free part of the Duct

The oblique incision already described gives enough room if carried sufficiently high up. For difficult cases we have used the angular incision (mesial incision, the lower end of which is prolonged outwards). This angular incision is the most rational, for although the rectus is divided, the nerves which supply its upper and lower segments are preserved intact, and the function of the muscle is fully maintained after suture.

The peritoneum covering the kidney is incised along a line one finger's-breadth outside the vertical portion of the duodenum, and the latter carefully separated from

[1] Lorenz, *Deutsch. Zeitschr. f. Chir.* Bd. 79.
[2] Payr, *Deutsch. Zeitschr. f. Chir.* Bd. 75.
[3] Berg, *Centralbl. f. Chir.* Bd. 27, 1903.
[4] Quervain, *Centralbl. f. Chir.* Bd. 40, 1903.

its bed with a finger or by gauze dissection, and pulled up into the wound, *i.e.* turned over towards the middle line, exposing its posterior surface.

By retracting the liver forcibly upwards and packing off the surrounding structures, the common duct can be palpated right down to its termination. It is only when there are dense firm adhesions in the region of the gastro-hepatic omentum that this cannot be done. The knife should not be used to divide the adhesions for fear of injuring the portal vein (*vide* Cholelithotripsy). Occasionally the common duct can be examined by slitting open the gall-bladder and cystic duct (possibly removing the former afterwards). As a rule, however, if the duct can be sufficiently isolated, it may be incised directly. The stone is steadied by the fingers or by means of forceps, and an incision is made down on to it, first of all, according to Elliott, silk stays being passed through the duct at either end of the incision. Whether the incision should be made in the transverse or longitudinal axis will depend on the position in which it is most easy to insert the loops of silk.

After removal of the stone, the bile, which escapes freely, is mopped up, and if the width of its lumen will permit, the duct is examined for other stones with the finger in both directions. If the duct is too narrow to admit the finger it should be examined with a probe guided by a finger outside. The probe should also be passed in a downward direction to see if the opening of the duct into the duodenum is patent. If the latter is free the wound is then closed with two layers of sutures,—the first layer of fine catgut, including all the layers; the outer, of fine silk, including only the peritoneum. To prevent any danger should the sutures give way, a glass drainage tube should be introduced down to the line of suture.

When the wound in the duct cannot be reliably closed, or when one is not sure that the outlet into the duodenum is free, a rubber drainage tube should be inserted into the common duct up to the hepatic duct (Kehr) and the infected bile drained externally for some days. Mayo Robson fixes the tube in position with a catgut stitch. If a large wound has been made in the duct, it is better to close it and make a special opening for the tube higher up. The drainage obtained in this way is just as effective as that obtained after cholecystostomy, while the latter is only possible when the cystic duct is patent. If the gall-bladder has to be opened or removed on account of disease, the tube is passed through the cystic duct into the hepatic duct, the former being slit open if necessary.

A number of authors (Quénu, Körte, W. J. Mayo, and others) do not suture the duct completely, as a fistula in the common duct heals very readily,[1] and a much more certain outlet for the bile is provided. They close the wound in the duct only up to the point at which the drainage tube is inserted. In our opinion primary suture of the duct is only contraindicated in cases of suppurative cholangitis and cholecystitis, where, owing to obstruction of the duct, there is retention of infective bile. Mobilization of the duodenum makes the introduction of the sutures so easy that it is wrong to abandon it altogether. It seems to us that if a drain is employed at the same time it is quite unnecessary to leave the stitches long, as Poppert does, and remove them after some weeks.

W. J. Mayo, in a summary of 1100 cases of gall-stone operations, reports two very interesting cases of direct suture of the common duct with good immediate results,—the one a case of accidental injury during cholecystectomy, the other a case of excision of the gall-bladder for malignant disease involving the common duct.

Besides draining the duct, it is well to pack the wound with xeroform gauze wrapped in rubber tissue, and insert a glass tube for fear of leakage from the duct. The gauze is removed on the second or third day and the glass tube after the removal of the hepatic drain.

(b) Retroduodenal Choledochotomy

This operation[2] presents peculiar difficulties which, however, have been partly

[1] William Mayo alludes to the very rapid healing in a case where the whole length of the common duct was split and then closed with catgut sutures.

[2] Kehr mentions cases by Lane, Kocher, Jordan, Monprofit, Czerny, de Quervain, Payr, and Lorenz.

overcome by mobilization of the duodenum, for by mobilizing the duodenum, this part of the duct can be brought far enough up to allow of its being palpated and even incised.[1] The common duct is raised up along with the duodenum.

It is in the termination of the duct that a stone most commonly becomes impacted. According to Courvoisier's rule, which, however, has its exceptions, if the jaundice is associated with a shrunken gall-bladder the assumption is that the obstruction of the common duct is due to a stone; if, on the other hand, the gall-bladder is distended, the obstruction is caused by a new growth. This is important when one has to consider the question of utilising the gall-bladder for anastomosis with the intestine.

If the duodenal end of the duct can be freed sufficiently to allow one to cut directly down on to the stone, the operation is exactly similar to that just described. It is here very necessary to drain off the bile higher up by means of Kehr's hepatic drainage. It must be remembered, however, that external drainage of the bile, apart from its value in protecting the stitches in the common duct, is chiefly indicated in cases where only temporary drainage is required. Kehr also strongly supports this view.

It is always better, if possible, to establish drainage into the bowel. Lennander maintains that external drainage of the bile is followed by rapid loss of strength, especially in cholæmic patients, and this is much more the case if the duodenal portion of the duct has been interfered with where the duct of Wirsung is liable to injury. This complication occurred in a case of ours in 1903, after we had removed with much difficulty a stone impacted in the lower end of the duct by a direct incision over it; as much as 2800 cc. (approx. 5 pints) of bile and pancreatic secretion escaped from the wound per diem. Kraske has reported a similar experience where several litres a day discharged till the patient died from exhaustion.

Riedel states that in the majority of cases a stone impacted in the lowest retro-duodenal portion of the duct can be pushed upwards. Berg, Lorenz, Payr, and others have had the same experience after mobilizing the duodenum. We agree with Kehr that there are cases where this is impossible, more especially where firm adhesions in the nature of pericholedochitis are present, for then the isolation of the common duct may be so difficult that to attempt to move the stone is out of the question. Büngner, Payr, and others have shown that the lowest part of the duct is completely enveloped by the pancreas (95 per cent according to Büngner), and we have satisfied ourselves from observations on the cadaver, that the duct of Wirsung descends vertically for about an inch alongside the common duct.

In such cases Lithotripsy may be had recourse to, or an anastomosis may be made with the duodenum (duodeno-choledochostomy). De Quervain considers retro-duodenal choledochotomy is contraindicated in such cases, and believes that when it is impossible to free the duodenum owing to the presence of adhesions, the transduodenal operation should be performed.

108. Choledocholithotripsy. Courvoisier was the first to perform choledochlitho-tripsy. We early pointed out the advantage of adopting such a measure in cases where the duct is imbedded in a mass of indurated tissue from which it cannot be isolated. The operation is very simple when one has to do with soft cholesterin stones, which can be crushed between the fingers or with forceps without opening the duct. At the same time we consider that it is most suited to cases of obstruction of the common duct by a stone, where the presence of firm adhesions prevents the possibility of freeing and opening the gall-bladder, cystic duct, and common duct, so as to reach the point where the stone is impacted.

The need for crushing a stone even in the deepest part of the duct arises less often, as by mobilizing the duodenum one can grasp the stone in front and behind; the pressure employed must always be limited. Kehr and others reject lithotripsy

[1] Mobilization of the duodenum is of more service than the method (Langenbuch) described in 1898, which consists in freeing the first part of the duodenum and in detaching the vertical part forward by dividing the peritoneum. It involves less injury and goes more directly to the mark (cf. Lorenz, Payr, and others).

altogether, on the ground that fragments are left behind, and that the walls of the duct are damaged. But if lithotripsy is to be condemned on the ground that portions of the stone are often left behind, the same argument can not infrequently be urged against cholelithotomy. In 94 cases operated on by Poppert (cholelithotomy), small stones were left behind in 20 (Brüning). According to Robson, the fragments can be removed by irrigation with warm oil or a 5 per cent solution of animal soap. In 31 cases, reported by him, nothing injurious was observed.

109. Choledocho-Enterostomy. Riedel, Sprengel, and Courvoisier were the originators of this operation, in which an anastomosis is made between the common duct and the intestine. It is quite analogous to cholecystenterostomy. The bile passages are so distended by the retained bile that in all those cases in which it can be exposed and sufficiently freed, an anastomosis between the common duct and the intestine is generally quite practicable. As a rule the opening in the duct should be transverse.

It is even more necessary here, than in cholecystenterostomy, to employ external drainage of the bile above the site of the sutures. For this purpose the gall-bladder may be used (cholecystostomy) or direct hepatic drainage where there is room for it. Poppert's watertight method of inserting a tube with a wick of xeroform gauze [1] is to be commended, but we always insert a glass drain [2] as well to a corresponding depth.

The manner in which the drainage is carried out is of great importance. We cannot as in choledochotomy simply leave a portion of the line of suture open and allow the bile to escape thus. The sutures must all be absolutely secure, so that no bile or intestinal contents may escape, either primarily or secondarily. Mayo therefore urges that no gauze packing should be passed down in contact with the line of sutures that is not wrapped round in rubber tissue so as to facilitate its removal. It is more simple to use a glass tube, and fix it with catgut in such a way that it does not come in contact with the sutures at all.

110. Duodenocholedochotomy and Duodenocholedochostomy.[3] A stone impacted in the ampulla of Vater is best removed by an incision through the duodenum [4] when mobilization of the latter is impossible. Kraske holds this opinion now, having previously, like us, injured the duct of Wirsung. Kehr has also successfully employed this method in 20 out of 210 cases of choledochotomy, with only two fatalities. Pantaloni differentiates between the transduodenal lithotomy first performed by M'Burney and the transduodenal choledochoduodenostomy recommended and performed by us. We described it as internal choledochoduodenostomy to distinguish it from that in which an anastomosis is made from without, as *e.g.* cholecystenterostomy and choleangioenterostomy.

(a) Transduodenal Choledocholithotomy

The operation was performed first in 1891 by M'Burney, then by Czerny and Mayo Robson, and up to the end of 1899 it had been performed twenty times with two deaths. It is especially desirable to get free access, and the incision which we have planned, similar to the one used by Pozzi, should be worth recommending. It consists in an incision convex or angular below and to the left, with a median vertical limb, and lower transverse limb passing through the right rectus abdominis.

The middle finger is passed in below, and the duodenum, which has been mobilized, is raised up along with the lower end of the duct and the stone, while the forefinger and thumb hold the gut above and below and keep it closed. We incise the duodenum transversely, because we consider an incision parallel to the vessels to be more rational. The next point is to decide whether the stone can be extracted through the opening of the ductus choledochus with or without an incision into Vater's ampulla.

[1] Note that no dry or strongly antiseptic gauze should be placed in the wound without previously immersing it in carbolic lotion.

[2] Krukenberg proposes to twist the gall-bladder (after Gersuny) before suture, in order to prevent backflow.

[3] Cf. technique of Collins, Kraske, Mayo Robson, Kehr, and Zeller with Kehr.

[4] Lehmann (Heidelberg Klinik) has collected 22 cases (vide *Beiträge z. klin. Chir.* Bd. 42).

According to Collins, who, as opposed to M'Burney, merely dilates the papilla instead of splitting it up, the ampulla is situated at the junction of the posterior and internal wall of the duodenum, below a prominence of the mucous membrane, which is placed 3 cm. below the angle between its first and second parts. Collins introduces a probe, followed by a pair of toothed forceps (a pair of our own artery-forceps would probably answer the purpose), with which he extracts the stone. M'Burney, after introducing a sound, incises the opening for 1 cm., and presses the stone out from behind: he then sounds the canal, as the stones are frequently multiple. They may frequently be pushed downwards by manipulating the duct from without. Any bile which may escape may be mopped up with gauze compresses. The duodenum is closed in the usual way by two rows of continuous sutures. If the peritoneum has not been soiled the abdominal wound is closed: as a rule it is well to put in a drain, such as a strip of xeroform gauze, in the space behind the duodenum.

(b) Transduodenal Choledochoduodenostomy (interna)

In cases in which very large stones have become impacted in the lower part of the common duct, but not actually at its orifice, when access from without is rendered difficult on account of adhesions, when the stone appears to be fixed in this position, and lastly, when it is found impossible to pass a probe in from the papilla, or when the papilla cannot be found without greatly prolonging the operation, the procedure which we adopted in 1894, and which has been repeated by Kehr, Mayo Robson, Sprengel, and others, with equally satisfactory results, is indicated. At the time of our operation we were unacquainted with M'Burney's method.

The operation is as follows:—The stone situated behind the duodenum is fixed with the finger, and after the duodenum has been opened, as above described, at a point opposite to the stone, a longitudinal incision is made down on to the stone. The distended common bile-duct is more likely to be found applied to the duodenum in the whole length of the necessary incision, if the latter be made in the long axis of the stone. We advise, as does Elliot for choledochotomy in general, that the wall of the duodenum and bile-duct right down to the stone should be seized with artery-forceps as soon as incised, and, if necessary, a stitch may be passed through the middle of the entire thickness of both edges of the wound, so as to keep up the apposition of the two walls and facilitate a choledochoduodenostomy, as we have termed the operation, if this be required. After the stone has been extracted the canal should be probed—with the finger if possible—so that other stones may not be overlooked. The mucous membrane of the ampulla is then united to that of the intestine with interrupted sutures, so as to encircle the whole thickness of the walls of both organs. In Kocher's and Kehr's case, in which this method was adopted, no evil results ensued from chance regurgitation of intestinal contents.

To insert no sutures, as is Mayo Robson and Sprengel's practice, is only safe when the stone is situated in the part of the common duct which traverses the wall of the duodenum, and not farther up, that is when one can be sure that infective bile and intestinal contents cannot filter through between the walls of the duodenum and common bile duct. The higher up the stone is, therefore, the less reliable is this method, although it is the simplest. The sutures also arrest any bleeding.

The after-treatment is the same as for transduodenal lithotomy.

Appendix; Choledochectomy (Resection of the Common Duct). In Mayo's case of choledochectomy already alluded to the duodenum was mobilised by Kocher's method, the peripheral portion of the divided duct brought up and united to the upper end with catgut sutures including the whole thickness, after drawing the surrounding portions of peritoneum together with supporting sutures. The suture of the duct was not complete, and a drain was passed down to it.

Kehr mentions three cases of resection of the supraduodenal portion by Kehr and Doyen, and three of the retro-duodenal portion by Halsted, Czerny, and Körte. Halstead implanted the divided common duct and the duct of Wirsung into the

duodenum, and subsequently performed cysticoduodenostomy in addition. His patient recovered and lived till recurrence took place a year and a half later.

When a radical operation for carcinoma of the common duct is undertaken, success depends on (1) whether the new growth can be sufficiently isolated to allow of its complete removal, (2) whether it is possible to retain a healthy portion of the hepatic duct which can be freed and utilised for suturing; (3) and, further, whether the duodenum can be securely closed, and the hepatic duct (or remainder of the common duct) sufficiently approximated to permit of a secure hepaticoduodenostomy, with possibly implantation of the duct of Wirsung into a special opening in the duodenum, as in Halsted's case. The introduction of mobilization of the duodenum has now rendered many operations possible which were formerly impracticable.

111. Hepaticotomy and Hepaticolithotripsy. We performed the first hepaticotomy in 1889[1] (cf. Pantaloni), and since then it has been frequently performed by Cabot, Elliot, Czerny, Delagenière, Meriat, and others. The chief credit for having demonstrated the accessibility of the hepatic duct for surgical measures on a larger scale is due to Delagenière, while Kehr, especially by introducing hepatic drainage, has opened up a large field of operations. It is rare that the hepatic duct itself is the object of surgical interference either for stone or new growth. Delagenière states that in obstruction of the common duct by a stone the gall-bladder is undoubtedly shrunken, as stated by Courvoisier, but the hepatic duct is just as regularly dilated. The same is true for other forms of biliary obstruction.

(a) Hepaticotomy

A large incision is required for the examination and exposure of the hepatic duct. One can employ an oblique incision similar to that recommended for getting access to the bile-ducts, *i.e.* obliquely across the rectus, or better still, the angular incision. In difficult cases it may be necessary to fracture the 7th or 8th ribs at the junction with their cartilages and displace the costal margin upwards. Halsted found this procedure of great value in one case.

Technique.—The hepatic duct may be exposed for the extraction of a stone in the following manner:—The liver is turned well upwards and the portal vein exposed, after which a finger is inserted behind the free border of the gastro-hepatic omentum through the foramen of Winslow, and the hepatic duct grasped between two fingers and isolated. It is then incised between two silk stays (Elliot) and subsequently sutured if this can be done securely as in Delagenière's cases. According to Marcel Baudouin, and Kehr, however, it is always safer to drain the duct with a tube 6-8 mm. thick.[2] One should always attempt first of all in these cases to push the stone down to a more accessible part of the duct. If it is impossible to reach the duct on account of the density of the adhesions, we have then a choice of two other methods: (1) When the gall-bladder is thickened and diseased, we may excise it, slit up the cystic duct if the latter is not already distended, and through it reach the lumen of the hepatic duct; (2) if there is no indication for removing the gall-bladder, the latter should be opened, and access got to the common and hepatic ducts from within, the cystic duct, if necessary, being slit up in the manner already described for a difficult case of choledochotomy.

(b) Hepaticolithotripsy

At a discussion on choledocholithotripsy held in 1890 we remarked that the principle might with advantage be applied to a stone in the hepatic duct, and this has since been carried out by Mayo Robson, Baillet, and Delagenière. The latter points out that occasionally the stone may be crushed from within after opening the

[1] "Beiträge zur Chirurgie der Gallenwege," *Deutsch. med. Wochenschr.*, 1890, No. 13 ff.

[2] According to Delagenière, direct hepatic drainage was first employed by Cabot after the removal of a stone for hepaticotomy, while Delagenière introduced indirect drainage through the gall-bladder. Kehr, however, deserves most credit for having developed the method.

gall-bladder and cystic duct. The method is worth trying in difficult cases; the results have all been good, and the theoretical objections brought against it have been proved to be groundless.

112. **Hepaticostomy and Hepaticoenterostomy.** There are four ways in which infective bile can be drained from the hepatic duct: (1) by indirect external drainage (Hepaticostomia externa indirecta), *i.e.* when a tube is passed into the hepatic duct by way of the gall-bladder and cystic duct (Kehr), or if the gall-bladder be already removed simply through the cystic duct; (2) by direct external hepaticostomy (hepaticostomia externa directa), *i.e.* by suturing the dilated hepatic duct to the abdominal wall. It is only in cases where the duct is greatly dilated that this is

FIG. 322.—Hepatico-duodeno-tomy after Mayo for obliteration of the common bile duct, cholecystectomy having been performed at a previous date. The figure shows clearly the manner in which the duodenum, after mobilisation, is pulled up to the hilum of the liver, and how it is fixed with serous sutures to the hepato-duodenal ligament. At the most convenient point to the end of the hepatic duct the bowel is opened and sutured to the duct with catgut sutures, including the whole thickness of the wall. In the figure the posterior sutures have been introduced.

possible. (3) By trans-hepatic hepaticostomy (hepaticostomia transhepatica), as has been performed by Thomson and Mayo Robson (*cf.* hepatostomy). (4) Lastly, by hepaticoenterostomy (Kehr).

The technique depends on the anatomical changes present in each individual case: no general description will apply to every case (*cf.* cholangio-enterostomy below).

We have described a case (*loc. cit.*) in which there was a high degree of cystic distension of the hepatic duct, and Delagenière[1] has alluded to a case of Nicholaysen

[1] *Contribution à la chir. du canal hépatique*, Paris, 1896.

and Besançon in which a communication with the intestine would have been relatively simple. Kehr has accomplished it.

W. Mayo has prepared some very beautiful diagrams to illustrate the manner in which this operation is performed, and with his permission we reproduce one of his characteristic illustrations, which sufficiently explains the method.

In Mayo's case the gall-bladder had been removed at a previous operation. It was otherwise in the following case published by Halsted which shows how, by preservation of the gall-bladder at a first operation, it may be turned to good account in a case of severe recurrence. Halsted designates the operation performed by him under the circumstances mentioned as hepatico-cholecystenterostomy.

In devising the operation in this case, he utilised the idea which we shall consider under hepatocholangioenterostomy (see next section), namely, of using the gall-bladder as an intermediate reservoir for the bile in establishing a connection between the upper (para- and intra-hepatic) bile-ducts and the intestine. The cystic and common ducts were both obliterated, the gall-bladder and hepatic duct being dilated.

He first anastomosed the hepatic duct with the gall-bladder and then the gall-bladder with the duodenum. The result was highly successful. The patient had previously been operated on, and had it not been that, fortunately, the gall-bladder had been retained, this second operation could not have been possible.

113. External Hepatocholangiostomy and hepato-cholangioenterostomy.[1] (*a*) *Hepatocholangiostomia externa.* As a result of an operation we performed in 1882, we were able to point out that the small bile-ducts and biliary canaliculi can become so dilated from obstruction as to become visible on the surface of the liver, where they may even give way and form biliary abscesses, both inside and on the surface of the liver. Bearing this in mind we can therefore provide a temporary escape for the bile, until the obstruction either spontaneously disappears or is removed. In our first case the biliary fistula healed immediately after a stone was discharged (with severe colic) six months after operation.

The operation differs according to the stage at which the patient comes under treatment. If no rupture has occurred, as in Thomson's case, the swelling is exposed over its most tender part, and the liver capsule is stitched all round it to the parietal peritoneum. The "biliary abscess" is then opened, and any stones, or, as in our case, necrotic liver tissue, removed. If there has been perforation on the surface, and the contents have been walled off by adhesions, it is sufficient to lay open the cavity. The hæmorrhage may be very considerable, as in our case, and require packing. Generally speaking, however, one finds the operation comparatively simple, and as our case shows, the obstruction may even disappear spontaneously. It affords immediate relief from the pain and dangers of these conditions, and should be borne in mind when occasion arises.

Hirschberg[2] has described a different operation from ours and Thomson's, in which, after the abdomen has been opened and the liver exposed, a trocar is pushed into the liver and its track dilated until it will admit a finger, when the track is packed with a strip of gauze and kept open with a drainage tube. In this simple manner the retention from cholangitis or hypertrophic cirrhosis of the liver can be at once relieved, so that the method is decidedly worthy of notice. One must not overlook the fact that it is chiefly symptoms and not causes which are treated.

(*b*) *Hepatocholangio-enterostomy.* Recommended by Marcel Baudouin and Langenbuch, this operation was first performed by Jordan[3] and Kehr,[4] while Enderlen[5] and Zumstein have described the anatomical conditions from experimental observations. In both cases the patient died. Notwithstanding Kehr's assertion that external biliary fistulæ are followed by all sorts of calamities which can be avoided by making a fistula into the bowel, it is surely better to avoid the still greater calamity of losing the patient.

Kehr restricts the operation to cases where there is definite obstructions due to

[1] "Beiträge zur Chirurgie der Gallenwege," *loc. cit.*
[2] *Berliner Klinik*, Oct. 1902.
[3] *Kongress d. deutschen Ges. f. Chir.*, 1899.
[4] *Centralbl. f. Chir.* Bd. 7, 1904.
[5] *Grenzgebiete*, Bd. 14, 1904.

cicatrices or a new growth, but the more roundabout method suggested by Enderlen is often to be preferred. He first of all makes an external biliary fistula, and subsequently unites it to a piece of intestine (jejunum) which has been pulled up, and lastly closes the skin wound at a third operation.

A two-stage operation must always be taken into consideration in which first of all the dilated bile channels in the liver are opened up and packed, the ends of the packing being left outside (at the same time choice being made of a suitable spot on the under surface of the liver for later union with the bowel). When the shedding of necrotic portions of the liver described by Enderlen and Zumstein has ceased, and cicatrisation and the processes of regeneration are established, the duodenum or jejunum is then sutured to the liver so that the bile may be discharged into the intestine. The suture line is strengthened by stitching the omentum over it.

Greater security is got by making a fistula in the duodenum, into which an absorbable drainage tube is inserted, such as Mayo Robson's decalcified bone drain, which is fixed to the liver at the point of exit of the bile.

From the evidence of Kehr's case it seems to us a mistake to excise the gall-bladder without strong indications, because the bile passages in the liver can be most easily opened through its deeper wall, while one can also utilise the anterior wall for anastomosis with the intestine, as was done by Halsted. A hepato-cholangio-cystenterostomy, to give the operation its full descriptive name, is then possible.

(d) Surgery of the Liver (apart from the Ducts)

114. Surgical Treatment of Cirrhosis of the Liver. Affections of the bile-ducts yield far better to surgical treatment than does disease in other parts of the liver, but it must not be forgotten that most attention has been given to the gall-bladder and larger ducts, while the appearances at autopsies have too often revealed other conditions which might have been dealt with surgically.

This applies specially to certain forms of cirrhosis of the liver, and in particular to the hypertrophic variety. In the atrophic form, thanks to Talma's lead, we have learned to a certain extent how to treat one of the leading symptoms, namely ascites, not, however, always with permanent relief.

In the hypertrophic variety of cirrhosis, especially when associated with jaundice, much better results can be obtained if the operation is done at the right time.

The cause of the hypertrophy is often to be found in chronic biliary congestion. This has been clearly proved (cf. in some of our own cases) where the typical clinical and anatomical changes of hypertrophic cirrhosis have been traced to a circumscribed carcinoma of the bile-ducts. Other cases, *e.g.* those of Cumston,[1] in which the jaundice and ascites disappeared by draining the gall-bladder for three or four weeks, confirm this view. It may be, therefore, made a rule in all conditions of the liver associated with jaundice, in which the jaundice is obviously not due to some inoperable condition, such as cancer of the liver or pancreas, that the chief indication is to relieve the biliary congestion. The method in which this is to be done is decided by an exploratory laparotomy, in which the bile-ducts are exposed in their whole length.

It is obvious that in these cases, just as in obstruction of the common duct with a stone, operation must not be delayed till the changes in the liver are advanced and cholæmia has supervened. The surgery of the bile-ducts has certainly proved that the risks of the operation are attributable to delay and to the development of this type of toxæmia.

A careful examination of the ducts from the hilus of the liver to the duodenum will decide whether the obstruction to the bile is removable, be it a stone, new growth, or cicatrix, within or without the duct. W. Müller[2] has described a case where the only explanation of the ascites was to be found in adhesions in the region of the portal fissure. The condition was cured by operation. The results may be equally good in similar conditions of congestion in the region of the bile-ducts.

If no obstruction is found in the region of the larger ducts, but some doubt

[1] *American Journal of Med. Sciences*, July 1905. [2] Langenbeck's *Archiv*, Bd. 66.

remains, drainage must be carried out, using the most simple method, viz. cholecystostomy. But if one is convinced that there is no such obstruction, the question has to be considered of performing hepatocholangiostomy, *i.e.* draining the bile direct from the liver. We were the first to perform this operation. Hirschberg recommends it in another form for the treatment of hypertrophic cirrhosis of the liver.

The results of Talma's operation in draining away the blood in this way in cases of venous congestion have been most successful.

115. Talma's Operation for Ascites (Cirrhosis of the Liver). The principle of Talma's operation, which was simultaneously recommended by Drummond and successfully carried out by him and Morrison, consists in the formation of a venous communication between the portal and systemic circulations when the former is obstructed (generally due to cirrhosis of the liver, but not necessarily accompanied by an increase of the connective tissue). The chief symptoms are ascites and hæmorrhages, and it is for the relief of the former that the operation is undertaken. Bunge [1] regards hæmorrhage into the alimentary canal as the special indication.

In our previous edition we referred particularly to the works of Friedman and the experimental researches of Tilmann, but since then much has been published regarding the results as well as the indications for, and contraindications to the operation, while much light has been thrown on its method of action experimentally. As a result the operation is now regarded with much more confidence. Koslowsky records 168 cases with 45 per cent of cures, Greenough 42 per cent in 105 cases, Monprofit [2] 70 per cent in 224 operations, of which 35 per cent were permanent. Bunge states that one-third of his cases were cured, while improvement took place in another third. According to Wheeler, the best results are got in cases of hypertrophic cirrhosis of the liver. He agrees with Bunge in regarding icterus as a contraindication. But this view only partially holds good, for when jaundice is present, the most urgent indication is to drain off the bile in one of the ways described in section 114, after which the Talma operation may be performed. Often, however, it may not be required. As already pointed out, operation should not be considered when the patient is in a low state, as the result of disease of the heart or kidneys, or when there is marked atrophy of the liver. The latter condition is recognised by the presence of bile in the urine and by its absence or diminution in the fæces. According to Bunge, a diminished excretion of urea, increased output of ammonia, and the presence of lævulose in the urine, are to be regarded as serious, if not direct contraindications.

Kusnezow, Ito, and Omi have made a careful experimental study of cases in which clinically a good collateral circulation had been established by operation.[3] After omentofixation, the blood in the portal system is chiefly distributed by way of the gastro-splenic and gastro-epiploic veins into the omental veins, and through these into the epigastric veins, reaching the femoral vein *via* the superficial epigastric, the axillary *via* the thoraco-epigastric veins, and higher up by the intercostal and internal mammary veins.

It follows, therefore, that if the spleen be utilised instead of the omentum as the anastomosing factor with the abdominal wall, a more direct anastomosis is provided.

Kusnezow has shown that ligature of the portal vein in animals causes death in spite of omentofixation, because of the insufficiency of the anastomosis below the gastro-splenic vein. It is on this ground that Ito and Omi assert that "epiplopexy is inadequate, and that extensive adhesions among the abdominal viscera as well as with the abdominal wall are essential to success."

Technique. In properly selected cases, either epiplopexy or splenopexy may be performed. As the former is much more simple, it has been more generally used. Splenopexy is performed subsequent to omentofixation, if the latter has not been

[1] *Die Talma-Drummondsche Operation*, Jena, 1905.

[2] *Congrès français de chirurgie*, Oct. 1904.

[3] Cf. C. Wheeler, Talma-Morison's operation, *Brit. Med. Jour.*, Oct. 1905, with autopsies; *vide* also Prisson, *Deutsch. Zeits. f. Chir.* Bd. 75.

successful. We have had several excellent results from the latter operation. It is far the least dangerous operation if properly performed.

(*a*) *Exo-epiplopexy and simple Epiplopexy.* An incision is made in the middle line above the umbilicus, after which the steps of the operation differ according as to whether one wishes to establish extra- or intraperitoneal adhesions. The simplest method is that recommended by Narath [1] in which the omentum is sutured underneath the skin. For this purpose a pocket is made on the left side with a blunt instrument or a finger protected by a sterile rubber glove, and into this a piece of omentum is stitched. Narath has demonstrated the early appearance of the anastomosing branches between the subcutaneous veins and the imbedded omentum.

Subserous implantation has also proved satisfactory. The fascia of the linea alba is split and a suitable pocket is made on the left side external to the peritoneum. According to Schiassi, Tieschi, and Pascale, the extraperitoneal is more reliable than the intraperitoneal fixation.

The parietal peritoneum is then incised and the omentum pulled through, dragging on the transverse colon being avoided.[2] The portion of omentum that has been pulled through is then stitched all round to the edges of the opening in the peritoneum, or even the deep fascia with interrupted sutures, without constricting it. The fascia and skin are then carefully sutured. No drainage.

The ascitic fluid should be drawn off (aspirated) by means of a long glass tube passed down into the flanks and into the pouch of Douglas. There is a risk in using a permanent drain, as unless the after-treatment can be carefully carried out, it may be the means of introducing sepsis. It is better to puncture the abdomen repeatedly.

Instead of the exœpiplopexy described, epiplopexy can be performed by simply suturing the omentum to the parietal peritoneum without making a pocket for it outside, or by fixing the omentum in the space between the liver and the diaphragm. Guillot and Courbet have employed this method with success. Not only does it drain the portal system in the liver, but it provides fresh communicating vessels with the nutritive system of the hepatic artery. The advantage of fixing the omentum inside the abdomen is that there is less chance of a hernia resulting. Hernia is avoided in exœpiplopexy by means of careful stitching and by selection of a piece of omentum which has a good vascular supply, and which is not too large. Equally good results are got by roughening and scraping the surface of the liver, spleen, omentum, and intestine, and establishing adhesions by these means.

(*b*) *Splenopexy.* Splenopexy is undertaken when omentofixation has either failed or has not been practicable. The spleen is brought out through an incision along the costal margin, and according to Rydygier and Bardenheuer, is then either entirely or partially fixed, according to its size, in a pouch between the parietal peritoneum and the muscles. When there is difficulty in pulling it forward sufficiently, Depage, Franke, and Schlange advise cutting out a flap of muscle and peritoneum, and suturing the spleen to it.

Splenopexy cannot, therefore, be undertaken as a routine operation, for if the spleen is small and situated high up, its fixation is both difficult and uncertain (in one of Bunge's cases the spleen became free again).

Another method of draining the portal system worthy of consideration is by means of Eck's fistula, which consists in directly anastomosing the portal vein and the vena cava. According to Tansini [3] the portal vein and vena cava are exposed and temporarily clamped, with rubber-covered clamps: the former is cut across and the distal end inserted into a lateral opening in the vena cava to which it is sutured with continuous silk (termino-lateral anastomosis). Animals so treated have remained well for months.

Vidal performed the operation on man. The patient lived four months, but subsequently succumbed to acute pyæmia.

116. Hepatopexy. Fixation of the liver may be indicated for the relief of

[1] *Centralbl. f. Chir.* Bd. 32, 1905.
[2] In one of Franke's cases kinking of the colon occurred.
[3] *Centralbl. f. Chir.*, 1902, No. 36.

symptoms, *e.g.* pain, in such conditions as ptosis or floating liver. According to Böttcher,[1] hepatopexy was first performed in 1887 by Michel, in 1890 by Langenbuch, and in 1891 by Gérard-Marchant. In 1900 Böttcher was able to collect 23 reported cases.

When the liver is pushed down as a result of tight-lacing, the operation is quite easy. According to Riedel, if an enlarged gall-bladder is at the bottom of the trouble, cholecystostomy should be performed. In 1884 Billroth performed the first hepatopexy for partial ptosis of the liver of this type. Amputation of the pendent lobe practised by Langenbuch is a radical measure. Simple hepatopexy is intermediate between the two.

Technique. We employ the oblique incision two fingers'-breadth below the costal margin described in the chapter on surgery of the gall-bladder. Langenbuch, Ferrari, Franke, and also Poppert (according to Böttcher) employ this incision.

It must be large enough to allow one to get a good view of the parts, so that one may not be hampered for room in inserting the sutures. In this respect the angular incision already described is to be recommended. With the patient in a sloping position, and if necessary the head dependent, the liver is pushed up into its proper position, and a suitable spot on the parietal peritoneum selected for fixation. The liver is then allowed to slip down again, and two, three, or possibly more sutures are inserted above the upper end of the wound through the parietal peritoneum and deep fascia.

If there are fibrous changes on the surface of the liver, as are found after tight-lacing, these are taken advantage of for fixing sutures. One end of the suture is now thread on a fine curved needle, and passed through the surface of the liver at the desired spot and tied to the other end, the liver, at the same time, being held in the proper position with the patient's head lowered. We use silk exclusively for this purpose and consider catgut a mistake. It is important to insert gauze packing as well as the stitches, as it promotes strong surface adhesions (Langenbuch, Franke, Tascherning, and Poppert). We use strips of xeroform gauze wrung out of 5 per cent carbolic lotion laid between the stitches on the convex surface of the liver. This is the same principle as is employed in nephropexy, and not only does the gauze produce adhesions, but it also forms firm scar tissue round the incision which supports the replaced liver. The packing should not be removed for 8 to 14 days. The wound is completely sutured up to where the gauze is inserted.

In complete prolapse of the liver associated with a general visceroptosis and a lax abdominal wall, one has a choice between Legueu's method, in which the liver is suspended by means of strong looped sutures which include the whole thickness of the organ, and which hold it up as it were in a sling, or Péan's method, which consists in making an artificial diaphragm out of peritoneum below the liver, or lastly Depage's method of excision of the abdominal wall and closure by sutures.

117. Liver Abscesses and Cysts (Echinococcus). No further description is necessary of the treatment of an abscess or cyst of the liver accessible from the front or back by laparotomy. After division of the soft parts, one can either, if the liver is not adherent, wait until adhesions are formed, *i.e.* operate in two stages, or, as is usually done, isolate the area to be incised by means of a circular continuous suture which unites the visceral and parietal peritoneum.

Special measures have to be taken in opening cysts on the convex surface of the liver by way of the thorax—transthoracic laparotomy. For a description of this operation see Section 86, page 502.

118. Resection of the Liver. As the results of immediate laparotomy for injuries of the liver associated with severe hæmorrhage have shown that recovery can follow widespread lacerations of that organ, surgeons need no longer hesitate to carry out extensive resections. Out of 543 cases collected by Elder[2] in 1887, the death rate was 66·8 per cent, while according to Thöle's figures (399 cases) it is only 39·8 per cent.[3]

[1] Böttcher, *Über Hepatopexie*, Leipzig, 1900. [2] Langenbeck's *Archiv*, Bd. 34, 1887.
[3] *Deutscher Chirurgenkongress*, Berlin, 1906.

Nötzel[1] has published a case in which the "right lobe of the liver was almost torn in halves," and Wilms reports a case of complete separation of the left lobe where recovery followed suture and plugging. G. Costa[2] reports success in a similar extensive injury.

Thöle reckons the real mortality as only 16·8 per cent out of 148 resections of the liver.

Keen, who has three times successfully excised tumours of the liver, and who has great faith in this operation, quotes the cases collected by Cushing and Down, viz. seventy-six, with a mortality of only 14 per cent. These cases included twenty hydatid cysts, seventeen carcinomata, and twelve syphilitic tumours. In his last case Keen removed a large part of the left lobe of the liver. As a rule the operation was performed when a tumour was present which could be shelled out, or when a diffuse tumour had developed either in a pendent lobe or at the margin of a normal lobe, for example in carcinoma of the gall-bladder involving the liver tissue.

The deaths which have occurred in cases of resection of the liver were nearly all due to hæmorrhage and shock. Keen only mentions three cases of embolism and sepsis. One of our cases died as the result of a secondary prolapse of intestine.

Arrest of hæmorrhage is therefore the key to the operation. There are a number of experimental studies bearing on the subject, namely, by Kusnetzow, Pensky, and Auvray, and propositions by Cecherelli, Bianchi, Segale, and others. It is not possible to lay down general rules, as the cases are so diverse.

The result of the very thorough experiments by Kusnetzow and Pensky may be considered established, viz. that the large veins in the liver tissue can be satisfactorily ligatured separately by passing a stitch round them. In removing the left lobe of the liver, Keen successfully arrested the hæmorrhage from these large vessels by means of five ligatures. As he divided the tissues severe hæmorrhage occurred, whereupon he put his finger on the lumen of the open vessel, passed a needle threaded with catgut round it, and had the ligature slowly tightened by an assistant.

Parenchymatous hæmorrhages from small vessels can, as a rule, be safely and permanently arrested by plugging. But in spite of this, it is quite possible that before the tampons can be properly secured in position, a very severe hæmorrhage may occur as the liver tissue is being divided.

In order to be sure that the operation before its close shall not lead to an exhausting loss of blood, it is well to sever the liver with the thermo-cautery, always keeping the fact in view that the instrument must be allowed to act very slowly and at a dull red heat. Keen, who has been very successful with his cases, employed the thermo-cautery when he was unable to perform simple enucleation. A method of arresting hæmorrhage which we use, and which is well adapted to some cases, is the application of pressure-forceps. We used the large powerful pressure-forceps which we employ for resection of the stomach. In a case of carcinoma of the right lobe of the liver along with carcinoma of the gall-bladder, it was found by careful examination that the condition of the parts was very suitable for operative interference. The gall-bladder was distended; the cystic duct could be isolated, ligatured, and divided. On the liver a typical carcinoma nodule with depressed centre at once presented in the wound. Firm adhesions on the under surface led to injury to the serous membrane, which resulted in serious venous hæmorrhage. This was arrested by tampons. In spite of the great thickness of the right lobe, which was in no way divided from the rest of the liver, but was greatly elongated, we put on a pair of large forceps behind the nodule, closed them tightly, and so crushed the liver tissue. The forceps kept their place very well, and stood the strain perfectly. The liver, together with the gall-bladder, was simply cut away with a knife close up to the forceps.

The forceps were kept on for forty-eight hours, and were then removed without any hæmorrhage. On the grounds of this experience we can recommend the use of such forceps, and we advise that they be closed as tightly as possible, for though the liver tissue is friable the serous covering is very tough.

The forceps are therefore of great service, although they have the great disadvantage that if left *in situ* it is very difficult to approximate the edges of the wound

[1] *Beitr. z. klin. Chir.*, Tubingen, 1906. [2] *Policlinico*, 1905.

exactly, and, consequently, if vomiting occurs a prolapse of the gut is apt to result. This happened in two of our cases, once without ill effect, but once with a fatal result. The peritoneum and fascia must, therefore, be closed in spite of the presence of the forceps, and the latter should be removed through the smallest gap possible. Or the forceps may be replaced, as in the case of the stomach, by a mattress suture inserted behind them, and, if necessary, a continuous suture over all. If, in the use of the thermo-cautery, care be taken to make the gap wedge-shaped a few serous sutures may be put in. The after-treatment consists in packing with xeroform gauze (without exception when an exposed wound surface is left) for forty-eight hours, and a drain must be introduced on account of the escape of blood and the outflow of bile. The peritoneum and fascia must be carefully sutured.

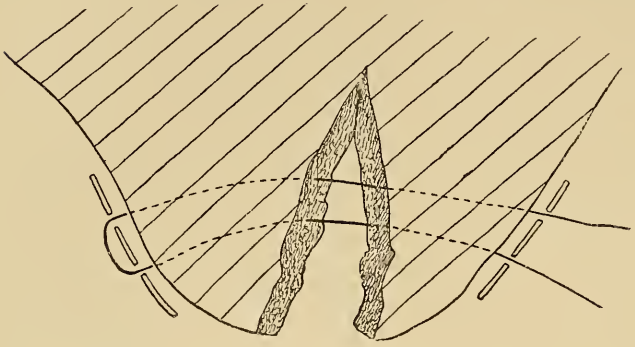

FIG. 323.

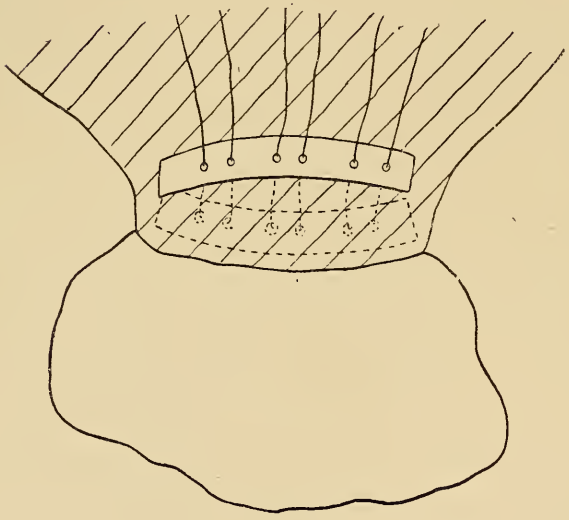

FIG. 324.

As it is desirable that the abdominal wound should be closed for fear of complications, it is better to employ some means of arresting hæmorrhage which can be buried in the organ, rather than use forceps. Payr and Martina [1] have investigated this matter experimentally, and Thöle [2] has reviewed the literature on the subject.

B. Müller [3] has shown that the oozing that takes place during the division of the liver can be controlled by injections of adrenalin (1 in 1000 to 1 in 10,000 in saline) as well as by the thermo-cautery. By making a sufficient area anæmic no bleeding occurs, while the larger vessels can be clearly seen, temporarily clamped, and subsequently ligatured according to Kusnetzow's method.

At the same time both temporary and permanent control of the vessels can be got by "ligature *en masse*." The ligature is tied tightly so as to cut its way through the friable tissues as far as the vessels. It appears to us to be a suitable and more certain method of employing the ligature *en masse*, to apply one ligature after another and to tie them in the course of the removal of the portion of liver or tumour. This does not exclude the ligature of isolated vessels for greater security, as they become visible in the incision.

[1] *Kongress d. deutschen Ges. f. Chir.*, Berlin, 1906.
[2] *Cod. loco.*
[3] *Munch. med. Wochenschr.*, 1904, s. 526.

The "plate-sutures" used by Cecherelli, Cernezzi, Segale, Beck, and Bianchi, act in an analogous way to ligature *en masse*. From numerous experiments on animals, Payr and Martina have found magnesium plates the most reliable, as they stimulate the formation of new connective tissue, and become entirely absorbed in a few weeks.

Figs. 323 and 324, taken from Payr's paper in the *Centralblatt*, give a sufficient idea of the method. One disadvantage connected with the use of plates is that if the sutures are pulled too tight necrosis is apt to occur, which may give rise to complications, especially of an embolic type (pneumonia). And although the good results obtained in animals by Payr and Martina cannot be doubted, we might point out that the necrosis which occurs from the use of plates is more serious than that produced by "ligature *en masse*" because the former remain embedded in living tissue, which is not the case with the latter method.

If possible, the portion of liver excised should be wedge-shaped, whichever method is adopted to arrest the bleeding, so that the peritoneum may be completely united by sutures. The latter sutures should be silk, while the material in ligature *en masse* should be absorbable catgut.

If the peritoneum cannot be completely brought together, a strip of xeroform gauze wrung out of carbolic is placed on the line of suture, and one to three drainage tubes are inserted between the stitches in the abdominal wall down to it.

119. Ligature of the Hepatic Artery and Portal Vein. In view of the increasing number of extensive operations now undertaken in the region of the hilum of the liver for disease of the bile-ducts, duodenum, and pylorus, it is well to know what measures one should adopt in case of injury to the portal vein or hepatic artery. If a lateral ligature cannot be applied to a tear in the vein, there is no choice but to plug the wound. Death does not necessarily result, and several cases have been reported in which very severe bleeding about the hilum of the liver has been arrested by plugging.

Experiments on animals have shown that it is possible to divide the vein, ligature the central end, and implant the peripheral end into the vena cava (Tansini). But to what extent this can be carried out in man (Eck's fistula) remains to be seen.

Hitherto an accidental injury necessitating ligature of the hepatic artery during a difficult excision of the pylorus has proved fatal from necrosis of the liver. Kehr, however, successfully applied a proximal ligature in the case of an aneurysm of a branch of the hepatic artery which had perforated into the gall-bladder.

Kehr mentions Mester, Langenbuch, Ehrard, and Hausson's work, and recently Haberer has repeated Cohnheim and Litten's experiments, which show that it is possible to ligature the trunk of the hepatic artery, as a collateral circulation is established by the gastro-duodenal and right gastro-epiploic arteries.

If, on the other hand, the hepatic artery is tied below the point where these branches are given off, necrosis of the liver as a rule sets in. Necrosis will also occur if the hepatic is ligatured after the arteries of the stomach have been divided, *e.g.* in pylorectomy.

According to Kehr's experience necrosis need not follow ligature of the hepatic artery if the circulation has been affected by the formation of an aneurysm. In this case, as mentioned by Langenbuch and demonstrated by Haberer, a collateral circulation is formed between the phrenic arteries through the coronary ligaments and the capsule of Glisson.

In regard to the technique, just as in a difficult case of exposure of the bile-ducts, it is absolutely essential to have plenty room (*vide* the angled incision in Fig. 320). The liver is then turned upwards, the duodenum and gall-bladder put on the stretch, and the hepato-duodenal ligament brought into view, with the artery, portal vein, and bile-duct (or hepatic duct) lying together.

(e) Surgery of the Pancreas

120. General Remarks. Pancreatic surgery has developed in two directions: firstly, in the prevention of the dangers associated with the escape of pancreatic

secretion (fat necrosis) in injuries or disease of the organ; and, secondly, in preventing the effects of disease of the pancreas on the flow of bile and the intestinal contents by operations on the bile system or alimentary canal.

The difficulty in diagnosis is the chief obstacle to success in the operative treatment of pancreatic disease, especially as most of the latter conditions, *e.g.* injury and inflammation, require prompt interference. Taking into account, however, the immediate danger to life the results are brilliant, but, unfortunately, we know that many patients are allowed to die from ignorance that such conditions can be cured.

On the other hand, some surgeons go too far in regarding as an operation on the pancreas every case in which, during the removal of disease in the bile-ducts or the pylorus, small portions of the pancreas are either cut away with the knife or separated with the finger. This is surely only a complication of the original operation —an important one perhaps—as every injury of the pancreas calls for plugging and drainage to secure removal of pancreatic secretion.

121. Operations for Secondary Disease of the Pancreas and Palliative Operations. Mayo Robson[1] has furnished some very valuable observations on the variations that exist in regard to the manner in which the pancreatic duct opens into the duodenum. They are important as showing how the pancreas may be affected by disease of the bile-ducts and *vice versa*.

In general (90 per cent, Opie) the bile-duct and duct of Wirsung open separately into the ampulla of Vater. An impacted stone or an inflammatory swelling in this situation will therefore necessarily react on the pancreas or *vice versa* the liver. In the rarer cases where the openings are distinct this is not so. The different relation of the common duct in its pancreatic portion is of importance, for in two-thirds of the cases it is enveloped by the pancreas, and in one-third runs alongside it.

In a few cases the duct of Santorini, which has a separate orifice, is so large that it can take the place of the duct of Wirsung.

Considering these relations, we can easily understand how readily the pancreas may be involved in diseases of the bile-ducts, and especially in cholelithiasis and its complications. The majority of cases of pancreatitis, whether slight or severe, chronic or acute, can be referred to this origin, and therefore must be treated by removing the cause. Removal of gall-stones from the pancreatic and intraparietal portions of the common duct, combined with thorough drainage of the infectious bile for a sufficient period, are therefore the principal methods of treating diseases of the pancreas.

Chronic and acute catarrh of the pancreas of mild or severe suppurative types can be cured by these measures, and their consequences can be avoided, namely, suppurative interstitial pancreatitis with formation of abscess, hæmorrhagic, necrotic, and gangrenous pancreatitis, and atrophy and cirrhosis of the pancreas (with diabetes). Mayo Robson, in his *Hunterian Lectures*, called attention to the possibility of suppurative pancreatitis arising as a result of cholelithiasis in the same manner as suppurative cholangitis and liver abscess. He believes that pancreatitis as a rule exists in all cases where there is a stone in the intraparietal and pancreatic portion of the common duct associated with inflammation.[2]

Technique. For the method of treatment of diseases of the bile-ducts leading to pancreatitis, reference may be made to the chapter on surgery of the bile-ducts. In all cases where there is associated disease of the pancreas, the pancreas must be made accessible for examination and must be pulled forward. A long oblique incision or the angular incision is used, and the duodenum is mobilised provided this is not impossible on account of adhesions.

The question whether simple cholecystostomy, or, as Körte advises, cholecystenterostomy is to be performed, in cases of biliary congestion and inflammation of the bile-duct, must be determined by the local condition and the general state of the patient. Mayo has demonstrated that very good results can be obtained by the much more simple method of forming an external biliary fistula.

[1] Address in Surgery, Canada Med. Association, Aug. 1904.

[2] Robson lays great stress on a "pancreatic reaction" in the urine discovered by himself and Cammidge for the diagnosis of disease of the pancreas, *Lancet*, March 14, 1904.

In cases where the duodenum is displaced by pressure, gastroenterostomy, according to the rules given in the chapter on that subject, is called for.

122. Intrinsic Operations on the Pancreas. (*a*) *Exposure of the Pancreas for injury.* Mikulicz has collected 45 cases of injury to the pancreas, and the reports show that, compared with the great danger to life of expectant treatment, operative interference gives very good results.

A middle-line incision is advisable, for one can never be sure that other viscera, and more especially the stomach and intestines, may not be involved as well.

The gastro-colic omentum is separated[1] and the lesser peritoneal sac opened, in the floor of which the pancreas lies covered by the parietal peritoneum of the posterior abdominal wall. Injuries are best dealt with by careful suture with strong catgut to arrest the bleeding and prevent the escape of pancreatic secretion, after which a cigarette drain is passed down to the gland. In Küttner's case the pancreas was almost completely torn across.

(*b*) Cysts are by far the commonest affections of the pancreas for which operation is undertaken. When they project forwards in the middle line between the stomach and colon they are readily diagnosed, but when they are located in either the head or tail of the gland, their recognition is by no means easy. They are usually of considerable size and can be exposed without difficulty.

The routine treatment should consist merely in incision and drainage. To do this, the abdomen is opened above the umbilicus over the most prominent part of the swelling, if possible in the middle line, but sometimes the incision has to be made at the outer border of the rectus, especially on the left side. The operation Gussenbauer described in 1882 is easily performed.

After opening the abdomen, access is got to the cyst either through the gastro-colic ligament, the lesser omentum, or the great omentum below the transverse colon, depending on its situation. The cyst wall, which is covered by the peritoneum of the posterior abdominal wall, is then firmly sutured to the parietal peritoneum and fascia by means of a circular stitch, after which it is opened and washed out with sterile saline lotion. The operation may be carried out in two stages, the opening of the cyst being deferred until the third day. If the cyst is very tense it is a good plan to puncture it, and aspirate part of the fluid.

By operating in two stages there is no risk attached to opening the cyst except the possibility of hæmorrhage from the cyst wall. This is an important point, as the secretion contained in the cyst may erode the edges of the wound. Leakage may take place through the stitch holes, and if this happens the cyst must be incised at once. The opening should just be large enough to admit a long drainage tube, which should reach down to the bottom of the cyst.

The larger incision that Delagenière employs has the advantage that it allows one to palpate the pancreas from the inside of the cyst, which may lead to the detection of other cysts, new growths or calculi, the removal of which will result in a radical cure. It is attended, however, with greater risk from the escape of the contents and from the accumulation of blood inside the cyst. Of course if the original cause of the trouble is not removed (*e.g.* obstruction of Wirsung's duct by stone, etc.) mere incision of the cyst leads to a permanent fistula.

Drainage through the loin is more difficult and unnecessary. A fistula forms as readily if the primary cause is not removed, while a cure can be obtained just as well by anterior drainage. The only advantage that drainage in the loin possesses over drainage in front is that the sinus track is considerably shorter.[2]

Excision of Pancreatic Cysts. Of 21 operations collected by Körte[3] 7 were incomplete, 6 died, and 15 recovered. In undertaking the excision of a cyst, one has

[1] Going through the gastro-hepatic omentum above the stomach does not give such easy access to the head of the pancreas since one dare not divide the "hepato-duodenal" ligament. It is only in cases of gastroptosis that it is a proper and direct route.

[2] Moynihan quotes Takayasu's collection of 64 cases with 8 deaths, and Körte's larger statistics of 84 cases with 5 deaths.

[3] *Deutsche Chirurgie*, bei Euke, Stuttgart, 1808.

to convince oneself first of all that it is possible to separate it from its deep connection with the pancreas. For this purpose the cyst must be incised and carefully examined from within. It is also important to decide whether it is attached to the body or to the head of the pancreas. Cysts in the latter situation cannot, as a rule, be separated.

Mikulicz's case recovered, notwithstanding that he had to ligature the splenic vessels. Special care must be taken to avoid injuring the superior mesenteric artery and vein. The cyst is separated from the pancreas, and the cavity plugged or sutured, and a drain of gauze passed down to the sutures. Ligature *en masse* should be avoided, and if the pedicle is large it is better to suture it.

(*a*) *Extirpation of Solid Tumours of the Pancreas.* The pancreas is reached by dividing the gastro-colic ligament, and turning the stomach upwards and the transverse colon downwards. It lies behind the peritoneum on the posterior wall of the abdomen in the bottom of the wound. Excision can only be attempted in the case of a circumscribed tumour; diffuse and adherent tumours cannot be removed.

The first successful case was published by Trendelenburg in 1882. Körte collected ten cases, of which six recovered, while Moynihan has collected 13 cases. The tumour is removed from its situation in the body or head of the pancreas and the cavity dealt with by ligature or suture. The subsequent treatment is the same as for cysts.

The treatment of acute and especially of hæmorrhagic pancreatitis is of much greater importance than the excision of pancreatic tumours, most of which are discovered accidentally as the result of errors in diagnosis.

Surgical Treatment of Acute Pancreatitis. In 1898 Körte collected 7 cases in which operation had been undertaken for pancreatic abscess. Of these 4 recovered, but since then other cases have been published. They are dealt with in the same manner as that described for tumours, the abscess cavity being cauterized (for which purpose we recommend swabbing out the cavity with 5-10 per cent carbolic acid in alcohol), packed with gauze, and drained.

In 1898 Körte had no definite treatment for acute hæmorrhagic pancreatitis. Mikulicz,[1] however, has described the results of operation in 75 cases, which included other varieties than the hæmorrhagic form. At the French Surgical Congress in 1905 Garre reported seven recoveries out of eleven cases operated on. Mayo Robson in 1904 advocated operation for acute pancreatitis for reasons similar to those governing the treatment of gangrenous appendicitis, to stop bleeding and drain septic exudate.

He has operated on five patients, three of whom recovered, and knows of 59 acute cases with 23 recoveries. Unless operation is resorted to immediately death as a rule follows. The diagnosis is made from acute epigastric pain, severe vomiting, collapse, and signs of intestinal obstruction. Operation should be undertaken in the first twenty-four hours, so as to avoid extensive fat necrosis and secondary peritonitis.

Technique. When there is severe collapse the operation merely consists in exposing the pancreas with as little interference as possible, and evacuating the exudate. The pancreas may also be incised. In Muspratt's case it was of a deep purplish red colour and acutely distended. The bleeding was arrested by ligature.

An incision of medium length is made in the middle line and the gastrocolic ligament, or occasionally the transverse mesocolon is divided. Moynihan prefers the access through the lesser omentum (gastro-hepatic omentum). The diagnosis is confirmed, according to Moynihan, by the presence of yellowish white spots of fat necrosis in the omentum along with a blood-stained serous effusion. Ample drainage must be provided on account of the collapse. Although it prolongs somewhat the operation, incision of the pancreas is very desirable. In 37 cases where incision was practised 25 recovered according to Mikulicz;[2] while of 42 which were merely drained only 4 recovered (Moynihan). Gauze surrounded with rubber tissue (a large cigarette drain) is the best form of drainage to employ.

When pus has already formed, Mayo Robson emphasises the importance of inserting a tube through the loin in the costo-vertebral angle. The pancreas can be examined from this point with the finger. Suppuration either above or below the liver

[1] *Annals of Surgery*, May 1903. [2] *Ibid.*, July 1903.

must be dealt with by appropriate incisions and drainage, and if there is obstruction to the bile, cholecystostomy must also be performed.

Pancreolithotomy and Wirsungo-duodenostomy. When the stone does not occupy the terminal portion of the pancreatic duct, it should be cut down on by an incision through the substance of the gland. After removal the opening is closed with catgut sutures and the wound drained. Robson has performed this operation, and Moynihan cites cases by Pierce Gould, Dalziell, and Allen.

Moynihan [1] and Robson have both performed wirsungo-duodenostomy for a stone impacted in the duct of Wirsung. In Mayo Robson's case a longitudinal incision was made through the rectus, the bile-ducts, pancreas, and duodenum were exposed, and the duodenum opened. The ampulla of Vater was then incised and the stone removed with a scoop. Beyond closing the wound in the duodenum the operator employed no sutures. Drainage. Uneventful recovery.

(f) Surgery of the Spleen

123. Splenotomy and Splenectomy. The spleen may be incised to open an abscess and for the purpose of transplanting the thyroid (Payr). It is not always easy to reach the spleen through a small incision, as we have repeatedly found when transplanting the thyroid. It is certainly not advisable to make a large incision, such as is suitable for extirpation of the spleen.

A suitable short incision is one extending from the costal margin downwards along the outer border of the rectus, otherwise we condemn it on account of the division of the nerves. If this does not give much room, *i.e.* if the spleen does not come up when the fundus of the stomach is pulled upon, and it is found necessary to insert the hand to pull up the spleen on account of adhesions or of its deep situation, a transverse incision may be combined with it running obliquely upwards and outwards from its lower end. This incision may be made by splitting the muscles without dividing their fibres transversely.

Apart from enlargement of the spleen due to malaria, simple hypertrophy, Banti's disease, etc., for which special text-books must be consulted, the chief conditions for which splenectomy is performed are injuries, tumours, cysts, and especially sarcoma.

Injuries of the spleen [2] demand excision of the gland. No evil effects follow its removal, while the danger of hæmorrhage is effectually stopped. In a report on six of his own cases [3] Noetzel points out that as injuries of other viscera are so commonly associated with injuries of the spleen, it is advisable to employ an incision in the middle line.

If this does not give sufficient room an incision should be carried from the lower end of the wound transversely outwards through the rectus, and if necessary the broad abdominal muscles. In the case of the latter muscles the incision will be more or less in the direction of their fibres, and will not produce much injury to the muscles themselves or to the nerves going to supply the rectus.

An angular incision similar to that we recommended for exposing the bile-ducts should always be employed if the spleen is much enlarged or deeply placed; for, as we pointed out before, it is a more rational incision than one along the outer edge of the rectus, or one which necessitates longitudinal separation of the muscular fibres. The wound after suture is quite strong and there is no danger of the muscle becoming atrophied.

If there are many adhesions, an oblique incision along the costal margin—similar to that used for liver operations—can be used with advantage, along with resection of the ribs in the manner recommended by Vanverts and Auvray. A more simple procedure than that of resecting the eighth, ninth, and tenth costal cartilages is to fracture or divide the ribs and turn backwards the costal margins as a flap (Marwedel).

The presence of adhesions requires that the incision is well planned and of sufficient

[1] *Abdominal Operations*, London, 1905.
[2] Cf. Edler, Langenbeck's *Archiv*, Bd. 34, and Berger, *ibid.* Bd. 68.
[3] *Beiträge zur klinischen Chirurgie*, Bd. 48.

size. Omental adhesions can be easily divided between two ligatures. The pedicle should be early exposed and the vessels in the gastro-splenic omentum (splenic artery and vein and vasa brevia) ligatured if possible. If the artery, vein, and smaller vessels can be isolated and ligatured separately, it is preferable to do so, but one is often glad to ligature or clamp them *en masse*.

Among the normal ligaments and means of fixation other than the connection with the stomach, mention must be made of the phrenico-lineal ligament to the diaphragm and kidney. Division of this frees the spleen from its posterior connections.

W. Jebson and F. Albert[1] have collected thirty-two cases of malignant tumours of the spleen. Of these twelve were operated on, eleven cases being of total extirpation. Eight recovered and four remained well at the time of publication.

124. Rydygier's Splenopexy. Splenopexy is undertaken for floating spleen and in Talma's operation for the cure of ascites (biliary congestion).

Sutures should not be passed through the substance of the spleen, as they cut through very easily and may give rise to hæmorrhage.

Adhesions are procured most readily by Kouwer's method, in which the spleen is exposed and the wound packed with gauze.

Rydygier's operation is the typical one. The parietal peritoneum is incised, and a pocket is formed by stripping it off the abdominal wall into which the spleen is placed (Bardenheuer) either entirely or partially. The spleen then occupies an extraperitoneal position. This exosplenopexy is comparatively easy where the spleen can be pulled well forward, *e.g.* floating spleen, and can be conveniently carried out through an oblique incision along the costal margin. If the spleen is not movable, a more extensive division and separation of the parietal peritoneum is necessary through a longer incision nearer the normal position of the spleen.

(g) Surgery of the Stomach

125. General Remarks. In an address delivered in 1904, Mikulicz emphasised the important position the physician occupies in regard to modern gastro-intestinal surgery, and it is a gratifying fact that in recent years practitioners are coming more and more to recognise that a large number of affections of the stomach can only be cured by mechanical or surgical measures. Formerly the majority of chronic affections of the stomach were indiscriminately regarded as chronic gastric catarrh; now, however, it is realised that the catarrh is not a primary condition, but is the result of purely mechanical causes, especially stasis of the contents and difficulty in emptying the stomach. Credit for this discovery is due to those physicians who recognised the mechanical value of the stomach tube. In place, however, of the inconvenience and only partial benefits of gastric lavage, surgical measures now provide a rapid and certain cure.

By far the greatest number of the operations on the stomach are now directed towards establishing proper mechanical relations, and most prominent of all is the operation of gastroenterostomy, which was evolved in so brilliant a manner by Wölfler from an idea of Nicoladoni's. It cannot be denied that occasionally surgeons have been led away by the brilliant results obtained, and have undertaken it on insufficient grounds. But at the present time it is a more serious fault to allow patients to drag along for years with ineffective medical treatment when an operation alone can afford a certain and rapid cure.

Even more important than the failure to appreciate the necessity for restoring the mechanical relations in many cases of so-called gastric catarrh, is the fact that the overwhelming majority of gastric tumours, especially cancer, are as a rule treated in the first instance as gastric catarrh with the result that valuable time is lost.

As will be shown later, the results of the radical treatment of cancer of the stomach prove that in many cases early diagnosis only is needed to avert the melancholy effects of the disease and to enable a cure to be obtained by resection of

[1] *Annals of Surgery*, July 1904.

the stomach. This point will only be realised when the profession has learnt definitely that catarrh of the stomach is a secondary condition. If the primary cause is not to be found in chemical or other injurious agents, such as alcohol, irregularities of diet, etc., or in some general disease, which has an indirect influence on the gastric functions, then some mechanical cause or the presence of a new growth must be suspected and a thorough examination undertaken with this in view.

In comparison with these two principal operations, gastrostomy, gastropexy, and gastroplasty, etc., are of secondary importance.

126. Gastroenterostomy.[1]—*General Directions.* Apart from being the most frequently called-for operation on the stomach, gastroenterostomy is of the greatest value in restoring alimentation when the patient has been greatly reduced under medical treatment. It has achieved its greatest triumph in the treatment of simple gastric ulcer and its sequelæ, but at the same time it is a valuable makeshift in the treatment of cancer where radical operation is no longer possible. It must be admitted, however, that in this connection, many of the brilliant results recorded, where there has been complete restoration of health for years, leave room for the suspicion that the original tumour had been mistaken for cancer.

The results in the treatment of simple ulcer give the best index to its value. Our own statistics have been recorded on three occasions.[2] In 92 cases where gastroenterostomy was performed for non-cancerous affections we have only had three deaths, none of which could be directly attributed to the operation; two were due to hæmorrhage from the ulcer (one from erosion of the splenic artery, and one from a duodenal ulcer) and one was due to pneumonia. In the last case alone can the result be associated with the operation. Both the other patients would have died sooner or later without operation (possibly later), while the patient who died of pneumonia was in an extremely reduced condition, and was the subject of arteriosclerosis, atrophy of the heart, and pulmonary tuberculosis. The mortality may thus be considered as 1 per cent.

There is no danger in the operation itself; it is only from general or local conditions that complications are to be feared. One cannot guarantee that there will be no subsequent bleeding from the ulcer; one of our cases succumbed from a subsequent hæmorrhage. There are other post-operative conditions which may also give rise to danger or prejudice recovery. Apart from hæmorrhage, these may be regarded under two heads—(1) symptoms of regurgitation, described under the general term "vicious circle," varying from slight nausea and vomiting to symptoms of ileus; (2) the development of peptic ulcers in the loop of intestine connected with the stomach.[3] At the same time we should mention the possibilities of volvulus and internal hernia after a posterior gastroenterostomy. Moynihan reports 4 cases of the latter condition.

These complications must be prevented at the operation. We have had to open the abdomen again on six occasions for more or less severe degrees of vicious circle, and three times for peptic ulcer. In every case, however, the patient recovered. But although the damage may be repaired by a new correct operative interference, it is better to prevent it at the outset.

To Roux belongs the credit of having established the real principle by which the vicious circle is to be prevented. Essentially it consists in ensuring that the contents of the upper loop of intestine empty into the lower, when it will not matter if some of the gastric contents pass through the pylorus into the upper portion of the gut, or *vice versa* if some contents escape from the newly-formed opening into the upper end. Peristalsis can always be relied upon to empty the bowel from above downwards. It is only when the contents of the proximal loop cannot empty into the lower that

[1] The reader is referred to Krönlein's paper and the subsequent discussion at the Surgical Congress at Berlin, 1906, the discussion at Surgical Congresses in other countries, and at the Congress of the International Society of Surgery in Brussels, 1905.

[2] Kaiser, *Deutsche Zeitschr. f. Chir.* Bd. 61; Humbert, Dissertation, Bern, 1902; Gilli, *ibid.*, 1907.

[3] Von Braun first drew attention to the relative frequency of peptic ulcer. Since then Brodnitz has collected 14 cases, Tiegel 26, Gossel 31, and we can add two more, both after the Y-operation.

there is any danger, for then the loop becomes distended from the passage of food into it, either through the pylorus or the anastomotic opening, with the result that it is regurgitated back into the stomach and the vicious circle is set up. If the efferent loop is constricted by the weight of the proximal loop the condition becomes more exaggerated. Regurgitation, when it is really only reflux and not a disguised vicious circle, does no harm, for it has been proved experimentally (by Oddi and Dastre) as well as by the results of cholecystogastrostomy [1] that the presence of bile in the stomach does not produce any real disturbance as long as there is a free outlet from the stomach.

The methods we can employ to ensure that both the stomach and proximal loop of intestine can empty are:—(1) to make the anastomotic opening of large size by approximating a sufficient extent of the gut to the stomach; (2) To form an enteroanastomosis below the gastroenterostomy according to the method advocated by Braun or Roux (Y-method); (3) to unite the stomach with the duodenum. So long as a proper outlet is provided, it does not matter whether the anastomosis is made in front of or behind the colon, though much importance has been attached to this point.

It is more important to make the anastomosis at a point where the stomach empties most satisfactorily. We were the first to call attention to this by our operation of "inferior gastroenterostomy," in which we showed the importance of making the opening at the most dependent point of the greater curvature, the stomach being empty, *i.e.* generally in the antrum pylori.

The observations of Kelling, Cannon, and Blake [2] have shown that the most dependent part of the stomach during contraction corresponds to the pylorus, that the peristaltic pressure is greatest at this point (Kelling), and further, that a longitudinal opening in the stomach above this becomes contracted into a mere slit. The fact, confirmed by W. Mayo, that disturbances of the nature of vicious circle are most often seen when gastroenterostomy has been performed in cases where the pylorus is still patent, is in agreement with this idea. We have frequently been able to confirm this. Food passes as before through the pylorus and back through the anastomosis into the stomach, even if the latter opening is of large size.

It follows, therefore, that care must be exercised in discriminating between cases where the pylorus is patent and where it is almost occluded. In the former (in operations for ulcer, ptosis, or simple dilatation) one must be particularly careful to provide ample escape for the contents of the upper loop of gut, while in cases of marked stenosis or closure of the pylorus every method answers the purpose.

Our classification of the different forms of gastroenterostomy is based on this important characteristic, in order to draw attention to the advantages and disadvantages of the individual methods.

(a) Gastro-jejunostomia Inferior Longitudinalis

127. Gastro-jejunostomia Antecolica Inferior Longitudinalis. The anterior method is much the most simple. In pyloric stenosis its results are excellent, and as it entails the least interference with peritoneum, it gives rise to the fewest adhesions. Not only is the anastomosis most easily made, but, when proper cases are selected, there is complete freedom from discomfort, and pain from subsequent adhesions. Further, if a second operation, *e.g.* for peptic ulcer, has to be undertaken, the anastomosis is easily located and the second operation is facilitated.

Wölfler's original operation has been improved by following Kappeler's suggestion, and uniting a greater extent of intestine and stomach than is required merely for the anastomotic opening. In this way obstructive kinking at the opening is avoided, the lower loop of intestine is not compressed by the weight of the upper loop and a spur is avoided. It is a further improvement to make the opening a large one.

Dollinger, who has had excellent results in twenty cases, is a firm advocate of the simple anterior method. He makes the anastomotic opening $2\frac{1}{2}$ to 3 ins. long.

[1] Perrin, *Thèse de Lyon*, 1901.

[2] Division of Surgery, Harvard University, May 1905

Technique. A middle-line incision is made about 5 ins. in length, of which three-fourths should be above the umbilicus. The lower part of the incision is carried slightly to the left of the umbilicus, so as to facilitate the subsequent stitching. The skin, linea alba, and fascia transversalis are divided, a few vessels near the umbilicus secured, and the peritoneum is opened. A careful inspection of the stomach and duodenum is then made, and the nature of the disease defined.

The transverse colon and omentum are turned upwards, and the duodeno-jejunal flexure sought for by passing the finger underneath the mesocolon to the left side of the vertebral column. Having identified the commencement of the jejunum, a loop, about 16 inches long, is selected, emptied by stripping it between the fingers, and clamped with a pair of light forceps (crushing-forceps must not be used), which are applied so as not to include the mesentery. The loop is placed with the proximal end pointing towards the cardia and the distal end towards the pylorus.

Fig. 325.

The stomach, which must be empty, is then pulled downwards, and the most dependent part of the pyloric portion identified. At this point the gastrocolic ligament is separated from the greater curvature for at least 3 inches, and any small branches of the gastro-epiploic vessels, chiefly veins, passing on to the stomach are ligatured. The gastro-epiploic vessels themselves should not be ligatured. A fold of the greater curvature is then clamped in a similar way with a pair of light forceps. If there is any difficulty in applying clamps to the intestine, a stout ligature may be passed round it so as to include a loop about 8 inches long, and lightly tied, without constricting the mesentery, the ends of the ligature being left long and secured with forceps. The stomach may be also held up between the fingers of an assistant so as to bring the anterior wall in relation to the bowel, the finger at the same time preventing any escape.

The selected portions of stomach and intestine are brought up into the wound as far as possible, and after the transverse colon, omentum, and intestine have been replaced, the field of operation is shut off with gauze pads. The introduction of the pads is facilitated by raising up the edges of the wound with blunt hooks.

In making the anastomosis, the first serous layer of sutures, which should be of fine silk, should be inserted for a distance of $3\frac{1}{2}$ inches, leaving the ends long and clamped with artery forceps. The peritoneal and muscular coats of the stomach and intestine are then incised $\frac{1}{5}$th inch from the suture line and for a distance of $2\frac{1}{2}$ inches, and united by a continuous suture of fine silk, the ends of which are left long. The mucous membrane is then divided and the edges are brought over the sero-muscular suture without any tension, and united with continuous catgut, which is carried right round the posterior and anterior walls without interruption, thus completing the communication between the stomach and intestine. The anterior seromuscular suture is next completed with the ends of the posterior suture, which were left long. When the wall of the intestine is too thin to allow of stitching it in layers, the serous, muscular, and mucous coats should all be included in one stitch. After the stomach and intestine have been opened, the exposed mucous surfaces should be cleansed with gauze wrung out of lysol, and before beginning the anterior serous suture, the stomach and intestine are cleaned with lysol, and the soiled pieces of gauze nearest them removed. The anterior serous suture is completed with the long ends of the posterior serous

suture. In this way a portion of intestine half an inch long is applied to the stomach above and below the opening.

128 Gastro-jejunostomia Retrocolica Inferior Longitudinalis. This operation, which is associated with Peterson's name, was developed in Czerny's clinic from a method v. Hacker had previously described. It has met with much favour, and in the hands of experienced surgeons such as Mayo, Moynihan, and Czerny it has given particularly good results.

As before, the opening in the stomach is placed at the greater curvature, but, unlike the anterior operation, where the anastomosis is made at least 16 inches from the commencement of the jejunum, here the loop of intestine is made as short

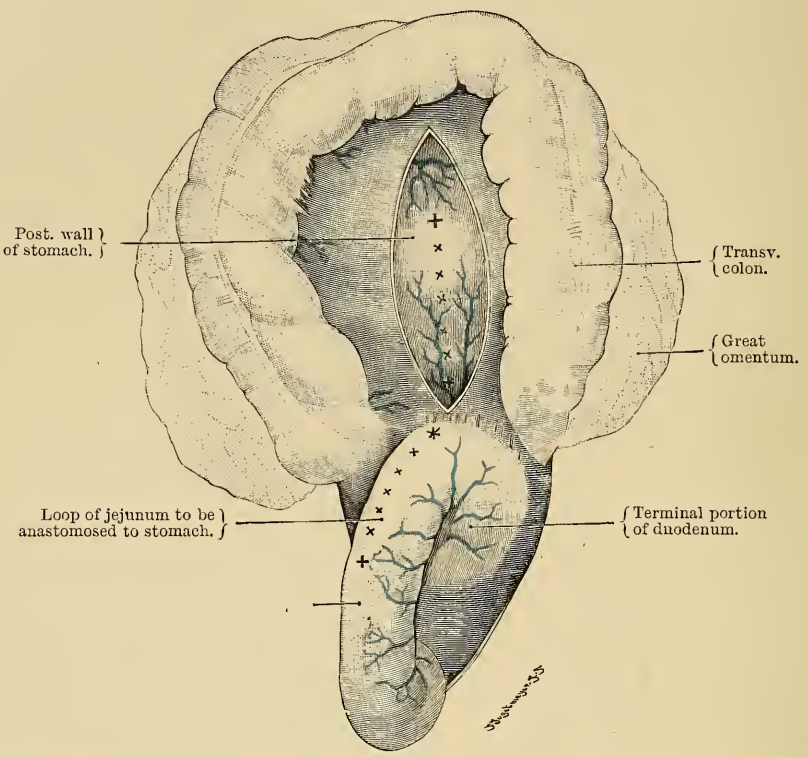

FIG. 326.—Gastrojejunostomia retrocolica verticalis. Stomach and transverse colon are thrown upwards and the transverse mesocolon is split longitudinally. Between the edges of the latter are seen, above, the vessels of the greater curvature, below, those of the lesser curvature. The vertical apposition of the jejunum is represented by crosses, the larger crosses indicating the upper and lower ends of the line of sutures. Below is shown the commencement of the jejunum, and below and to the right the termination of the duodenum.

as possible. In addition to placing the gut for anastomosis in the long axis of the stomach, the afferent limb, as shown in Fig. 326, is sutured in a vertical direction on the posterior wall of the stomach, so that, owing to its downward direction, no regurgitation can take place into it. In the majority of cases this has the desired effect, but it sometimes happens that as the dilated stomach becomes reduced in size, and the greater curvature comes to occupy a higher level, the upper loop, instead of being directed downwards and forwards, becomes drawn upwards so that its axis is from below upwards, thus reproducing one of the harmful features that occur with anterior gastroenterostomy. We have encountered one such case.

In order to prevent this, the anastomotic opening must be made of large size, *i.e.* $2\frac{1}{2}$ inches.

Technique. The abdomen is opened as described in section 127, the transverse colon and omentum are thrown upwards, and the posterior surface of the stomach, including the greater curvature, is exposed through a slit in the transverse mesocolon between the branches of the middle colic artery and vein (see Figs. 326 and 338). The greater curvature is freed as before by detaching the gastro-colic ligament along with its vessels, and the margins of the slit in the transverse mesocolon are stitched with interrupted sutures to the stomach, leaving a portion of the latter exposed. This

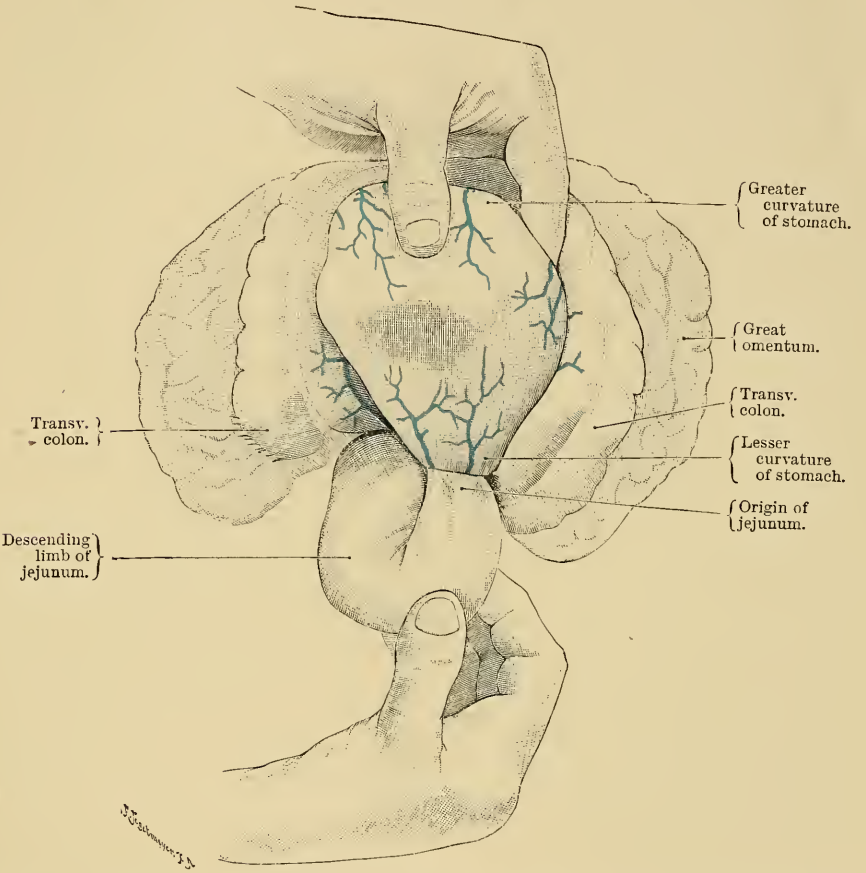

FIG. 327.—Gastrojejunostomia retrocolica. The stomach, which has been thrown upwards along with the transverse colon, is here shown pushed forwards by the fingers of the left hand introduced behind it. The upper loop of the jejunum is pulled downwards, prior to its being stitched, with a continuous suture to the stomach, from the point where it is in contact with the lesser curvature, in a line transverse to the curvatures. The anastomosis is made with the greater curvature in the manner shown in the following figure.

manœuvre is necessary to prevent the gut becoming constricted, or becoming herniated into the lesser sac, several cases of which Moynihan has collected.

The jejunum, as near its commencement as possible, is then applied in a vertical direction to the stomach (care being taken that there is no tension), and fixed in position with sutures.

Clamps are applied to the stomach and intestine as before, and the anastomosis is made in the same way as was described for anterior gastro-jejunostomy (No. 127).

It is, however, rather more difficult. It is a good plan, as proposed by Gould,[1] to make the opening in the stomach at right angles to the greater curvature, for this allows the opening to be prolonged down to the lowest part of the stomach. As Figs. 328 and 329, which are taken from Gould's work, show, he converts the opening when made into a longitudinal one and so obtains better gaping of the communicating aperture.

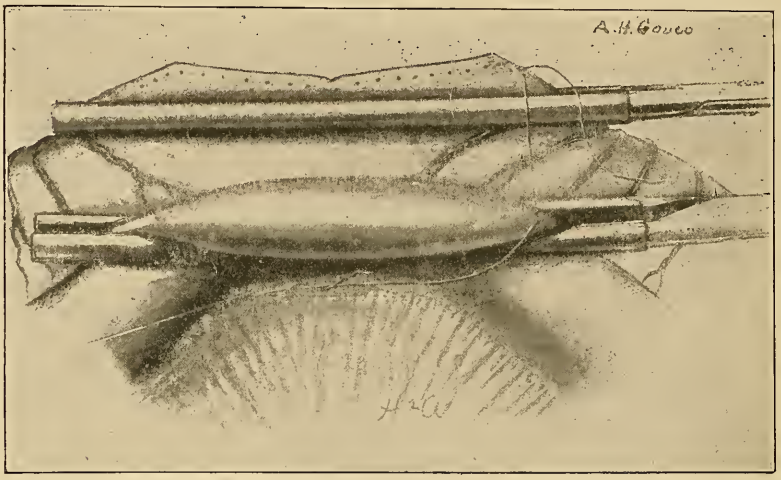

FIG. 328.

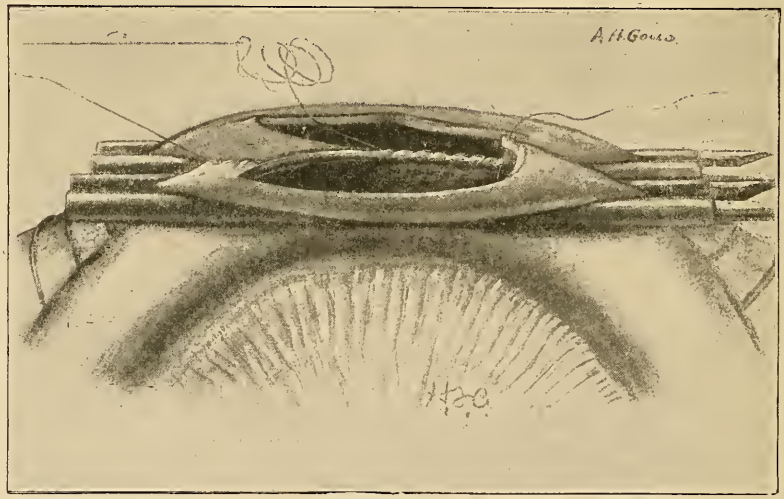

FIG. 329.

FIGS. 328 and 329.—Gastroenterostomia inferior longitudinalis. Gould's modification. The transverse opening at the greater curvature has been converted by the clamps into a longitudinal one, corresponding with the direction of the opening in the jejunum.

(b) Gastro-jejunostomia Inferior Verticalis

Although the horizontal attachment of the gut to the stomach allows of a large opening being made, and ensures free escape from the stomach, it also permits a

[1] Gould, Division of Surgery, Harvard University, May 1905.

regurgitation of the contents of the upper loop. This, of course, does no harm if sufficient provision has been made for its escape into the lower loop, and by neutralising the hyperacid gastric juice it may even tend to promote the healing of an ulcer and prevent the production of peptic ulcer in the jejunum.

With the bowel in the vertical position free escape downwards is obtained, but the size of the opening is limited to the diameter of the intestine, and in these cases

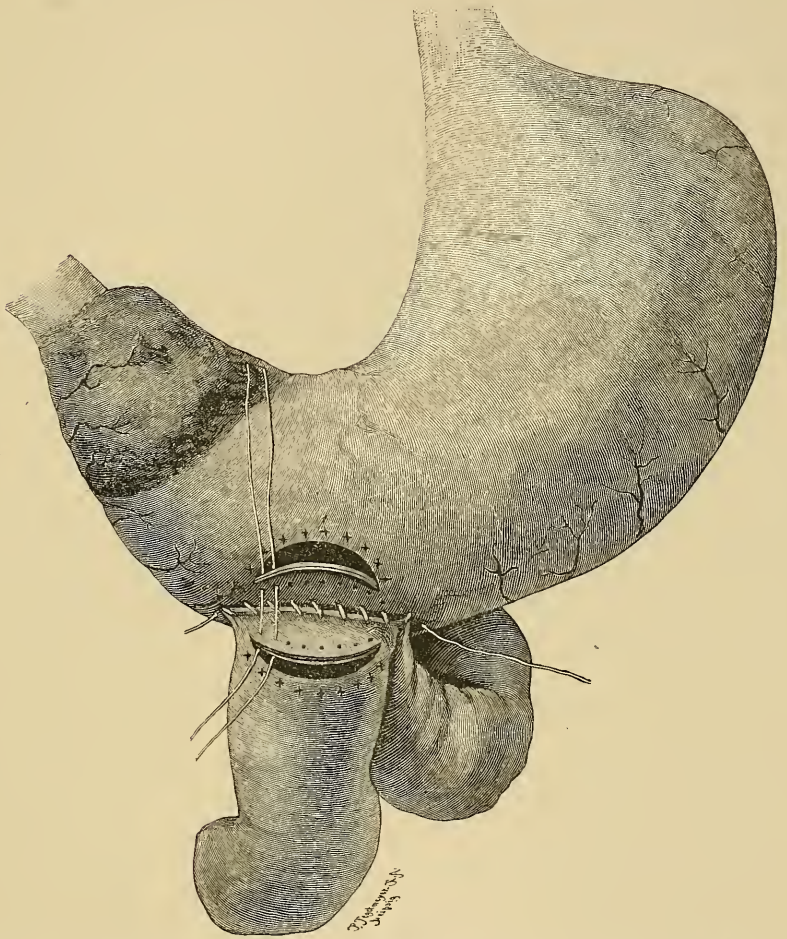

FIG. 320.—Gastroenterostomia inferior antecolica verticalis. The jejunum at a point 16 ins. from its commencement has been applied vertically to the greater curvature of the stomach (in the figure the opening in the stomach is drawn too high above the greater curvature), and the two have been united with a continuous serous suture of fine silk. The stomach and jejunum have been opened (the descending limb is anterior) and the deep suture through the entire thickness of their coats begun. The incisions in the stomach and intestine should be longer.

where the pylorus still allows the gastric contents to pass into the duodenum and the proximal loop becomes filled, there is a risk of kinking taking place and of the afferent loop becoming obstructed.

This may be prevented by attaching more of the afferent end of the gut to the stomach, but to make quite sure, the contents of the upper loop must be made to empty into the bowel at a point below where the anastomosis has been made.

There are two ways of ensuring this: (1) By making an anastomosis between the afferent and efferent loops (Braun); (2) or by cutting across the bowel, and inserting the distal end of the upper portion into the lower portion, below the point where the latter is implanted in the stomach.

As regards the escape from the stomach, it is quite immaterial whether the anastomosis is made in front of or behind the colon, provided that the opening in the stomach is made in the lowest portion of the greater curvature (pars pylorica). In the anterior operation a long loop of bowel is selected in order to avoid any trouble from pressure on the colon. We have never seen any harm result from this method of treatment.

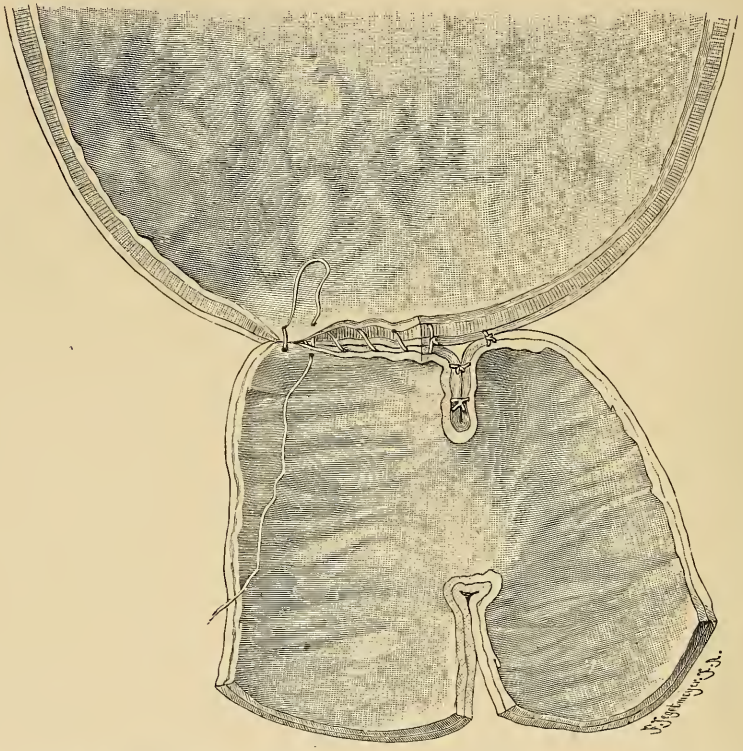

FIG. 331.—Gastroenterostomosis antecolica inferior verticalis. A fold has been made in the convexity of the loop of jejunum, and this has been fixed to the stomach by sutures (sagittal section). The deep sutures for the anastomosis have been inserted through all the coats, and the continuous serous suture is begun. The figure shows how the gastric contents are guided into the lower limb of the intestine, *i.e.* on the left of the figure.

In our opinion, equally good results are obtained with either the anterior or posterior methods, and we have found that entero-anastomosis is quite as reliable as the Y-operation. It therefore comes to be a question as to which operation is the easier for surgeons who have not frequent opportunities for performing gastroenterostomy, which method will subsequently give rise to the least trouble (especially from adhesions), and finally which affords the best chance of performing a second operation, should subsequent complications ensue.

As has been already mentioned, anterior gastroenterostomy best fulfils these three conditions, and the majority of surgeons find a lateral, easier than an end-to-side anastomosis. We will therefore describe anterior gastroenterostomy with Braun's anastomosis as being the easier, although the Y-method can be very well combined

with the anterior method,[1] and also describe the Y-method with retrocolic anastomosis, since it was practised in this form by its principal exponent Roux. Braun's lateral anastomosis can also be performed with the posterior method.

129. Gastro-jejunostomia Antecolica Verticalis cum Enteroanastomosi. The abdomen is opened, and after the omentum and transverse colon have been turned up,[2] and the greater curvature exposed through a small opening in the gastro-colic ligament, a loop of intestine 16 inches long is pulled up, as described in paragraph 127.

The parts to be anastomosed are brought up into the wound and the rest of the peritoneal cavity is thoroughly shut off with sterile compresses.

The loop of intestine (Fig. 333) is then clamped with light clamps (Fig. 335), which hold the two limbs parallel side by side, and the latter are united with a silk serous suture which is begun about $1\frac{1}{4}$ inches below where the gut is kinked.[3] This suture should be inserted for 2 inches and the ends are left long, to be tied later. The gut is then incised longitudinally for $1\frac{1}{2}$ inches 3 mm. on each side of the suture

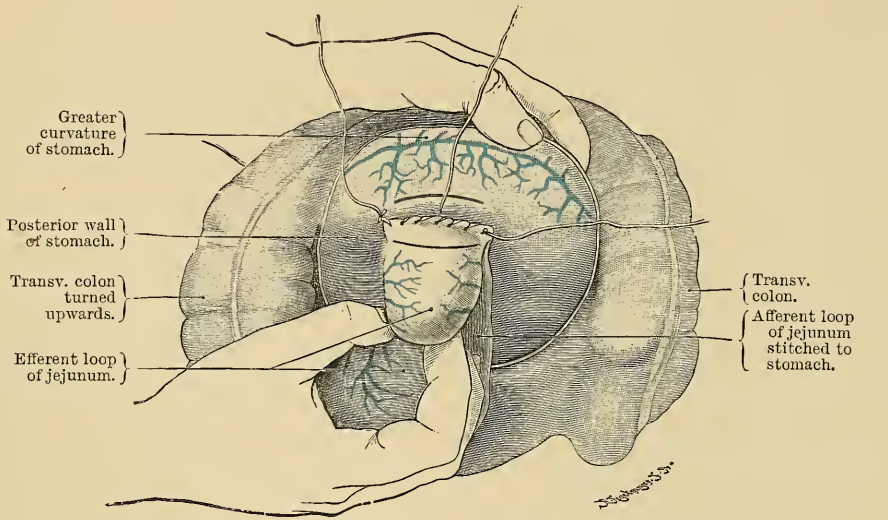

FIG. 332.—Gastrojejunostomia retrocolica verticalis. The jejunum has been sutured to the stomach. The central of the three threads represents the upper end of the suture uniting the jejunum and stomach in the vertical direction. The two lateral threads are the ends of the posterior serous suture of the anastomosis. The dark lines on the stomach and intestine show the direction of the anastomotic opening, which is transverse to the long axis of the jejunum and equal to its diameter.

and the contents are mopped up with lysol swabs. A continuous catgut suture is inserted through the whole thickness of the wall, accurately uniting the mucous layers, the parts are again cleaned with lysol, and the anterior serous suture is completed with silk and tied to the ends of the posterior serous suture.

The intestinal anastomosis is now complete. The flexure of the gut above the clamp is then applied to the stomach, after the latter has been clamped or held in position and closed by the fingers of an assistant. The whole breadth (Fig. 334), or, if preferred, length of the convex surface of the jejunal loop is then sutured to the greater curvature, the ends of the suture being left long. In incising the muscular

[1] Rothgaus (*Nederl. Tijdschr. f. Geneesk.*, 1902) has obtained excellent results with gastroenterostomia antecolica anterior in Y.

[2] If the omentum is too thick, then it can simply be divided longitudinally.

[3] To prevent a peptic ulcer, it is better not to make the anastomosis too low down.

coats the incision should be made slightly convex, and the edges united with a posterior sero-muscular suture, the ends of which are also left long.

The mucous membrane is then divided, purified, and united with a circular catgut suture all round. The introduction of the anterior sero-muscular and serous sutures (silk) follows, after cleansing the whole region again with lysol and changing the

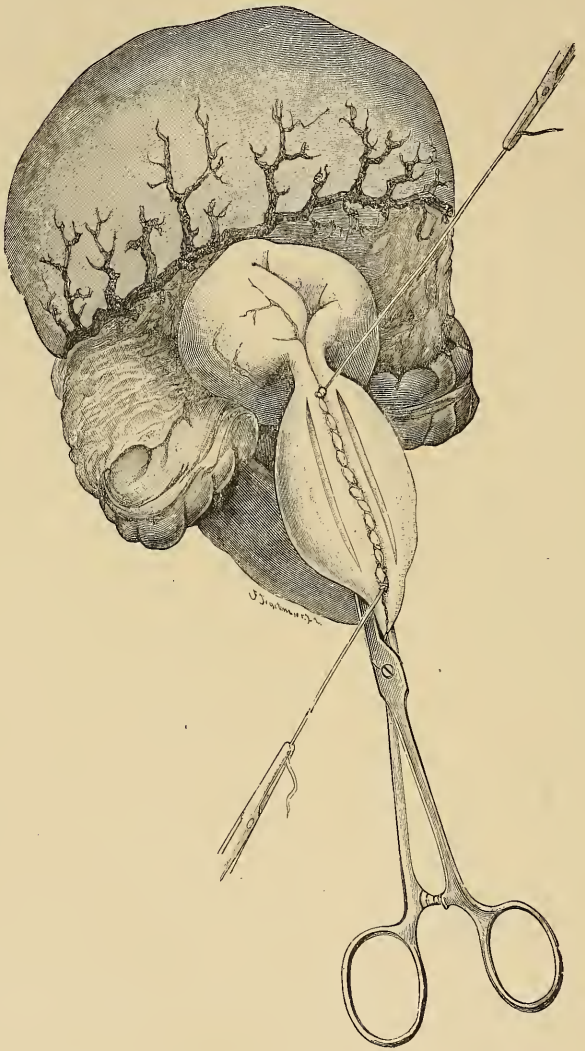

FIG. 333.—Gastrojejunostomia antecolica cum enteroanastomosi. Stage 1: The two limbs of the jejunal loop are clamped 16 inches from the duodeno-jejunal flexure, and the first layer of serous sutures is inserted.

small gauze compress in contact with it. If the wall of the gut is thin it is easier to include the mucous layer in the sero-muscular suture.

130. Gastro-jejunostomia Retrocolica Inferior Verticalis Y-formis.—Roux's operation is performed as follows: The initial steps are the same as those described in section 128, viz. the abdomen is opened, the colon and omentum are turned upwards,

the mesocolon is divided, the edges are stitched to the posterior wall of the stomach, and the commencement of the jejunum is identified.

The loop need not be so far removed from the commencement of the jejunum as in the anterior operation, but should be sufficiently long to be pulled forward comfort-

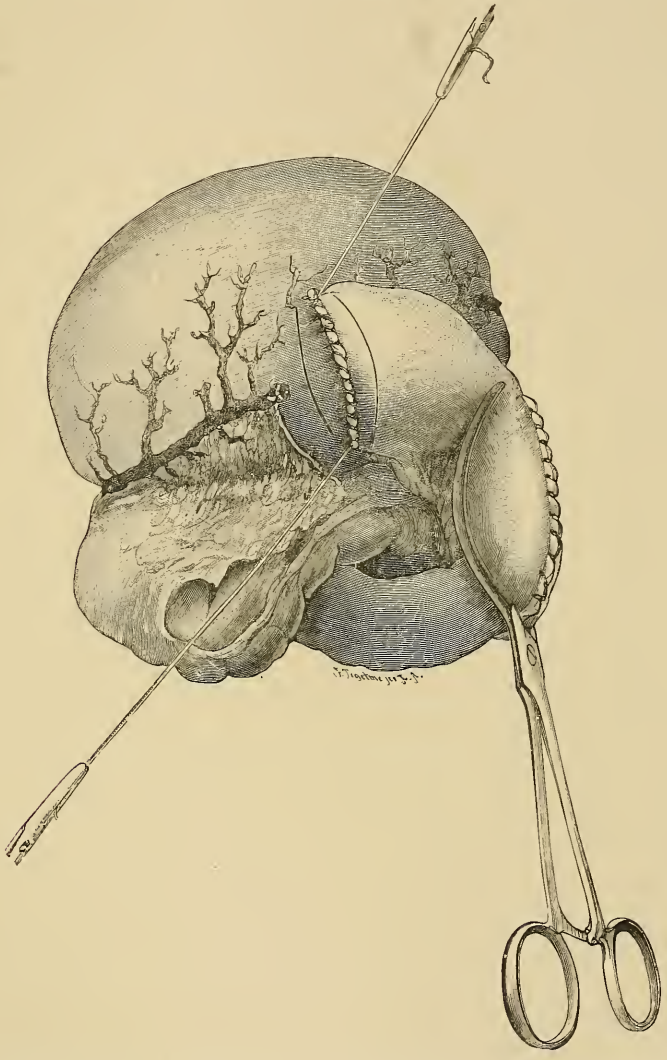

Fig. 334.—Gastrojejunostomia antecolica cum enteroanastomosi. Stage 2: The enteroanastomosis is completed, and the clamp is left *in situ*. The convexity of the loop is seen applied to the greater curvature transversely, the vessels having been divided and ligatured. The posterior serous suture has been inserted, and the direction of the incision is shown on the stomach and jejunum.

ably. The jejunum is drawn forwards and is best clamped by means of two thick silk ligatures which are passed round it above and below through the mesenteric attachment and lightly tied, leaving the ends long and securing them with artery forceps. The intestine is grasped with two strong toothed Kocher's forceps, or two small crushing-forceps placed close together, and cut across between them, the division

being carried into the mesentery as far as the first large arterial arch (*vide* Fig. 337). The redundant bowel is cut off flush with the forceps, and the ends are cleansed with lysol and alcohol.

The greater curvature and posterior wall of the stomach are protruded through the opening in the meso-colon, and the two surfaces of the stomach are kept firmly in contact by the fingers of an assistant to prevent escape of the contents (Fig. 337); or, when possible, it is more convenient to use a clamp.

Using the compression forceps as a handle, the lower end of the gut is then applied to the stomach behind the greater curvature, either transversely or longitudinally, according to which is found the easier, and is fixed there with a layer of serous sutures. The forceps are of use in slightly rotating the gut and bringing the posterior wall close up to the stomach.

Fig. 335.—Intestinal clamp, the grip of which is light and elastic in contrast to the crushing-forceps.

An incision, equal in length to the diameter of the intestine, is now made in the stomach, and the edges of both are united all round with a continuous catgut suture, including all the layers, after which the anterior silk serous suture is inserted and tied to the posterior suture.

Thorough cleansing of the stomach and intestine, as well as the line of suture, must not, of course, be omitted before completing the serous suture.

The anastomosis with the stomach being completed, the upper end of the intestine is implanted into the lower limb at a point $2\frac{1}{4}$ inches below it[1] in the usual way with two rows of sutures. We find it better to incise the lower portion of bowel transversely for half its circumference, parallel to the course of the vessels and its circular fibres. Roux employs a longitudinal incision. The pressure-forceps on the upper end of the jejunum are removed whenever the posterior serous suture has been inserted, as the gut is then in position, and the deep sutures can be inserted through the whole thickness of the wall so quickly that there is little bleeding from the compressed edges.

Finally the gap in the mesentery is closed with interrupted sutures and the surrounding parts are cleansed with lysol swabs.

It is interesting to observe that Monprofit, Graser, and others who have employed the Y-method exclusively maintain that it is the best of all methods. The originator of the method, Roux, on the other hand, in one of his latest publications, has ascribed limitations to his operation. He employs it only in cases where there is mechanical obstruction, and has returned to ordinary gastroenterostomy for simple ulceration, in order to take advantage of the neutralising action of the regurgitated alkaline intestinal secretion on the hyperacid gastric contents, a concession which is quite in agreement with the statement we have already made.

The first occasion on which we had recently to operate again for fresh gastric symptoms, arising from an ulcer on the lesser curvature, was a case in which six years previously the Y-operation had been performed. Here the Y-method had functioned faultlessly—too faultlessly to neutralise the hyperacid gastric juice.

[1] A lower insertion may be more convenient. Roux allows 8 to 12 inches. We are afraid of the action of the gastric juice on the connecting portion, with associated peptic ulcer, since the gastric juice is not neutralised by the bile and pancreatic secretion.

(c) Gastroduodenostomy

In those cases where the indications point to gastroenterostomy, and in which the pylorus is found to be quite patent, if gastro-jejunostomy is performed

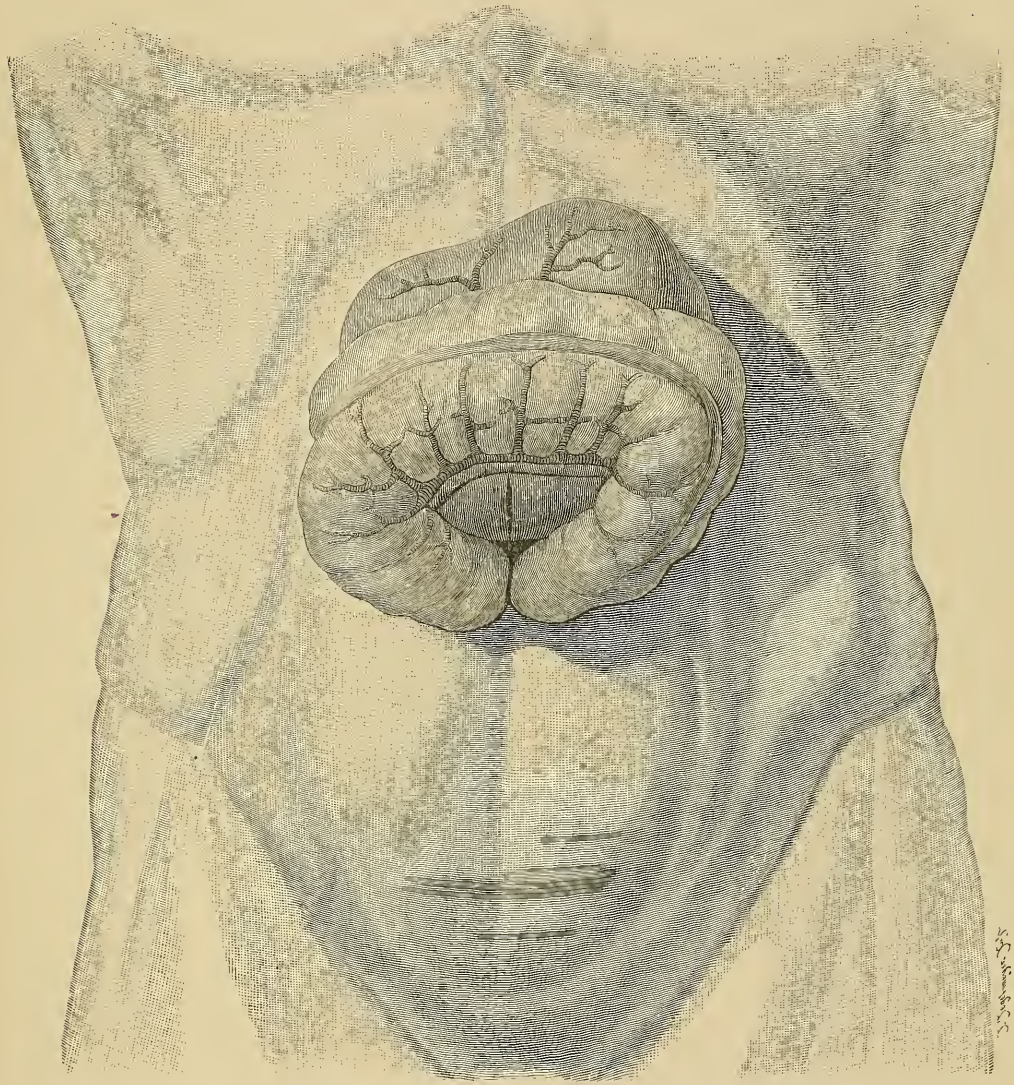

FIG. 336.—**Y**-method of gastroenterostomy (gastroenterostomia retrocolica posterior), first stage. The stomach has been pulled out and thrown upwards along with the transverse colon. Below the loop of colon the posterior wall of the stomach covered by transverse mesocolon is seen, a longitudinal incision having been made into the latter.

there is a great risk of the loop above the anastomosis becoming loaded with bile, and steps have to be taken to ensure complete evacuation into the lower portion of bowel. This can only be obtained with certainty by a second anastomosis, which, however, always means a prolonged operation to avert, as it

does, the onset of peptic ulcer. There are, however, few observations on this point.

Many surgeons, including Tavel, de Quervain, Krönlein, Koslowsky, and Jaboulay, not unnaturally conceived the idea of anastomosing the duodenum instead of the jejunum with the stomach, and in 1894 Jaboulay made an unsuccessful attempt in this direction. Henle, however, in 1898 obtained a very good result with it in a

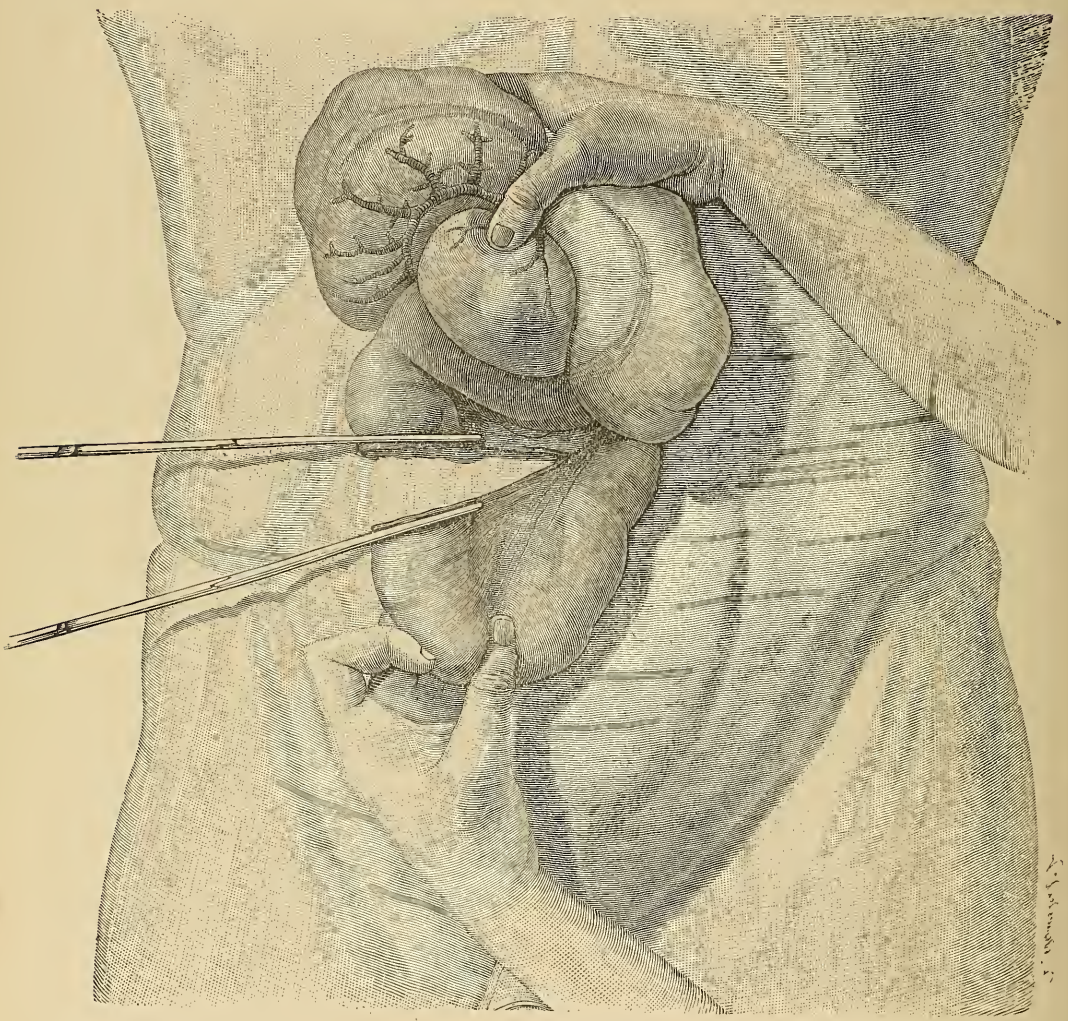

FIG. 337.—Y-method, second stage. The loop of jejunum is pulled forwards and divided between two pairs of crushing-forceps, the division being carried into the mesentery; the posterior wall of the stomach is projected through the opening in the transverse mesocolon by the fingers of the right hand.

case in which he found it impossible to carry out his original intention of performing pyloroplasty.

Villard[1] has an extensive experience of this anastomosis, which he makes below the pylorus and describes as "Gastro-duodénostomie sous-pylorique." Although he

[1] *Revue de chir.*, Paris, December 1903, "Gastro-duodénostomie sous-pylorique."

has employed it frequently, he agrees with the earlier operators that it is not to be chosen as a substitute for the other forms of gastroenterostomy, or even for pyloroplasty, but will remain an alternative in the presence of contraindications for the one or the other. The suturing of the stomach and duodenum is much more difficult than the operations usually practised.

We were the first to assign definite indications for the operation and to show how, by simplifying the technique, the operation can be made more effective, and therefore why it should be more often employed. By mobilising the duodenum [1] in

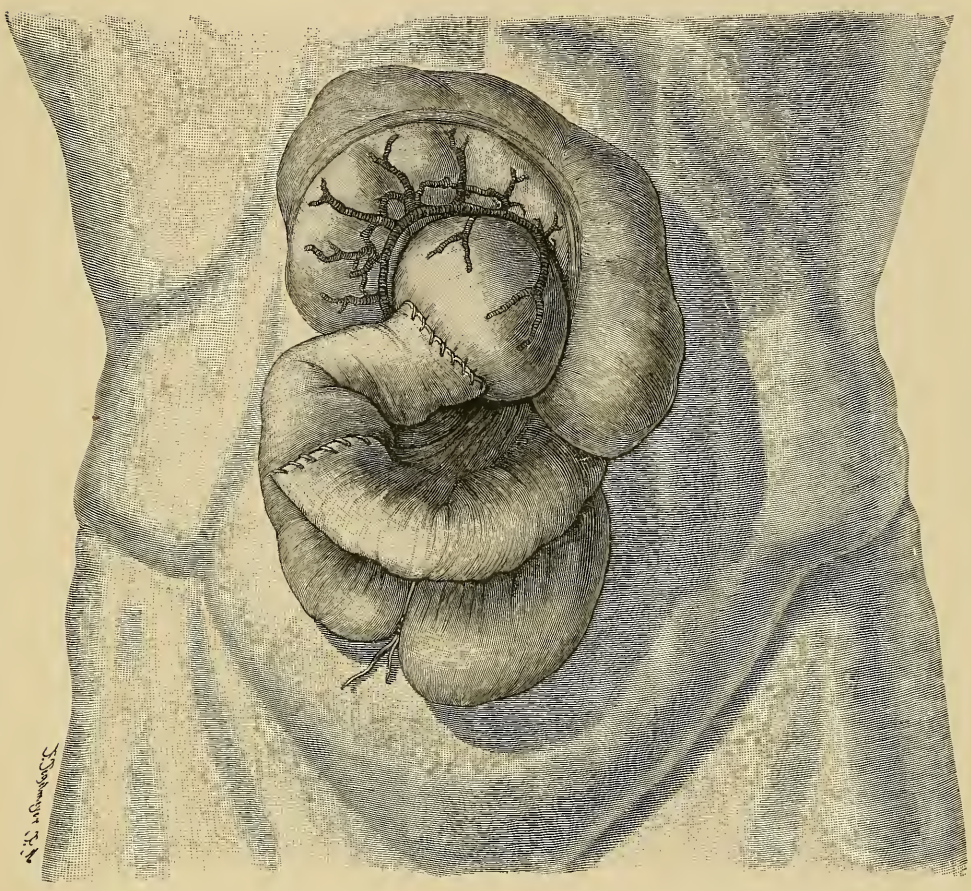

FIG. 338.—Y-method, third stage. The lower end of the divided jejunum is stitched to the posterior wall of the stomach with a double row of continuous sutures; the upper end, after being folded downwards and to the left, has been anastomosed with the bowel below. A temporary ligature has been tied round the emptied loop of bowel.

the manner we introduced, gastroduodenostomy will give in suitable cases as good results as the other forms of gastroenterostomy.

Dr. Gilli, who, in his dissertation, has collected 13 of our cases, comes to the conclusion that, as regards the immediate results, nothing better could be desired (none of the patients died), and that the final results are better than from all other methods. Apart from one patient who died of some unknown affection sixteen months later, one who died of hæmorrhage from an ulcer, and a third who could not

[1] "Mobilisierung des Duodenum und Gastro-duodenostomie," *Centralbl. f. Chir.* Bd. 2, 1902.

be traced, in only one case is the condition described as merely materially improved. In all the others the result is stated to be entirely satisfactory.

The explanation of these good results is self-evident—there is no loop of intestine in which the bile can collect, and therefore a vicious circle is made impossible.

Regurgitation of bile of course occurs, as it does in all the other methods of gastroenterostomy, but it is only of a temporary character and ceases when the anastomosis assumes the function of the pylorus and closes itself. This is amply proved by the results.

The following conditions may be regarded as contraindications :—(1) When the mobility of the duodenum and pylorus is interfered with by adhesions, or by cicatricial infiltration of their walls due to an extensive ulcer. Gastroduodenostomy is only possible when the duodenum can be made freely movable, and, further, the anastomosis can only be made with healthy walls; (2) where there is a marked degree of atonic dilatation of the stomach associated with ptosis, the method is equally unsatisfactory, for, in order to ensure that the stomach is thoroughly emptied, it is necessary to make the opening in its most dependent point. Gravity, however, is not the principal factor in expelling the stomach contents. Schnitzler, who has reported several successful cases of lateral gastroduodenostomy, has established this as a contraindication, for in one of his cases he had to open up the abdomen a second time.[1]

The operation is positively indicated in cases where evacuation of the stomach by the normal route is interfered with but not prevented, inasmuch as there is no great dilatation of the stomach or depression of the greater curvature far beyond the level of the umbilicus, such as occurs in severe pyloric stenosis. This method is particularly suitable when the disease which gives occasion for the operation is not situated in the neighbourhood of the pylorus, *e.g.* when ptosis, impaired motility, or hyperacidity in cases of ulcer in some other part of the stomach, necessitate an operation. These cases are by no means rare, and call for consideration distinct from that for obvious cases with a high degree of stenosis and marked gastric stasis.

Technique.—If there is any uncertainty as to what method is to be employed, a mesial incision is made, or preferably one over the right rectus, incising the sheath, displacing the muscle, and then dividing the posterior layer of the sheath and the peritoneum. If necessary, more room can be obtained by prolonging the incision at its lower end transversely outwards and dividing the rectus in the manner already described as the typical incision for cholecystotomy.

But if there is no doubt beforehand, and it has been decided that gastro-duodenostomy is required, the most suitable incision is the oblique one, two fingers'-breadth below the costal margin, already described (see p. 533). It leads directly down to the duodenum. The peritoneum covering the right kidney is incised vertically about an inch outside the second portion of the duodenum, and the latter is then detached inwards, and together with the head of the pancreas brought forward into the wound. The upper flexure of the duodenum is held in position by the hepato-duodenal ligament, while the lower flexure along with a portion of the third part of the duodenum can be mobilised as far as the point where the latter is crossed by the right colic artery.

When this separation has been effected, as is shown in Fig. 339, the fingers can be passed behind the pylorus and the second part of the duodenum, which allows of a curved clamp being applied to bring both parts in suitable apposition for the anastomosis being made.

The posterior serous suture is then inserted (as described in section 130), beginning above at the upper end of the second part of the duodenum. The serous and muscular coats are then incised vertically on either side and united with a posterior suture, after which the mucous membrane is divided, cleansed with lysol, and united with a continuous suture from behind forwards. Over this the anterior sero-muscular suture

[1] We are assured that Schnitzler is convinced that mobilisation of the duodenum can be performed quickly and easily and does not involve any interference with the nutrition of the duodenum or the healing of the wound.

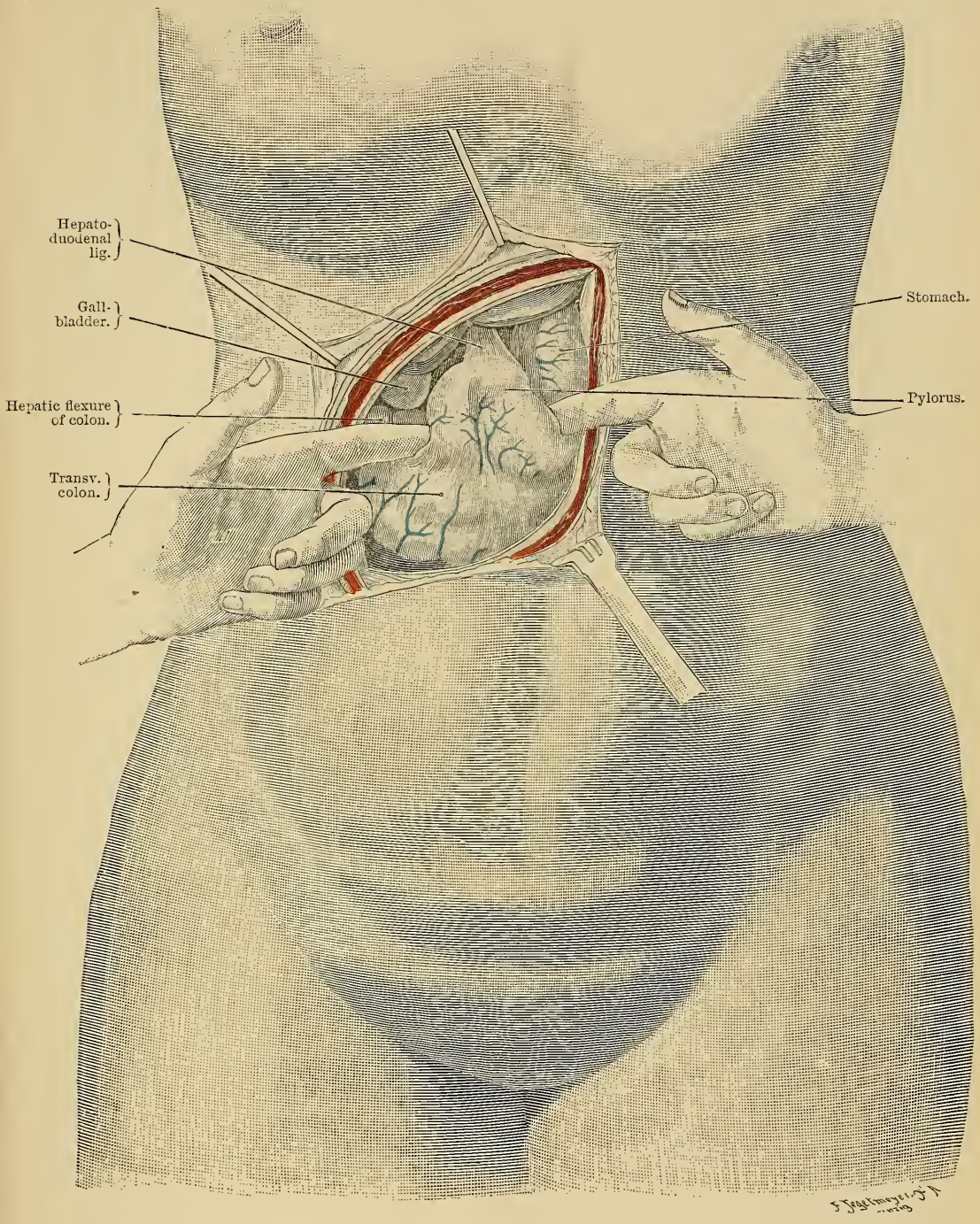

FIG. 339.—Gastroduodenostomy after mobilisation of the duodenum. The pyloric portion of the stomach and the second part of the duodenum are shown raised up on the index fingers and approximated from behind. Above the index finger of the left hand the hepatic flexure is exposed. The duodenal flexure is held in position by the hepato-duodenal ligament.

is inserted, and finally, after the anastomosis has been cleansed, the anterior serous suture is completed with silk.

The size of the opening between the stomach and duodenum need not be more than $1\frac{3}{4}$ inches, and it should be made as high up in the second part of the duodenum as possible, without causing any tension.

The ampulla of Vater lies opposite the lower end of the opening. As is to be expected, occasionally the bile and pancreatic fluid find their way at first into the stomach. This naturally neutralises the acidity of the gastric contents, but as a rule it is only a temporary condition.

Appendix. — Kocher's Gastroduodenostomy for simple Stenosis without Resection. Instead of lateral gastroduodenostomy, Meinhard Schmidt[1] has in certain cases recommended a method which is somewhat analogous to our operation of excision of the pylorus. It consists in dividing the pylorus transversely, closing the upper end, and implanting the duodenum into a special opening in the posterior wall of the stomach.[2] There is no doubt that there may be indications for this operation, for it certainly prevents any chance of regurgitation into the stomach, even better than the lateral method, and in our cases of resection of the pylorus we have always found this end-to-side union function perfectly.

Schmidt's method has a further advantage which he himself does not allude to, viz. that by pulling up the stomach we may insert the duodenum farther away from the pylorus into a portion of the stomach which is more dependent, *i.e.* the greater curvature, a point which would add considerably to the efficacy of the operation.

In the fourth edition of this work we dealt at length with the history, indications, and results of gastroenterostomy. In the present edition we only record what our recent experience has taught us. It has taught us that more consideration must be given to the ultimate results, now that, with an improved technique, the immediate dangers of the operation are negligible.

The matter rests thus: Gastroenterostomy must be regarded as one of the most satisfactory operations for the treatment of affections of the stomach associated with narrowing of the pylorus with which medical measures are powerless to cope. But in a certain number of cases it is followed by complications which result from the unavoidable formation of adhesions, and which are influenced by the operative method employed. The simpler the method[3] the less the trouble from adhesions. According to our series of cases, the best permanent cures are obtained with simple anterior gastroenterostomy. Other late complications, especially the occurrence of peptic ulcer,[4] are manifestly dependent on the method selected.

We must learn to avoid these dangers also. The surgeon who operates on hundreds of cases and never sees them again may easily be an enthusiast for one method if the immediate results are good, but it is only by carefully following up the patients that a knowledge of the serious disadvantages is gained. This has been the case with posterior gastroenterostomy and the Y-operation, in both of which the immediate results are good, but in which the troubles already mentioned may subsequently occur.

Further, the anastomotic opening not infrequently contracts again, causing a recurrence of the symptoms, and for this the responsibility lies with the method adopted. We have seen the opening become narrowed after the use of Murphy's button and the elastic ligature, and in the former case we should be surprised if subsequent disturbances of this nature did not occur. Systematic suturing in layers with accurate union of the mucous membrane is the best guarantee against later cicatricial stenosis.

If in describing the various forms of gastroenterostomy we have omitted to refer

[1] *Centralbl. f. Chir.*, 1901, No. 4. [2] See next section on Gastrectomy.

[3] It is worthy of consideration that Paterson in his Hunterian Lectures (*Lancet*, February to March 1906) gives the preference to anterior gastroenterostomy. Kümmel also with his rich experience adheres to anterior gastroenterostomy (Cf. Ringel, Hamburg, 1901).

[4] Delaloye (in a publication of Feurer's experience) has collected 29 cases from literature, Dissertation, Bern, 1906; *vide* also Tiegel, *Grenzgebiete*, Bd. 13, and Gosset, *Revue de chirurgie*, t. 26.

to that ingeniously constructed instrument, Murphy's button,[1] and modifications of it by Robson, Lamotte, Jaboulay, De Beule, and others, or to contrivances such as M'Graw's elastic ligature, it is for reasons mentioned. All these modifications, though very convenient at the time of the operation, only invite accidents, which can be avoided with certainty by the use of sutures. In anterior gastroenterostomy the suturing can be so easily done outside the peritoneal cavity that no one need grudge the little trouble it entails.

Appendix.—Pyloroplasty. Pyloroplasty has been advanced by Loreta, Heinecke, Mikulicz, and Finney as a simpler method than gastroduodenostomy. Loreta aims simply at stretching the stenosed pylorus by divulsion. It can only be considered in the presence of limited cicatricial bands, otherwise recurrence is certain, unless the divulsion is performed so energetically as to produce complications.

Heinecke and Mikulicz have attempted to dilate the stenosed pylorus by incising it in its longitudinal axis and stitching it up in a transverse direction. The ultimate results, however, are neither so effective nor so certain as gastroduodenostomy and the immediate results are in no way more satisfactory.

With Finney's operation, on the other hand, a sufficiently wide pyloric opening can be obtained. He[2] does not confine himself to mere division of the stenosis, but prolongs the incision into the stomach and the duodenum, and unites the cut edges of both all round right up to the pylorus and thus provides a wide communicating channel. Gould's[3] improvement on Finney's operation is shown in Fig. 340.

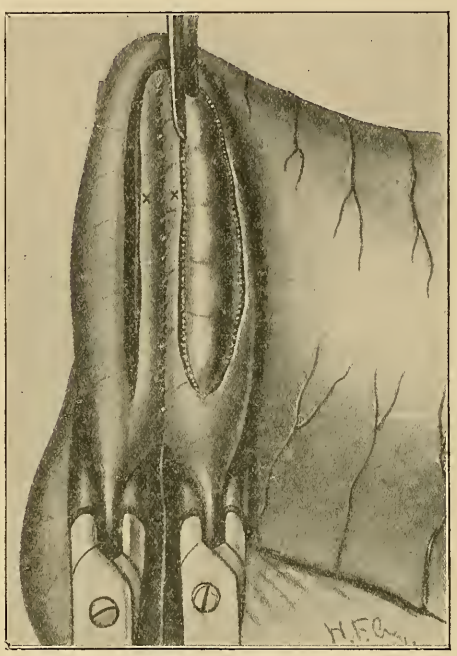

Fig. 340.—Gould's modification of Finney's pyloroplasty. The stomach and duodenum are clamped, the incision has been carried through the contracted pylorus, and the posterior continuous sero-muscular suture inserted.

Although the method provides a free communication between stomach and duodenum, it is no more effective than our lateral gastroduodenostomy and is more difficult to perform. We do not think it is beneficial to include in the suture the cicatrised part of the pylorus, as in many of our cases this portion of the pylorus was so cicatrised as to be practically immovable, and we were glad to leave it alone. The indications, therefore, for this method, are in our opinion even more limited than are those for gastroduodenostomy (by the methods described by Villard and ourselves).

131. Gastrectomy. Gastrectomy was first performed in 1879 by Péan and shortly afterwards by Rydygier, but it is due to Billroth's enterprise and the careful experimental observations of Gussenbauer, Winiwarter, Czerny, and Kaiser that the operation now owes its success. The first successful resection was done by Billroth.

Reference will be found in our previous edition to Guinard's valuable work, which deals with 291 cases, *i.e.* up to 1898, the mortality being 35 per cent. More recently, however, Leriche[4] has published a very complete and carefully-compiled review of

[1] *Vide* also Graser's communications at the Berlin Surgical Congress, 1906.
[2] Finney, *Bulletin*, Johns Hopkins Hospital, Baltimore, July 1902.
[3] Division of Surgery, May 1905, Harvard University, Boston.
[4] *Des résections de l'estomac*, Lyon, 1906.

1366 cases, collected under the supervision and at the instigation of Poncet, in which operation was undertaken for cancer of the stomach, the mortality being 25 per cent. Sarcoma of the stomach is also dealt with (Lécène and Petit, 57, and Howard, 61), and 24 cases in which gastrectomy was performed are quoted with a mortality of 11 per cent.

Gastrectomy is employed in the treatment of simple ulcer as well as malignant tumours. Very different opinions are held in regard to the whole question of gastrectomy for simple gastric ulcer, for while Krogius, Jedlicka (Maydl), and Rydygier attribute to it a wide sphere of usefulness, the majority of surgeons hold it is only indicated when the ulcer exhibits any sign of malignancy. We have come to a definite opinion regarding the latter condition, and from our experience of several very troublesome cases we would warn our younger colleagues against excising innocent ulcers. If the ulcer is freely movable, whether at the pylorus or elsewhere in the stomach, excision may be employed, but if, as is so often the case, it is surrounded by adhesive perigastritis with thickening, an attempt to excise it may land the surgeon in the greatest difficulty and lead to injury of adherent organs or important vessels.

(a) Gastrectomia Partialis

132. Pylorectomy. According to Leriche's figures (*vide supra*) Mayo and Mikulicz have performed the greatest number of resections of the stomach, viz. 100. We have now had an experience of 120 cases, and are in a position to justify the merits of the operation we recommend by stating our results, both as regards immediate and permanent recovery. In the first 52 cases we did, before 1898, which have been published by Broquet, the mortality was 25 per cent; in a subsequent series extending to 1903, collected by Dr. Matti, it was 17 per cent, and in the 21 cases[1] we have operated on within the last two years the mortality is also 17 per cent. But these figures are more interesting when we come to consider the diversity in the cause of death. Of the first 52 patients, two died of collapse, three of gangrene of the colon, two of gangrene of the duodenum, three of sepsis, two of pneumonia, three of pulmonary embolism, while in one case death was due to perforation by the Murphy's button; in the 47 cases collected by Matti the deaths due to local complications were only two, one from the stitches giving way and one from gangrene of the colon; while six were the result of broncho-pneumonia and degeneration of the myocardium, three patients being in an extremely reduced state. Finally, of the four deaths in our last 21 cases three are attributable to simultaneous resection of the colon, and one to pre-existing suppurative pancreatitis.

Our statistics of combined pylorectomy and gastroduodenostomy are proportionately more favourable. According to Matti, the mortality in 71 patients operated on between 1881-1904 was 16·8 per cent, and if we could be accused of having carefully selected our cases in this instance, the same cannot be said of our last 21 cases, for in these our method was used nineteen times.[2] In one of the two other cases, so much of the stomach had to be excised, that as the lumen of the remaining portion was so small, we united it directly to the duodenum, according to Billroth's first method. In the other case, a gastro-jejunostomy had been previously performed by one of our colleagues, and this we utilised after closing the stomach and duodenum.

Of the above 19 cases in which our method was employed, only two ended fatally —a mortality of 10 per cent. But even this percentage does not adequately express what can be accomplished in the radical treatment of cancer of the stomach by the possession of a proper operative technique. Complicated and uncomplicated cases should be regarded separately in comparing the results of simple resection of the stomach with those complicated by simultaneous resection of the intestine (transverse colon), pancreas, or liver.

[1] Deducting one case of death under the anæsthetic.

[2] This disposes of the statement by Kelling and others that the better statistics of gastro-duodenostomy depend on the fact that only the more favourable cases are suitable for this operation.

In the 32 cases tabulated by Broquet where Kocher's method was used, of the five deaths, two were in cases complicated by resection of pancreas and one by resection of the colon. In Matti's 39 cases, one death was due to gangrene of the colon, while of the two deaths in our last 19 cases, one was after an extensive resection of the colon and the other after resection of both the colon and the duodenum. It will thus be seen that although both Broquet's and Matti's cases give the mortality of simple gastrectomy as 13 per cent (two-thirds were due to cardiac degeneration and pneumonia, and only 4·3 per cent to complications in the course of healing of the wound), all the 17 uncomplicated cases operated on during the last two and a half years recovered.

Further experience has confirmed our opinion that surgery has reached a point where resection of the stomach, if performed at the right time, can be regarded as free from danger, *i.e.* in regard to the method of resection we employ, with closure of the stomach and gastroduodenostomy.

It has been urged that our method is difficult to perform. In answer to this, we would point out the difficulty which even experienced surgeons have in obtaining secure closure of the duodenum, a difficulty which is not diminished, and which cannot be evaded even with the Billroth II. operation. But the best answer is afforded by a glance at our results. Guinard shows that out of a total of 291 pylorectomies, the mortality after Rydygier-Billroth's operation No. 1, which was performed 148 times, was 35·3 per cent, while that after Kocher's operation (54 cases) was only 15·6 per cent. Similarly Hartmann's statistics with Kocher's operation are better than those of most of the surgeons who employed other methods.[1]

There is finally the question of permanent cure. It has been often alleged on theoretical grounds that in order to be able to perform gastroduodenostomy, an insufficient extent of duodenum must necessarily be removed.

Here again a reference to statistics affords the most conclusive evidence of this fallacy. Ninety-seven of our patients have been traced by Matti, and of these, twenty, *i.e.* 20·6 per cent, were alive, and with the exception of a girl aged nineteen who had an acute type of cancer, were in good health. In two of these nineteen cures the tumours could not be regarded histologically as carcinoma. Eight patients had been operated on for more than three years previously and one had died of pulmonary phthisis nine years after the operation, no recurrence being found at the autopsy. Four others of this list have since reported themselves as well. Five had died, either after a longer interval than three years or of some other condition and without any trace of recurrence. Deducting, therefore, these patients who have not yet reported themselves and also the 2 cases of simple ulcer, 18·4 per cent, *i.e.* 17 out of 92 cases, may be regarded as radical cures.[2]

All our patients operated on by the combined operation recovered with three exceptions. In two the tumour was not situated at the pylorus and were dealt with by circular resection of the stomach. In one case the Rydygier-Billroth method was employed, while the latter can also be included in our list as a proof that recurrence does not take place in the duodenum.

Leriche instances several cases of local recurrence after Billroth I. and Kocher's operations, but this does not at all prove that the recurrence was in the duodenum and not in the stomach. On the other hand, we maintain, with a proper technique, no more of the duodenum is required for anastomosis with the stomach than is required for the insertion of occlusion sutures. This argument, therefore, against gastroduodenostomy cannot be upheld, for even occlusion is always necessary and more duodenum cannot be removed and at the same time be reliably closed with a double row of sutures.

[1] Makkas states that in Mikulicz's resections of the stomach the mortality by Billroth I., where the duodenum is used, is less than by Billroth II., and Martin has lost 3 cases out of 4 by Billroth II. from complications immediately traceable to the method.

[2] Makkas (*Gedenkband für Mikulicz*, Jena, 1907) collected 130 of Mikulicz's cases of resection of the stomach. No report could be got of 10. Of 119 of which information was obtained, 17 were alive and apparently free from recurrence. Five, however, had died which had been hitherto regarded as radical cures, because they lived more than three years. This corresponds to radical cure in 18·4 per cent.

In this connection it is interesting to see what fruit the theoretical fear of our method has produced. Brunner [1] has come to the conclusion that the weak spot (*partie honteuse*), in the second Billroth operation (Billroth II.) is the closure of the duodenal stump and quotes a number of examples in his own experience as well as in the clinics of Czerny, Körte, Garré and Krönlein, where the sutures closing the duodenum gave way and led to suppuration and usually to death.

Schönholzer's views (Körte), which agree with those of Makkas (Mikulicz), are of special interest, namely, that the direct mortality from the first Billroth method is less than that from Billroth II. But Billroth I. is equivalent to our method as regards the amount of duodenum retained.

Steinthal [2] found that in three out of four patients who died after pylorectomy the cause of death was due to faulty closure of the duodenum, while in two other cases the same thing occurred without, however, being fatal. Kausch [3] in a review of 184 cases from Mikulicz's clinic refers to the obvious drawbacks of Billroth II. Peritonitis has frequently been found as the result of insufficiency of the sutures with perforation generally of the duodenal stump. In addition there is the risk of vicious circle.

In order to avoid the danger of the duodenum giving way, Brunner now recommends that it should be sutured to the abdominal wound. Steinthal, who tried this in 10 cases, found the results unsatisfactory, only one healing well, while a persistent fistula was left in the others. He recommends that the wound should be packed with gauze down to the duodenal stump. Kausch does not approve of either method and prefers Billroth I.

The last argument against gastroduodenostomy was destroyed when we demonstrated the simple manner in which the duodenum could be mobilised without endangering its blood-supply, and we maintain that gastroduodenostomy is possible in every case where, as in Billroth's second operation, the stump of the duodenum can be closed. The proof is to be found in the results obtained both by us and those other surgeons who have adopted our method.[4] With the exception of one case where a colleague had previously performed a palliative gastro-jejunostomy, the duodenum was implanted into the stomach in all of our last series of cases, and as they all made excellent recoveries, it seems to us that our combination of pylorectomy and gastroduodenostomy has established sufficient claims to be regarded as a standard method, for it possesses all the advantages of Billroth's second operation without its disadvantages. Those cases where the duodenum is involved and so adherent that it cannot be sufficiently freed to allow of its being securely stitched must as a rule be regarded as unsuitable for a radical operation. The first Rydygier-Billroth operation is inferior to our method and is no more simple to perform.

133. Technique of Pylorectomy with Gastroduodenostomy. After what has been said in the introduction to the surgery of the stomach and intestines, and in connection with gastroenterostomy, it is scarcely necessary to repeat our observations. *It should be a rule that the anastomosis be made with sutures*, as they are preferable to every other method. Murphy's button should only be used in extreme circumstances. With two or three rows of Czerny-Lembert sutures one has the satisfaction of knowing that the anastomosis is secure and can watch the further course of the case without anxiety. On the other hand, the use of Murphy's button and its modification (Jaboulay) exposes one to the risk of complications and makes one dependent on the skill of the instrument-maker.

Further, care must be taken that the proper kind of forceps are used for occluding the stomach and intestine. As already stated, crushing-forceps must be clearly distinguished from ordinary clamp-forceps. We believe we were the first to direct attention to the value of using strong, closely-fitting, crushing-forceps in operations necessitating division of stomach and intestine, and we attribute our good results partly to their use and to the fact that we do not hesitate to invaginate

[1] *Centralbl. f. Chir.*, 1905, No. 47. [2] *Ibid.*, 1905, No. 50.
[3] *Ibid.*, 1906, No. 5.
[4] Cf. the list of authors on this subject in our fourth edition.

the crushed edges with sutures.[1] When forceps such as those illustrated as stomach forceps in Fig. 341 are used, the section is made close to the blades. No necrosing edges are left, and the forceps form a convenient handle and facilitate the introduction of the sutures.

In contrast to these crushing-forceps, which grasp the extreme edges of the divided tissues, ordinary clamps should not cause any crushing. Doyen's pattern is too strong for this purpose. Ordinary clamps take the place of the fingers and shut off the lumen of the gut with the lightest pressure at some distance from the point where the division is made. Although they may be readily replaced by the hands of an assistant they are more convenient. A ligature tied lightly round the gut will serve the same purpose.

The Typical Operation. A mesial incision, 6 inches in length, is made above the umbilicus, and may be prolonged if necessary by carrying it to the left of the umbilicus. Skin, superficial fascia, and the aponeurosis of the linea alba are divided, and any bleeding points near the umbilicus secured. The extraperitoneal fat, which is often present in large amount, is divided and the peritoneum opened. Immediately above the umbilicus the peritoneum is covered by a fairly distinct layer of transversely-striated fascia (fascia umbilicalis).

The stomach is drawn forward and the position, extent, and mobility of the tumour are defined, while at the same time the mobility of the duodenum should be determined.

If any glands are present along the lower border of the pylorus or in the hollow of the duodenum, they must be freed by blunt dissection, taking care to ligature all the small vessels. As a rule the superior pancreatico-duodenal artery will also have to be tied. The gastrocolic ligament is then divided along the greater curvature, the separation being carried beyond the tumour as far as the point at which it is proposed to divide the stomach. The right gastro-epiploic artery will generally have to be tied.

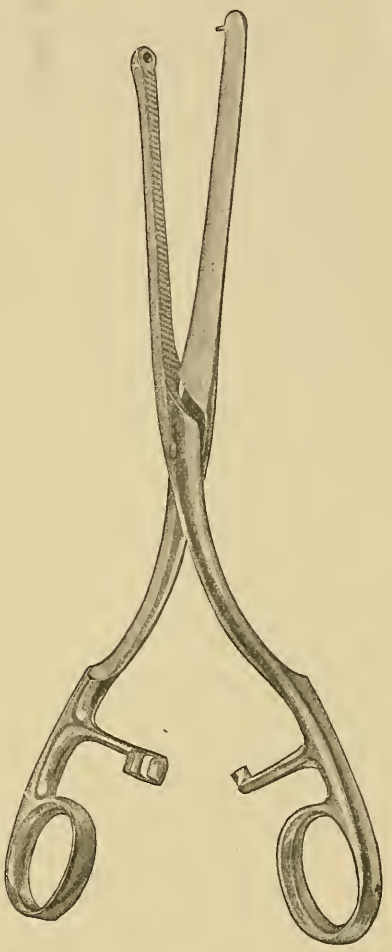

Fig. 341.—Large-sized intestinal crushing-forceps. The forceps are applied as firmly as possible and the intestine is cut through flush with the blades. The distal ends are here drawn rather too thick and heavy. Note that the forceps can be opened by still further pressing together the handles, and can thus be removed without causing injury.

Having freed the lower border of the duodenum, keeping close to the gut and avoiding unnecessary injury to its blood-supply, attention is then directed to the upper border of the duodenum. The fold of peritoneum attached along its upper border is divided close to the gut and the vessels in it are double ligatured.

A finger is now passed behind the first part of the duodenum to make sure that the division will be through healthy tissue, and that it is sufficiently free to allow of its being sutured to the posterior wall of the stomach. If, however, it will not reach

[1] In order not to lose the advantage of secure occlusion, one may not employ F. Schultze's modification of our operation, which presupposes a convenient access to the interior of the stomach.

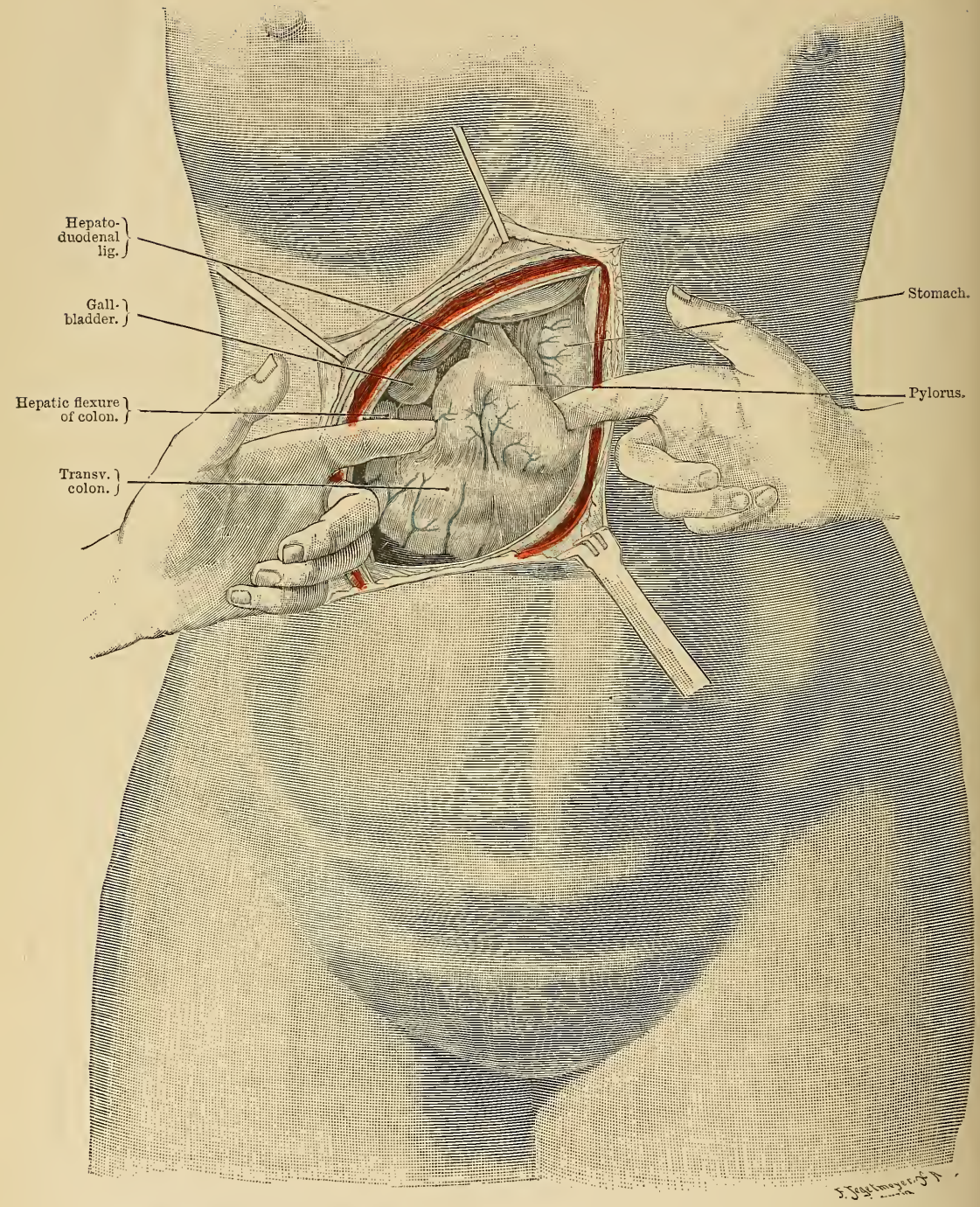

FIG. 342.—Gastroduodenostomy after mobilisation of the duodenum. The pyloric portion of the stomach and the second part of the duodenum are shown raised up on the index fingers and approximated from behind. Above the index finger of the left hand the hepatic flexure is exposed. The duodenal flexure is held in position by the hepato-duodenal ligament.

the stomach, it must be mobilized in the manner described under gastroduodenostomy (*vide supra*), *i.e.* by incising the peritoneum over the right kidney a thumb's-breadth outside the second part and detaching the latter inwards towards the stomach (see Fig. 342).

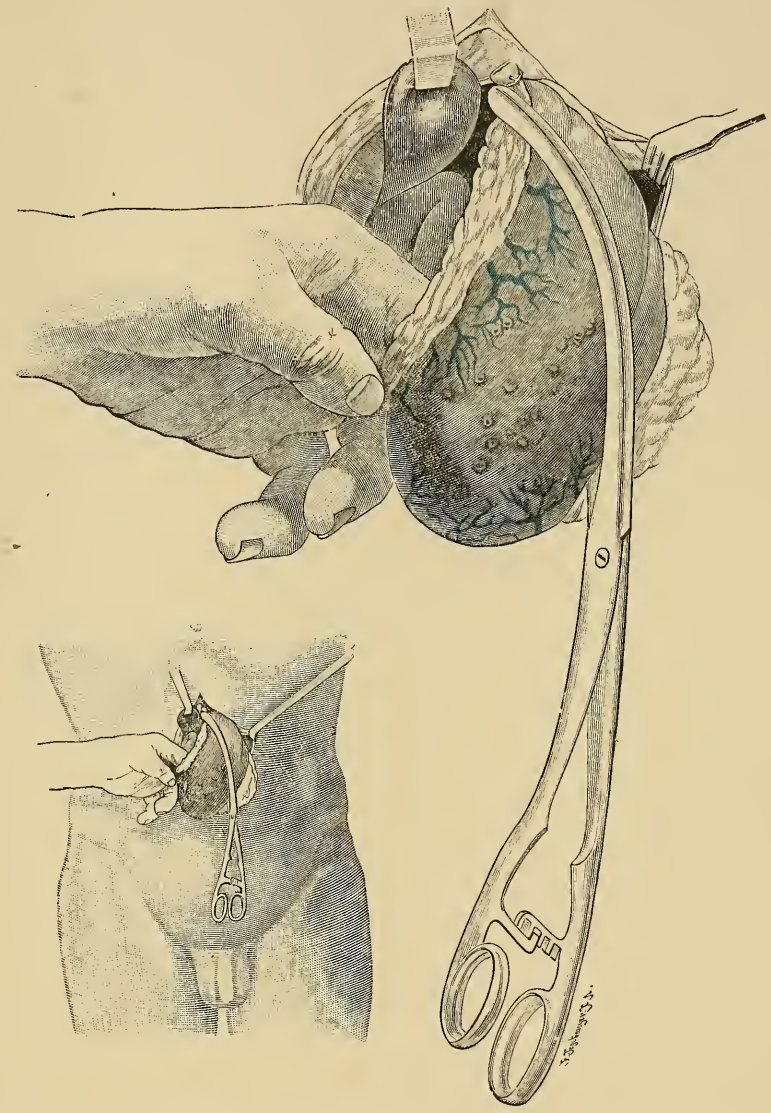

FIG. 343.—Pylorectomy. The lesser curvature has been freed beyond where the glands extend, the coronary artery has been ligatured, and a pair of crushing-forceps applied (only one pair of forceps is here shown). The edge of the liver is hooked upwards, and the pylorus and first part of the duodenum exposed.

The finger is then inserted behind the lesser omentum internal to the point where the peritoneum and vessels have been divided along the upper border of the duodenum, and the gastrohepatic omentum is divided so that the glands lying along the lesser curvature are below the line of division, and all the vessels are tied. This

division is carried as far as the glands extend. Beyond this point the coronary artery with its accompanying veins is ligatured and cut across close to the lesser curvature.

Provided now that it is not adherent to the colon or the posterior abdominal wall, the stomach can be lifted up and the resection begun. Two large crushing-

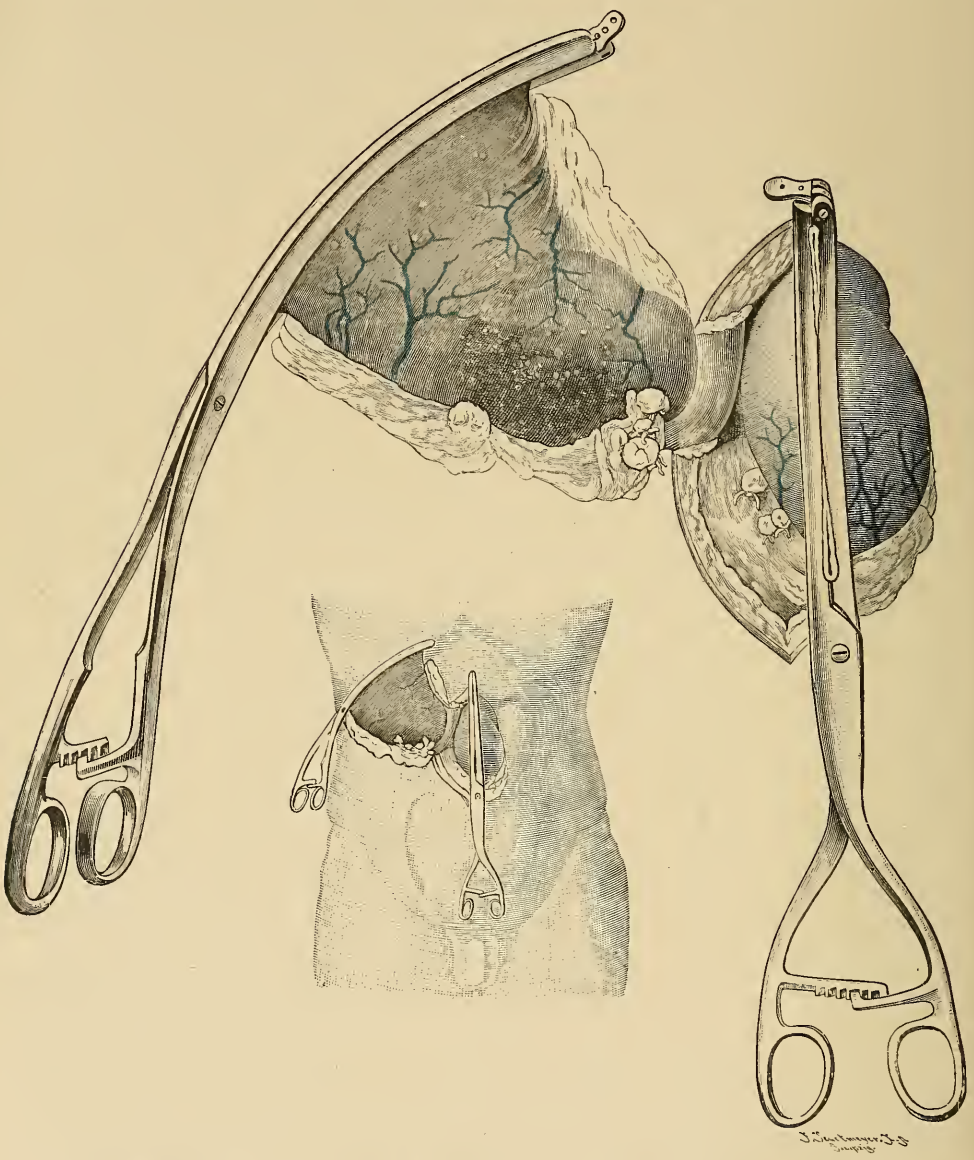

FIG. 344.—Pylorectomy. The stomach is here shown divided between two pairs of crushing-forceps, and the pyloric portion turned over to the right.

forceps (see Fig. 344) are then placed on the stomach close together, two fingers'-breadth beyond where there is any induration, and, after a roll of gauze has been placed underneath it, the stomach is cut across flush with the forceps on the upper healthy portion. The cut surfaces are cleansed with lysol and alcohol, while the

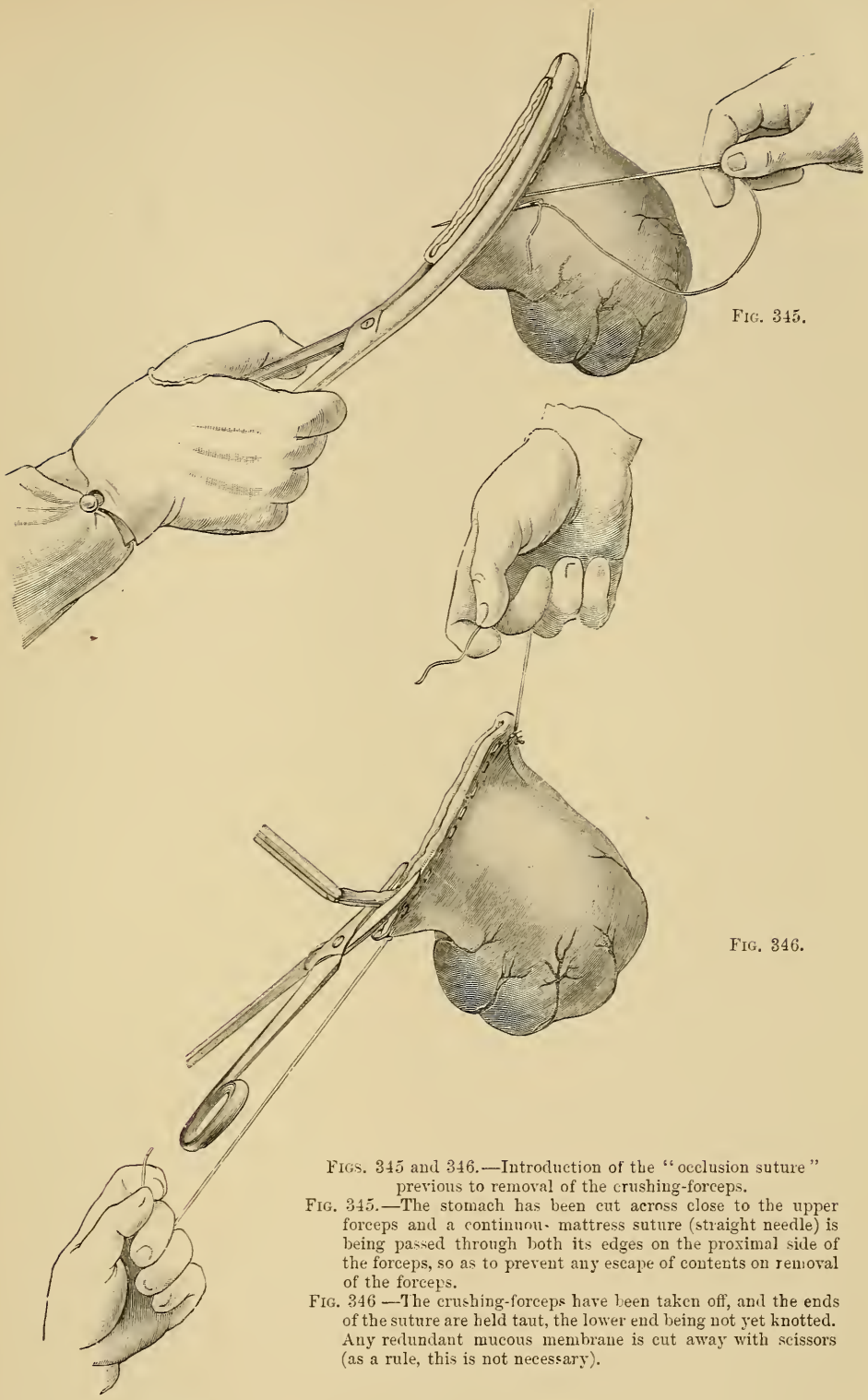

FIG. 345.

FIG. 346.

FIGS. 345 and 346.—Introduction of the "occlusion suture" previous to removal of the crushing-forceps.

FIG. 345.—The stomach has been cut across close to the upper forceps and a continuous mattress suture (straight needle) is being passed through both its edges on the proximal side of the forceps, so as to prevent any escape of contents on removal of the forceps.

FIG. 346.—The crushing-forceps have been taken off, and the ends of the suture are held taut, the lower end being not yet knotted. Any redundant mucous membrane is cut away with scissors (as a rule, this is not necessary).

forceps on the tumour portion of the stomach are wrapped in gauze and thrown over to the right (Fig. 344).

Traction is then made on the duodenum in order to see that when clamps are applied to it it is sufficiently free to allow of the distal pair being placed in contact with the stomach without causing tension. The duodenum is then clamped with two pairs of crushing-forceps at a part which is free from any palpable induration (this without exception stops short at the pylorus). The blades are firmly closed as in the case of the stomach, and it is cut across between the forceps. The tumour is then removed and the edges are cleansed with lysol and alcohol.

Fig. 347.

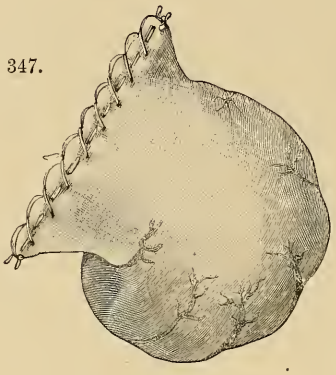

Fig. 348.

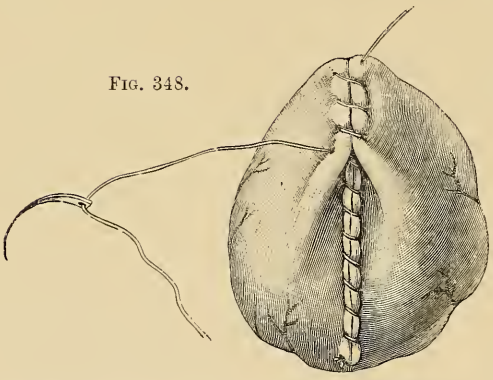

Figs. 347 and 348.—"Occlusion" of the stomach.

Fig. 347.—The stomach has been completely closed by a second continuous suture passing through all the coats and applied over the first.

Fig. 348 illustrates how the above two sutures are inverted by a continuous serous muscular suture.

An assistant now holds up the forceps in which the stomach is held (Fig. 345), and the latter is closed with a continuous through-and-through suture (mattress suture) which should be threaded on a straight needle, and inserted immediately behind the forceps (see Fig. 345) ($\frac{1}{2}$ Gely's suture). After drawing the suture tight the forceps are taken off. The projecting tissues may be trimmed with scissors, and any bleeding from the edge should be arrested by underrunning the vessel with a stitch or by clamping and tying the bleeding points.

A continuous running-suture, which includes the serous and muscular coats, is now introduced, and the cut edge of the stomach completely covered over. This suture is tied to the commencement of the first one, and over it a continuous serous stitch is applied, which invaginates both ends of the deeper layers of sutures (Figs. 347 and 348).

A light pair of clamp-forceps is next applied to the posterior wall of the stomach some distance from the line of suture. These forceps must on no account be of the crushing variety, for bruising of the stomach must be carefully avoided. If the forceps cannot be easily applied, the stomach can be held either in one or both hands of a reliable assistant, who rotates the posterior wall forwards and at the same time holds it in contact with the duodenum, so that the latter occupies a position parallel to and 2 inches from the occlusion suture and as near as possible to the greater curvature.

The posterior inferior wall of the stomach and the duodenal stump which is still closed by the forceps are placed in position (Fig. 349). The forceps on the duodenum form an excellent handle and enable one to rotate the posterior wall forward, and hold it accurately in position for the introduction of the posterior continuous serous suture. This is inserted without difficulty with a small curved needle, and as it holds the duodenum and stomach in contact, the subsequent stitching is comparatively easy. The forceps are not removed until the posterior serous suture is

completed, and not until the bowel has been lightly clamped lower down (not crushing-forceps) or shut off by lightly tying a thick suture round it. It is often sufficient if the assistant presses the duodenum against the stomach. The stomach is then

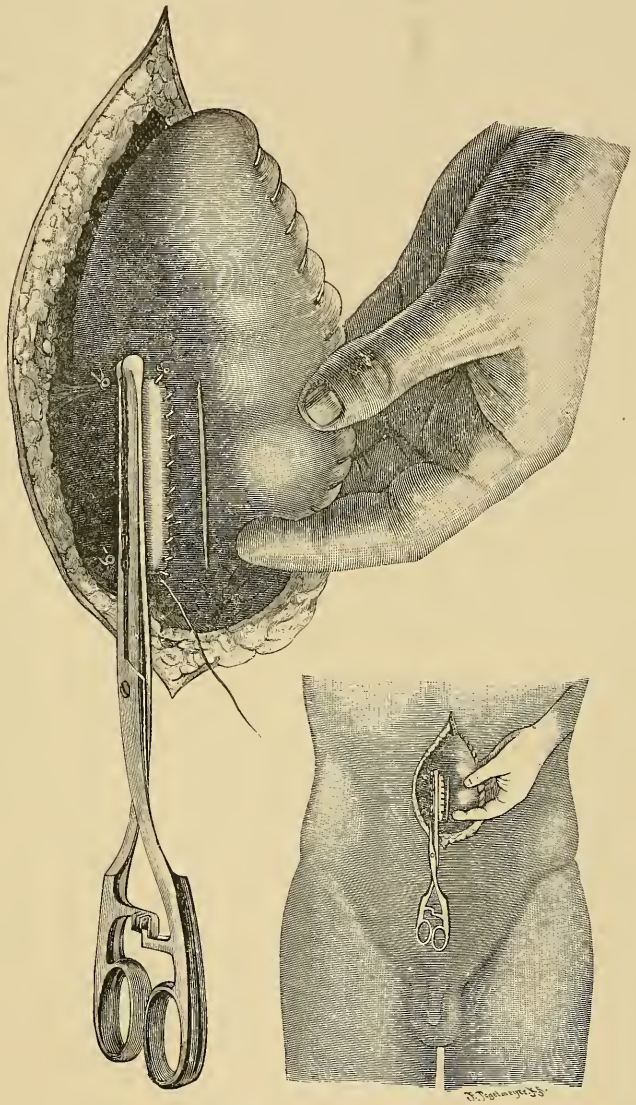

FIG. 349.—Pylorectomy. Last stage: Gastroduodenostomy. The end of the duodenum, which is closed with a pair of crushing-forceps, is applied to the posterior surface of the stomach, and the posterior serous suture is inserted. The stomach, which is held in position and closed by an assistant, is incised close to the greater curvature, the length of the incision corresponding to the breadth of the duodenum. The ligatured ends of the vessels along the upper and lower borders of the duodenum are seen immediately behind the forceps.

incised for a length equivalent to the breadth of the duodenum and at a distance of about a fifth of an inch from the posterior serous suture. Any large vessels, chiefly veins in the submucous tissue, are tied, and the edges united to the duodenum all

round with a continuous through-and-through suture. Care must be taken that the mucous membrane is in accurate apposition.

The introduction of the anterior serous suture presents no difficulty, and the

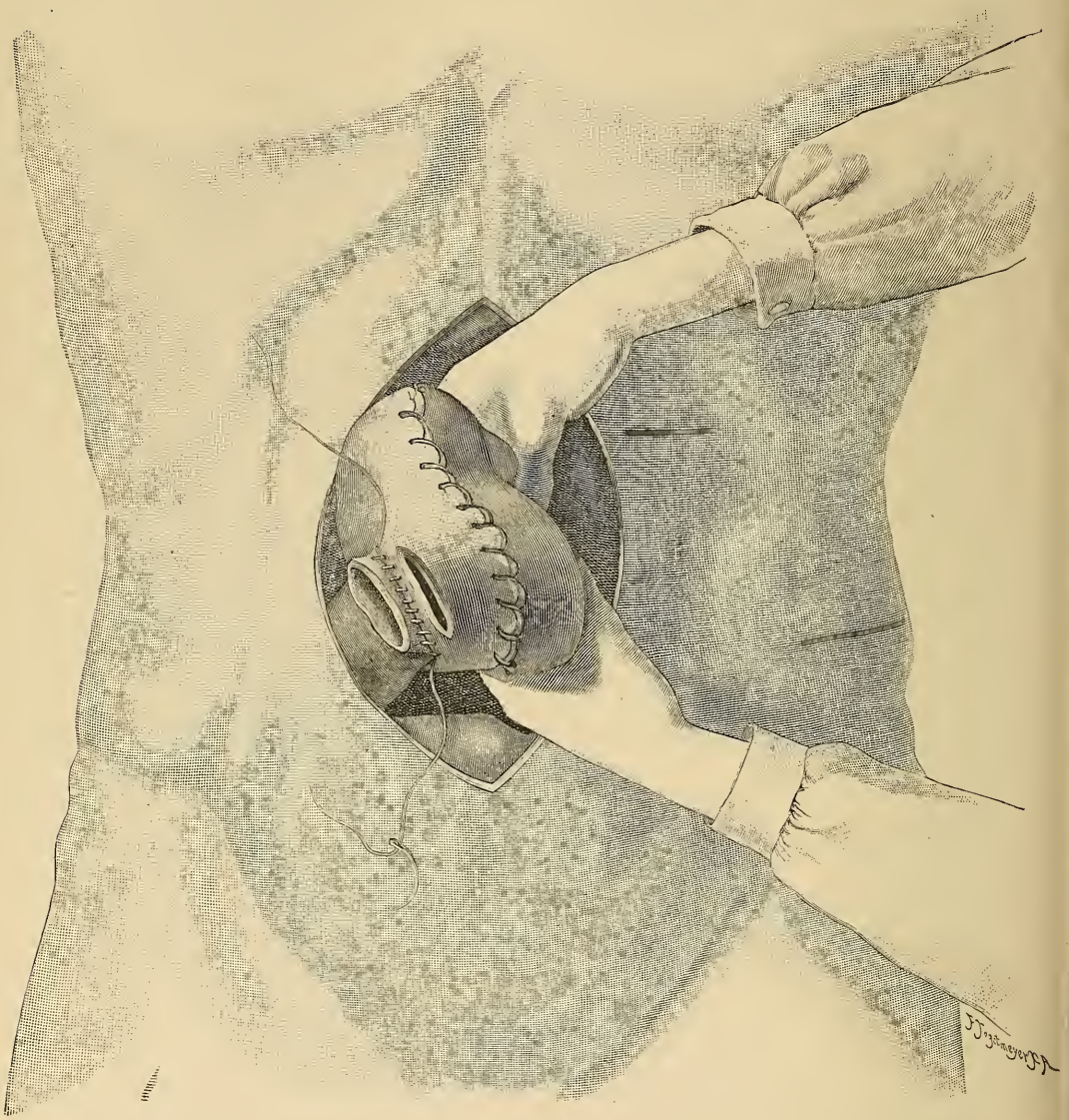

FIG. 350.—Resection of the pylorus. The stomach has been closed, and the duodenum is applied to its posterior wall. The posterior continuous serous suture has been inserted, and an incision corresponding to the lumen of the duodenum has been made in the stomach. The forceps have been removed from the duodenum to show deep suture.

anastomosis is completed by tying the anterior to the end of the posterior serous suture; it is assumed the material used is silk, which may be very fine if of good quality.[1]

[1] We again draw special attention to the fact that we absolutely reject Murphy's button for our

134. Pylorectomy with Gastro-jejunostomy. Billroth employs this operation in exceptional cases where the original Billroth method cannot be carried out, *i.e.* the insertion of the duodenum into the lower corner of the divided stomach. At the Congress of the Deutsche Gesellschaft für Chirurgie in 1887 we drew attention to the advantages of completely closing the stomach and implanting the duodenum into a separate opening and recommended it as a routine method. At that time we had gastro-jejunostomy in view, but we are convinced that it is not so effective as gastro-duodenostomy.

Despite its by no means brilliant results, gastro-jejunostomy has come to be widely employed in conjunction with gastrectomy in the Billroth II. operation. The reason for this is that gastro-jejunostomy is more easily performed, but the disadvantages, particularly in regard to the vicious circle, of a simple lateral anastomosis are still present.

Even a mild degree of vicious circle has here the disadvantage that the security of the suture by which the duodenum is closed is threatened by the upper part of the intestine becoming overloaded. This is the reason why, to use Brunner's words, this suture has become the *partie honteuse* in the Billroth II. operation, and why v. Mikulicz, one of the most successful abdominal surgeons, has come to the conclusion that of the two methods Billroth I. still gives the better results.

As we have already stated, gastroduodenostomy was always possible in our last series of cases. He who therefore adheres to the more convenient gastro-jejunostomy from unwarranted theoretical reasons is, in our opinion, bound to perform the operation in such a way that the possibility of a vicious circle is excluded, *i.e.* with the addition of Braun's entero-anastomosis or Roux's Y-operation.

The Billroth II. method requires no special description—it is performed according to the rules laid down in the previous section. Both the stomach and the duodenum are completely closed. The occlusion of the duodenum requires special care, for it is here that accidents most often occur. To ensure that it is securely closed the duodenum has to be separated for as great an extent as is required for implantation into the stomach, and in this respect the method presents no advantages over gastroduodenostomy.

After the occlusion of the stomach and duodenum has been completed, gastro-jejunostomy is performed, and to be entirely satisfactory the latter must be combined with one or other of the methods mentioned above, *i.e.* either Braun's entero-anastomosis or Roux's Y-operation. It is therefore seen that instead of the stomach or intestine being twice surtured as in our operation, four sutures have to be inserted, two occluding and two anastomosing. To avoid this some surgeons have had recourse to performing the operation in two stages—a not altogether pleasant experience for the patient.

135. Pylorectomy by the Rydygier-Billroth Method, No. I. This is the original method introduced by Billroth, with which the first successful resection of the stomach was accomplished. In it the tumour is excised, the duodenum implanted into the lower part of the cut edges of the stomach and the upper part closed. The weak spot of the operation is the point where the occluding suture of the upper portion of the stomach wound joins the anastomosing suture lower down, for it is difficult to obtain secure closure without causing tension. The method, therefore, has now been abandoned by the majority of surgeons.

136. Pylorectomy after Henle and Mikulicz, and after Rydygier. The Henle-Mikulicz method is analogous to the Rydygier-Billroth or Billroth I. operation, with this difference, viz. that a loop of jejunum instead of the duodenum is implanted into the lower part of the divided stomach. It may be employed in cases where the

gastroduodenostomy. If one looks at Kümmel's statistics (published by Ringel) relating to specially difficult cases, where fifteen died out of twenty-four, it is seen that Kocher's method gave the best results, but only in the cases in which Murphy's button was not used. Zoege von Manteuffel (*vide* W. Fick, Langenbeck's *Archiv*, Bd. 54) has only lost one case out of six operated on by our method, and speaks well of it. Hochenegg (*vide* Porges, *Wiener klin. Wochenschr.*, 1897) has not lost any cases out of four pylorectomies, and credits Kocher's methods with the excellent results he has obtained.

condition of the duodenum renders it unsuitable for gastroduodenostomy—in our opinion a very exceptional occurrence.

Rydygier's operation is categorical. He divides the jejunum 12 to 16 inches below the duodeno-jejunal flexure as in gastroenterostomy, inserts the upper end into the intestine six inches lower down and the lower end into the greater curvature. The operation is therefore a combination of the principle of Roux's Y-method with the Billroth II., and in this connection is worthy of much more consideration than the Henle-Mikulicz operation.

Rydygier, however, loses sight of the best feature in the Billroth II. operation when he proposes (in his second operation) to fix the efferent gut in the lower end of the divided stomach; and certainly few surgeons will approve of a complicated procedure such as refraining from immediate resection of the pyloric portion, but suturing it in the abdominal wound in order to feed the patient by passing a tube through this "fistula" into the duodenum, and only completing the resection at some later time.

The best features in Billroth's second and Rydygier's second method can be retained by first performing gastroenterostomy by the Y-method (gastroenterostomy by our method with a Braun's anastomosis is equally good), and at a later operation resecting and closing the stomach and intestine. Rydygier himself states that patients are often unwilling to submit to a second operation, and we maintain that the difficulty of dealing with the duodenal stump is not surmounted by this method any more than by Billroth's second method.[1]

137. Irregular and Partial Circular Gastrectomy. An irregular or circular gastrectomy may be indicated when the tumour is situated away from the pylorus, *e.g.* on the lesser curvature, or the posterior wall. If, in such a case, partial resection is undertaken, it is advisable to begin with the separation of the chain of glands along the greater and lesser curvatures and with division of both omenta. One or two pairs of clamps are then applied to shut off the rest of the stomach from the portion to be excised, and after carefully packing with gauze in order to prevent any soiling of the peritoneum, the stomach is cut across wide of the tumour, the serous coat being first divided all round with the knife, after which the tumour is cut away with scissors, keeping sufficiently far from the edge of the ulcer. Forceps are applied to the bleeding points, but it is not necessary to ligature them, as the hæmorrhage is arrested when the sutures are inserted. The projecting mucous membrane is first closed with a catgut stitch, after which the muscular and serous coats are united with a continuous suture of fine silk, and lastly the serous coat is sutured.

When a circular resection is undertaken, it is often necessary to make an additional incision in the gastric wall before the proximal and distal portions of the stomach can be securely united with three layers of sutures.

Cancer rarely affects the stomach elsewhere than at the pylorus. Comparatively recently, however, we have encountered two cases in which this was otherwise. Such cases are distinguished clinically by the absence of signs of pyloric obstruction or dilatation of the stomach, and beyond a sensation of fullness in the stomach, pain, disturbance of digestion and emaciation, the condition gives rise to few symptoms. These subjective phenomena may often only exist for some weeks or months, although objective changes characteristic of carcinoma (diminution of hydrochloric acid, etc.) are already present.

Simple ulcer, on the other hand, is more often situated at a distance from the pylorus, most commonly on the lesser curvature. We recently excised an ulcer in this position which had given rise to a recurrence of symptoms notwithstanding the fact that anterior gastroenterostomy by the Y-method had been performed some time previously. Although the anastomosis was functionally perfect, a typical ulcer on the lesser curvature was discovered. Recovery in this case was uneventful. As a rule, partial and circular resections run a satisfactory course.

[1] We learn from Kausch's *Gedenkband an Mikulicz* (Jena, bei Fischer, 1907) that Martin, a pupil of the admirable Mikulicz school, saw three deaths occur where Billroth II. had been performed, one because the stitches closing the duodenum did not hold, one from vicious circle, and a third death resulted from vomiting, while, according to Kocher, a fatal local complication occurred in one case.

138. Gastrectomy associated with Resection of the Colon. Although we shall consider the technique of resection of the large intestine in a later chapter, we might mention here that till recently the presence of adhesions between the stomach, colon, and mesocolon, was regarded as a most unfavourable complication to the performance of gastrectomy, while if the tumour is adherent to the pancreas and liver, resection, as a rule, has to be abandoned altogether as the chance of obtaining a radical cure is so slight.

Formerly, the great risk of removing a tumour which was adherent to the mesocolon lay in the onset of gangrene of the colon, which was manifested by symptoms of peritonitis developing about the end of the first week, the patient, after having at first made good progress, getting suddenly worse. This grave complication no longer need be feared. We are now able to judge of the vitality of the bowel by observing whether there is pulsation in its vessels. Wherever pulsation in the vessels cannot be found, the portion of the colon involved must be resected.

But notwithstanding this assistance, the mortality is still high. In no less than three of the four fatal cases mentioned in our third series of pylorectomies, simultaneous resection of the colon had been performed. On the other hand, two patients recovered after a similar operation.

What, therefore, can we do to diminish the dangers of a radical operation in those cases where the colon is involved? Whatever measures we adopt, the risks can only be partially diminished, for we are dealing with patients with advanced disease, who are already much reduced, and who, naturally, have to face an extensive operation.

Serious local complications can be prevented. In dealing with resection of the large intestine we shall consider the reasons why the results are worse than after resection of small intestine or stomach. The contents of the colon are so highly infective that the slightest escape sets up an infection of the surrounding tissues, while the stitches are so readily infected from the interior of the bowel, that, notwithstanding two or three layers of sutures, the closure may not be reliable.

We consider the only remedy for this is to close both ends of the large intestine with occluding sutures, and conduct off the contents of the gut by anastomosing a terminal loop of the small intestine with the large intestine at a suitable distance from the seat of the resection. This allows one to remove (1) as much of the colon as has a doubtful vitality, without any fear of causing necrosis from defective blood-supply, while at the same time (2) the junction of the intestines is relieved from the risk of mechanical and chemical injury from pressure of fæces. We refer the reader to the description of ileo-colostomy, which is described in the treatment of ileo-cæcal tumours (see p. 631), and which is an operation free from all risk.

The large intestine is resected as far as the interference with the mesocolon seems to have affected its blood-supply. The bowel is crushed with two strong compression-forceps and a ligature applied in the groove left by the one instrument. It is then divided close to the other pair of forceps with the thermo-cautery, which completely destroys the mucous membrane of the stump. The stump is then covered in with a suture passed through serous and muscular coats, and lastly the closure is completed with a serous stitch.

A loop of ileum near its termination is then drawn out and a lateral anastomosis made with the pelvic colon, using clamps in the manner to be described later. The ileum may be cut across low down, the cæcal end occluded, and the other end inserted into the pelvic or descending colon.

139. Gastrectomy with Resection of the Cardia. First of all, Mikulicz, and then Micheli, Marwedel, and Aesthower, showed how to obtain sufficient access in operations on the cardia, where careful suturing is essential. Marwedel's [1] operation deserves most commendation. In it an oblique incision is made along the costal margin, analogous to that described for exposure of the bile-ducts. The 7th and possibly also the 6th ribs are divided at the junction of their costal cartilages, and a flap consisting of skin and muscle is reflected upwards as far as the costo-chondral junction of the 7th, 8th, and 9th ribs, the cartilages of which are divided with the knife. By turning up the costal arch as a flap, good access is in this way obtained.

[1] *Centralbl. f. Chir.*, Aug. 1903.

We are convinced that, as was mentioned in connection with operations on the bile-ducts, it is frequently possible by merely bending the costal arch forcibly upwards to fracture the ribs at the junction of their cartilages. This is a much simpler procedure and provides excellent access.

Further, the researches of Biondi, Levy, and Krukenberg have proved of essential service, in regard to the technique of excision of the deeply-placed cardiac end of the stomach. According to Krukenberg, it is essential to free the œsophagus at its opening in the diaphragm, and to pull down 3-4 inches into the abdominal cavity (his experiments were performed on medium-sized dogs). Division of the peritoneum is essential. It is an undoubted advantage to procure a long intra-abdominal portion of œsophagus, because the point at which it is inserted into the stomach can be further invaginated, and the serous coat of the latter stitched higher up on the œsophagus, after the manner of Kader's gastrostomy.

From an operation which we undertook on the 21st November 1905, and from subsequent experiments on the cadaver, we recommend the following procedure :—

The abdomen is opened by a mesial incision, extending from the sternum to the umbilicus, exposing above the sternal attachment of the 6th and 7th costal cartilages. A second incision is carried outwards from the junction of the middle and lower thirds of the wound to meet the left costal margin at the junction of the 7th and 8th cartilage, and is then prolonged over the 7th cartilage obliquely upwards and outwards as far as the 6th rib, which is exposed subperiosteally and cut across, care being taken not to injure the pleura. The 7th and 8th cartilages are similarly divided at their junction with the ribs, and the ribs drawn upwards. At the upper end of the mesial incision the sternal attachments of the 6th and 7th cartilages are divided, after separating the perichondrium. The costal margin can now be turned up as a flap along with the skin and muscles, and access got to the under surface of the diaphragm.

This preliminary operation greatly facilitates access to the œsophageal foramen. By raising the left lobe of the liver, the left end of the coronary ligament (left lateral ligament) which passes from the diaphragm on to the cardia and œsophagus, is put on the stretch, and divided at the cardia, after which the peritoneum is incised all round as close as possible to the junction of the œsophagus with the stomach. In this way the vagus nerves are preserved.

A finger can now be hooked round the œsophagus and 2½ inches or more of the latter gently pulled down, force being avoided, as the muscular coat of the œsophagus readily tears. The vagus nerves can be easily drawn forwards if required. If the peritoneum round the end of the œsophagus is not divided, the diaphragm is not pulled down with it, while the pleura only follows it slightly as is shown by examination from the pleural cavity.

Two pairs of strong clamp-forceps[1] are then applied to the œsophagus close together immediately above the cancerous cardia, the portion in the grip of the upper forceps is ligatured, and the œsophagus cut across above the lower pair. The muscular coat of the œsophagus is now closed with stitches, and a Murphy's button passed by Sauerbruch's method into the blind end of the œsophagus from the mouth, a clamp being subsequently applied above it. Excision of the cardia is now performed in the same way as we described under resection of the pylorus, using large crushing-forceps and securely closing the stomach. The female half of a Murphy's button is then inserted into the stomach through a small special opening (which is closed immediately after), and is made to project against a portion of the fundus of the stomach which can be conveniently approximated to the œsophagus. A small incision is then made over it and the cylinder allowed to protrude.[2] In the same way the male portion in the lower end of the œsophagus is pushed through a small incision in the wall of the œsophagus above the constricting suture and the two halves of the button are united.

From what we have said regarding the first Billroth operation, we condemn inserting the œsophagus into the divided edge of the stomach by sutures (a method

[1] Crushing-forceps must be avoided here, since they cut through the friable œsophageal wall.

[2] Sometimes the incision can be made at first at the place where the button is to be fixed into the stomach wall.

which Levy has employed), but adhere to the principle, first laid down by us at the Surgical Congress in 1887, that the œsophagus, like the intestine, should be inserted into a special opening in the stomach.

No successful case of resection of the cardia has as yet been recorded, the operation seems to have been first performed on man by Mikulicz and Bernays.

We see no reason, however, why as good results should not be obtained after it as after total excision, if due regard be paid to contraindications. It follows, however, that it must be more rarely indicated, since at the time when operation is considered, the growth in the cardia has often spread to the œsophagus, or the primary focus may have originally been in the œsophagus.

According to Levy, Krehl has proved that the vagi may be divided in front of and behind the cardia without doing any harm.

(b) Total Gastrectomy

Since the last edition of this work was published, Boeckel [1] and Ito and Asahara [2] have collected the recorded cases of total and partial excision of the stomach. According to Ito and Asahara 108 cases have been reported.

Boeckel's list comprises 46 cases. The majority, however, must only be regarded as extensive resections, and were every surgeon to record extensive resections as total gastrectomies it is easily seen that the number of the latter would be considerably augmented. In Boeckel's own case of complete gastrectomy it was found at the autopsy six months later that there was a "new" stomach measuring 4 inches along its lesser curvature and 8 inches along its greater curvature.

Of these 46 total and "subtotal" gastrectomies, 39·1 per cent died, leaving 28 patients, in 21 of which the subsequent history has been traced. Eleven died from recurrence, 6 cases (two of which were not malignant) are still alive, while 4 have lived for more than four years. Of the malignant cases, those operated on by Ricard, Ribera, Brooks Brigham, and Maydl are still alive.

As regards the history of the operation, Ito and Asahara, from their knowledge of the literature on the subject, give Czerny the credit of having proved experimentally (Scriba and Kaiser) that total excision of the stomach is possible. One of the dogs used for experiments was carefully studied by Ogata (Ludwig), who showed that its digestion was in no way inferior to that of a healthy dog. This was, of course, a case of subtotal excision.

Carwallo and Pachon only once succeeded in performing a complete excision in a cat, Grohe once in a dog, while Monari and Filippi's animals all died. In 1880 Albert recommended total excision in man, and Nicoladoni suggested substituting part of the transverse colon for the stomach.

In 1883 Cormor first attempted total excision in man with a fatal result, but in 1897 Schlatter performed the first successful case, which, however, was subsequently shown to be subtotal.

140. Technique of Total Gastrectomy. A surgeon may feel justly proud if he has excised the stomach successfully, for it is an operation which demands a very skilful technique. The condition of the cardia is of vital importance, and the success of the operation largely depends on whether a portion of the cardiac end can be preserved or not.

The operation is not dangerous provided that the peritoneum covering the abdominal portion of the œsophagus can be preserved, and that, after clamping the latter immediately below the diaphragm there is sufficient room between the upper clamp and that on the stomach to allow of the application of two pairs of crushing-forceps. Only in this way can the cardiac end of the stomach be securely closed and infection prevented, while at the same time the tissue to be sutured is—thanks to the peritoneum—highly resistant and capable of rapid healing. To put it shortly, subtotal resection is a comparatively safe operation, but even when the greatest

[1] *De l'ablation de l'estomac*, Paris, 1903.

[2] Ito and Asahara, *Deutsche Zeitschr. f. Chir.* Bd. 80, 1905.

care is exercised genuine total excision often fails, because the slightest strain on the œsophagus will cause the stitches to cut through where it has no serous coat. When the disease involves the cardia itself the peritoneum must be divided at a higher level and a portion of the œsophagus pulled down through the diaphragm into the abdomen.

The condition of the œsophagus and the adjacent cardiac portion of the stomach is therefore the critical factor as regards success, and careful attention must be given to this point before undertaking the operation. It is much less important what part of the intestine is united to the œsophagus and cardia (whether duodenum or upper jejunum), the essential thing is that the anastomosis should be made without causing tension.[1]

It is interesting to observe how few objections have been brought against utilising the duodenum in these circumstances, while our method of partial gastrectomy has been severely criticised. Although the difficulties are greater in the former case, the majority of surgeons see no objection to uniting the duodenum to the œsophagus. Mobilisation of the duodenum materially facilitates the operation, and may well be employed in these cases with advantage.

(c) Total Gastrectomy with Œsophago-Duodenostomy

We give the following description of an operation as performed for diffuse cancer of the stomach necessitating also resection of the colon.

The operation was performed on 9th June 1899, with the assistance of Dr. Albert Kocher, and in the presence of numerous doctors and students.

After the abdomen was opened, the large tumour, which had been felt before operation, presented in the wound, and we saw at once that it was firmly adherent to the colon and transverse mesocolon, so that their removal had also to be considered. We therefore made a careful examination to ascertain whether excision should be undertaken or not.

As usual, the growth at the pylorus was sharply defined from the duodenum. There were no adhesions with the liver, but the stomach was firmly bound down to the spleen, so that dragging on the stomach pulled forward the spleen. The tumour moved freely in front of the spine. In order to secure a better view the incision was prolonged upwards to the xiphisternum, and we were then able, by passing a hand over the fundus of the stomach, to grip the œsophagus. The stomach was densely infiltrated up to the œsophagus, and here the disease was as sharply defined as at the pylorus. There were large adherent masses of hard glands felt along the greater curvature, but there were no nodules on the peritoneum. To enable us to draw the stomach farther out of the wound we clamped the adherent part of the transverse colon on either side with powerful forceps, and divided it with the thermo-cautery, so that a piece of transverse colon 5 inches long was left attached to the stomach. The duodenum, after being carefully isolated, was divided between two strong clamps, the divided ends being cleansed with lysol. The stomach could now be drawn farther out and the adhesions to the spleen separated, the vessels being divided between two ligatures.

We had some difficulty in separating the stomach posteriorly, as the transverse mesocolon had to be very cautiously separated as it passed over the pancreas, but this was successfully done after some large vessels were divided and ligatured. The upper part of the fundus of the stomach was quite free, and, after dividing the small omentum along the lesser curvature, we were able to isolate the œsophagus sufficiently to be able to apply two clamps close together and to cut between them.

With a little trouble the forceps on the duodenum were approximated to those on the œsophagus, and while they were held in position the serous suture was inserted posteriorly, and then, after shutting off the surrounding part with gauze tampons, we carefully removed the forceps. A continuous suture of fine silk (double) was then inserted through all the coats, and the edges of the œsophagus and duodenum

[1] Cf. Kelling's careful researches, Langenbeck's *Archiv*, Bd. 75.

were united, while, finally, the anterior serous suture was inserted and tied to the posterior one.

Considerable difficulty was experienced owing to the difference in size of the two lumina; the duodenum was too wide and had to be reduced by sutures to make it fit the lumen of the œsophagus. Lastly, we performed an end-to-end union of the divided colon in the usual way, using fine silk (double).

At the end of the operation, which lasted three hours, the patient was not at all collapsed. A subcutaneous injection of saline (1½ pint), as well as a coffee enema, was given in this case.

It will be seen from the above description that œsophago-duodenal suture can be accomplished with good prospects of success, if crushing-forceps can be applied both above and below at a point where there is a complete peritoneal covering, and if the forceps can be approximated and a reliable posterior serous suture inserted. Half the battle is gained when the two ends are brought into firm relation with one another.

Before the crushing-forceps are removed escape must be prevented by applying clamps both above and below at a sufficient distance away (3 cm. or more), after which the circular suture through the whole thickness and the anterior serous suture is completed (all with silk). We again mention, as was emphasised in speaking of operations for carcinoma of the cardia, that access is greatly facilitated by Marwedel's method of turning up the costal margin as a flap.

(d) Total Gastrectomy with Œsophago-jejunostomy

If the duodenum cannot be made to reach the œsophagus without tension, a loop of jejunum about 16 inches below the duodeno-jejunal flexure is selected (Schlatter), and an end-to-side anastomosis made by planting the œsophagus into an incision on the convex side of the intestine. Or the intestine may be divided, the lower end anastomosed end to end with the œsophagus, and the upper end inserted into the bowel lower down as in Roux's Y-operation.[1]

Before removing the crushing-forceps off the intestine one should always be careful to pack off the surrounding parts with gauze so that there may be no risk of soiling. Rubber gloves should be worn when inserting the sutures.

With regard to Murphy's button, which was used with success in Brooks' case, it may be employed (1) whenever there is any strain on the œsophagus, or when the introduction of sutures would seem to be too difficult. Brooks thinks it unnecessary to apply a layer of sutures over the Murphy's button. Before the introduction of the button the œsophagus should be securely closed with clamps 3 to 4 cm. higher up. (2) When the serous coat has to be divided, in order to pull down the œsophagus through the diaphragmatic opening into the abdomen. The end of the œsophagus may then be either closed with a ligature over which the muscular coat is stitched, and the button, passed from above, fixed in a small lateral opening; or, the male half of the button may be inserted in the end of the œsophagus, and the anastomosis completed with the female half in the duodenum or jejunum.

It is unnecessary to add to the description of the after-treatment of total and subtotal resection of the stomach given in the fourth edition, as a knowledge of it may be assumed. It does not differ from that for partial gastrectomy except that greater caution must be exercised as regards diet.

Appendix.—Gastroplasty

141. Gastroplasty. In 1898 Albert published a paper with reference to an idea of Nicoladoni regarding the possibility of substituting the transverse colon for the stomach. The middle part of the former attached to its mesocolon was inserted into the gap left after circular resection of the stomach, and the ends of the large intestine were to be reunited. The idea is not unreasonable. The colon can be transplanted

[1] It is interesting that no objection is raised in this case to making an ante-colic anastomosis, a proceeding so often proscribed for gastroenterostomy.

in this fashion and still maintain almost its normal connection with its vessels of supply, and it is not impossible that the great omentum could be used to strengthen and lend security to the line of suture on the stomach by doubling it over the line of junction above and below.

In his experimental work on the stomach with regard to transplantation Reerink refers to Senn's attempts. The latter was the first to recommend the regular employment of omentum for the purpose of lending security to the line of sutures. He also refers to the cases reported by Braun and Bennet in which plugs of omentum were used to close openings in the stomach, and also to Tietze's experiments on plastic operations with the omentum, of which we have already made mention in the introductory part, and to those of Enderlein. Reerink describes an attempt to get union between a piece excised from the transverse colon and the margins of a defect in the stomach. The result was entirely successful as long as the gut remained in undisturbed connection with the mesocolon. The transplanted sections of gut maintained their nutrition and continued to functionate. By other observers ulceration has been seen to occur on the pieces of gut which were transplanted.

Baldassari and Finotti [1] have had very good experimental results in cases of defects of the stomach and intestine from implanting seromuscular flaps from the abdominal wall. The layer of muscle towards the lumen became covered over with mucous membrane and contracted like connective tissue.

142. Gastrostomy. A temporary opening has occasionally to be made in the stomach, *e.g.* in perforation of a gastric ulcer when the patient is *in extremis*. This can be done by simply stitching the edges of the ulcer to the wound (Poisonnier) [2] or again it may be required for the purpose of dilating a stricture of the œsophagus. The formation of a permanent gastric fistula, however, is a much more important operation. It is indicated in cases where the patient cannot be fed by the mouth, *e.g.* in carcinoma of the œsophagus. Patients who are emaciated to a degree, or even moribund at the time of operation, may live for months and be quite able for work after gastrostomy.

It is important that the operation should not be delayed too long, otherwise the results are often not satisfactory. The patient is already poisoned by the absorption from extensive foul ulcers, and is more liable to pneumonia and heart-failure, while there is the risk of peri-œsophageal abscesses suddenly forming and bursting into the pleura, trachea, or aorta.

One advantage of early gastrostomy is that swallowing often improves spontaneously to a remarkable extent, so much so that the patient may consider that he has undergone an "unnecessary" operation. The ulcerated area is given a rest, the dilatation above it disappears, the decomposition as well as the associated inflammatory swelling of the surrounding parts diminishes, and the stricture again becomes permeable.

If it is properly performed, *i.e.* if escape of gastric juice from the fistula is prevented, gastrostomy gives rise to no inconvenience. We used formerly to keep the opening in the stomach closed with sticking plaster, but now we leave in a rubber tube permanently and clamp it with a pair of forceps, for it not infrequently happened that the patient either injured himself by forcibly pushing in the tube, or else failed to get it in at all.

(*a*) *Direct Gastrostomy.* The method which has given us the most satisfactory results is as follows:—A vertical incision is carried from the costal margin downwards over the middle of the left rectus through the skin and the anterior layer of the rectal sheath. We now pass towards the middle line between the rectus and the anterior layer of its sheath, till we reach the inner border, which is then pulled forcibly outwards according to Hacker and Girard's method. The tough posterior wall of the sheath and the peritoneum are then incised for about 2 ins. Two fingers are introduced into the abdomen and the stomach is pulled out, care being taken not to mistake the transverse colon for the latter. Care must also be taken not to suture the stomach too close to the pylorus, as the outflow through it would be hindered. A

[1] *Clinica chir.* Bd. 11.

[2] Poisonnier, *Arch. provinc. de chir.*, 1906, No. 7.

portion of the stomach is drawn out till the greater and lesser curvatures appear, and a sufficient area of the anterior wall, close to the former, is stitched firmly to the

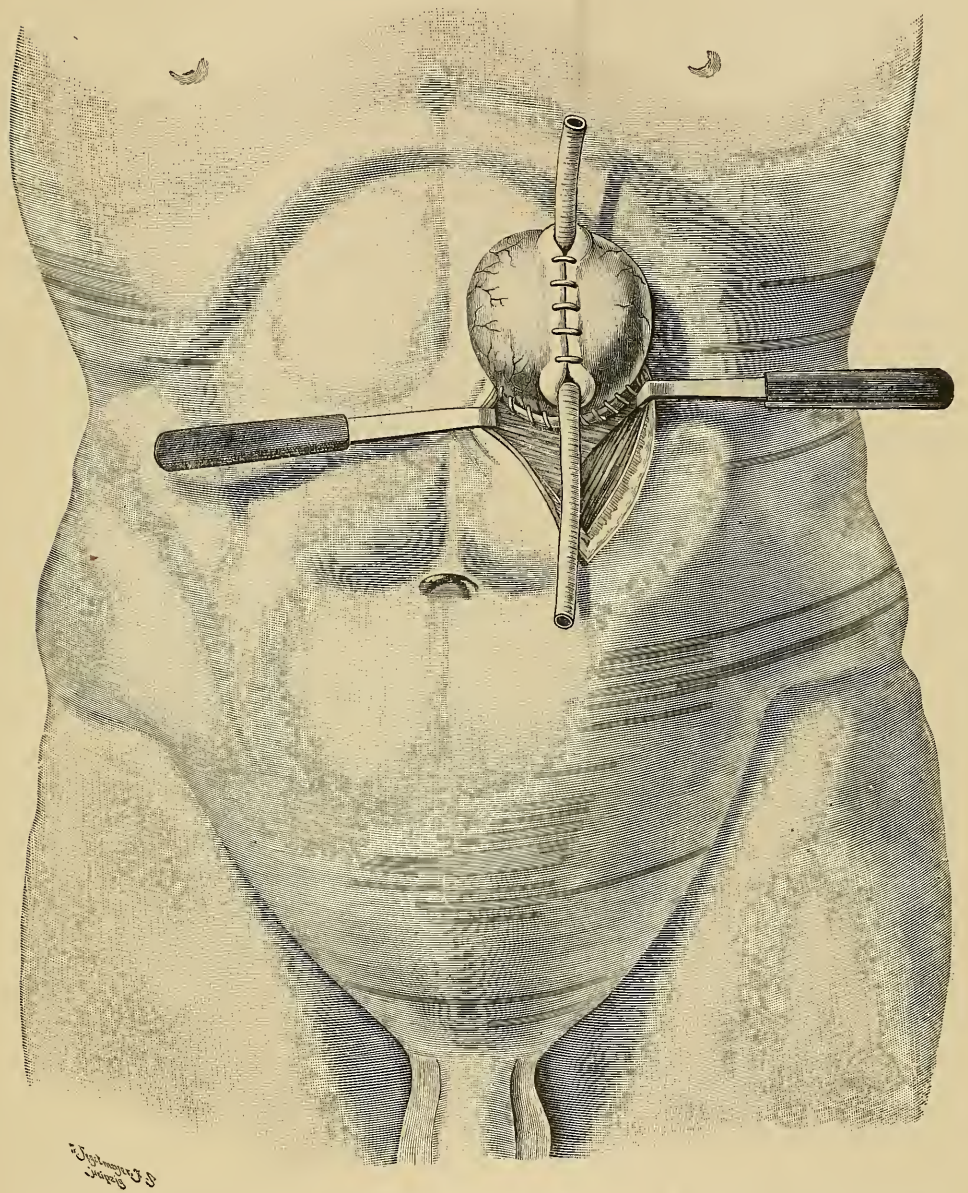

FIG. 351.—Hacker-Frank-Witzel method combined with gastropexy. A vertical incision is carried downwards from the edge of the ribs along the middle of the rectus muscle, which is drawn to the side; the peritoneum and transversalis fascia are stitched to the serous coat of the stomach all round and the stomach is folded and sutured over a drainage tube.

abdominal wound, a continuous silk suture passing through the serous and muscular coats of the stomach, and including the peritoneum and fascia of the abdominal wall. A narrow drainage tube (Witzel) is now laid vertically on the anterior surface of the

stomach wall, and the latter is stitched over it for half an inch by means of a continuous suture, applied in such a way as to include the serosa and a layer of the muscular coat on either side of the tube (Fig. 351). Just below the suture a small opening is made into the stomach, 4 ins. of the tubing is passed into it, and the serous coat is stitched over the part of the tube which is left exposed as it passes through the aperture in the stomach (Fig. 352, *a-c*). The stomach, all round the spot where the tube comes out of its tunnel, is now securely sutured to the skin. The edges of the wound are then stitched together over the stomach protuberance, and a short glass drain is inserted above and below, under the sutured skin wound.

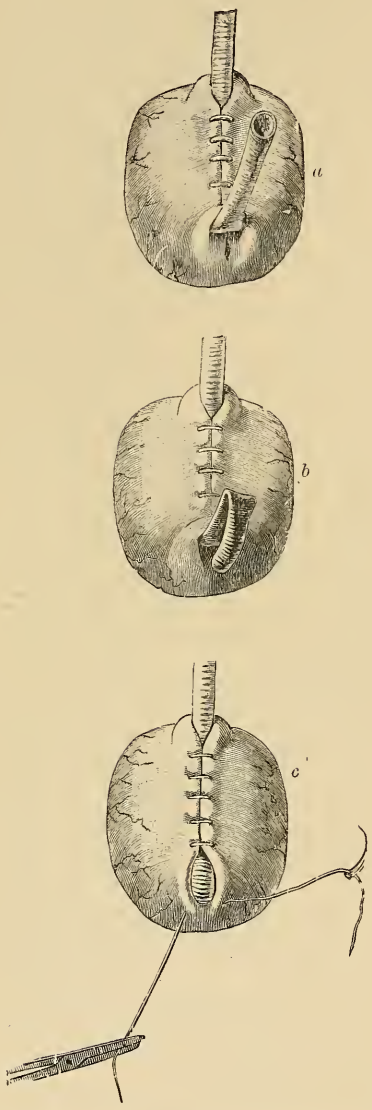

FIG. 352.—*a-c* illustrate the manner in which one extremity of the tube is introduced into the stomach through a small opening, and how the latter is covered over by another folding suture.

Some sterile water is poured through a funnel into the tube to see if the canal is clear. An iodoform gauze and collodion dressing is applied, and the tube is fixed to prevent it from falling out.

By the combination of the methods described by Hacker, Frank, and Witzel an entirely satisfactory result is obtained, as a long narrow canal is formed between the skin surface and the opening into the stomach. It is to some extent kept closed by the rectus abdominis, which lies to one side, and by its tension prevents any escape of gastric contents. The patient can feed himself properly through a narrow catheter, and no dressing is required, except perhaps a piece of elastic plaster. In an autopsy which we performed recently the stomach was found to be firmly adherent by cicatricial tissue to the abdominal wall, while the opening in the stomach, which had contracted, was drawn in and lined by perfectly normal mucous membrane, and was so small that it was difficult to find. It was connected with the opening in the skin by a canal $1\frac{3}{4}$ inches long, which had no mucous lining and was perfectly smooth.

By the addition of Witzel's method of forming an oblique canal in the stomach wall in conjunction with the muscular closure afforded by the rectus abdominis, not only is there no leakage from the fistula, but the closure is sometimes too effective, and some of our patients have been unable to reintroduce the feeding tube when they have pulled it out after leaving hospital.

Fischer and Marwedel constructed an oblique canal, not by making folds in the stomach wall, but by pushing a tube in between the muscular and mucous coats. Barrozzi speaks highly of the method.

Kader and Fontana, abandoning the oblique canal, have endeavoured merely to form a simple canal in place of the valvular fistula, and have sought by this means

to simplify the method of performing gastrostomy. Mikulicz has made extensive use of Kader's method.

We have recently tried this method on several occasions, and, on account of its simplicity, and because, as a rule, it gives a perfectly firm closure, we consider it desirable to illustrate the procedure [1] (Figs. 353 to 354).

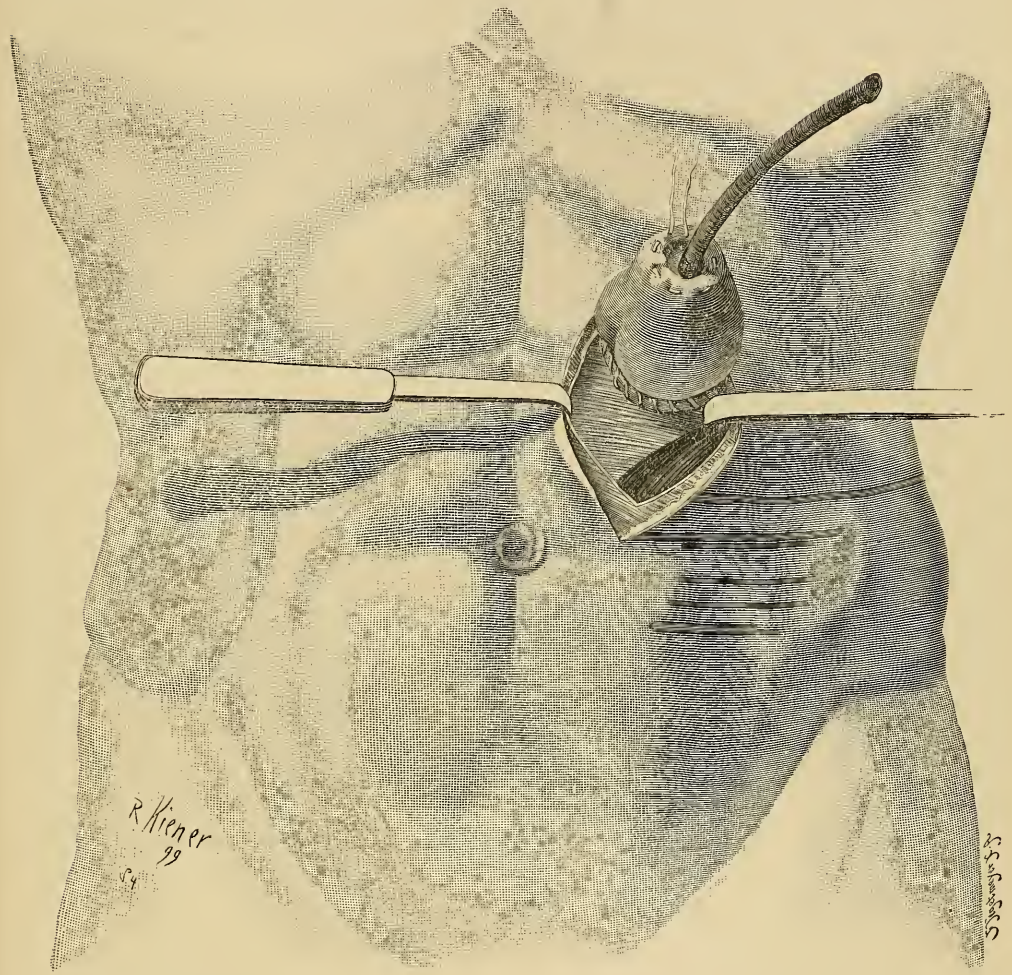

FIG. 353.—Gastrostomy. Kader's method of making a canal. A cone of stomach is drawn out and sutured to the peritoneum and fascia transversalis, the rectus being well retracted outwards. A rubber tube has been introduced at the apex of the cone and fixed with sutures; the tube has then been pushed farther in and a purse-string suture applied, which, however, is not yet drawn tight.

The cone of the stomach which is drawn out is incised at its apex by a fine knife, and in doing this care must be taken to fix the stomach so that the mucous membrane is not invaginated. The edges of the mucous membrane are secured with small hooks, and a tube is introduced and fixed in position by a fine suture, which traverses the whole thickness of the stomach wall.

The apex of the cone is now invaginated by pressing upon the firmly-secured tube,

[1] Lücke has described a similar modification.

and at a distance of 1 cm. a purse-string suture is introduced (Fig. 353) and tightened up around the tube. If it be desired to have a still longer canal, a second suture is introduced after invaginating the previous one, at a distance of about 1 cm., and tightened up around the tube as before.

In this way, as we have endeavoured to show in Fig. 354, a canal 1 or 2 cm. long, in which the tube lies vertically, is formed out of the stomach wall, and is invaginated into its cavity.

The chief difference between this and the method just described is, that there is no question of a rapid removal of the tube, as it is tightly grasped.

In order to ensure against accidents in gastrostomy, one must regard the following points as specially important in the method we have recommended :—

(*a*) The base of the portion of the stomach which is drawn out of the abdomen is to be sutured to the abdominal wall by a continuous circular suture (deep fixation suture) which completely shuts off the abdominal cavity. This is the best means of preventing peritonitis, because it prevents the escape of stomach contents into the abdomen, in case any should flow out between the wall of the stomach and the wound in the skin, or in case the stomach becomes detached from the skin.

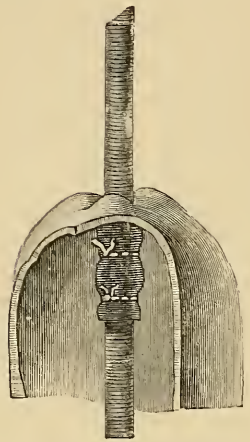

Fig. 354.—A longitudinal section of the stomach cone showing how a canal for the rubber tube is formed by a process of invagination.

(*b*) The secure suturing of the drain into the stomach, and of the stomach to the skin wound (superficial fixation suture), in such a way that the contents cannot escape alongside it, and so infect the pocket beneath the skin. This is important because, if a subcutaneous abscess is produced, it may spread to the peritoneum.

(*c*) The satisfactory drainage of the skin wound above and below the portion of the stomach which lies between the superficial and deep fixation sutures. Should there be any escape of stomach contents, the accumulation of any discharge must be prevented.

It does not so much depend upon how the incision through the wall of the stomach is made in order to prevent the subsequent escape of stomach contents : the important object is to make the opening as small as possible. Graser and Golding-Bird have already drawn attention to this point, and have advised that the opening, which is made as small as possible at first, should be subsequently stretched to the necessary size. By making a sufficiently small incision, the prolapse of the movable mucous membrane so closes the opening that nothing escapes ; besides this, it is also of importance that the opening (as Frank has well pointed out) be placed as high as possible in the stomach, and that it be also fixed as high as possible in the abdominal wall, which is just the reverse of what should be done in gastroenterostomy, where the lowest part of the stomach should be chosen.

In carcinoma of the cardiac end of the stomach, gastrostomy is of little use, for the stomach wall is apt to tear and the ulcerated mucous membrane does not derive the chief benefit of the operation, namely protection from every form of chemical irritation. In such cases v. Eiselsberg's jejunostomy (*vide infra*) is preferable, but it is here especially that a modification of gastroenterostomy lately introduced by Tavel[1] may be used with advantage.

(*b*) *Tavel's Jejuno-gastrostomy.*[2] The skin incision is placed lower down than for direct gastrostomy. Tavel places the centre of his left paramedian incision at the level of the umbilicus.

A loop of jejunum which has a long mesentery is selected and a portion of it is

[1] *Archives provinciales de chirurgie*, June 1906 ; *vide* also Dissertation by Dr. Th. Jeanneret, Bern, 1907.

[2] Prof. Tavel has been good enough to communicate his latest method of procedure to us.

excised. The excised portion is clamped so that its mesenteric attachment is in the middle and not at one end of the blades of the forceps.

The continuity of the gut from which the portion has been excised is restored by approximating and suturing the two ends. The isolated loop is brought out through the mesocolon and omentum (gastrocolic ligament) in front of the stomach and the anal end inserted into the stomach, while the oral end is brought out through a special opening as high up as possible in the abdominal wall.

Tavel affirms that the fistula is kept absolutely closed by the normal peristalsis, and that in coughing or even vomiting the stomach will empty itself through the œsophagus sooner than through the connecting piece of jejunum.

(*c*) *Roux's Œsophago-jejuno-gastrostomy.* Roux[1] has extended the principle of Tavel's operation in a very interesting direction. In a patient with an impermeable œsophageal stricture he isolated a long portion of the intestine, and passed it right up under the skin into the neck, with the object of uniting it with the œsophagus in this region and forming a new œsophagus.

Roux points out that the vessels supplying the jejunum are distributed on a far more regular plan than those which supply the bowel lower down, especially the ileum. In the case of the jejunum, there are numerous short vasa recta given off the last arterial arch, while spaces between the vessels which go to form the latter make it easy to divide the mesentery extensively without damaging the circulation in the intestine.

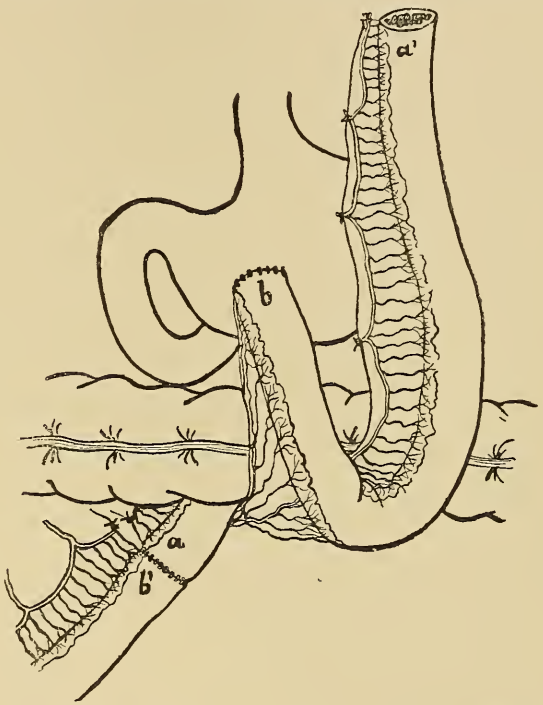

FIG. 355.—Reproduction of a sketch by Roux to illustrate œsophago-jejuno-gastrostomy. The continuity of the intestine, from which the loop has been resected, is restored. The anal end of the isolated loop is inserted into the stomach, the oral end is pulled upwards. Note the situation of the ligatures on the mesenteric vessels.

He found that by ligaturing four or five of these afferent vessels and at the same time preserving the peripheral arch the vitality of the gut was maintained by the vasa recta quite satisfactorily. In this way he was able to isolate a long enough portion of jejunum and to insert its anal end into the stomach near the lesser curvature in front of the transverse colon.

A longitudinal incision is then made below the supraspernal notch and a long pair of Richelot's forceps passed under the skin so as to make a subcutaneous channel through which the oral end of the gut wrapped in gauze is pulled and fixed to the edges of the wound with sutures. A stomach tube is then passed from above into the stomach and fixed in position, after which the ends of the divided jejunum were united with a Murphy's button. To enable the transplanted piece of bowel to be pulled through the wound, the sheath and to some extent the muscle fibres of the rectus were notched. The main wound is completely closed.

Fig. 356 illustrates the appearance after the operation. The closure of the gut

[1] *Semaine médicale*, January 1907.

is automatic and complete, and when food is put into it, it is rapidly carried down to the stomach by the peristalsis of the bowel.

We would point out that the idea of œsophago-jejunostomy (*infra*) had been previously put forward by Wullstein,[1] who, on the strength of experimental observations, suggested bringing a portion of intestine up in front of the thorax and uniting it by a plastic operation to the œsophagus, after the latter had been exposed in the neck. Roux's suggestion is, however, the simplest. We attempted the operation in an old man with cancer of the cardia, but had to resort to jejunostomy as the blood-supply of the isolated gut failed.

Appendix. Adhering to our principle only to describe those operations which we can recommend from our own experience, we refrain from giving a description of Bircher's gastroplication for dilatation of the stomach, and of gastropexy, introduced by Rovsing, for gastroptosis. Gastro-enterostomy gives such excellent results in dilatation and ptosis that apart from theoretical considerations we give it the preference from our own experience and that of others.

Gastro-gastrostomy for hour-glass stomach requires no special description as it is so rarely indicated, and because the procedure is the same as that described for gastrectomy. When it is not possible, gastroenterostomy should be performed.

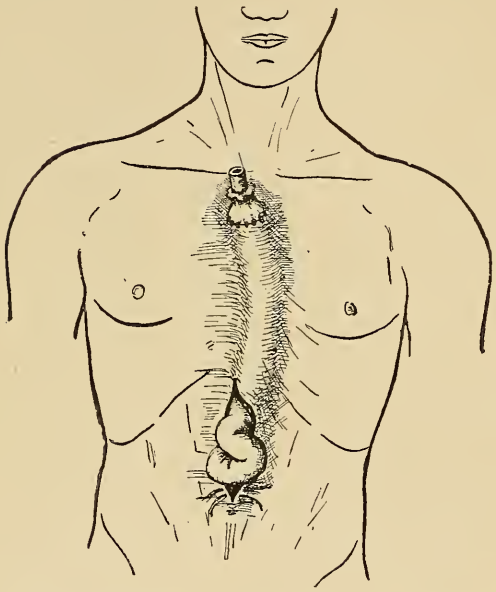

Fig. 356 represents the appearances after œsophago-jejuno-gastrostomy. (From a sketch by Roux in the *Semaine médicale*, Jan. 1907.)

(h) Surgery of the Intestines

143. General Remarks on Intestinal Surgery. The technique, as well as the results of operations on the intestine, differ according to the portion of gut affected. The surgery of the duodenum has already been dealt with partly under diseases of the bile-ducts and of the stomach, but it will also have to be considered in connection with diseases of the small intestine.

In considering the rest of the intestine it will be convenient to treat separately the vermiform appendix, the small intestine, and the large intestine, as the prognosis and treatment of disease in each of these situations is widely different, and depends chiefly on the altered quality of the content, as well as the ease with which it can pass through small openings and defects in stitching.

In this connection the vermiform appendix is by far the most favourable, as its contents are very scanty, and unless perforation occurs at its base in the course of a gangrenous appendicitis or as the result of accidental injury, the amount of fæcal escape is very slight. It possesses a strong peristaltic current, which in virtue of its direction, and provided it is not destroyed, acts against the escape of the colonic contents in those cases where a rupture has taken place, a point to which sufficient attention has not been drawn.

The difference as regards prognosis in the large and small intestine mainly depends on the altered character of their contents, for in the case of the latter the contents undergo a very active process of decomposition, and the slightest escape is sufficient to set up infection of the surrounding parts.

[1] *Deutsche med. Wochenschr.*, 1904, No. 20.

Sutures, moreover, are more readily infected and are therefore more liable to give way in the large than in the small intestine. The latter, therefore, lends itself far better to operative manipulations, suture, resection, short-circuit, etc., than the former. Even the most experienced surgeons often find that the sutures of the large intestine are insecure and give way.

Success in all intestinal operations is mainly dependent on the security of the intestinal sutures, especially in enterostomy, in all forms of anastomosis either simple or for short-circuiting, and in all operations where resection and suture or gut are required, *e.g.* in simple resection and plastic resections where one portion of intestine is substituted for another or for a hollow viscus, such as the bladder.

We shall consider intestinal surgery on these lines and deal with the features peculiar to each.

144. Enterostomy. Under the term enterostomy, *i.e.* making an opening in the intestine, are included such operations as appendicostomy, duodeno-, jejuno-, ileo-stomy, or colo-stomy. It is undertaken chiefly for the purpose of emptying the bowel, and may be either temporary to prevent the risk of stagnation of infectious contents, or to provide a permanent escape when the gut is obstructed lower down.

But in addition to affording relief in obstruction of the bowels (generally low down in the colon) enterostomy is employed for the purpose of administering nourishment when food cannot be taken by the mouth, and occasionally it is used for the exhibition of drugs. In these cases the opening is made high up in the intestine (duodenum or jejunum).

(*a*) *Temporary Enterotomy.* In temporary enterostomy, or to use the better term, enterotomy, the opening is closed immediately after the intestinal contents have been emptied. It is of great value both in mechanical ileus and in the dynamic type where the stagnation is caused by impaired peristalsis, consequent on over-distension and circulatory disturbances.

It is less often employed in infective enteritis, although with the exception of acute obstruction there is no condition which more urgently calls for the bowel being emptied, as the decomposition is very active and gives rise to rapid toxæmia. While the stomach can be readily emptied and washed out with a tube, the ordinary measures for emptying the bowels are often unsatisfactory or contraindicated. Enterotomy, by getting rid of the intestinal contents, therefore, achieves the same good results in severe toxæmia that lavage of the stomach does and is often the means of saving the patient's life. This is especially true in peritonitis where for a longer period provision has as a rule to be made for emptying the intestine than is required in the case of temporary stasis or infective enteritis. (See the following section.)

The technique of enterotomy is very simple. A coil of intestine is pulled out, fixed in the wound with a loop of thread which is passed through the mesentery close to the bowel, and secured with artery-forceps. The bowel is opened by a transverse incision on its convex surface, and a double flanged glass tube is tied in, to which is connected a rubber tube to carry away the fluid contents from the wound.

If enterotomy has to be performed in the course of a laparotomy, *e.g.* in a case of ileus, the bowel should be emptied both from above and below towards the opening, which should be, as a rule, as low down as possible.

The whole length of the small intestine can be thoroughly emptied, and if necessary can also be washed out with salt solution. Dahlgren has introduced a double roller by which the bowel can be "milked." We find it easier, however, to manipulate the bowel with the hands protected with rubber gloves than with instruments. Moynihan employs a glass tube 8 inches long which he inserts into the intestine, and after fixing it in position with a rubber band, 6 or 7 feet of gut are pulled over the tube and emptied. Finally the gut is picked up, and the small incision closed with a double row of sutures, after which the intestine is thoroughly cleansed with saline and replaced.

(*b*) *Permanent Enterostomy.* If provision has to be made for emptying the intestine repeatedly, the opening must be made so as to allow the intestinal

contents to escape for a longer or shorter period. This can be obtained in two ways, depending on whether the opening is to be allowed to close after a short interval or whether it is to remain open permanently.

A permanent opening in the small intestine is as a rule only indicated in cases of high-seated obstruction, *e.g.* in cancer of the stomach, to allow of the patient being fed. The technique of the operation will be described in the sections dealing with duodenostomy and jejunostomy. By stitching the mucous membrane to the skin, so that the mucous membrane projects like the lips, a permanent opening is obtained which functions well. Such a permanent opening is most frequently indicated in the large intestine (*vide* Colostomy).

On the other hand, an opening in the small intestine is generally of a temporary nature and is often resorted to in cases of ileus and peritonitis for the purpose of draining away the infective intestinal contents.[1] Some years ago in an article on ileus we drew attention to the toxæmia that follows the absorption of decomposing intestinal contents, and to the serious effect of distension on the intestinal wall.

It is generally recognised now that absorption of the decomposing stagnant fæces is the most serious feature of ileus and peritonitis, and that the toxæmic collapse is most rapidly relieved by emptying the intestines. Enterotomy or enterostomy is now universally employed in obstruction of the bowels in addition to laparotomy, or enterostomy alone may be all the patient can survive.

It is only recently that enterostomy has been extensively employed in the treatment of peritonitis. Some surgeons, notably Heidenhain,[2] Haffter,[3] and Lennander are strongly in favour of making more than one opening, and Payr, Lund, Moskowicz, Escher, and Hofmeister have recorded very good results with multiple enterostomy. As we have already mentioned, the opening is often used in order to stimulate the peristalsis by an injection of concentrated solution of Karlsbad salts (Busch), atropin in doses of 1 mg. ($\frac{1}{64}$ gr.) (according to Dahlgren, repeated four times), or physostigmin doses up to 1 decimg. ($\frac{1}{600}$ gr.).

Technique of Enterostomy, avoiding a Permanent Fistula. Enterostomy has often to be undertaken in patients already suffering from toxic collapse, the result of neglected ileus or peritonitis. It must therefore be performed as rapidly and in as simple a manner as possible under local anæsthesia (novocain and adrenalin).

The bowel should be opened at a point where the distension is most marked, if possible low down in the ileum. The skin and aponeurosis are incised, the muscles (internal oblique and transversalis) split with a blunt dissector, and after a second injection of novocain under the fascia transversalis the peritoneum is opened. One has then to determine whether the intestines are too adherent to the abdominal wall to allow of their being pulled out.

(1) *Enterostomy when the Gut is adherent, and the Intestinal Wall is friable.*— When a loop of bowel cannot be brought out, the edges of the wound, particularly the divided muscles, should be rubbed over with xeroform powder, and the parietal peritoneum and deep fascia (fascia transversalis) stitched to the serous and muscular coats of the bowel with a continuous suture (*vide* Fig. 357). A fine curved needle, and the thinnest silk must be used for this purpose, as if there is much tension, gas and fluid contents may escape even through very small stitch holes.

After the bowel is securely stitched to the abdominal wall it is punctured with a small knife. Gas at first escapes freely, followed by the fluid contents, which should be washed away with saline lotion (the bowel itself is not washed out). The surrounding parts are best protected by covering them with a large sheet of gutta-percha tissue which can be made to adhere firmly by pressure with warm gauze

[1] Posner and Lewin (*Deutsch. med. Wochenschr.*, February 1895) have given experimental proofs of the importance of autoinfection from the intestine. Twenty-four hours after tying the rectum in rabbits they found the B. coli in the blood of the heart, peritoneum, kidneys, and urine. Similarly Genersich of Mikulicz's clinic (*Beitr. z. klin. Chir.*, 1903) has recorded experiments on ligature of the intestine, in which there were produced excessive meteorism and decomposition of intestinal contents, damage to the intestinal wall, absorption of toxins, and rapid escape of the colon bacillus. Magnus has directly demonstrated intestinal poisons.

[2] Busch, *Deutsche Zeitschr. f. Chir.*, 1904.

[3] *Deutsche Zeitschr. f. Chir.* Bd. 74.

compresses. The intestinal contents are then led away into a bowl by folding over the edges of the rubber sheet.[1]

When the intestine has collapsed after being emptied, deep sutures should be inserted at both extremities and in the middle of the incision, if there is any doubt that the suture is not secure. A small drainage tube is then inserted in the opening and the wound packed with iodoform gauze.

(2) *Enterostomy when the Bowel is free and can be pulled out of the Abdomen.*—If it is found that, when the peritoneum is opened, the bowel can be brought out of the wound, and that its walls are not friable, the operation is carried out on different lines to that just described. Here the intestinal contents are led off without coming in contact with the wound at all, and for this purpose either Paul or Mixter's tube is used by preference in England and America.

After the peritoneum has been opened a distended loop is pulled out, emptied by milking back its contents, and clamped, gauze compresses being carefully packed under the clamp to protect the wound from soiling. A small incision is then made into the gut on its convex side, a glass tube is tied in with fine silk (Fig. 358) and the edges of the incision are disinfected with lysol and alcohol. The forceps are now taken off and the bowel is emptied: if desired, it may be washed out before the loop is replaced inside the abdomen. The gut, in which the tube is, is then replaced, and stitched to the parietal peritoneum and fascia with two sero-muscular stitches.

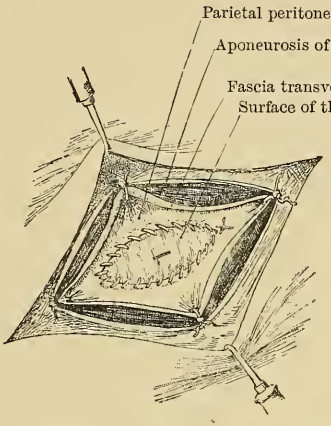

FIG. 357.—Formation of a fæcal fistula.

Before the gut is opened a purse-string suture should be inserted, which when tightened keeps the tube in position, while the ends of this suture may also be fixed to the abdominal wall. Iodoform gauze is packed all round the glass tube, and the intestinal contents are led off with a rubber tube. Adhesions form in a few days (*i.e.* before the sutures cut their way out and the tube becomes loose) and the wound is protected by granulations.

One can be more certain of the opening ultimately closing by making an oblique fistula according to Witzel's method. To do this, a rubber tube is applied along the wall of the gut and fixed there with stitches. The one end of the tube enters the gut while the other is brought out through the wound in the manner described for gastrostomy.

An oblique fistula heals spontaneously soon after the tube is taken out. The bowel round the tube should be stitched to the under surface of the peritoneum in the same way as when Paul's tube is utilised.

Patients who come to the table cyanosed, with cold extremities and with a small rapid pulse, are quite unable to stand any shock, absorption of poisons, severe pain, an increase of the abdominal hyperæmia, or any action of toxins. They often recover in a marvellous manner under enterostomy, subcutaneous saline injections, and nutrient enemata.

Enterostomy is also of advantage in the collapse due to ileus and peritonitis, when an attempt to remove the original cause by laparotomy would only hasten a fatal issue.[2]

[1] We consider this adhesive rubber tissue better than Heidenhain's cloth covered with zinc paste which Busch recommends.

[2] Cf. the excellent work of W. Braun (*Beitr. z. klin. Chir.*, 1904) which is based on Krause's large experience.

(*c*) *Permanent Enterostomy.* While temporary enterotomy as well as enterostomy in the vast majority of cases is performed in the ileum, as ileostomy, and occasionally as jejunostomy and colostomy, a permanent opening, on the other hand, is most commonly made in the jejunum and colon, the upper portion of the intestinal canal being utilised for the administration of nourishment, the lower portion, when a permanent exit for intestinal contents is intended. The different forms must therefore be kept separate.

145. Duodenostomy. The method of exposing the bile-duct or the duct of

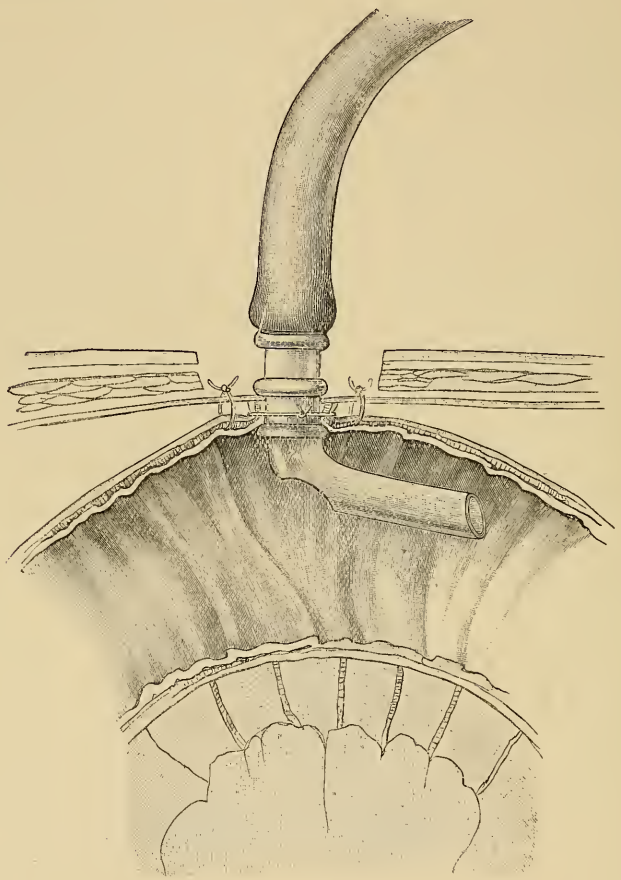

Fig. 352.—Enterostomy in small intestines. The figure illustrates, in section, the manner in which the glass tube is fixed in the intestine, and how the bowel is united to the fasciæ with sero-muscular stitches. The external wound is not closed.

Wirsung through the duodenum has been described under the surgery of the bile-ducts and pancreas. The idea of making a permanent opening in the duodenum was first suggested and carried out by Braun, while Langenbeck performed the first successful case. Hartmann recommends it instead of jejunostomy.

There is no doubt that the operation is greatly simplified by mobilising the duodenum, for the bowel can then be brought up and fixed to the abdominal wall without tension, a procedure which, without mobilisation, may be very difficult. A somewhat larger incision is required than that for jejunostomy, and since the introduction of Maydl's modification of jejunostomy, in which the bile and

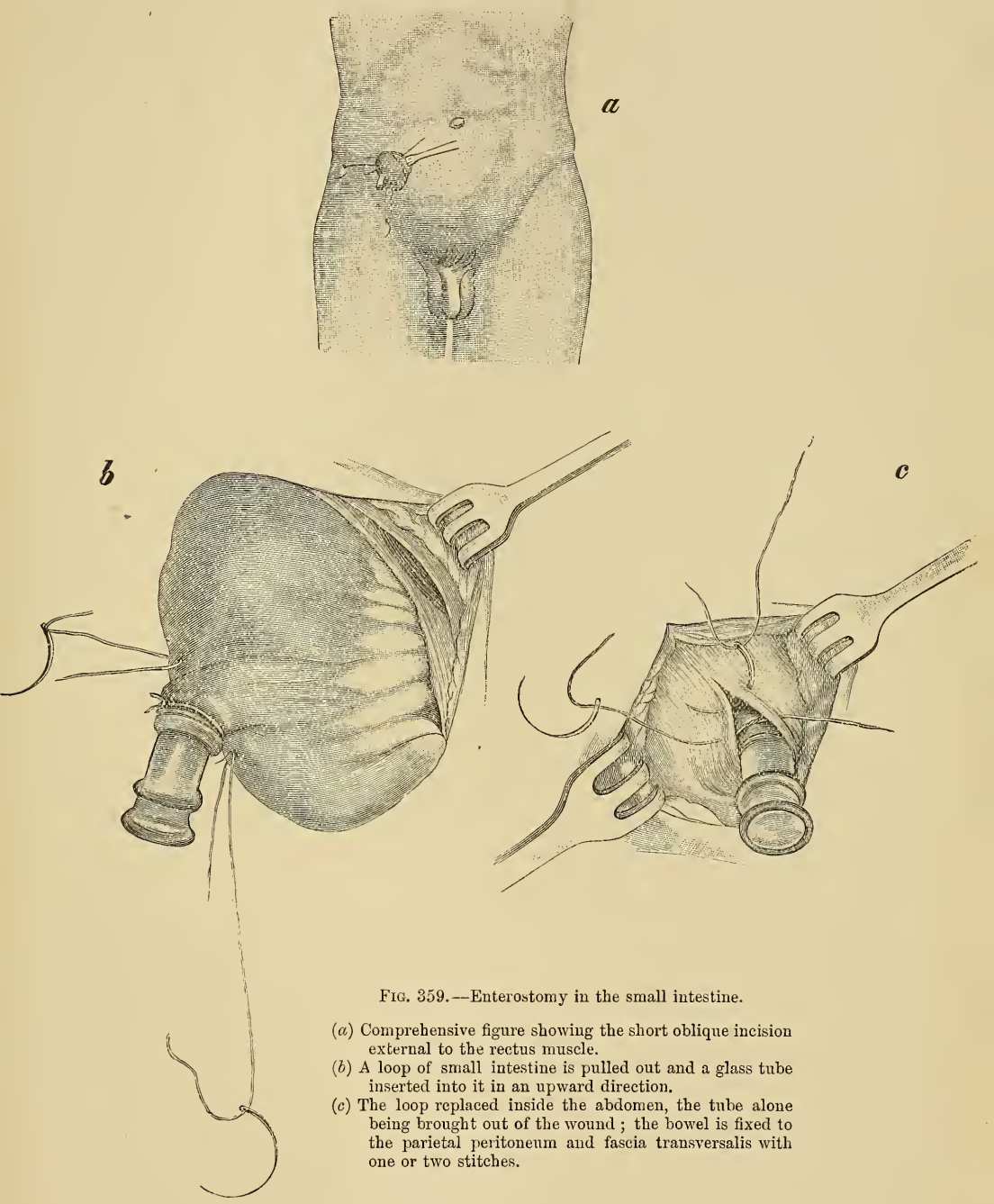

Fig. 359.—Enterostomy in the small intestine.

(*a*) Comprehensive figure showing the short oblique incision external to the rectus muscle.
(*b*) A loop of small intestine is pulled out and a glass tube inserted into it in an upward direction.
(*c*) The loop replaced inside the abdomen, the tube alone being brought out of the wound; the bowel is fixed to the parietal peritoneum and fascia transversalis with one or two stitches.

pancreatic secretion is led away from the wound with certainty, the advantages of duodenostomy have disappeared. The description of the technique of duodenostomy can therefore be omitted.

146. Jejunostomy. Jejunostomy may be employed in cases of inoperable pyloric obstruction in which owing to the extent of the disease gastroenterostomy cannot be performed. It is also indicated in diffuse inoperable carcinoma of the stomach, carcinoma of the cardia, in the case of a shrunken stomach, and as a preliminary to an extensive resection.[1]

Its object is to permit of the ingestion of food and to v. Eiselsberg belongs the credit for its introduction. The operation has been materially improved since Maydl introduced his Y-method based on Roux's pattern of gastro-enterostomy, and by Mayo Robson's short-circuit method analogous to Braun's method of gastroenterostomy.

Tavel's method of jejuno-gastrostomy marks a real advance, for by implanting the intestine properly with its oral end in the abdominal wall there is absolutely no danger of escape of intestinal contents nor of the permanent fistula becoming obnoxious to the patient.

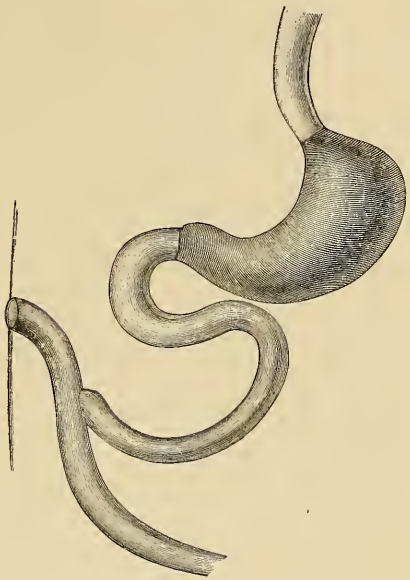

FIG. 360.—Sketch illustrating Maydl's Y-jejunostomy for the treatment of diffuse inoperable carcinoma of the stomach.

The intestine can be fixed in the abdominal wall so that a large opening is obtained through which the patient may be fed, without the least leakage, beyond a little intestinal mucus, provided the oral end of the divided jejunum is fixed in the abdominal wall and the anal end let into the gut 4 to 6 inches below the enterostomy opening, as indicated in Fig. 360.

The technique is as follows:—An incision is made to the left of the umbilicus, the skin and sheath of the rectus are divided, the muscle is displaced, and the peritoneum opened. The commencement of the jejunum is identified, and the intestine divided 8 to 10 inches lower between two crushing-forceps in the manner described in resection of the bowel.

The mesentery is then divided and the upper end of the gut implanted into the intestine 4 to 6 inches lower down as in gastroenterostomy by the Y-method.

The lower end of the gut is next pulled out through a special opening in the peritoneum and the rectus muscle, and stitched to the skin with sutures which include the whole thickness of its wall. The opening in the peritoneum and fascia need not be so small as to constrict the gut, as the muscle fibres are sufficient to keep the opening closed, no special contrivance being required for the purpose as the direction of the peristalsis prevents any escape.

Instead of using the Y-method, Mayo Robson short-circuits the loop of jejunum with a lateral anastomosis. Experience will show whether this application of entero-anastomosis (which in any case must not be made too small) affords sufficient security against leakage of bile and pancreatic juice. *Mutatis mutandis*, the technique corresponds to that described for Braun's anastomosis (see Gastroenterostomy with entero-anastomosis).

Except when there is a prospect of being able to close the jejunal fistula later on, there is no object in making a lateral opening, either by the method described in temporary enterostomy (using Paul or Mixter's tube), or by Witzel's method (oblique fistula), or by invagination according to Kelling's plan.

[1] For this preliminary operation proposed by Cackorie *vide* Friedrich's Diss., Kiel, 1904.

In contrast to the relatively small opening provided by the lateral operation, the "lip-like" fistula obtained by the other method has the advantage that it is large enough to allow the patient to feed himself in comfort with a large tube after he has chewed the food, as Trendelenburg advises in the case of gastrostomy.

147. Colostomy. Colostomy is almost exclusively employed in order to provide escape for the intestinal contents above an obstruction, and consists in the formation of an artificial anus. The conditions in which one may be called upon to open the intestine differ greatly, and their bearing on the technique of the operation has not received sufficient attention, *e.g.* whether the bowel is opened and stitched to the abdominal wall for the purpose of administering food, or in order to provide an outlet for the fæces.[1]

In the former case the essential feature consists in suturing the oral end of the divided bowel, *i.e.* the upper end of the efferent or lower portion to the skin. The risk of the wound becoming contaminated is thus very slight owing to the downward peristalsis of the bowel, and beyond a little mucus nothing escapes. But on the other hand, when the object is to get rid of the contents of the intestine, exactly the opposite has to be done, and the anal end, *i.e.* the lower end of the afferent or upper portion, is brought up into the wound, while every care must be taken to prevent soiling.

In making an artificial anus (and a fæcal fistula) the treatment of the lower portion of the bowel is of no great importance as the contents of this portion are automatically kept back in the intestine and carried away from the wound. But it is a different matter when the oral end of the lower portion of gut is sutured in the wound to provide for artificial feeding, as here one has to convey the contents of the upper portion away from the wound into the gut lower down.

The trouble always arises from the afferent gut, rarely, if at all, from the efferent, so that the first consideration is always how to keep the intestinal contents away from the wound. As shown for jejunostomy, this can be satisfactorily done by Braun's lateral anastomosis, or by draining the upper gut into the lower by Roux's Y-method, in all cases where the bowel below is free or can be made free by the removal of a tumour or stenosis.

These two methods are applicable to the colon also when colostomy is undertaken for operable cancer of the large intestine. Painful experience, however, has taught surgeons that there is a difference in the application of these methods to the large and small intestines. The contents of the large intestine accumulate much more readily above an obstruction and cause damage to the wall of the bowel, and are also incomparably more septic than the contents of the small intestine, hence complications can only be prevented by taking the utmost care to provide free escape. We shall return to this difference again in the chapter on intestinal resection, and proceed to the precautionary measures to be taken in simple colostomy.

There is another difference between simple colostomy, *i.e.* an artificial anus, and the formation of a fæcal fistula in the small intestine. The latter is generally only a temporary measure, and one has to consider how it is to be closed when no longer required. In opening the large intestine, on the other hand, one is often dealing with the formation of a permanent fistula, and here our efforts must be directed towards providing a competent sphincter which will keep the opening closed and prevent a continuous escape of intestinal contents.

Technique of Colostomy.—In describing the operation we shall not consider any half measures in making either a permanent or temporary artificial anus (the latter, for instance, as a preliminary to excision of the rectum). We regard as half measures all methods in which intestinal contents can pass down into the lower portion of gut, as in the event of an operation being undertaken on the lower portion of bowel subsequently requiring the introduction of sutures, the stitches are in danger of

[1] In the former edition we tried to point out this difference even by the nomenclature, since we suggested the termination -stomy; for instance, that the term "cæcostomy" be retained for cases where the cæcum is opened in colitis for the injection of fluids and therapeutic agents, and that the term "coloprocty" be used when it is intended to drain the contents of the colon.

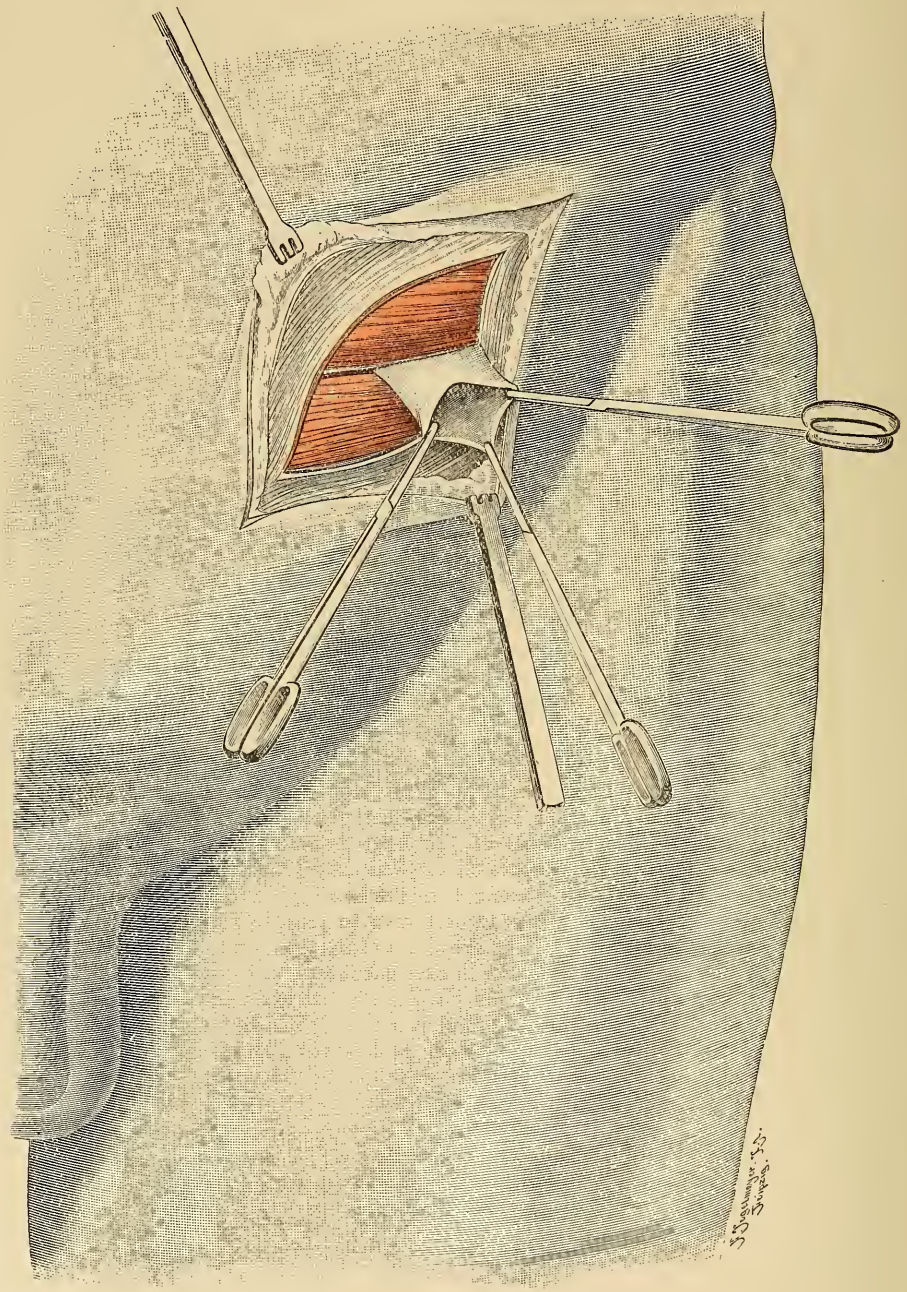

FIG. 361.—Formation of a temporary artificial anus in the left iliac region; skin, superficial fascia, and fascia musc. obliqui externi are divided in an oblique direction, the deep abdominal muscles (obliquus internus in figure) are only separated. The parietal peritoneum has been drawn out between the deeper abdominal muscles and opened.

becoming infected from contact with the intestinal contents, and unless the fæces are entirely kept away ulcers situated lower down do not get a chance of healing. A lateral opening is only to be made when a loop cannot be pulled out, as happens in the case of the cæcum (cæcotomy), and when the pelvic colon is firmly bound down by adhesions. Mosetig[1] has devised an operation in which a valve is formed below the opening, which deserves consideration on account of its simplicity. He ties a ligature lightly round the intestine and stitches the projecting walls above and below

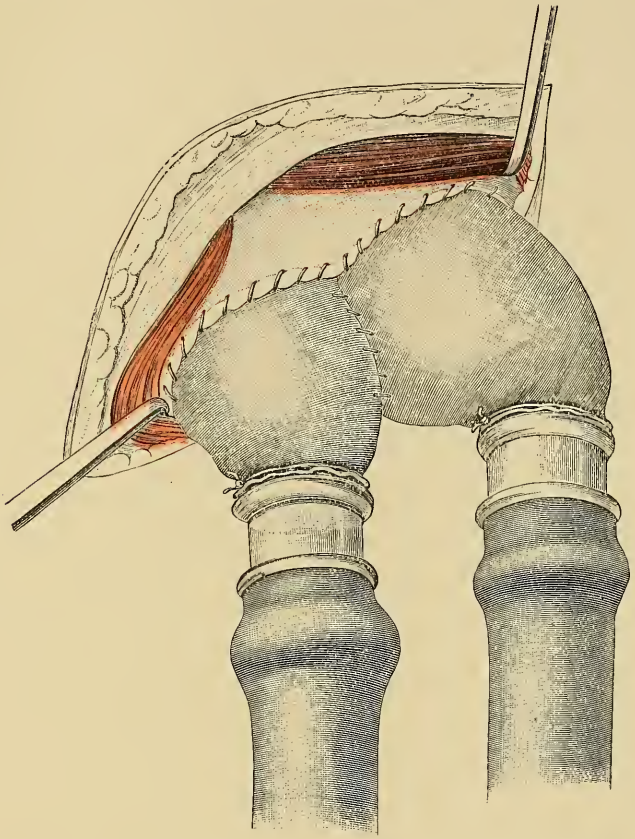

FIG. 362.—Enterostomy. Formation of artificial anus in the pelvic colon (Moynihan). The parietal peritoneum and fascia transversalis are stitched to the bowel with sero-muscular stitches. Two glass tubes are tied into the bowel.

this to one another, thus forming a diaphragm which, according to experiments by Silbermark and Domeny, remains permanent.

Lateral colostomy requires no special description. A circular area of the wall of the bowel is stitched to the peritoneum and fascia with sutures which include the serous and muscular coats. Before the bowel is opened, it is better to wait for one or two days. After it is opened the edges are fixed to the skin with 4 to 6 sutures which include the whole thickness of the bowel wall (*vide* Technique of Jejunostomy).

The routine operation of colostomy is performed as follows:—Local anæsthesia with novocain and adrenalin. An incision is made through the skin, fascia, and aponeurosis of the external oblique two fingers'-breadth above Poupart's ligament,

[1] Cf. Silbermark and Domeny, *Deutsche Zeitschrift f. Chir.* Bd. 78.

and the same distance internal to the anterior superior iliac spine. The internal oblique and transversalis are split with two blunt dissectors and held apart with suitable retractors, the fascia transversalis and peritoneum are incised for a distance of about 2 inches, and the pelvic colon, which is readily found in the iliac fossa, is brought out of the wound. If it cannot be pulled out owing to its mesentery being short, it may be mobilised by dividing the peritoneum and avoiding the vessels. It is then stitched to the parietal peritoneum and transversalis fascia, the stitches being passed through its serous and muscular coats.

If it is proposed to excise the bowel lower down at a later operation, the portion brought out should be as high up as possible, *i.e.* near the descending colon, so that the mobility of the bowel below may not be interfered with. But when there is no radical operation in view at a later stage, or if the whole portion below the opening is to be removed, then the loop stitched to the abdominal wall should be as low down as possible.

After the bowel has been emptied between the fingers the mesentery of the pelvic loop is put on the stretch and a small slit is made in an interval between the vessels, through which a strip of iodoform gauze is pulled and tied round both limbs of the loop, the upper end being loosely tied while that on the lower end is pulled tight. Below this a clamp is applied. The convexity of the loop is then grasped with a pair of crushing-forceps which include the bowel as far as the mesentery, and a Paul's tube is inserted through an opening in the summit of the constricted loop and tied in, so as to prevent escape alongside it. The crushing-forceps are then removed, and round the groove left in the descending limb a ligature is passed and firmly tied. A second ligature is also passed round the groove on the upper portion of intestine and is tied round the glass tube after the latter has been pushed farther into the bowel.

In this way the intestine is closed above and below the tube. The convexity of the loop is now cut away (after packing all round with gauze wrung out of lysol), as much of the mucous membrane being excised as possible while the rest is disinfected with alcohol. A rubber tube is attached to the glass tube and the contents of the bowel are led away. The tube round which the gauze loop is tied prevents retraction of the gut till adhesions are formed.

No harm results if the ligature on the lower end comes off in a day or two, owing to accumulation of fæces, as irrigation with a double tube will soon remove it. One should, however, make sure beforehand if there is any risk of infectious material collecting in the lower portion of gut. It is only interruption of the downward flow which can hinder the spontaneous action of the peristaltic movements, otherwise this is quite sufficient to prevent any leakage from the lower portion of the gut into the wound, with the exception of some harmless mucus.

When accumulation of fæces in the lower portion of gut cannot be prevented, it is advisable to tie a glass tube into it as well, instead of closing it. The use of two glass tubes does away with the necessity of completing the operation in two stages. This, however, is highly desirable when a lateral opening is made in the gut, since in this case it is very difficult to prevent the wound from being soiled.

By bringing out the bowel between the fibres of muscle an amount of control over the opening is obtained. Witzel brings the rectum through the gluteal muscle, and v. Hacker, as already mentioned in connection with jejunostomy, utilises the rectus for the purpose. Hoffman drew attention to the fact that by making the track obliquely through the abdominal wall a colotomy opening is effectively kept closed. He brings the gut out through the abdominal wall at a little distance from the wound.

When the bowel is brought out through the abdominal muscles in the manner we have advised the opening is sufficiently controlled and phlegmonous cellulitis of the wound is prevented. As the muscle fibres are simply separated without interfering with its nerve-supply, they contract sufficiently closely round the gut to keep the opening shut. More secure closure may be effected by a pad and spring, which can easily be obtained with a properly-fitting belt.

148. Appendicostomy. It is not uncommon to find after perityphlitis that a fistula persists which will not close spontaneously, and which is peculiar in that one

can pass a long probe down it into the bowel without any fæcal escape beyond a very little slightly purulent mucus. These fistulæ have been proved by operation to be due to a perforation of the vermiform process when the latter was adherent to the abdominal wall—in other words, spontaneous appendicostomy had been performed.

It follows, therefore, that if the appendix is opened artificially and sutured into the abdominal wall, considerable advantages are presented over cæcostomy. Weir[1] first suggested appendicostomy. No escape of intestinal contents takes place through the fistula, because the strong peristalsis is directed towards the bowel; but by inserting a tube gas can be allowed to escape, or fluids can be injected either for the purpose of nourishment or as medical agents for the treatment of affections of the large intestine.

Appendicostomy has been suggested as a substitute for cæcostomy, especially in the treatment of ulcerative or membranous colitis. It is, of course, essential that the appendix itself is not diseased, and that it is long enough and sufficiently free to allow of its tip being fixed in the abdominal wall. It is then cut across and the edges stitched to the skin. It is an operation free from danger, provided the appendix retains its peristaltic function. When it cannot be performed, recourse must be had to lateral cæcostomy.

149. Entero-anastomosis and Intestinal Occlusion. One of the most important operations in intestinal surgery, and one which has even a more extensive field of usefulness than Wölfler's gastroenterostomy, consists in uniting two portions of intestine so that the contents of the upper will empty into the lower without passing through the intermediate or short-circuited loop. Wölfler is responsible for its development and use, although the idea had already been suggested by Maisonneuve. According to Haberer[2] Billroth performed the operation first, and v. Hacker had the first successful case.

Although to a certain extent a portion of bowel is always functionally isolated in every anastomosis, the term "occlusion" is used in a limited sense to imply that the intermediate portion is completely shut out, one or both ends opening on the surface so that it is no longer connected with the ordinary circulation of fæces.

According to Haberer, Senn first suggested unilateral, and Salzer total isolation of bowel, while Hochenegg first performed the operation successfully. According to Hartmann, on the other hand, Trendelenburg had the first case.

For the sake of precision we speak also of total occlusion. The difference is an important one. When the gut is not isolated in the stricter sense of the term, we are dealing merely with a lateral or side-to-side anastomosis. But when, on the contrary, occlusion is performed, we mean that the intestine above and below is united either laterally after closing both ends, or directly by end-to-end anastomosis, or that only one end is closed while the other is utilised for an end-to-side anastomosis.

The anastomosis between the ileum and colon is the one most commonly performed. v. Eiselsberg, who has had the greatest experience, employed lateral anastomosis for this purpose in 40 out of 52 cases with 13 deaths. Lateral anastomosis is the simplest method of putting a diseased portion of intestine at rest, and we have found that in very extensive tuberculosis of the cæcum and large intestine, a complete cure can be got without real isolation. We were able to prove the truth of this positively in a case where a subsequent laparotomy was found necessary.

We therefore regard lateral anastomosis of healthy intestine above and below the disease as an excellent operation in cases of tuberculosis of the bowel, where removal of the diseased portion is difficult and dangerous. It is also of great use in inoperable carcinoma, particularly in the neighbourhood of the cæcum, the hepatic or splenic flexures. The patients may recover their working capacity for months or years. But, as we shall show later, unexpected radical cures may be obtained by resection even when the disease is very wide-spread, so that one must always attempt to perform this operation. Lateral anastomosis is also of value in cases of stenosis due to other

[1] *Vide* M. Gil, *Revista di med. pract.*, Madrid, 1906.
[2] Haberer, *Archiv f. klin. Chir.* Bd. 72.

causes, *e.g.* syphilitic or inflammatory. When there is acute obstruction and a large accumulation of fæces above the obstruction, it is essential to empty the bowel by enterotomy before making the anastomosis. In cases also where the function of the intestine is impaired by peritonitis, it is occasionally possible to anastomose a contractile portion of intestine above directly with the colon. Friedrich[1] successfully short-circuited 13 feet of small intestine.

In cases of ileus, where the patient is in a very poor general condition at the time of operation, anastomosis is a very important preliminary or introductory to a later radical operation, especially in malignant cases where an acute ileus may often be the first indication of the trouble.

Anastomosis with total occlusion of the bowel may further be undertaken in the treatment of intestinal fistulæ—more especially pyo-stercoraceous fistulæ where excision cannot be employed. The principal disadvantage of total isolation in contrast to simple lateral anastomosis, is the necessity for an artificial opening in the isolated portion of the bowel. Complete closure of both ends of the isolated portion has been found inadmissible in pathological cases. Not only are external fistulæ cured in this way, but also those opening into the bladder or vagina.

Intestinal isolation is again indicated in obstinate cases of colitis, and in idiopathic dilatation of the large intestine with obstipation and congenital hypertrophy of the colon. The operation by choice is here ileo-sigmoid anastomosis, between the lower ileum (about 12 to 20 ins. above the ileo-cæcal valve) and the pelvic colon. v. Beck has had excellent results in five cases of diffuse colitis by short-circuiting the whole of the colon "as a more or less rudimentary structure, which is of no great significance for the nourishment of the patient."

Lastly, the isolation of healthy gut has been undertaken in order to replace other hollow viscera, *e.g.* the bladder in extroversion, the intestine after extensive removal of very fixed portions (in the large intestine and rectum) and also the stomach. It has also been employed to establish a communication between the stomach and the abdominal wall (Tavel's jejunogastrostomy) and even to replace the œsophagus (Roux).

150. Technique of Lateral Anastomosis. The diagram of Braun's entero-anastomosis in the section on gastroenterostomy (p. 576) may serve as the type of the method of procedure. Certain rules, however, must be observed in the performance of an anastomosis:

(1) There must be no strain on the intestine entering into the anastomosis. The most movable portions should also be selected. In the small intestine, this corresponds to the lower ileum, at a little distance from the cæcum. Immediately above the ileo-cæcal junction the mesentery is shorter. In the large intestine the transverse and the pelvic colon have the longest mesentery and are less likely to be stretched.

(2) Though not essential, it is desirable that the bowel should occupy an isoperistaltic position, but an antiperistaltic position is possible. The bowel must not be twisted.

(3) Very congested or over-distended portions of the intestine must not be joined without a previous enterotomy, or, as in the large intestine, without an enterostomy having been performed some time previously above the proposed site of the sutures.

The operation is performed as follows:—The selected portions of gut are emptied, approximated in an isoperistaltic position, and clamped. The posterior serous suture should be about 2 inches long, and the incision into the gut about $1\frac{1}{2}$ inches long and $\frac{1}{5}$ inch from the suture, after which the edges are united all round with a continuous suture including the whole thickness of the intestinal wall. Before inserting the anterior serous suture the clamps are taken off, the parts cleansed with lysol, and fresh packing inserted.

Mechanical contrivances such as Murphy's button, and the modifications used by Jaboulay and v. Beule, Senn's absorbable bone plates and similar plates used by Baracz, Landerer, and Alessandri are all inferior to suture. They are less reliable and do not give so rapid or perfect a result. The same applies to the use of M'Graw's

[1] *Med. Klinik*, 1905, No. 2.

elastic ligature,[1] which, although it is simple and easy to apply (as we mentioned under gastroenterostomy), is apt to be followed by contraction of the opening.

151. Entero-anastomosis with Unilateral or Bilateral Occlusion of the Gut. At the sixteenth French Congress of Surgery (Paris, 1903), H. Hartmann gave a very complete description of the various methods in which short-circuiting may be performed. His diagrams, which we reproduce here, need no further description.

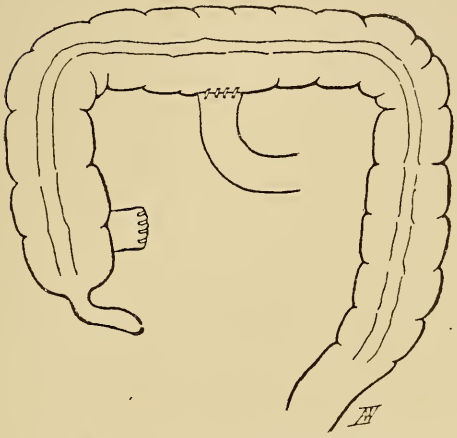

FIG. 363.—Unilateral occlusion with end-to-end anastomosis.

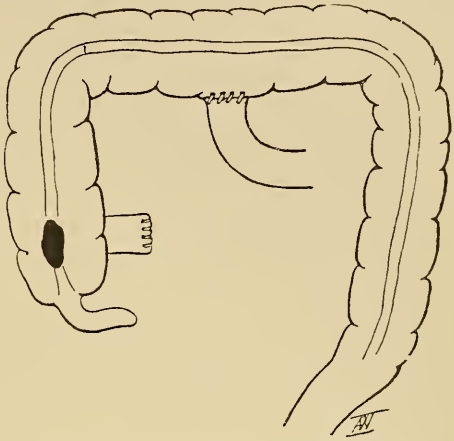

FIG. 364.—Same as Fig. 363, but with formation of fæcal fistula in the occluded bowel.

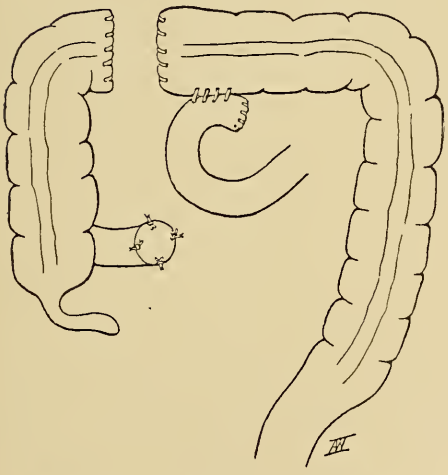

FIG. 365.—Unilateral occlusion with lateral anastomosis and enterostomy of the occluded bowel.

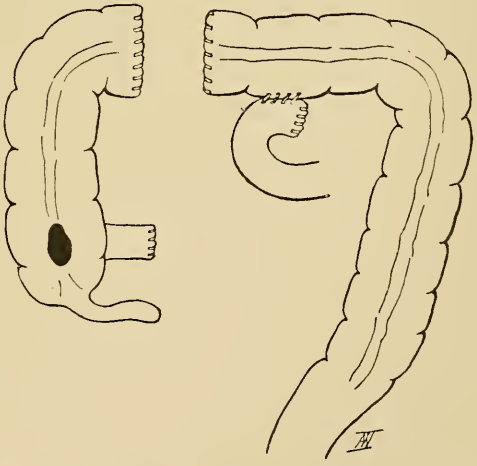

FIG. 366.—Same as 365, but with formation of fæcal fistula.

Hartmann very properly points out that the term "intestinal occlusion" should only be used when the continuity of the gut is broken by division in one or two places.

Technique.—As a rule the abdomen is opened in the middle line, but occasionally an oblique lateral incision is more suitable. In selecting the portions of intestine for

[1] *Journ. of Michigan State Soc.*, Aug. 1904.

the anastomosis, great care must be taken to ascertain that the one segment is above and the other below the obstruction. If there is any doubt, then a lateral anastomosis only may be made.

The gut above the obstruction is clamped with two pairs of crushing-forceps, placed

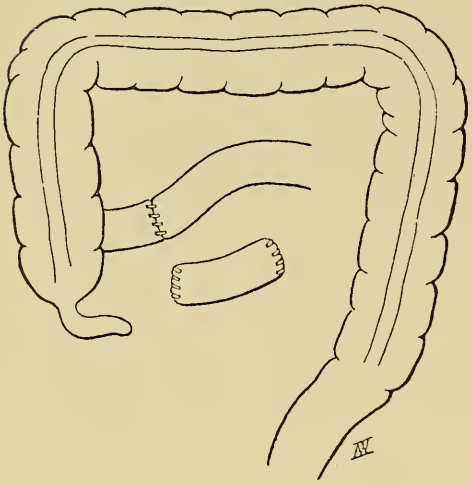

Fig. 367.—Bilateral occlusion with end-to-end anastomosis. Closure of occluded bowel.

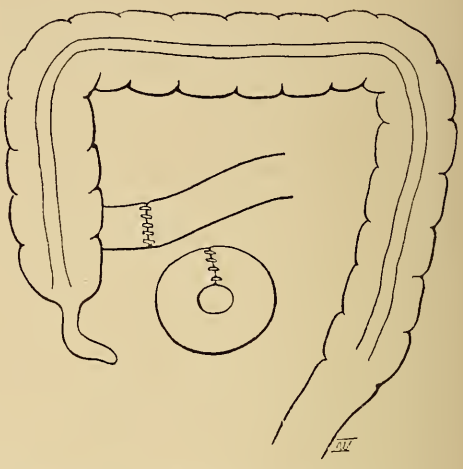

Fig. 368.—Same as Fig. 367. A different method, however, of closing the occluded bowel.

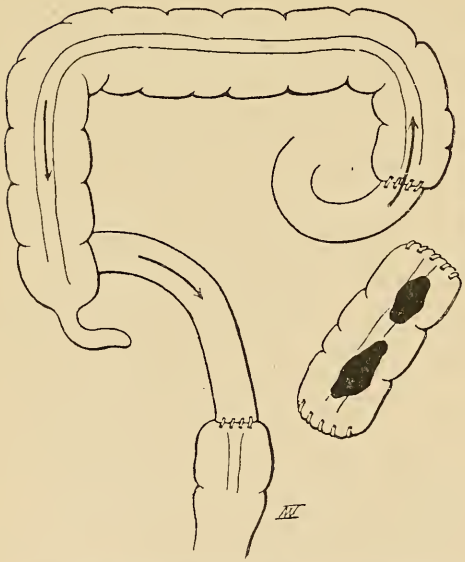

Fig. 369.—Bilateral occlusion, reversed end-to-end anastomosis, formation of fæcal fistulæ in occluded bowel.

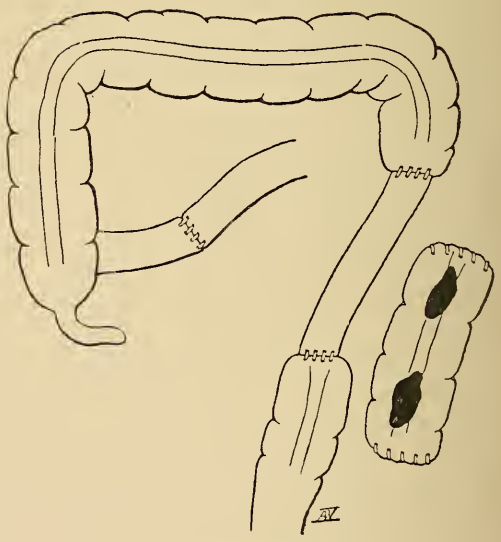

Fig. 370.—Bilateral exclusion as in Fig. 369. Continuity restored by enteroplasty.

about an inch and a half apart and is cut across (see Section 153). The forceps on the upper end are left on, while those on the lower end are taken off and the crushed portion of bowel is tied with a silk ligature. The division of the bowel should be flush with the forceps on the upper end. The ligatured stump is pulled out, and the mucous

membrane cauterized and invaginated with two rows of sero-muscular sutures, after which the stump is dropped back into the abdomen.

When the obstruction is complete, the end of the gut should not be closed, but should be brought out through a special opening in the abdominal wall (Fig. 365), at a distance from the main incision, and stitched there as described under enterostomy (see p. 613). The upper end of the gut, which is still closed with the forceps, is then inserted directly into the bowel below the obstruction. The forceps are useful in bringing the parts into apposition. In the large intestine a longitudinal band is to be selected. Fig. 363 illustrates the method of unilateral isolation with end-to-side anastomosis.

In this normal process the contents of the isolated portion are carried down by the peristalsis, without requiring the formation of an external fistula. The theoretical fear that the isolated portion becomes filled from below by a back flow of intestinal contents is groundless, provided the outlet downwards is free. It is therefore wrong to divide the gut below the isolated loop and close up both ends (Fig. 365), merely to be able to make a lateral anastomosis lower down.

Salzer's total isolation (Figs. 365 and 366) is only indicated in cases where much accumulation is anticipated in the occluded portion from discharge from the ulcer or backward pressure of fæces from the lower portion of the gut. According to Hartmann, Lance has demonstrated a backward intestinal flow in nine out of fifteen cases where unilateral exclusion was practised. Hochenegg and Eiselsberg maintain that both ends of the excluded portion should be brought to the surface so that it may be irrigated and kept clean. Hartmann knows of only two cases (Wiesinger's and Kammerer's) where occlusion of the isolated portion led to cure, and then only after fistulæ had formed and continued for some time.

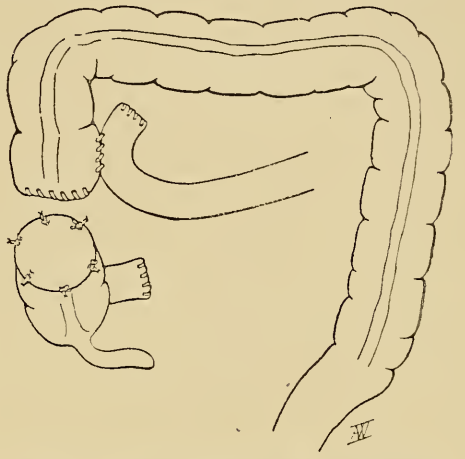

FIG. 371.—Bilateral occlusion, side-to-side anastomosis, formation of artificial anus in occluded bowel.

In very difficult cases where the large intestine above the obstruction is too distended to permit of its being implanted lower down, one may occasionally attempt a recurrent anastomosis (Fig. 369), *i.e.* cut across the ileum and insert its proximal end into the colon above the obstruction, and the distal end into the pelvic colon, the fæces thus passing, by way of a portion of ileum, from the large intestine into the rectum. Or one may interpose a piece of ileum between the two ends of the large intestine by an enteroplastic operation (Fig. 370).

In occlusion, as in resection of gut, it is important not to leave any openings or bridges in the mesentery. The divided edges of the mesentery should in every case be stitched either to mesentery or to omentum, so as to obliterate any opening through which internal strangulation might occur.

152. Intestinal Resection.—*General Remarks.* In considering the indications, methods, and prognosis of intestinal resection, we shall deal with the different portions of the intestine separately. Statements which hold good for resection of small intestine, apply only slightly to resection of the ileocæcal region, and not at all to resection of the large intestine. Resection of the small intestine, ileocæcal region, and large intestine must be considered separately, as there is little that is common to all these forms.

Resection of the intestine has become an exceedingly important and comparatively frequent surgical operation, and by its proper performance the surgeon is able to

preserve many lives which would be otherwise lost. It is absolutely necessary that, besides attending to the obvious necessity for asepsis, the definite steps in the technique of the operation must be adhered to.

By observing these rules large portions of the bowel may be removed. We have performed a considerable number of very extensive intestinal resections, the most extensive being the removal of 7 feet of small intestine, and in another case $5\frac{1}{2}$ feet. Both patients made an uninterrupted recovery.

In Maydl's clinic, Kukula has recorded two cases of resection of more than $6\frac{1}{2}$ feet of intestine, and has drawn attention to experiments by Monari and Trzebicky in which as much as seven-eighths of the small intestine was removed from animals without injury. Kukula believes that as much as half of the human small

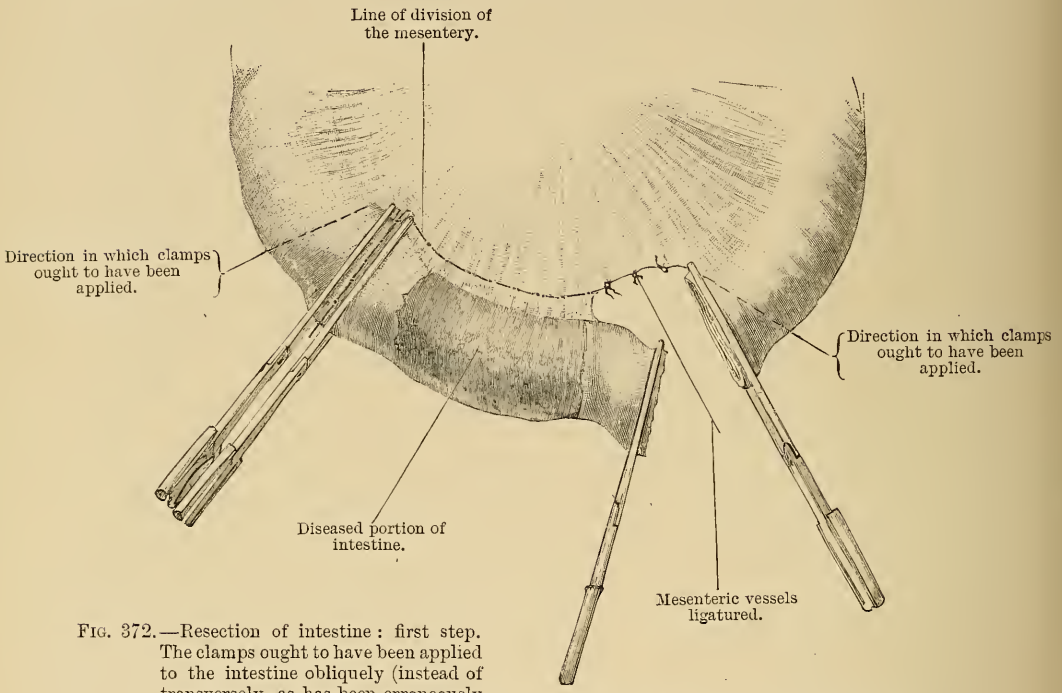

FIG. 372.—Resection of intestine: first step. The clamps ought to have been applied to the intestine obliquely (instead of transversely, as has been erroneously indicated) to ensure a good blood-supply. The intestine has been cut across between two of the forceps, and between the other two the line of section is indicated by an interrupted line. The line of division of the mesentery is shown, part of it having been divided and its vessels ligatured.

intestine may be removed without doing harm, and of the large intestine as much as may be desired. Roux reports the case of a patient who survived with a small intestine only 5 feet long, and with only half the length of the large intestine.

R. Park[1] has published a case in which he successfully removed 9 feet of small intestine, and records twelve recoveries in sixteen cases, one over 6 feet, a second over 9 feet, and a third over 10 feet. According to Schlatter[2] after such extensive resections the diet has to be very carefully selected on account of the great loss of albumen and fat.

It is important to know that such very extensive resections can be performed without harm and with uninterrupted recovery, because the first rule in intestinal as in stomach resections is this: *only to suture together wound edges which are thoroughly well nourished.* Before the sutures are introduced one must be absolutely

[1] *Arch. internat. de chir.* t. 1. [2] *Beitr. z. klin. Chir.* Bd. 49.

certain that plenty of blood is flowing to and from the mesentery at the ends of the intestine which are to be united.

The best and only sure method of ascertaining this is to examine the pulsation in the arteries: the only certain test of a satisfactory blood-supply in the uninjured gut is the presence in the arteries of pulsation, which can be felt right up to the intestine itself. In the case of collapsed patients, however, the pulsation is not always easily felt. If there be any doubt another piece of gut should be resected before the parts are sutured together.

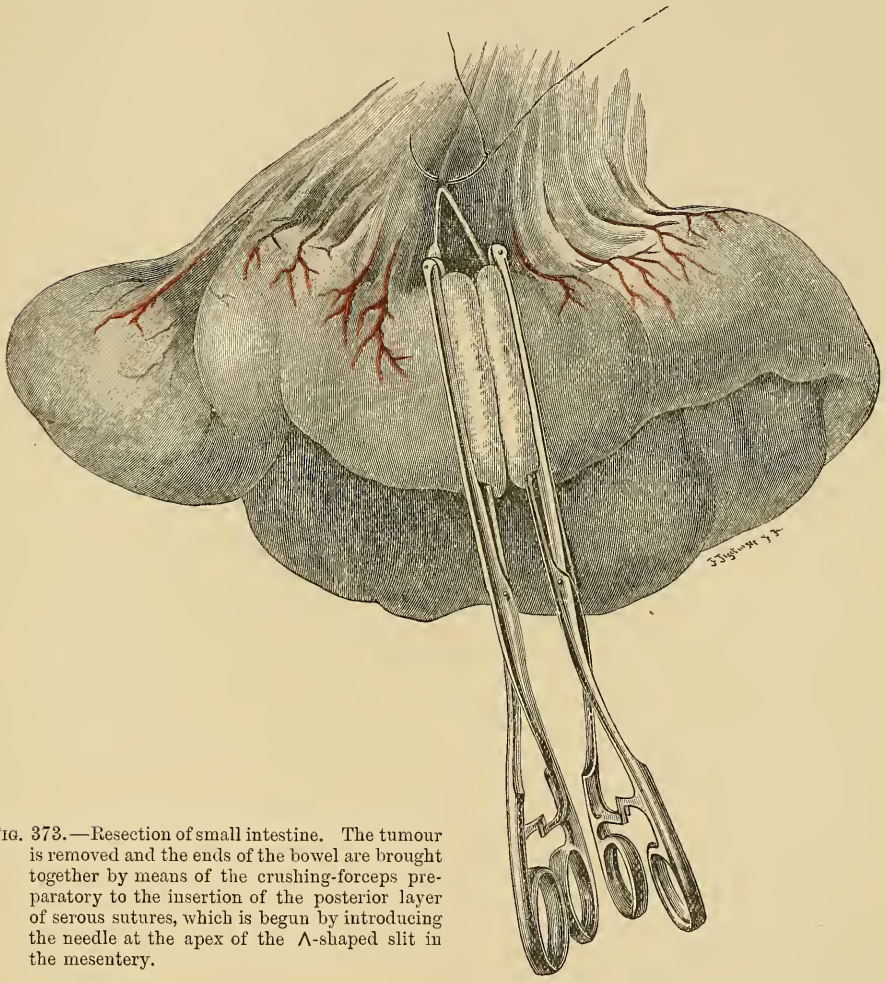

FIG. 373.—Resection of small intestine. The tumour is removed and the ends of the bowel are brought together by means of the crushing-forceps preparatory to the insertion of the posterior layer of serous sutures, which is begun by introducing the needle at the apex of the Λ-shaped slit in the mesentery.

153. Resection of Small Intestine. Resection of the small intestine is now so safe an operation, provided the technique is good, that one has no hesitation—*e.g.* in gangrenous hernia—in aiming at primary union and restoring the continuity of the bowel by suture immediately after removal of the gangrenous portion. It is only in cases where the patient is in a state of extreme collapse that an exception to this rule is made.

The following points must be attended to, if the operation is to be successful:—

1. The piece of intestine to be resected is to be drawn well out of the abdominal cavity, so that the operation may be performed extra-peritoneally and leisurely. The

loop of intestine which is pulled out is shut off from the peritoneal cavity by aseptic tampons.

2. Two crushing-forceps are applied close together to the part of the intestine where the section is to be made (Fig. 372), a part being chosen where the wound edges will be well nourished. These forceps are not to be applied exactly at right angles to the long axis of the intestine (as has been erroneously represented in Fig. 372), but somewhat obliquely, as indicated by the dotted line in the same figure, so that more intestine is removed from the convexity than from the mesenteric side. The transverse vessels which run towards the convexity are thus more likely to escape injury, up to the point of division.

3. The intestine is cut through between the forceps, and the cut surfaces are carefully mopped with moist lysol swabs (1 per cent) and alcohol. The mesentery (transverse or pelvic colon) is then divided *along its attachment to the part of the intestine to be removed*, the vessels being seized, one after another, with artery-forceps. The intervening piece of intestine with forceps on each end is thus removed.

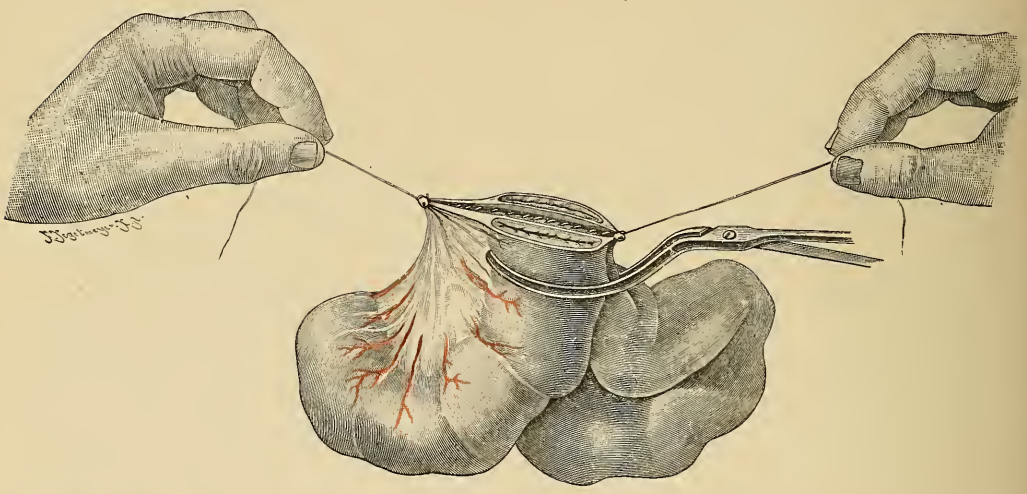

Fig. 374.—Resection of small intestine. After the insertion of the posterior layer of serous sutures the crushing-forceps are removed and an intestinal clamp applied. The ends of the posterior serous sutures are held on the stretch, so that after thorough disinfection of the bowel the deep circular continuous suture (through all the layers) may be inserted.

4. The intestine is then sutured, the crushing-forceps being used as handles by which the posterior serous surfaces are brought in apposition for the insertion of a continuous silk suture (*vide* Fig. 373). An intestinal clamp is then applied as is shown in Fig. 374, and the crushing-forceps are removed, after cleansing the divided ends with small gauze swabs and carefully protecting against soiling. The edges are then stitched all round and invaginated with a continuous suture taking up the whole thickness of the walls. The ends of the first loop having been knotted, the one is left long enough to tie with, while the other, to which the needle is attached, is used to bring the edges of the gut into uninterrupted and firm contact by means of a simple continuous glover's suture carried right round the circumference to the starting-point, where it is knotted with the end which has been left long. The intestine is thus firmly and securely closed. The line of suture is cleansed with lysol swabs, any ragged mucous membrane is removed, and the protruded intestine washed with warm sterilised salt solution, while the surrounding cloths shut off the peritoneal cavity.

5. The cloths are now changed and the anterior serous suture is inserted with the finest possible needle, and fine but strong silk. The suture penetrates only the

serous and a part of the muscular coats in such a way that the former are inverted and brought into broad position (Lembert suture). The double suture (indicated in longitudinal section in Fig. 375) was first described by Czerny, and then by us without knowing that he had employed it.

The first loop of the Lembert suture is knotted and then carried uninterruptedly right round the intestine, and knotted with the initial end which is left long. The line of suture is again disinfected with lysol, which is then washed off by a warm sterilised salt solution. The towels having been removed, the intestine is replaced in the abdomen, the edges of the wound being raised up forcibly by hooks, and care taken not to use any force. The abdominal wall is closed with a double row of sutures.

If the intestine is distended with flatus and fluid contents, it should be opened

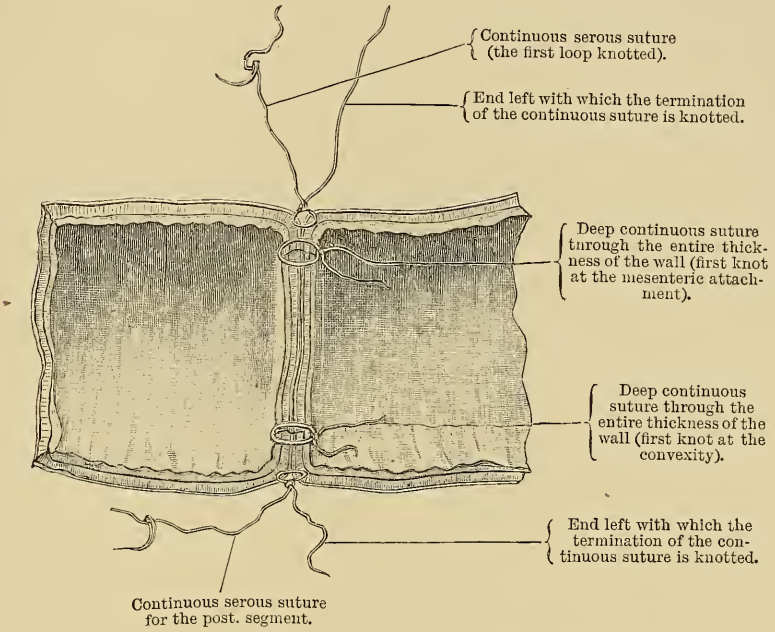

FIG. 375.—Intestinal suturing, to demonstrate the double row of sutures. The posterior half of the gut is cut longitudinally. The view is from within.

above the line of suture by a transverse incision 4 to 5 mm. in length, and the contents removed by pressure and allowed to flow into a small glass dish, after which the opening is stitched up. The part is again cleansed as above described and the reduction of the intestine effected.

We maintain that continuous sutures are alone permissible in enteroraphy, and fine silk is to be exclusively employed.

The circular method of suturing the gut is always safest, if the bowel can be brought out of the abdominal cavity. There is, then, no reason to substitute any other method in place of it. When, however, the circular suture cannot be inserted with absolute confidence because the parts are not fully exposed to view, some method of simplifying the procedure may be sought. The most valuable means we have of effecting this is by using a Murphy's button. Other methods, such as those described by Maundsell and recommended by Ullmann, are also reliable. In this method the upper end of the gut is invaginated, and the invaginated end is brought out through a lateral longitudinal incision higher up. The lower end is pushed

through the invaginated upper end so that both can be ligatured over a turnip bobbin and drawn back again.

With regard to suture of the intestine Chlumsky has made some very interesting experiments. He has shown that sutures give a much more efficient mechanical union than Murphy's button; and further, that the suture is more reliable on the first day and shortly after the operation than on the days immediately following. The firmness of the union only begins to increase again from the fifth day onwards, and reaches its original strength on the seventh day. He demonstrates that end-to-end anastomosis is firmer than lateral anastomosis. From these experiments it may be concluded that, as far as firmness of the line of suture is concerned, it is permissible to give a purgative on the first day, unless there be some definite contraindication present, such as suspected ulceration of the intestine. It is often desirable to be able to empty the gut at once. On the four next days much greater caution must be exercised.

Katzenstein has attempted to take advantage of the characteristic action of glutenkasein on the serous membrane in order to give greater firmness to the external sutures; such applications, however, unfortunately predispose to the formation of adhesions. A solution of Lugol has been used in Mikulicz's clinic for a similar purpose.

In cases in which the end-to-end method of uniting the gut cannot comfortably and safely be employed, it is often necessary to close one or both of the intestinal ends and to perform a lateral anastomosis.

The circular method of closing the intestine has been greatly simplified by Doyen. He applies a pair of crushing-forceps (after the principle described in resection of the stomach), removes the forceps, and ligatures the compressed part. A running purse-string suture is applied over this (the advantage of this has been pointed out by de Quervain and confirmed by Haegler) and the ligature invaginated. One or two rows of serous sutures are then introduced to still further unite the peritoneal surface. The further procedures are the same as under lateral entero-anastomosis above described.

We have recently got Dr. Fricker (in conjunction with Dr. Albert Kocher) to perform a series of experiments to demonstrate the advantage of extending Doyen's method to the operation of uniting two pieces of intestine end-to-end as well as to the operation of intestinal anastomosis. Compression-forceps are applied to the ends of the intestine, and a simple through and through "mattress suture" (with wire thread) is inserted behind the forceps, just as is done in resecting the stomach. The ends are not tied, but are held taut. By this means the gut is temporarily closed without the use of clamps, and by bringing together the threads used in closing it the two ends of the intestine can be brought into exact apposition, and continuous sutures can be put in as above described. The temporary "mattress sutures" are then simply drawn out and the continuous Lembert suture is introduced. By adopting this plan the escape of intestinal contents is prevented. The method is of use in cases where one cannot properly protect the surrounding parts from soiling with the contents of the intestine by simple removal of the compression-forceps and application of a clamp-forceps.

154. Ileo-cæcal Resection. End-to-end suture of the small intestine is a very safe operation, but occasionally in the case of a stricture it may be difficult, owing to the inequality in the size of the gut above and below. In anastomosing the small to the large intestine this difficulty is even more marked, and end-to-end anastomosis is only possible when the lumen of the ileum has become chronically enlarged above an obstruction while there is contraction of the colon below it.

In all other cases the principle laid down for resection of the stomach must be followed. The bowel with the larger lumen must be closed with occluding sutures and the smaller inserted into it laterally, *i.e.* in resecting the ileo-cæcal region the end of the small intestine is to be inserted into the large intestine by an end-to-side anastomosis.

The advantage of this procedure, which has been already proved in resection of the small intestine, is that the suturing is much easier when the bowel can be readily

reached and brought outside the abdomen. In ileo-cæcal resection, when much bowel is removed, it is better not to insert the ileum into the ascending colon but into the more movable transverse colon.[1]

It is quite unnecessary as a routine procedure to follow Friedrich's advice[2] and remove the whole of the ascending colon, including the hepatic flexure, and make the division through the transverse colon. We have often performed this ileo-transversostomy (a short but bad term) for one or other of the following indications, viz. (1) because a more secure anastomosis could be made with the transverse than seemed possible with the ascending colon, or (2) because we could not be sure that the colon up to its transverse portion was free of disease, or (3) to be able thoroughly to remove the glands lying in the mesocolon.

In tuberculous tumours of the ileo-cæcal region the excision of the ascending colon may be rendered difficult owing to the shrunken condition of the gut from pericolitis, but we have positive evidence that tuberculous affections of this sort can be cured by the simple process of short-circuiting (ileo-transversostomy). When one is dealing with a healthy ascending colon, by division of the peritoneum on its outer aspect it can be freed along with the hepatic flexure in a few minutes, after which the peritoneum is divided along the inner border of the colon, the vessels are secured, and the lumbar glands exposed. Friedrich has had three uneventful recoveries in four such cases. We regard Friedrich's communication as important, as it shows how readily the colon can, if necessary, be excised, and more especially its fixed portions, viz. the hepatic and splenic flexures. Apart from the fact that it ensures complete removal of the disease, the chief feature of Friedrich's operation consists in the implantation of the small into the large intestine, by which means the fluid contents of the narrow small intestine are conveyed into the wide large intestine. The anastomosis may either be an end-to-side or a lateral one (Roux).[3] Both are equally safe.

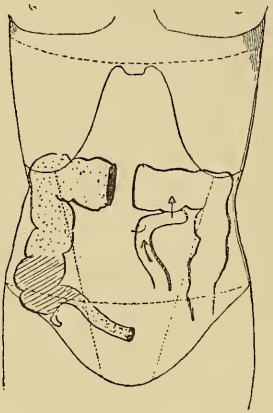

FIG. 376.—To illustrate the principle of resection of the colon for carcinoma of the ileo-cæcal region (after Friedrich).

Campiche, who has collected 202 cases of tuberculosis of the cæcum, shows that with end-to-side anastomosis there were 81 per cent of cures and with lateral anastomosis 88 per cent. This merely proves that, as in the case of the stomach, end-to-side anastomosis requires rather more practice, for with lateral anastomosis a larger incision can be made, and even if the sutures are not quite accurate, supporting sutures can be added and still leave a sufficiently wide opening of communication. In our opinion the former method is the simpler, and, provided the technique is good, it is quite as safe as lateral anastomosis.

It should be a rule that the operation is performed in one stage, not in two or three stages, as is required in other parts of the large intestine. Of Babes'[4] ten cases by the one-stage operation, all recovered. He rightly maintains, that the administration of the anæsthetic plays an important part, especially when the patient is debilitated as a result of ileus. He gives morphia $\frac{1}{4}$ gr., and makes the incision with local anæsthesia (we always use novocain and adrenalin) and only employs a short ether anæsthesia while opening the peritoneum. No anæsthetic is given during the separation or stitching of the intestine, and the anæsthesia is only resumed when the skin is being stitched.

Technique of Ileo-colic Resection.—An oblique incision, similar to that recommended in difficult cases of appendicitis, is made close to the outer border of the rectus, but

[1] Cf. also Scudder, *Boston Med. and Surg. Journal*, November 1904, where very good illustrations of this method are given.

[2] *Archives internat. de chir.* Gand, 1905.

[3] *Deutsche Zeitschr. f. Chir.* Bd. 80.

[4] Langenbeck's *Archiv*, Bd. 80.

without opening the rectus sheath, the centre of the incision being placed midway between the umbilicus and the anterior superior spine of the ilium. By prolonging the wound upwards to the costal margin if necessary access can be got to the hepatic flexure and the transverse colon. The gridiron method of splitting the muscles is only to be used in the case of a circumscribed movable tumour of the cæcum.

The skin, linea semilunaris, transversalis fascia, and peritoneum are divided. If local anæsthesia is used, a fresh injection of novocain should be given before dividing the peritoneum. The edges of the wound are then retracted, and the tumour freed and brought out by dividing any peritoneal bands or adhesions which tack it down to the iliac fossa. The peritoneum on the outer side of the colon must be freely divided before it can be sufficiently lifted up and healthy bowel exposed above and below the growth.

The ascending colon is pulled well forward, isolated, and clamped with two pairs of crushing-forceps placed about $\frac{3}{4}$ of an inch apart. The distal pair is removed and the bowel tied with a strong ligature in the groove where it has been crushed. A gauze swab wrung out of lysol is placed beneath it and the intestine is cut across close

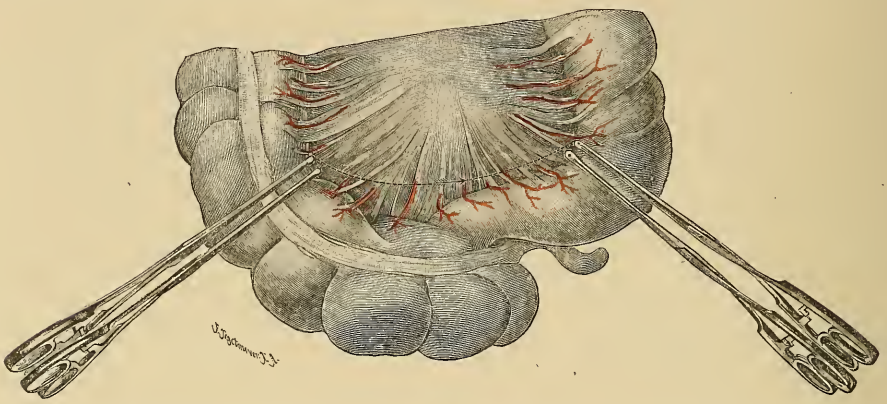

FIG. 377.—Ileo-cæcal resection. Stage 1 : Cæcum, ascending colon, and ileum have been exposed and two pairs of crushing-forceps applied above and below. The division of the mesentery is indicated by a dotted line. The forceps on the large intestine are here represented as too near, as it would not be possible to pass a ligature round the groove left by the removal of the distal forceps.

to the proximal pair of forceps; the redundant tissue is removed and the crushed end swabbed with alcohol. The mucous membrane of the peripheral stump is destroyed and swabbed with lysol. By using the proximal pair of forceps as a handle, the mesentery on the inner side of the bowel is divided, under-running the vessels with an aneurysm needle and ligaturing them firmly in sections. If the mesentery is thick, it should be crushed before it is divided. The distal ends of the vessels are then caught up with artery-forceps.

If there are any enlarged glands in the mesentery, they are to be removed, but if none are found, the division of the mesentery should be as near the gut as possible, to avoid tying the ileo-colic artery which supplies the ascending colon, an accident which would necessitate a further or entire removal of the ascending colon.

The mesentery of the small intestine is also divided close to the gut, and as the mesentery of the lowest portion of the ileum is so short, it is advisable not to utilise it, but rather select a portion higher up, which can be readily brought up to the ascending or the transverse colon without tension. As before, the intestine is divided between two crushing-forceps after which the diseased ileo-cæcum is removed.

The ileum is then anastomosed to the colon, but first of all one must make sure that the blood-supply to the ends of the gut, which are still grasped by the crushing-

forceps, is good, by noting the pulsation in the arteries; and secondly, that the ileum can be approximated to the ascending colon sufficiently well to allow of their being sutured. If this cannot be done, the transverse colon must be pulled down and the ileum inserted into it.

As Fig. 378 shows, the end of the large intestine is carefully closed with a layer of sero-muscular sutures, over which a layer of serous sutures is inserted.

The end of the small intestine is then applied to the large intestine and its posterior serous coat fixed by a line of serous sutures to a longitudinal muscular band. Both portions of gut are then emptied and clamped, the colon is opened by a

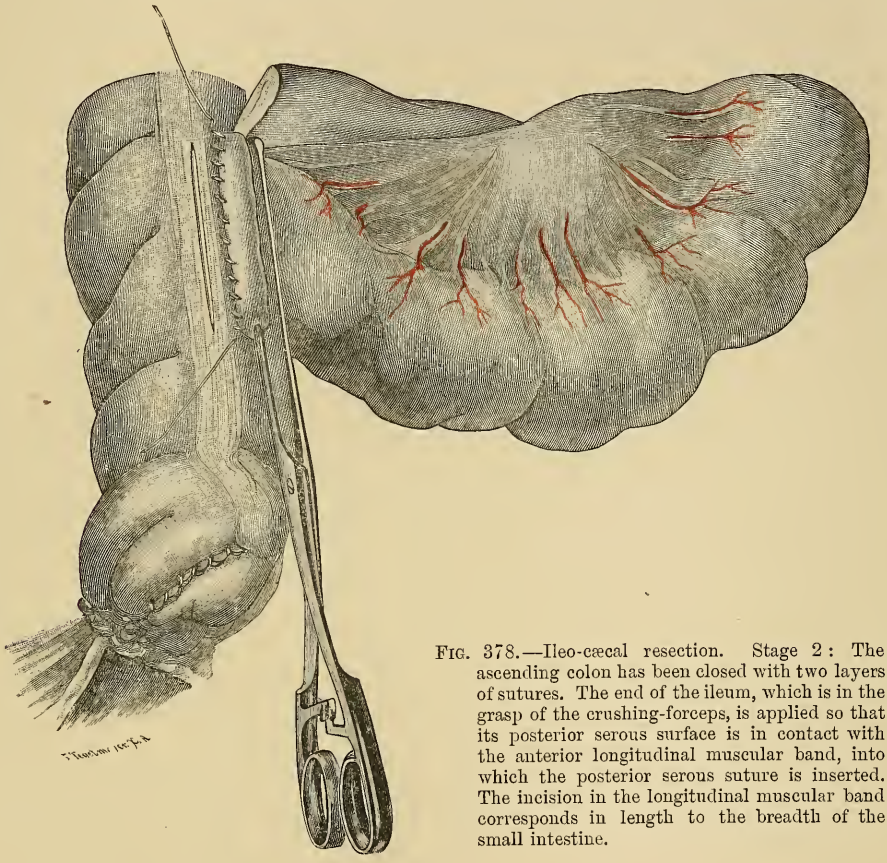

FIG. 378.—Ileo-cæcal resection. Stage 2: The ascending colon has been closed with two layers of sutures. The end of the ileum, which is in the grasp of the crushing-forceps, is applied so that its posterior serous surface is in contact with the anterior longitudinal muscular band, into which the posterior serous suture is inserted. The incision in the longitudinal muscular band corresponds in length to the breadth of the small intestine.

longitudinal incision in the muscular band, and the crushing-forceps are removed off the small intestine. A suture including all the layers is next inserted in the ordinary way, and the serous coat is sutured over it.

If possible, the raw surfaces on the abdominal wall are covered over with peritoneum, and the free edge of the mesentery stitched to the peritoneum. If the operation has been carefully performed and there has been no soiling of the peritoneum, a single glass drain is passed down to the site of the anastomosis and the wound is closed in layers. It is advisable also to insert two short drainage tubes into the wound as abscesses of the abdominal wall readily occur, from even the slightest contact with intestinal contents.

155. Resection of the Large Intestine. Resection within the limits of the colon must be regarded quite differently from resection of the small intestine and even of the ileo-cæcal region. In the case of the small intestine the contents are fluid and can

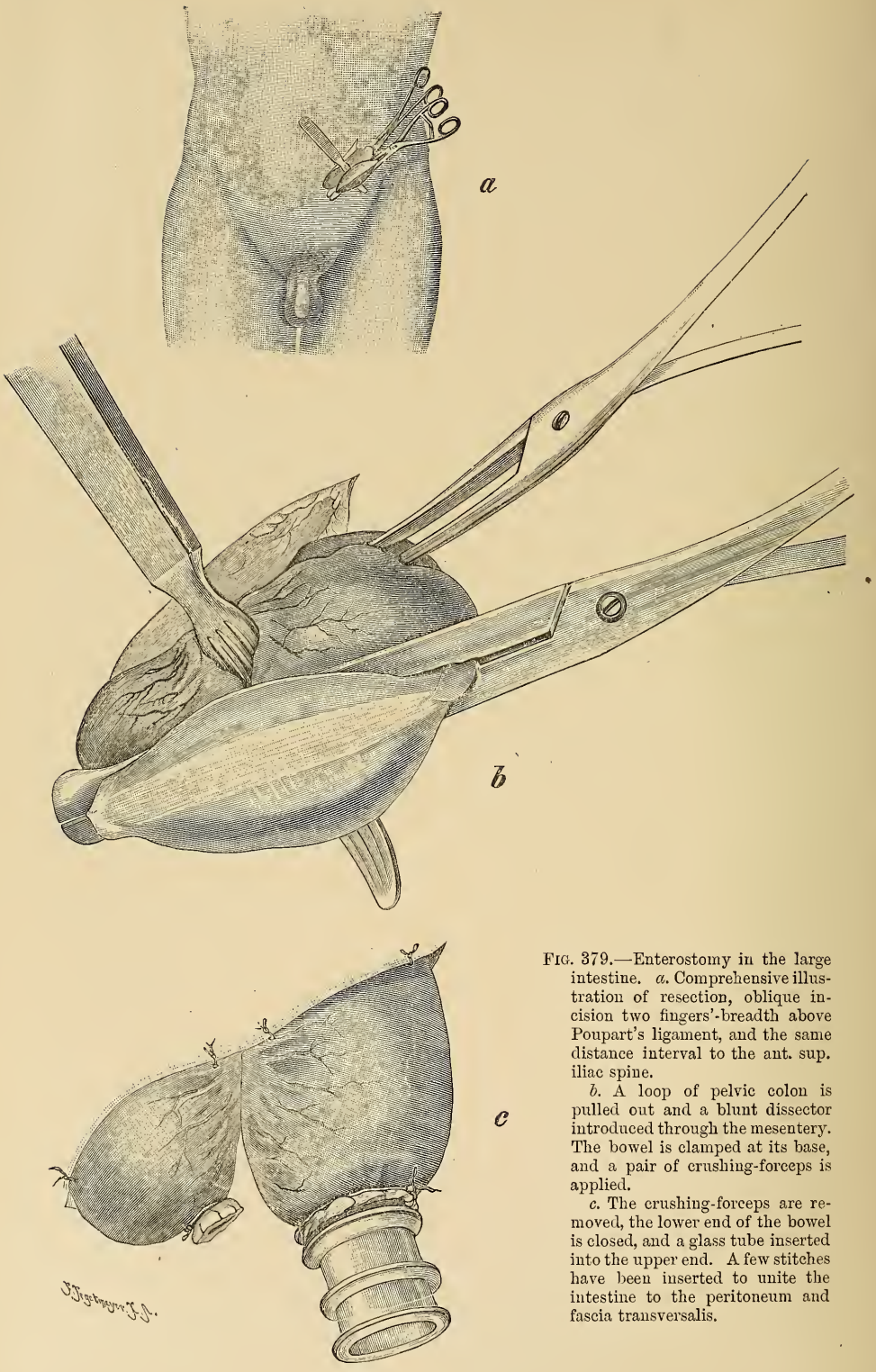

FIG. 379.—Enterostomy in the large intestine. *a*. Comprehensive illustration of resection, oblique incision two fingers'-breadth above Poupart's ligament, and the same distance interval to the ant. sup. iliac spine.

b. A loop of pelvic colon is pulled out and a blunt dissector introduced through the mesentery. The bowel is clamped at its base, and a pair of crushing-forceps is applied.

c. The crushing-forceps are removed, the lower end of the bowel is closed, and a glass tube inserted into the upper end. A few stitches have been inserted to unite the intestine to the peritoneum and fascia transversalis.

therefore be readily propelled onwards by the peristalsis through the sutured portion, even when the lumen of the latter has been rather diminished, and its power of contracting temporarily interfered with.

With the contents of the colon, however, it is different, for when they come in contact with the portion that is sutured, their progress is apt to be arrested owing to temporary obstruction and diminished peristalsis. They exert a prejudicial action on the sutures and may give rise to local ulceration, cutting out of the stitches, and perforation.

Accidents of this sort may occur even after thorough purgation and accurate stitching, and they can be made good only by most careful observation and by prompt and energetic treatment. The sutured gut must be brought to the surface, an artificial anus made, and the peritoneum cleansed as thoroughly as possible to prevent the onset of acute general peritonitis. Even in cases which do not go so far as perforation, fæcal abscess or peritonitis, the occurrence of an infective necrosis of the mucous membrane is sufficient to set up septic metastatic conditions (more especially pneumonia in old people) to which they rapidly succumb from heart failure and diarrhœa.

The trouble from the sutures can be avoided with certainty if we conduct the fæces away from the bowel above the resection. To do this an artificial anus must be made, not a fæcal fistula, so that the whole of the intestinal contents are led away through the opening, and the lower portion is thrown out of use. Or, one may anastomose the small intestine with the large intestine below the site of suture by ileo-colostomy, ileo-sigmoidostomy or ileo-proctostomy. Or, finally, the whole of the lower portion of gut may be excised and the upper portion implanted in the abdominal wall or even into the anus.

It makes a great difference whether resection of the large intestine is undertaken when the patient is suffering from obstruction or ileus, with a fæcal collection above the obstruction, or whether the bowel has been thoroughly emptied for a week or a fortnight before. In the latter case we have often been able to resect the large intestine without making an artificial anus above the site of suture, and as a rule with success, but in such cases both ends of the gut must be pulled well out of the wound, carefully approximated, and a large communication made between them. Even then the sutures occasionally give way.

The same care must be taken in making a lateral anastomosis, *i.e.* when both ends of the bowel are occluded and a large communication is made through the opposed longitudinal muscular bands. This method is in many cases to be preferred in the large intestine. In the case of the small intestine we attach no special importance to lateral anastomosis, while we consider end-to-side anastomosis between large and small intestine just as good as, and more simple than, lateral anastomosis.

The methods by which the above conditions can be carried out are very varied. The steps of the operation, viz. (1) safe removal of fæces, (2) isolation of the diseased portion of bowel, (3) removal of the disease, and (4) suture of the gut, may be combined in several ways, especially as one may operate in one or in several stages. The individual features of each case as well as the resistance of the patient must be considered before deciding whether to operate in one, two, or three stages.

In neglected ileus where the condition of the patient is already very serious, it is often as well to attend to the first point only—namely, the emptying of the gut—and wait till the patient's strength has been restored by the administration of fluid and nourishment, and till the danger of perforation of distension ulcers is past. These ulcers[1] are particularly liable to occur in the large intestine. The first stage of the operation is therefore limited in these cases to making an artificial anus above the obstruction, as described under "Enterostomy."

When the patient's general condition is less serious, and will allow of further operative interference, an attempt should be made to convey the contents of the ileum into the large intestine below the obstruction, while the resection of the gut is reserved for a later date. Thus, for tumours of the cæcum, ileo-transversostomy is performed, and ileo-sigmoidostomy for disease elsewhere in the colon. End-to-side

[1] See our article on "Ileus" in *Grenzgebiete d. Med. u. Chir.*

ileo-colostomy is the only reliable method preparatory to subsequent resection of gut.

Lastly, when the patient's condition is good, one has to decide whether the entire operation may not be performed in one stage. This should only be attempted in special cases; in the majority of cases one is compelled to operate in at least two stages.

According to Anschutz,[1] Oskar Bloch first proposed the two-stage operation, and Mikulicz developed it in the form of merely bringing out the gut. Many surgeons (*e.g.* Rotter,[2] who has had great experience in this branch of surgery) have proved that the mortality has diminished greatly since the adoption of Mikulicz's method. Schloffer[3] developed and recommended resection in three stages, the steps of which consist in colostomy, resection and suture of the bowel, and closure of the fistula.

Operation in one stage is only possible when a permanent artificial anus has been made. It can be employed, for instance, in malignant disease of the pelvic colon,

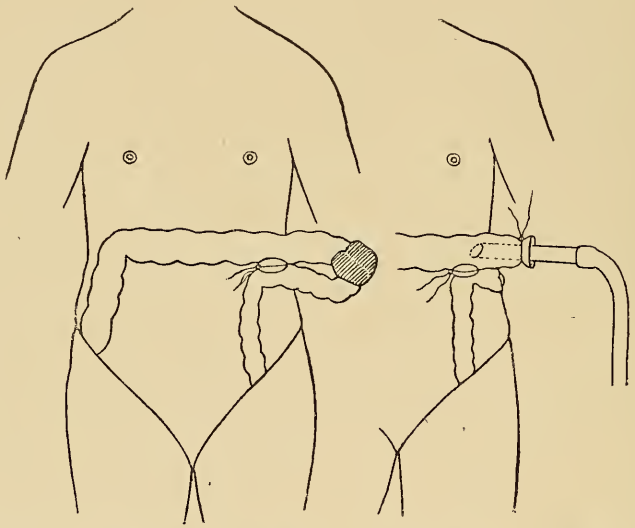

FIG. 380.—Resection of large intestine with M'Graw's elastic ligature. In the figure to the left the tumour is shown pulled outside the abdomen and the anastomosis made with the elastic ligature. In the figure to the right the tumour is removed, the lower end of the bowel closed and replaced just inside the abdomen, while a glass tube is tied into the upper end.

and occasionally of the descending colon up to the transverse colon, if the entire portion of gut down to the anus is excised (cf. section on excision of the rectum). Thus Kümmel and de Quervain have divided the transverse colon above the obstruction and inserted it into the anus, after excising the whole of the intervening bowel. If the patient's strength is well maintained, it is not necessary to do this in two stages.

The same holds good in ileo-colostomy. There is no reason why the ileum low down should not be implanted into the ascending, transverse, or pelvic colon, and why the whole of the short-circuited gut should not be excised in one stage, provided that the patient can stand it, as the possibility of fæcal stagnation is excluded. It is only when the patient's condition is not sufficiently good that the operation must be done in two stages.

[1] *Gedenkband für Mikulicz*, loc. cit.

[2] Rotter had a mortality of 55 per cent by operation in one stage (twenty-five cases). Mikulicz has reduced the mortality from 49 per cent to 10 per cent by the method of operating in stages.

[3] *Beitr. z. klin. Chir.* Bd. 38.

When the operation is done in two or three stages, it depends on the method adopted and the condition of the patient whether only a few days or a month should elapse between the first and the subsequent stages. M'Graw[1] has devised a method in which the whole operation is completed in four or five days. Like Mikulicz, he brings the tumour out of the wound after separating it, but he then makes an anastomosis between the afferent and efferent limbs of the gut with his elastic ligature, and closes and replaces the lower end before he stitches the intestine to the edges of the wound. The tumour is cut away and a large glass tube tied into the upper end. After four or five days the elastic ligature cuts its way through, and the fæces are passed per anum. The glass tube is then removed and the upper end of the gut closed and replaced.

Technique of Resection of the large Intestine.[2] We have excised a comparatively large number of tumours of the large intestine, and our results as regards radical cure even in advanced cases have been satisfactory, the patients having enjoyed good health for many years.[3] Apart from the cæcum, which is a very common situation for tumours (for the treatment of which see previous section), carcinoma of the pelvic colon demands special attention. At the same time, carcinoma not uncommonly occurs in the hepatic and splenic flexures and in the transverse colon. Malignant tumours of the pelvic colon are as a rule small and of the scirrhus type, whereas those elsewhere in the large intestine often attain a large size (one or double closed fist), and their removal may present great difficulty.

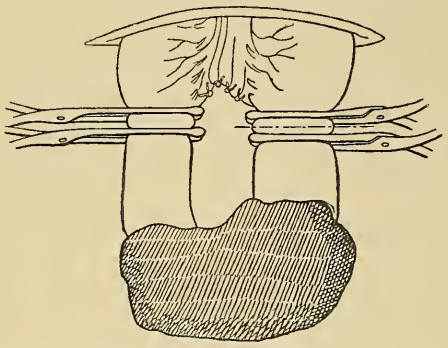

FIG. 381.—Resection of large intestine. The tumour is drawn well out, and two pairs of crushing-forceps are applied to the bowel above and below after the mesentery has been ligatured.

Tumours of the transverse colon are exposed by a transverse incision; oblique lateral incisions are required for tumours of the hepatic and splenic flexures. Muscles should be split rather than divided, while all motor nerves should be preserved. Retracting-forceps will be found of great advantage.

The tumour is separated from adherent omentum and pulled out along with any adherent loops of small intestine. The bowel is crushed and divided, and when the tumour has been brought sufficiently far outside the abdominal cavity, the peritoneum is carefully shut off with gauze packing. The tumour must be very thoroughly freed, for it is absolutely essential to bring it well out of the abdominal cavity, while it is immaterial whether a longer or shorter portion of healthy large intestine is removed along with it. This is an absolutely essential point. Catgut ligatures are used for tying the mesocolon, as there is a risk of their becoming infected during the resection of the bowel. Crushing-forceps may be applied to the mesentery if desired.

After the tumour is thoroughly freed and brought outside the abdominal wound, one has to decide how the continuity of the bowel is to be restored when the tumour has been excised, and how the intestinal contents can be best led away from the site of the resection.

It is only in exceptional cases (when the bowel has been very thoroughly emptied as a result of careful preparation and diet) that direct union of large intestine is to be

[1] *Annals of Surgery*, 1904.

[2] This description does not apply to patients who are in a very bad general condition with severe fæcal impaction (ileus) at the time of operation. In the latter the removal of the contents of the intestine by artificial opening or enteroanastomosis will be sufficient.

[3] We have not the exact figures at our disposal at present, but they will be published separately. Rotter has recorded five radical cures out of eight operations.

attempted, either by end-to-end suture, or by lateral anastomosis with occlusion. On the other hand, if the patient has been well prepared, a direct union may as a rule be made between the lower ileum and the large intestine. Ileo-colostomy is then performed as described in Section 154 (*vide* Fig. 378), only the point at which the ileum is inserted being varied.

If such a unilateral occlusion is out of the question, because it involves the sacrifice of too much bowel, the two limbs of the bowel should be stitched to the parietal peritoneum and fascia of the wound with sutures which include the serous and muscular coats. Two pairs of compression-forceps are then applied to both the afferent and efferent bowel at a sufficient distance beyond the tumour. The distal pair on the efferent limb is removed, the bowel tied with a strong ligature, and divided close to the proximal forceps. The afferent bowel is divided between the two pairs of forceps.

After applying a clamp to the afferent loop and packing a layer of protecting gauze round it, the crushing-forceps are removed, and a glass tube, with a rubber tube attached, is fixed in the gut. This ends the first operation.

After the bowel has been well evacuated and the patient's strength restored, food is withheld for a few days, and the spur between the two limbs is destroyed, for a distance of 7-8 cm., by means of Dupuytren's enterotom or suitable crushing-forceps. This is of course more easily done if both ends of the gut have been left open with a glass tube in each.

Instead of simply destroying the spur, one may anastomose the two limbs, and when the anastomosis is healed the artificial anus may be closed. This method resembles that of M'Graw, only here the bowel is stitched instead of using the elastic ligature; the latter is less trustworthy, as the opening is apt to narrow again.

In cases where the gut is comparatively free from fæces at the time of the first operation, primary anastomosis may be performed as shown in Fig. 380. The artificial anus is closed after eight to ten days.

156. Surgical Interference in Disease of the Vermiform Appendix.[1] The treatment of interval cases of appendicitis has been fully considered in our former edition. The indications for operative interference in appendicitis have widened so enormously in recent years that it is difficult to formulate rules on this subject.

Now that every busy surgeon counts his operations for appendicitis by hundreds, and the statistics of some surgeons run into thousands, the temptation of treating any part of the subject too exhaustively must be avoided. The information we here give is therefore confined to the bare essentials; further details will be found in the excellent and exhaustive treatises by Sprengel[2] and Kelly.

The significance of the operation for appendicitis is very different according to whether we are dealing with the so-called radical operation during the quiescent stage or during the acute stage. The radical operation, as performed by the majority of surgeons, is not an operation for appendicitis, but in a large proportion of cases is merely amputation of an appendix which shows no sign whatever of existing inflammation, but which is removed because at one time it was the seat of inflammatory changes, the results of which can still be recognised. This operation may be classed along with those other cases in which the operation is performed on account of distress in the shape of appendicular colic, the appendix itself showing no sign of disease when examined, or where, exceptionally, some ulceration, retained excrement, a calculus, cicatrices, adhesions, or kinking may be discovered as the cause. In 39 per cent of his radical operations Roux found no marked change; in 61 per cent he found either a perforation, a cicatrix, or some stenosis.

[1] Haberer (Lecture, Vienna, 1905) has traced the historical development of appendicitis. In 1824 Louyer-Villermay first reported two fatal cases of inflammation of the appendix. Shortly after this Melier and Meniere advocated laparotomy in cases of suppuration from this cause. Burne (1839) referred the majority of cases of perityphlitis to perforation of the appendix. Mikulicz (1885) and Kronlein (1886) reported successful treatment of acute peritonitis with resection of the appendix, and in 1888 Gaston advocated appendectomy as a radical measure. The American surgeons (M'Burney and Murphy) were the first to undertake early operation on principle.

[2] Sprengel, *Deutsche Chirurgie*, 1906.

It is evident that such operations must be incomparably more successful than operations performed during inflammatory attacks. In the present state of abdominal surgery an operation on so small an organ as the vermiform appendix is entirely devoid of danger, and may be undertaken without hesitation. The mortality in such cases with a surgeon of the aseptic school is nil.

An exception, however, must be made when extensive adhesions have formed after a severe acute suppurative attack, for in these cases the appendix is often so buried that its separation may result in considerable bruising or even perforation of the intestine, which, if unnoticed, will lead to serious results. This radical operation in cases where there are no, or only very slight, adhesions, has been treasured as the jewel of operative surgery. Without exposing the patient to danger and with a minimum of trouble and anxiety, it gives the surgeon the satisfaction of having for ever relieved the patient, not only from suffering, but also from a danger constantly threatening his life.

Roux has come to the conclusion that the radical operation should be performed on every patient who has had a single attack of appendicitis, while other surgeons prefer to wait till after a severe attack or till several attacks have occurred.

Our own experience has led us to recommend operation if the patient has had one *definite attack of appendicitis, or repeated or continuous attacks, even though the symptoms have been but slight, provided there is sufficient evidence of the existence of changes in the appendix.* Every surgeon must have seen cases in which the patient, after recovering from one or two slight attacks, has subsequently been seized with a fatal attack. It is such calamities as these which have led surgeons to recommend radical treatment.

Where the choice is given, one should certainly take to heart the advice given by Roux and other specialists on the appendix—it cannot be enough emphasised—and always operate in the stage at which all symptoms of inflammation have entirely disappeared, *i.e.* some months after an acute attack.

(*a*) *Technique of radical Operation when Inflammation has subsided.* The method, often described as M'Burney's or Roux's method, of opening the abdomen by splitting the muscles in the direction of their fibres gives the least chance of trouble after the operation for the removal of the vermiform appendix. For, apart from infection, which should not occur, the only injury which can result from the operation is the formation of a ventral hernia. If the abdomen be opened by separating the muscular fibres, and if injury to their nerve-supply be avoided, there is no question of the formation of a hernia. Not only that, a patient operated on by this method can leave his bed and follow his occupation after eight days, just as a patient can on whom our operation for the radical cure of hernia has been performed.[1]

The incision (Fig. 382) is purposely made over the fleshy region of the abdominal muscles, three fingers'-breadth above and parallel to Poupart's ligament. Divide skin, subcutaneous tissue, and the aponeurosis of the external oblique,[2] and with blunt hooks pull apart the edges of the latter as widely as possible. Next incise the fascia covering the internal oblique muscle, and separate and pull apart the muscular fibres, again putting in the blunt hooks. Lastly, the same manœuvre is gone through with the transversalis muscle.

The fascia transversalis, which is now exposed, is divided. The peritoneum merely requires to be incised for about an inch in order to allow of the finger being introduced and the cæcum brought out till the point of entrance of the ileum appears. In the angle between the two, where the anterior longitudinal band ends, the base of the processus vermiformis can be located with certainty, and is the first thing to

[1] The incision, the direction of which changes in the different layers, was recommended by M'Burney in 1894. Baracz and the Americans call it the gridiron incision.

[2] The dispute about large or small incisions has not the importance attributed to it by Hahn and Bier. For radical operation in the quiescent stage our incision is about 7 cm. long; in acute and complicated cases it must be longer. v. Eiselsberg and Haberer justly maintain that it is not right to make the operation in the depths of the wound more difficult for the sake of getting a scar shorter by one or two centimetres. This certainly means more risk to the patient. The surgeon who knows how to stitch and get genuine linear scars attaches no value to abnormally small incisions.

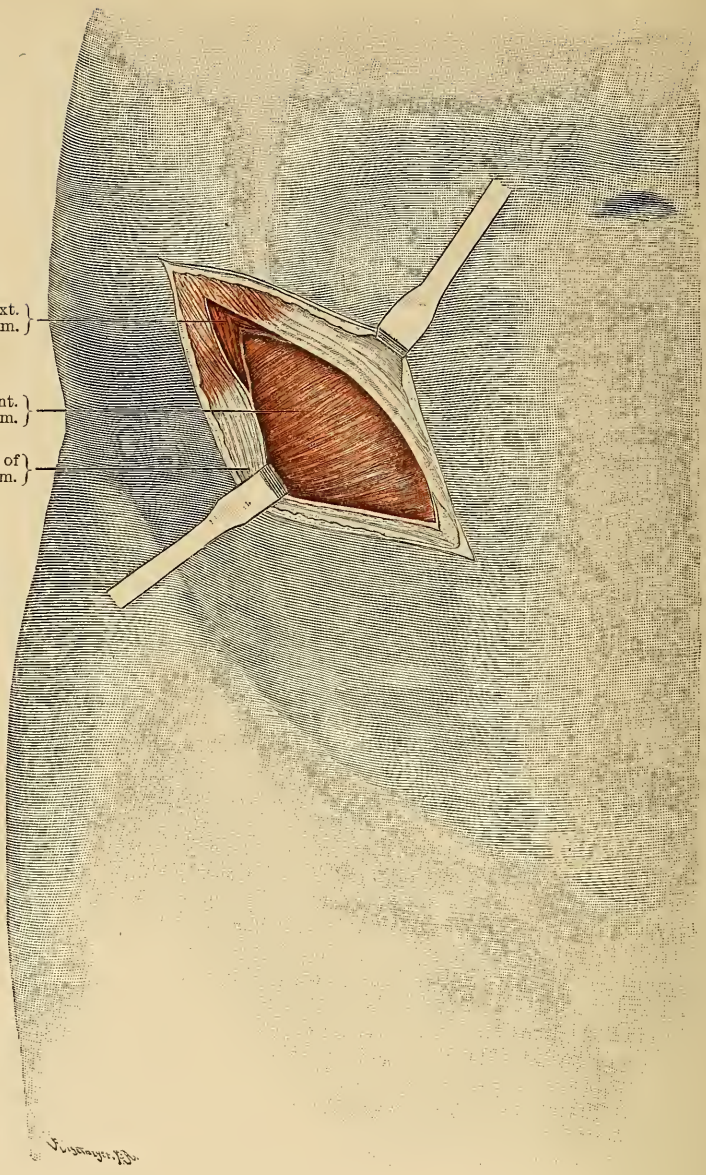

Fig. 382.—Permuscular incision for removal of the appendix, dividing skin, superficial fascia, aponeurosis of ext. oblique as well as muscular fibres (separation). The incision is placed three fingers'-breadth above the outer third of Poupart's ligament. The internal oblique and transversalis muscles are split parallel to their fibres and forcibly held apart, exposing the peritoneum covered by the thin transversalis fascia.

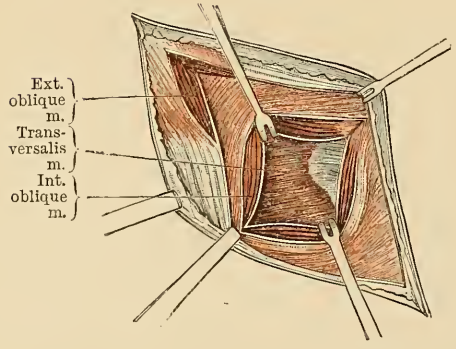

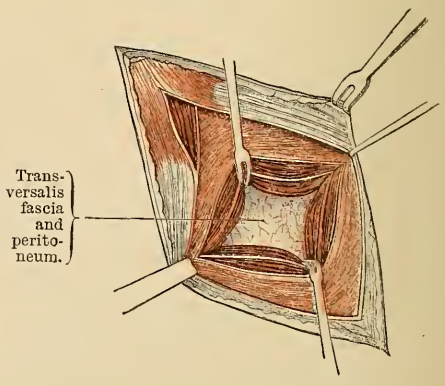

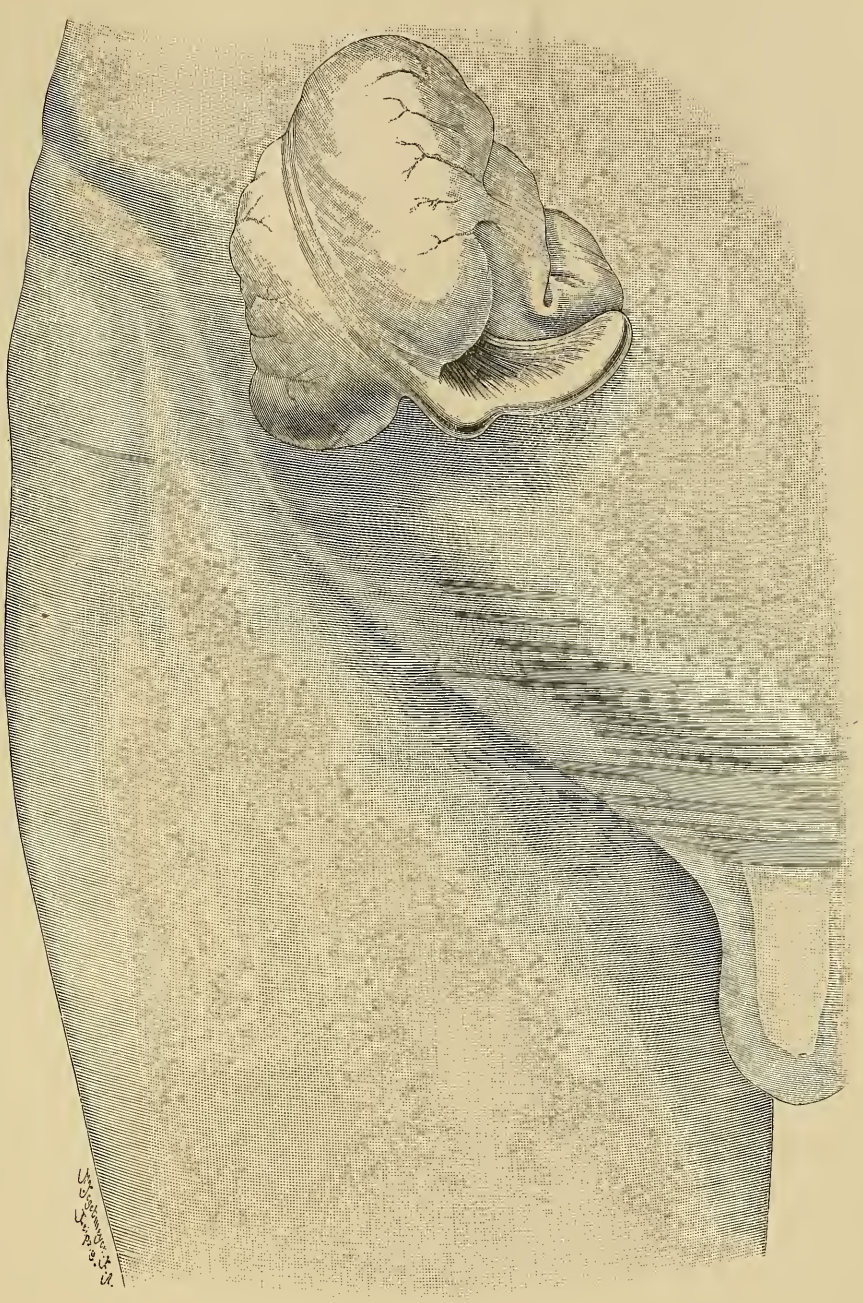

FIG. 383.—Radical operation for appendicitis. The cæcum and lower end of ileum have been drawn out of the wound. The figure shows the anterior longitudinal muscular band of the large intestine ending at the base of the appendix. The meso-appendix is well seen.

look for. The appendix is then freed and brought up to the abdominal wound. A small pair of crushing-forceps is applied at the base and then taken off, the point of their application is ligatured, and the part beyond cut off. The forceps should not be too narrow. A sufficient breadth is thus crushed, so that it is not necessary to cut through an uncrushed portion. The stump is buried by means of a continuous serous suture, and for this purpose it is best to use the end of the ligature which has been applied to the small artery in the mesentery of the appendix. If the tip of the appendix is firmly adherent deep down, it is often an advantage to separate and divide the base first, after which the process is gradually freed towards its tip, dividing the shortened mesentery and the adhesions towards the apex.

The base is crushed, tied with a silk ligature, and then divided with the thermo-cautery. Previous to dividing it, however, it should be grasped with a pair of Kocher's artery-forceps which form a useful handle.

In such simple cases, when the appendix shows no material macroscopic changes, the peritoneum and fascia transversalis are stitched up without a drain (de Quervain uses the tobacco-pouch stitch), and stitches may be introduced to close the split edges of the muscle. A continuous suture is put into the divided external oblique, and the skin incision is closed.

(*b*) *Early Operation in the Acute Stage of Appendicitis.* In the few years that have elapsed since the publication of our last edition, the greatest revolution has taken place regarding the question of operation in the acute stage of appendicitis—the so-called early operation. Formerly there were only a few strenuous advocates of the early operation, *e.g.* Rehn, Sprengel, Bernays, Sonnenberg, Riedel; now, however, experience of its undoubted advantages has led to its general adoption.

Bernays was among the first to convince the general public as well as the practitioner of the benefits of early interference, by publishing the brilliant results he had obtained in seventy-one cases of acute suppurative and gangrenous appendicitis, in which all his patients recovered after early operation.

In the last few years, the equally good results of other surgeons such as Körte, Rotter, Krogius, Kümmel, Riedel, Ochsner, and especially American operators, have borne this out. Körte, in his exhaustive work on perityphlitis, has produced convincing proofs of the advantages of early operation.[1] According to Nordmann,[2] of eighty patients operated on within the first three days for appendicitis, when the inflammation was still limited, none died! while of fifty-four operated on within the same period when there was diffuse peritonitis sixteen died, the majority of the latter having been operated on the third day after onset. At the Congress of the Deutsche Gesellschaft für Chirurgie it was shown that the mortality from the genuine early operation (*i.e.* when the patient is operated on within twenty-four hours of the onset) is nil, and that it increases on the second and third days to reach still higher percentages in the intermediate stage. In contrast with Bernays' figures, in forty-five of Rotter's cases operated on in the first twenty-four hours, there were only four in which pus had formed, while of sixty-five operated on on the second day pus was present in thirty-five. While all his cases of pure appendicitis recovered, he had a mortality of 3 per cent for cases with merely serous exudation in the surrounding parts, and a considerably higher mortality in cases of suppuration, *i.e.* when perityphlitis had occurred.

The statement made by Bernays that "with early operation we are in a position to secure 98 per cent of recoveries even including the worst cases" has been absolutely verified. We can count on almost certain recovery from early operation so long as the phlegmonous inflammation, which, according to Roux, is characteristic of acute appendicitis, is limited to the appendix itself, *i.e.* merely purulent infiltration of the wall, ulcerative changes of the mucous membrane, or more extensive gangrene.

In addition to the appendix being intensely red and swollen, it is almost always covered with lymph, and there is a sero-purulent exudation round it. The period of the true early operation lasts so long as the surrounding serous and subserous tissues have not become involved in the acute suppurative infiltration or necrosis, *i.e.* when

[1] Compare also the great works of Kelly and of Sprengel on Disease of the Appendix.

[2] Langenbeck's *Archiv*, Bd. 78.

acute perityphlitis or paratyphlitis has not been superadded. This localised or circumscribed condition may be over-stepped in six hours, especially if there is a perforation and gangrene at the base of the appendix, but otherwise it may continue till the third day. In short, the most favourable time is passed with the lapse of twenty-four hours, after which the operation can no longer be regarded as "early."

Technique of early Operation in the acute Attack. As a rule a larger incision is required when operating in the acute stage than in the interval. There is therefore no advantage to be gained by splitting the muscles, or by the incision through the sheath of the rectus. We agree with Senn, Barker, and Bernays that it is better to choose the thinnest part of the abdominal wall, where the aponeuroses of the muscles unite to form the rectus sheath. This pararectal incision (*vide* Fig. 384) is placed external to the rectus sheath, and divides the skin, fascia, and the united aponeuroses of the three abdominal muscles. As is often necessary, it may be prolonged upwards or downwards without doing any harm.

The peritoneum is then freely incised, and its edges are grasped with artery-forceps to allow of the escape of any collection of fluid. After separating the omentum, which is often adherent, traction is made on the cæcum, and the appendix sought for with the finger and pulled out of the wound with or without the cæcum. If, after separating the adhesions, the appendix is found to have perforated, and pus or other infective fluid is found to be escaping from the lumen or from a small abscess in the vicinity, the origin of the appendix should be clamped, and the process rapidly removed. Escape from the lumen must be mopped up at once with gauze.

The removal of the appendix may be made more difficult if there is an open perforation at its base, or if the base has become thickened and friable from phlegmonous infiltration. As a rule it should not be crushed: a ligature is simply tied round it, and if necessary a portion of the cæcum may be included to give a better grip. In this case the cæcum should be clamped.

If there is much sero-purulent fluid already present round the appendix and in the cavity of the pelvis, mere swabbing may not be sufficient, and irrigation with saline may be necessary, but in the latter case a free outflow must be provided. A drainage tube is passed down to the stump, in case the ligature on the appendix gives way, and in addition, if there is a copious exudate, large glass tubes are passed down into the pouch of Douglas, upwards along the ascending colon and occasionally in other directions, depending on the position of the appendix. Besides the glass tubes, gauze drainage is very useful. Bernays inserts a gauze strip down to the stump and places gauze in contact with every inflamed loop of intestine. M'Cosh's cigarette drain (wick and rubber wrapping) is still better. The peritoneum and fascia transversalis alone are united round the drain and gauze. The muscles, superficial fascia, and skin are brought together after a day or two by secondary suture, or may be temporarily stitched over a piece of iodoform gauze.

(*c*) *Operation for Appendicitis in the intermediate Stage after Abscess Formation.* A professor of clinical medicine, justly held in high esteem, when discussing the treatment of appendicitis, is regularly in the habit of saying to his students that with all their operations at the present day surgeons do no more good than in the days when they limited themselves to opening perityphlitic abscesses handed over to them by the physician. In the early operation the diagnosis may be as often erroneous as correct, and operations are performed in cases of commencing typhoid, acute gastro-intestinal catarrh, biliary colic, etc. Operations after the inflammation is past could in great part be left undone, and are performed on perfectly healthy vermiform processes.

Now and then mistakes are undoubtedly made from operating early, but this is no reason why one should relinquish the great benefits of early operation in cases of genuine acute appendicitis. Those who have had the experience of seeing a surgeon decline to operate, although the friends of the patient urgently desired operation in the early hours of the disease, and then have seen the patient die of peritonitis in a few days; or who have seen the waiting policy followed till the abscess has become obvious to the eye of the physician, and the operation has become a serious consideration as the result of metastatic processes (the formation of fresh abscesses, thrombo-phlebitis

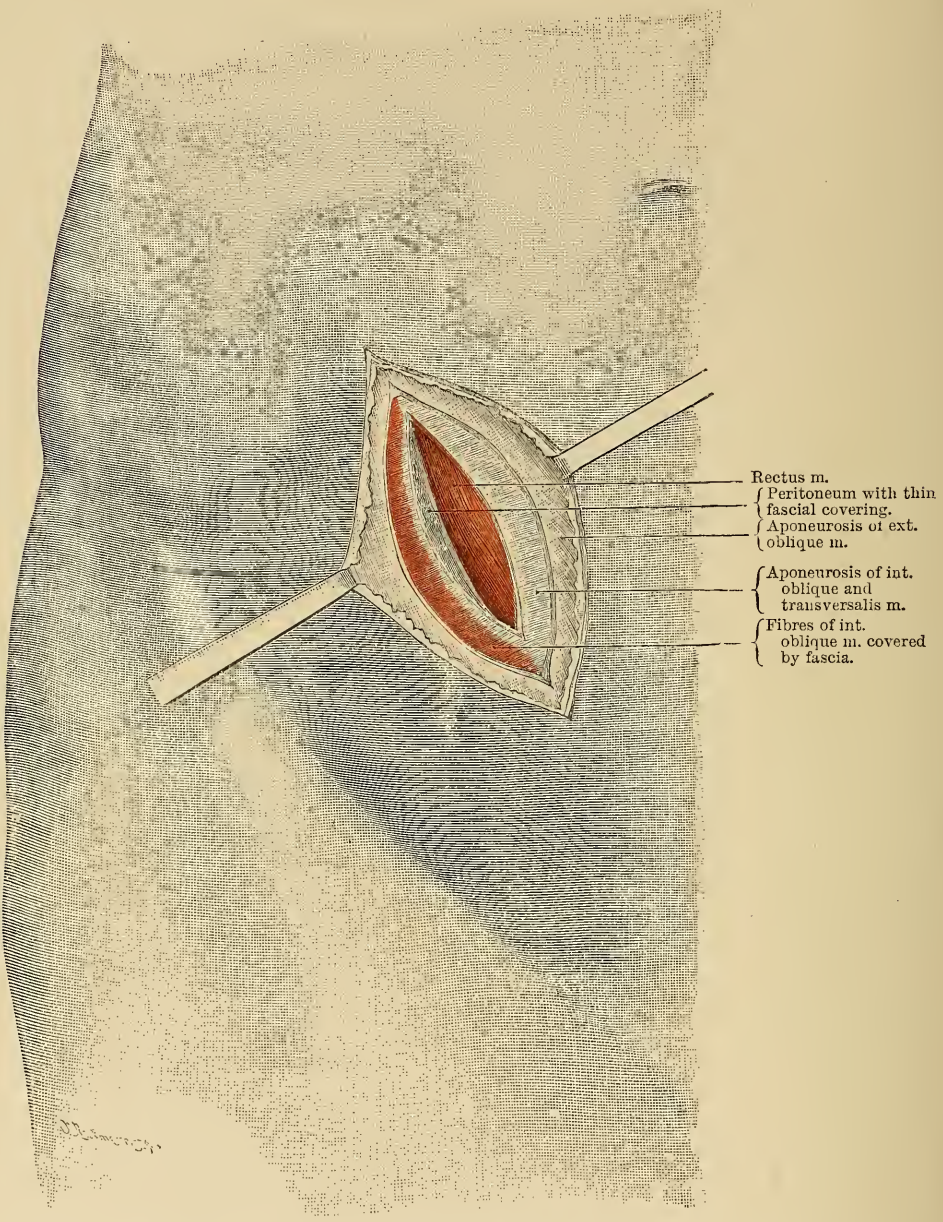

FIG. 384.—Parareceal incision in acute appendicitis associated with peritonitis. Skin, aponeurosis of ext. oblique, int. oblique, and transversalis muscles are divided, the edge of the rectus is exposed, with underneath it the transversalis fascia and peritoneum.

mesenterica (Golya) subhepatic abscess and pylephlebitis, acute phlegmonous parotitis) or as the result of infection of the peritoneum from opening deeply situated abscesses, abscesses in the pelvis or under the liver; or those who have seen two or three attacks of the mildest type followed by a fourth fatal recurrence, will have little inclination to gamble with the life of their patient, and wait for abscess formation with its attendant risks, when they can avoid it.[1]

On the contrary, when we see a patient with an abscess already definitely formed and easily diagnosed, we reflect whether it need be opened at all, or whether it would not be better to wait for spontaneous perforation into the gut.

If the temperature is already falling, the pain disappearing, and the distension diminishing, there is no need to be in a hurry to open the abscess, provided the patient is kept under supervision and properly treated by rest and diet, without opium. The fall of temperature is a certain indication that the inflammation is subsiding. When the abscess is easily accessible to the knife, by all means cut the course of the disease short by opening it.

On the other hand, when the inflammation is still of an acute and progressive character, operation must never be postponed. Here, however, the state of affairs is quite different from that of the genuine early operation. In the latter case, where the inflammation is limited to the appendix and its immediate neighbourhood, one aims at a radical cure by removing the diseased organ, whereas when an abscess has formed the removal of the appendix becomes a secondary consideration; and one has to treat the perityphlitis (paratyphlitis, parahepatitis, or pericolitis, depending on the position of the appendix and the extent of the inflammation). The first object is, then, the evacuation of the pus. Primary removal of the appendix is only indicated when it can be done quite easily, or when it seems necessary for the cure of the abscess.[2]

The method and place of opening depend upon its site. Abscesses form not only at the classic point between the umbilicus and anterior superior spine of the ilium, but also inside the true pelvis, in the left iliac fossa, towards the umbilicus, in the right lumbar region, below the liver or below the diaphragm, according to the site of the appendix. It follows, therefore, that the incision may require to be through the rectum, through the posterior vaginal wall, in the middle line of the abdomen, above the left Poupart's ligament, in the right lumbar region, at the umbilicus, or below the costal margin. When the abscess is in its "normal" position the incision is best made parallel to and just above Poupart's ligament, even in cases where the chief swelling seems to be situated above this point, and where the tenderness and resistance are both more intense at a higher level. If the incision be made farther away from Poupart's ligament it often opens the free abdominal cavity at a point where the exudate appears to be superficial only. The incision is made one finger's-breadth above the ligament, through skin, superficial fascia, and external oblique. The deeper abdominal muscles, often œdematous, are raised upwards with a blunt dissector from the groove of Poupart's ligament, and the dissection is continued upwards and backwards towards the exudate till pus wells up.

In cases in which the inflammation is abating it may be necessary to dissect deeply through the infiltrated tissues. Care must be taken not to bore into the ilio-psoas muscle. When the incision is made in the middle line for large pelvic abscesses it is also advisable to use a blunt dissector after cutting through the skin, superficial fascia, and linea alba in order to avoid injury to the bladder, which is often closely applied to the abscess.

Injury to the bladder will be avoided by seeing that the bladder is emptied, if necessary, by passing a catheter. It may be a very difficult matter to open deep

[1] Ochsner (Tristate Soc., Oct. 1904) had a mortality of 1·9 per cent in 255 cases of acute appendicitis with and without perforation, but without abscess, 3·4 per cent in 117 with abscess, and 30 per cent in those with general peritonitis.

[2] According to Nordmann, Korte's mortality was only 0·5 per cent when the abscesses were simply opened in the intermediate stage, while it was 8 per cent when the radical operation was done at the same time.

abscesses above or below the liver in the lumbar region. A large incision is essential, and the tissues must be dissected in layers, care being taken not to open and drain the abscess through the free peritoneal cavity. A short time ago one of our colleagues had a death within a few hours as the result of this mistake in a case of subhepatic abscess.

In spite of opening the abscess recovery may be very slow, or indeed the patient may finally succumb. This happens when one large and well-defined abscess has been opened, and when other abscesses which do not communicate with it are overlooked.

The foul-smelling contents of the abscess must be thoroughly removed by careful continuous irrigation with physiological saline, but it is not desirable to repeat the irrigation. The wound should be dressed with warm compresses, frequently changed.

To shorten the period of convalescence in such cases, and to render recovery certain, we have proposed in this intermediate stage that after the abscess has been opened the radical operation should be performed exactly as during the acute stage. A fresh incision is made quite separate from the one communicating with the abscess cavity, and as far removed from it as possible—*i.e.* at the border of the rectus muscle. Adhesions are carefully broken down, the appendix isolated and brought up into the wound (together with the cæcum if necessary), and amputated as described above. Catgut sutures are employed. The contiguous portions of the small intestine and cæcum, which may be covered with a layer of lymph, must be examined for a possible secondary perforation.

As in the acute stage the wound must be lightly packed with a strip of xeroform gauze passed down to the stump of the appendix. A glass tube should be inserted alongside the gauze, and the dressing should be completely shut off from the abscess wound by a carefully applied covering of collodion.

By means of this procedure we have seen large abscesses which have been opened externally heal up with comparative rapidity, so that we were able to discharge the patients in a few weeks without the necessity for disturbing their minds with the prospect of a second operation for the radical cure.

(*d*) *Operation for general Peritonitis in Cases of Appendicitis.* The surgeon who waits for the formation of an abscess, or for definite perityphlitis, lays himself open to blame should peritonitis ensue as a result of the delay. It is a fact that every year a great many lives are still lost from delay in operating during the acute stage, because a localised inflammatory process has been allowed to spread to the general peritoneal cavity.

It is a question of the virulency[1] of the bacteria, on the one hand, and the quantity of the infectious material present in the peritoneal cavity, on the other hand, which determines the early occurrence of diffuse peritonitis with all its accompanying dangers. If the perforation be a large one, as in extensive gangrene of the appendix, or if it be situated at the base, where intestinal contents can escape, the risk is much greater. Like Roux, we find that a serous or sero-purulent exudation into the free peritoneal cavity is of constant occurrence. Such exudations, however, doubtless find a natural limit for themselves as a rule, by the formation of fibrinous adhesions between the intestine, omentum, and abdominal wall. Not infrequently at autopsies on cases in which a large perityphlitic abscess has been opened, other multiple abscesses are found between the coils of intestine and masses of adherent omentum, under the diaphragm, and extending over the liver and spleen. A small number of these abscesses arise from secondary perforation from purely perityphlitic suppurative foci; most are the immediate consequence of the infective material which escapes when the appendix perforates. Such secondary perforations from an abscess are more dangerous than the primary abscess formation, because in the former case the infective material has developed in the body and become adapted to it, and is consequently much more virulent. It is desirable, therefore, to open the primary suppurative focus as early as possible in the progressive stage of inflammation. In spite of this, a number of patients nevertheless die after abscesses have been opened

[1] Brunner has shown experimentally that virulence and the quantity of the infective material decide whether the peritonitis becomes diffuse or not. Compare also Tavel and Lanz on peritonitis.

from the development of further abscesses, and if death is to be avoided in these cases the primary source of infection must be attacked, the appendix removed, and with it the periappendicular foci, before they have reached the stage of extensive abscesses.

Early operation is even more urgently indicated in those cases where there is no local pus formation, but where an exudate rapidly involves the whole peritoneal cavity, *e.g.* in streptococcal and *b. coli* infection of adults, and in pneumococcal peritonitis in children. The direct method of treatment of such a diffuse peritonitis extending from the diaphragm into the true pelvis is, as a rule, highly unsatisfactory owing to the shock which results from opening and handling the inflamed peritoneum, and the increase of absorption of septic material. If the abdominal cavity be opened freely and all the suppurative foci evacuated and drained, the existing collapse is augmented to a dangerous degree, and the means of preventing this has not yet been discovered. In his experiments on shock, Crile established the fact that cutting off the arterial supply to the intestine prevented the fall in the blood pressure—the chief symptom of shock. It remains to be ascertained whether some such temporary expedient be permissible in peritonitis. Possibly the application of pressure-forceps to the mesentery during the very short time required for examination and cleansing of the intestines might be adopted. Frequent subcutaneous and intravenous transfusions of salt solution are very effective as a remedy for shock. According to Crile a very large amount often requires to be introduced (as much as double the volume of the blood in the case of animals) before a successful result is obtained. Katzenstein has seen excellent results in these conditions by the use of continued slow but copious saline injections into the rectum. As an accompaniment to this, hypodermic injection of strychnine is excellent. Elevation of the buttocks and lower extremities should also be employed.

In peritonitis it is very useful to empty the stomach and intestine by washing out, and it may be necessary to form one or more fæcal fistulæ. It is a noteworthy fact that those surgeons who have obtained the best results in peritonitis lay great stress upon thoroughly evacuating the intestines by means of purgatives as opposed to the morphin treatment. Bernays' custom is to give calomel hourly in a dose of $\frac{1}{10}$ gr. after twelve hours have elapsed since the operation in the acute stage, and, if necessary, to give seidlitz powder and magnesium citrate (of course in cases in which there is no fear of further trouble from the perforation, *i.e.* when the appendix has been amputated).

Bernays, in opposition to Ochsner, strongly defends the use of aperients.

Besides the measures already mentioned for improving the patient's resistance or getting rid of the toxæmia, we have found the following treatment very serviceable in a large number of cases of general peritonitis following appendicitis.

The abdominal wall is incised on both sides at a point corresponding to that which we have recommended for the removal of the vermiform process. The incisions need not be any larger than is necessary to remove the appendix, and this is undertaken in the first place. The exudate is then thoroughly washed out and the abdomen irrigated with normal salt solution at a temperature of 42° C., using a long curved glass tube with a bulbous end which is passed upwards towards the liver, stomach, and spleen, and downwards into the pouch of Douglas. The irrigation is continued till the fluid comes away clear. Large long drainage tubes are passed from both wounds down to the pouch of Douglas and into both flanks, and warm moist compresses applied which are frequently changed. A saline purge (Carlsbad salts) is given to get the bowels thoroughly emptied, and if this fails to act they must be emptied by making one or more fæcal fistulæ. Very often in peritonitis of this sort, instead of suturing the base of the appendix, one has to utilise it for drainage.

The following is a summary of the principal points in the treatment of appendicitis :—

(1) In acute appendicitis it is the duty of the physician to urge the question of immediate early operation, for by no other treatment can the dangers be so certainly and rapidly averted. Operation should be performed under proper aseptic

precautions, preferably in hospital, within the first twenty-four hours, or if possible the first six to twelve hours.

(2) In the subacute stage surgical interference is called for if the inflammation and fever are increasing, and as a rule consists merely in the thorough evacuation of abscesses. When the latter are shut off and the temperature is falling, operation is not urgent, for as a rule they discharge spontaneously into the bowel. If, however, they are easily reached they should be opened.

(3) With the onset of general peritonitis the abdomen should be opened at once, the appendix if possible amputated, the exudate removed by irrigation and drainage, and the stomach and intestines emptied. If, however, paralysis of the bowel and symptoms of collapse are already present, enterostomy only is to be undertaken.

(4) When the inflammation has subsided, the removal of the appendix offers the most certain and safe means of preventing a further attack.[1] If possible three months should be allowed to elapse before undertaking the removal of the appendix.

(i) Surgery of the Rectum

157. Excision of the Rectum. As this is the most important operation on the rectum we will consider it first. It is most often undertaken for carcinoma of the rectum, but is also used in the treatment of other new growths, and occasionally for syphilis, tuberculosis, stricture, and prolapse. Extirpation of the rectum may either take the form of amputation, *i.e.* the rectum is removed from below upwards for a distance varying to a total excision, or of resection, in which an intermediate portion is excised.

Cases in which the sphincteric apparatus can be saved may be included in the term amputation, as the technique is very similar. One is, however, guided in the selection of the method by the situation and extent of the carcinoma. It must be admitted that there are surgeons who regard amputation as the routine procedure on principle, and only modify the operation to the extent that, when the tumour is situated low down, they bring the bowel down and fix it in the anus; whereas, when the tumour is situated high up they make an iliac, gluteal, or abdominal anus—in short they bring out the bowel in an abnormal position.

It is going too far to reject excision entirely. No one is in doubt as to what is to be done in a case of carcinoma of the pars analis. Here the anal canal and a portion of the rectum two fingers'-breadth above the new growth must be extirpated or amputated. The best method to adopt is that of Lisfranc: incision round the anus and removal of the rectum together with the surrounding fat and glands from the coccyx to the prostate or vagina (occasionally with portions of these organs), and from the inner surface of both sides of the pelvis.

In disease of the rectal ampulla,[2] the anal portion as a rule escapes, the growth being limited to the ampullary portion. In these cases we agree with Rehn that amputation is the normal operation, but we always attempt to preserve the sphincteric apparatus of the pars analis, when the latter is healthy. The rectal ampulla corresponds to that portion of the rectum extending from the pars analis up to the point where the bowel is completely surrounded by peritoneum, and has a mesentery. Tumours in this portion can be distinctly felt from below (at any rate under anæsthesia), and the extent of their mobility or fixation can generally be definitely determined.

Our method of removing the rectum by means of a posterior longitudinal incision with resection of the coccyx is the most satisfactory. It gives excellent access, and always enables one to reach sufficiently far above the growth as is compatible with a proper removal of the diseased tissue including the glands. Besides aiming at preserving the sphincters in these cases, our operation differs from amputation of the

[1] In Korte's cases (Nordmann) there had been only *one* preceding attack in 75 per cent of the cases which ended fatally as the result of recurrent attacks.

[2] Rehn's expression pars pelvina does not distinguish this section sufficiently from the pelvic colon, *i.e.* the intraperitoneal part of the rectum.

anal portion in that the peritoneum is opened, for the latter extends downwards on the anterior wall of the ampullary portion to nearly the upper border of the prostate.

Resection becomes a question of first importance when the carcinoma involves the lower part of the pelvic colon. In these cases, Kraske's operation with partial excision of the sacrum, or its modification with a parasacral incision, introduced by Hochenegg and others, can be employed. Even then, however, excision can only be contemplated when the tumour is either found to be movable or can be easily mobilised by simple division of the peritoneum. Tumours of the pelvic colon can as a rule be felt under chloroform by firm palpation through the abdominal wall, or can be recognised with the proctoscope.

Lastly, there are those cases where the growth extends up on to the pelvic colon and down on to the ampullary portion of the rectum; their mobility is limited and cannot be determined with certainty. They can only be dealt with, with any degree of certainty, by the combined method which Quénu has developed, namely, intra-peritoneal as well as coccygeal (or sacral) dissection in one stage, with total amputation of the rectum and the formation of an artificial iliac anus.

Cases are inoperable when the growth is adherent to the wall of the pelvis or to an organ, such as the bladder, which cannot be completely removed; and also when the growth has given rise to metastatic deposits (most frequently in the liver) or to carcinomatous peritonitis. Palliative measures must then be resorted to, *i.e.* artificial anus (*vide* Enterostomy). With these exceptions, however, the indications for excision of the rectum have been greatly extended in recent years, and it is very rare to find a surgeon opposed to operation in general. Moreover, from the evidence furnished by a number of clinics, it is shown that although the operative mortality is by no means small, the prospect of radical cure is as good in the rectum as in other organs more suited for operation.

In the fourth edition we noted and referred to the statistics of Kraske, Hochenegg, (Pilcher) von Eiselsberg (Prutz), Madelung, Garré (Schneider), Küster (Wendel), v. Bergmann (Wolff), Wölfler and Schuchardt. The immediate results vary greatly, according to the position and extent of the growth. In the more simple cases, the mortality, according to some surgeons, is 3 to 4 per cent, but in the advanced cases, when the combined method has to be used, it amounts to nearly 50 per cent according to Kraske. Rotter's mortality in 24 cases was 44 per cent. Hochenegg lost 3 out of 5 patients from the combined operation, otherwise his mortality was only 6·2 per cent. Mayo's[1] mortality in 19 cases, where Quénu's operation was used, was 26·3 per cent. According to Gross, the mortality from the combined method is only 8 per cent in women, and 80 per cent in men.

On the other hand, Martin du Pan[2] records 25·7 per cent of radical cures in 83 of our cases. Rotter (Petermann)[3] reports 28 per cent of radical cures, while Poppert had 17 radical cures out of 60 cases, and of these 8 were amputations and 9 resections. In the latter the comparison is very equal. Hochenegg (Richter[4]) records 33·3 of radical cures out of 63 patients. Mayo states that of the cases who recovered after operation by Quénu's method, half were permanently cured, and places the percentage of radical cures as 36·8 per cent in all his 19 cases.

As we have stated on a former occasion, the prospect of obtaining a permanent cure increases with the severity or the radical nature of the interference, and consequently runs in some measure parallel to the operative mortality. It is not to be wondered at that Quénu's abdomino-perineal method gives the greatest number of radical cures, for it is an operation to which greater danger is attached, and in which no attempt is made to maintain the normal continence, *i.e.* an artificial anus is made. As the mortality is less by the first three methods of operation, and a good proportion of perfect results may be obtained as regards continence, it must be admitted that Kraske, Poppert, and others, are right in holding that the more conservative methods should be employed, when the surgeon, after careful examination of the case, thinks that a radical cure may be thus obtained. Hochenegg got

[1] *St. Paul's Med. Jour.*, April 1906.
[2] *Thèse de Berne*, 1905.
[3] Langenbeck's *Archiv*, Bd. 80.
[4] *Deutsche Zeitschr. f. Chir.* Bd. 81.

complete continence in 9 out of 29 cases that recovered after resection, and Poppert had 10 cases of union by first intention with complete continence in 20 resections.

158. Technique of Amputation of the Rectum. The preparation of the patient, provided acute obstruction is not present, consists in thorough purgation a few days before operation, and irrigation of the bowel with large enemata. Fluid diet is restricted (no milk), and for the last two days 8 grains of bismuth are administered every three hours and 10 drops of opium three times.

For the historical development of the technique of the operation, reference should be made to the admirable papers of Krönlein and Rehn, read before the twenty-ninth Congress of the German Society of Surgeons in Berlin, 1900. Since Lisfranc performed the first extirpation of the rectum three-quarters of a century ago, great progress has been made, and the credit of having improved the technique of the operation is due more especially to Kraske, who, by introducing the method of gaining access from behind, greatly widened the possibilities of dealing radically with the disease. Rehn drew attention to the importance of an exact knowledge of the anatomy of the parts as demonstrated by Waldeyer, Gerota, and Goldmann.

Rehn agrees with Waldeyer as to the necessity, from the surgical point of view, of distinguishing between: (1) the perineal part of the rectum ("pars perinealis recti"), the firm sphincter apparatus which is closely interwoven with the pelvic fasciæ and muscles; (2) the loose and sacular pelvic part ("pars pelvina recti") which, reaching to the level of the third sacral vertebræ, is half intraperitoneal, and is enclosed in the rectal fascia—a thickening of the subserous tissue which is prolonged laterally to be attached to the pelvis; (3) the pelvic part of the colon ("pelvic colon" of Jonnesco), which is entirely enveloped in peritoneum and has a mesentery reaching to the sacral promontory. In this mesentery is the main artery of the rectum, the superior hæmorrhoidal, which divides into two lateral branches descending under the fascia of the pelvic portion of the rectum. Lower down are the hæmorrhoidal plexus of veins, the lymphatic vessels, and the sympathetic nerves. Between the fascia and the sacrum are the middle and lateral sacral arteries, the sacral venous plexus, the sacral lymph glands, and the spinal nerves.

The lymphatics from the skin of the anus go to the lymphatic glands in the groin, those from the rectal mucosa pass to glands which extend as far as the peritoneal reflexion and lie on the lateral aspect of the rectum in relation to the lateral branches of the superior hæmorrhoidal artery, between it and the fascia propria recti: higher up the glands lie in the mesentery of the pelvic part of the colon.

As we mentioned above, amputation is performed in carcinoma of the anal and ampullary portions of the rectum, *i.e.* in all cases in which the tumour can be reached from below with the finger. Adhesions to the prostate, vagina, or uterus are not direct contraindications, but when there are more extensive adhesions to the bony wall of the pelvis or to a large area of the bladder, operation must be abandoned.

(*a*) *Lisfranc's Perineal Method.* This method is suitable for carcinoma of the anal portion, where the muscular sphincteric apparatus cannot possibly be saved.

A circular incision is made round the anus, through healthy skin, which is dissected up and stitched over the anus so that the orifice of the latter is closed. The edges of the wound are forcibly separated with sharp hooks or retractors, and the whole region thoroughly cleansed with lysol, ether, and alcohol.

The rectum is then freed all round with scissors or the knife guided by the left forefinger, keeping well away from any induration and clamping all bleeding vessels. As soon as the attachment of the sphincter and levator ani is divided posteriorly the tumour becomes more movable. The bulb of the urethra is separated in front, after having passed an instrument into the bladder, by dividing the muscle of Roux at the level of the prostate, after which the dissection is carried upwards between the prostate and the prerectal fascia. If the prostate is adherent, part of it should be removed along with the tumour.

In women, the posterior vaginal wall is detached, but if it is adherent a sufficient extent must be removed along with the tumour. Laterally, the bundles of vessels entering the bowel should be under-run with an aneurysm needle, and tied with

catgut before they are divided, after which the unopened rectum can be pulled down. It is essential that a portion two fingers'-breadth above the tumour-induration be brought down, for it is here that the bowel is to be divided and, avoiding any further tension, fixed in the site of the original anal ring.

The bowel is then clamped with two pairs of crushing-forceps placed two fingers'-breadth above any induration and divided between them with the thermo-cautery, the projecting mucous membrane being destroyed. Before the forceps are removed, the *upper* end of the bowel is stitched to the skin round the anus with catgut sutures, and iodoform gauze is packed in on either side of the rectum, while in front the wound is closed with deep aluminium-bronze sutures. The forceps are then removed, a tampon is inserted into the rectum, and 4 to 6 wire fixation sutures are passed through the whole thickness of the intestinal wall.

Instead of the rectum being stitched in the region of the anus, it may be brought out laterally through the skin of the buttock between the lower fibres of the gluteus maximus (Witzel). A competent gluteal anus is thus formed, a method by which von Eiselsberg has had "good results."

(*b*) *Kocher's Coccygeal Method with a Posterior Median Incision.* In 1875, after Verneuil and Denonvilliers had separately excised the coccyx, we introduced the method we now regard as the normal one, viz. resection of the coccyx through a posterior mesial incision [1] (previously employed by Dieffenbach). Martin du Pan has shown that, notwithstanding all that Kraske has said in favour of the sacral operation, the great majority of surgeons employ, under various names, the coccygeal method. The statistics are also especially good.

We have seen no trouble follow removal of the coccyx, and therefore cannot set a high value on Kehr's method which aims at preserving it. As Wölfler has pointed out, the posterior mesial incision has the advantage of sparing the nerves and muscles of the anus.

The operation is indicated in those cases where the anal portion is intact, but where the disease involves more or less of the ampulla and the portion above the pouch of Douglas, which is completely covered by peritoneum, and which occupies the pelvic portion of the abdominal cavity, *i.e.* the pelvic colon. The method is thus suitable for a great variety of cases, since the ampulla is the principal site of cancer.

The anus is first of all closed with a subcutaneous circular suture which is firmly tied, the parts are thoroughly cleansed with ether and alcohol, and the patient is placed in the lithotomy position with the pelvis raised, or in the right lateral position.

The incision begins 1 inch behind the anus, and is carried in the natal groove on to the back of the sacrum (Fig. 385). The dense fascia covering the coccyx is divided and chipped off close to the bone, first from the sides and then, by pulling back the tip with a sharp hook, from its anterior surface, taking care to avoid the terminal branch of the middle sacral artery. The sacro-coccygeal articulation is then divided, or, if the latter cannot be found at once, the base of the bone is cut across with forceps.

The ano-coccygeal fascia is now split in the middle line, avoiding the transverse fibres of the sphincter ani, and the portion of the levator ani which crosses behind the rectum, and which is of importance in keeping the anus closed (Fig. 386).

This fascia gives attachments to the levator ani, ischio-coccygeus and coccygeus muscles, all of which are pushed aside with it, so far as their attachments to the coccyx are not already separated.

When this fascia has been sufficiently divided and separated, the blunt dissection of the rectum is begun with the finger, care being taken not to keep too near the rectum in case of tearing it, and to remove the fat and glands which are occasionally infiltrated with the disease. The finger is also passed into the ischio-rectal fossa behind and swept along the sides of the rectum, separating the latter along with its fatty fascia from the sacrum and from the fascia covering the obturator internus, until the

[1] *Centralbl. f. Chir.*, 1875.

whole circumference of the bowel, with the new growth and its coverings, can be grasped.

The lateral bundles of connective tissue, which are rich in fat, and which hold the rectum in position, are hooked up with the finger, or on an aneurysm needle, and ligatured on the proximal side, while forceps are applied to the distal ends. The

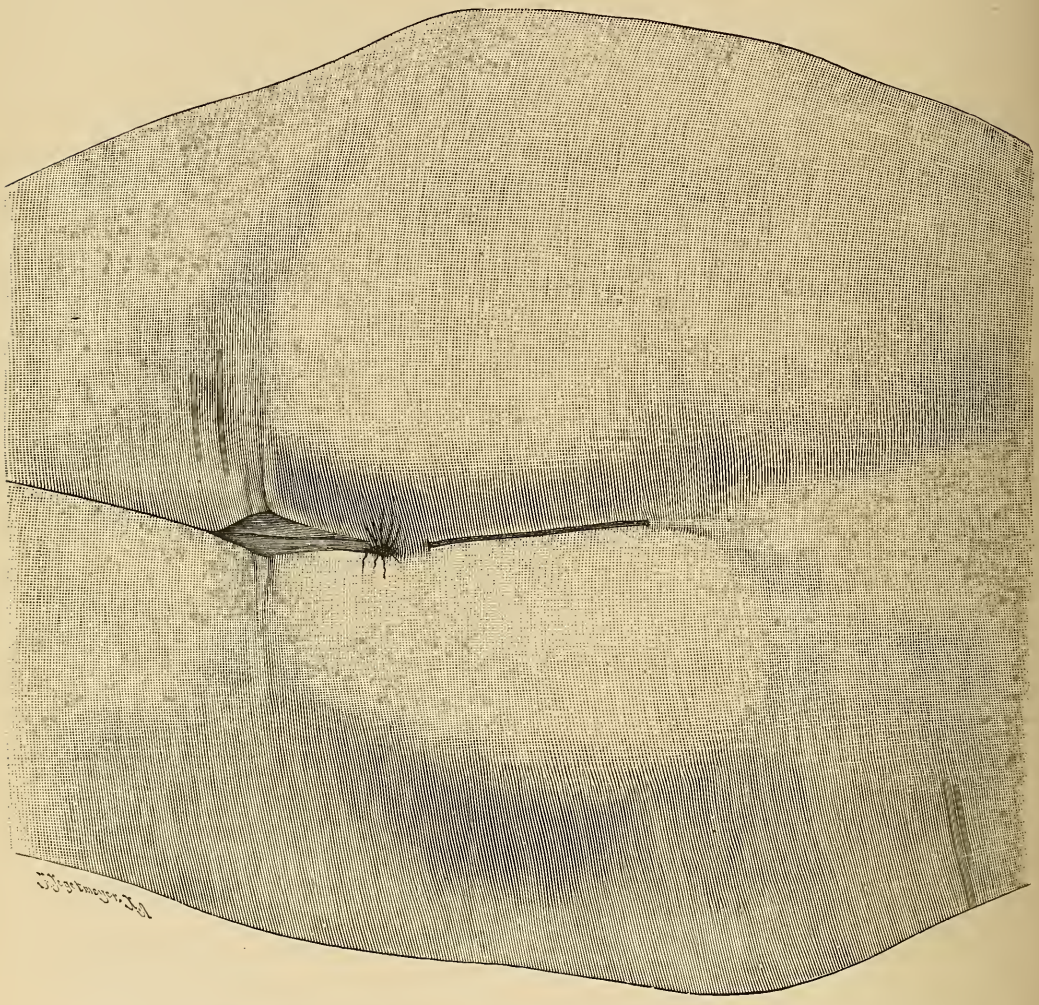

FIG. 385.—Excision of rectum, 1st stage. Patient lying on right side. The anus, after careful disinfection, is securely closed with a subcutaneous circular stitch. The incision is begun above the anus, and carried in the natal groove on to the back of the sacrum.

pouch of Douglas is opened into, as a rule on one side during the lateral dissection, after which the rectum can be easily surrounded with the finger.

It is advisable to expose and open the peritoneum as early as possible. By introducing the finger where the peritoneum has been opened on one side, and passing it round in front of the rectum, the other side can easily be opened, after which it may be freely divided in front of the rectum. Forceps are then applied to the edges of the peritoneum which are subsequently to be sutured. When this has been done the rectum can be pulled down much more easily, and the lateral bundles of vessels from

the superior hæmorrhoidal artery can be put on the stretch, ligatured on the proximal side, and caught with forceps peripherally (*vide* Fig. 387). There is no longer any danger of injuring the rectum. A loop of gauze is passed round the rectum for the purpose of pulling it down.

When the peritoneum has been opened and retracted, and the lateral bundles of vessels divided, the rectum becomes very movable, and the intra-peritoneal portion can be pulled well down, as shown in Fig. 388, where the lower extra-peritoneal portion is seen covered with fat, the upper portion with peritoneum and appendices epiploicae.

If enough has not now been pulled down to allow of two pairs of compression forceps being applied two fingers'-breadth above the tumour, the vessels higher up in

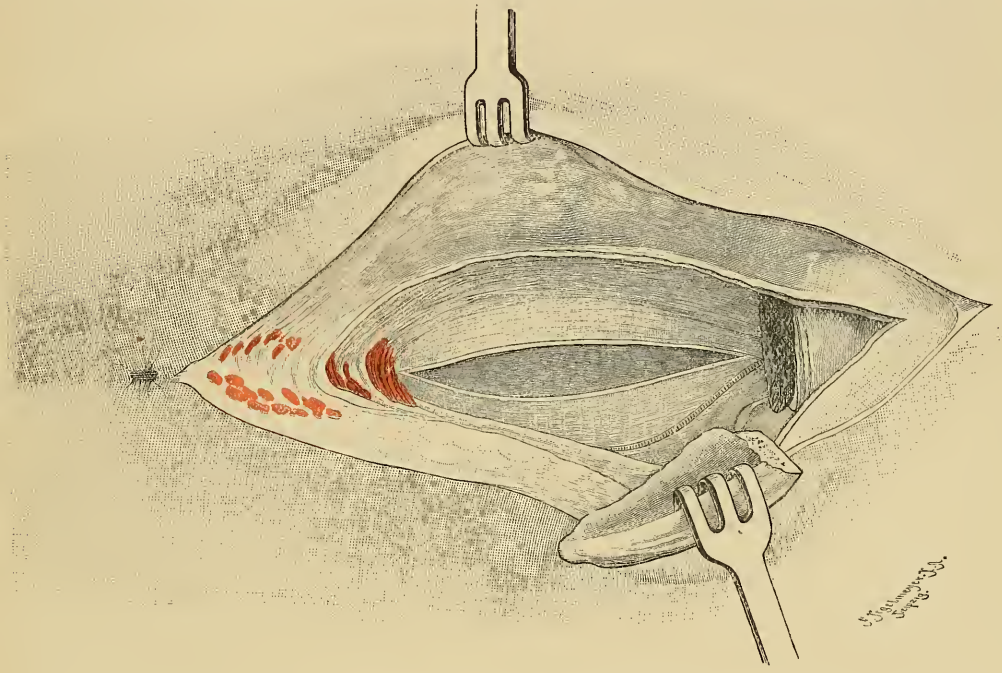

Fig. 386.—Excision of rectum, 2nd stage. The dense superficial fascia has been divided down to the sacrum. The coccyx is detached from the sacrum and turned downwards, exposing the fascia in front of the sacrum, on which a branch of the middle sacral artery is seen. This presacral fascia has been incised as low down as the sphincter ani and the fibres of the levator ani surrounding the rectum. The perirectal fat is seen in the interval between the cut edges of the presacral fascia.

the meso-rectum are hooked down from behind and divided between ligatures. By division of the peritoneum in this way the rectum is readily pulled down (the meso-rectum can easily be divided for a distance of 35-40 mm.).

One has now to determine whether the healthy rectum above is sufficiently free to allow of its being brought down to the anal ring without tension. Two pairs of intestinal crushing-forceps are then applied above the diseased portion, as previously described, *vide* Fig. 389. The upper pair are removed, and a strong silk ligature tied round the groove (the ligature is used subsequently to pull on the bowel to bring it down through the anal ring), after which the rectum is divided with the thermo-cautery between the ligature and the lower pair of forceps, and the mucosa is seared, a protective layer of gauze being packed under it.

The rectum, together with the new growth, is thrown backwards wrapped in gauze,

and completely freed by blunt dissection and scissors as far as the anal portion, all bleeding vessels being secured. This is easily done in women when the vaginal wall is still movable, but in men an instrument must be passed into the bladder before the bowel in front is freed from the prostate.

Contamination of the peritoneum is prevented by plugging with gauze, or sometimes the rent in it may be stitched up immediately after the stump of the rectum has been pulled well down. The object of stitching the upper end of the rectum to the anal portion is to produce the least possible disturbance of function, and at the same time to ensure a proper outlet for the contents of the bowel above. Excision of the mucosa of the anal part (Hochenegg) cannot therefore be recommended as, like the muscle, the mucosa is essential for the preservation of the reflex mechanism. The main thing is to insert the upper end of the gut into the anal ring without the slightest tension, and without the risk of it becoming gangrenous

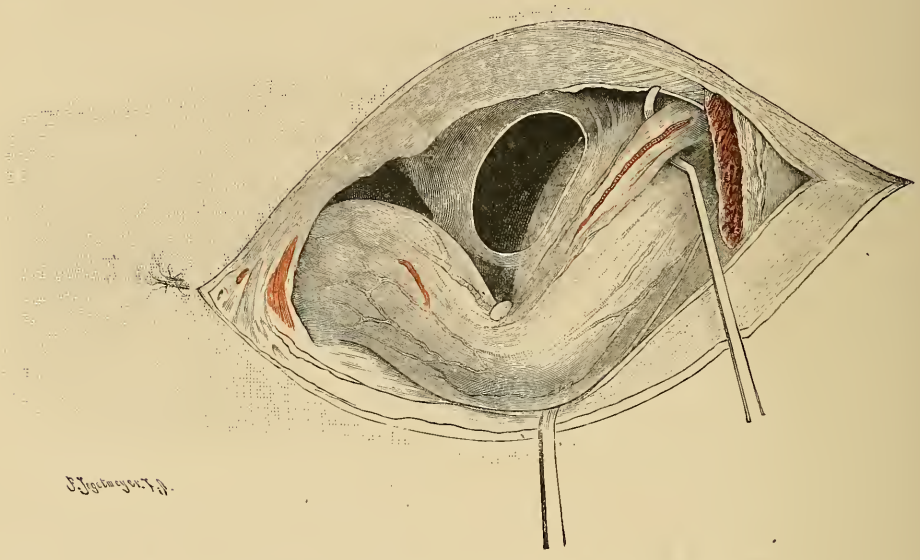

Fig. 387.—Excision of rectum, 3rd stage. The rectum has been freed by blunt dissection with the finger, and drawn downwards and backwards with a retractor. In the upper part of the wound a fatty strand of connective tissue is seen descending on the wall of the rectum, and is raised on an aneurysm needle prior to being ligatured and divided. Anteriorly (*i.e.* above in the fig.) the peritoneum has been opened. Its line of reflexion off the anterior wall of the bowel is well shown.

from being too extensively isolated; and lastly, in stitching it to the anal portion, it is important to pass the sutures through the whole thickness of the wall of the gut so that the junction may be secure.

Crushing-forceps are then applied above the anal portion to prevent escape from the foul ulcer, and the wound is carefully protected with dry gauze. The suture, which was inserted at the beginning of the operation to occlude the anus, is now cut, and the anal portion is dilated with a finger protected with rubber and thoroughly cleansed with lysol. The bowel is then divided below the forceps and the excision completed.

A circular incision is now carried round the anus, and the upper portion of gut is pulled through the anal portion by means of the silk ligature.

Finally the rectum is stitched to the upper edge of the anal portion with interrupted sutures (catgut), which must not be passed too deeply into the upper portion of the gut, nor must they be too numerous for fear of interfering with the circulation. The

bowel has not yet been opened, but now the wound is carefully protected posteriorly with gauze; the ligature on the lower end of the rectum is untied, the lumen packed with gauze, and the edges are stitched through their whole thickness to the edges of the skin incision encircling the anus with aluminium-bronze sutures.

We have also used Murphy's button to unite the anal portion to the rectum.

FIG. 388.—Excision of rectum, 4th stage. The rectum has been drawn out in the form of a loop, after detaching the peritoneum and connective tissue bundles which are attached to it laterally, and which contain branches of the superior hæmorrhoidal artery. The anterior and lateral aspects of the upper part of the loop are covered with peritoneum. The anterior longitudinal band is here seen in front, with the vessels behind. On its posterior and lower aspects (here coloured dark) the rectum is covered with fat. The appendices epiploicæ of the pelvic colon are shown in the upper angle of the wound.

The stitching of the anal portion to the end of the rectum is made much easier if the former is split posteriorly, but this interferes with the subsequent function. It is chiefly employed when only the mucous membrane is to be extirpated by Hochenegg's method, for otherwise this is very difficult.

The posterior wound is closed with deep aluminium-bronze wire sutures, leaving

only the lower end open into which iodoform gauze is lightly packed behind the rectum. If the wound has not been contaminated at all, a glass drain is sufficient.

Septic Excision of the Rectum. *(c) Septic Excision (or Resection) of the Rectum by a Longitudinal Incision through its Posterior Wall.* Long before Quénu and Baudet we drew attention to the desirability of excising the rectum as a closed tube (see earlier editions of this work), as it is only in this way that the operation can be really aseptic. (Compare the precautions mentioned in the above description of the coccygeal operation.)

Occasionally, however, one has to depart from this rule. This is so, first of all,

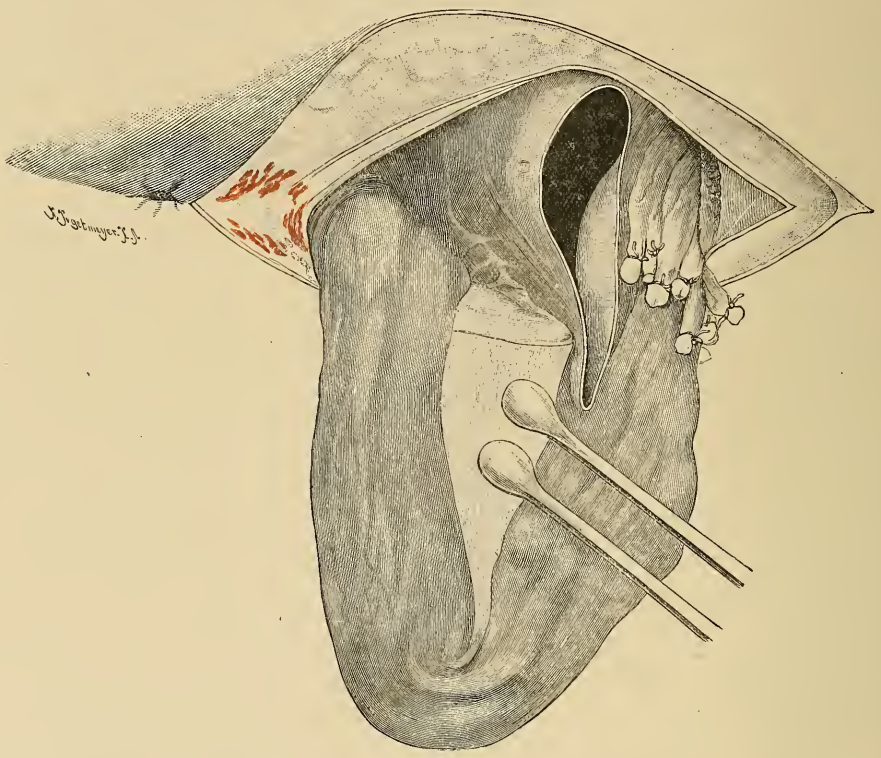

Fig. 389.—Excision of rectum, 5th stage. High amputation by the coccygeal method. The peritoneum is opened and drawn upwards, the lateral and posterior strands containing the vessels are ligatured, and the crushing-forceps are applied above.

if the rectum is torn at any point owing to the infiltration (in extensive ulceration) or to difficulty in separating the perirectal tissues. As a result the wound becomes contaminated with intestinal contents. It is then decidedly better to at once split the rectum through its posterior wall up to the tumour, as is done in the method originally introduced by Dieffenbach.

By catching the edges of the bowel with suitable forceps, *e.g.* Kocher's artery forceps, serious hæmorrhage is controlled, and at the same time good access is got to the ulcer, the rectum can be thoroughly cleansed, and a tampon inserted above the tumour. A finger protected with rubber is then passed above the new growth, which can be easily pulled down and evaginated through the gaping wound.

We have had good results with the following procedure :—The outer layer of the artificially-produced intussusceptum is divided transversely 3 cm. from the distal edge of the tumour. The incision, which traverses the wall of the bowel from its

mucous to its peritoneal aspect, is commenced anteriorly and continued round its circumference, the bleeding vessels being caught with forceps as they are divided.

By isolating, ligaturing, and dividing the vessels entering the bowel on its posterior and lateral aspects, the tumour can be more and more pulled down, until it is possible to divide the bowel 1½ to 2 inches above any induration. The division of the bowel on the proximal side of the tumour is also begun anteriorly, the incision this time, however, passing through the gut from its serous to its mucous surface. The proximal and distal cut edges are united step by step with catgut sutures, which traverse the whole thickness of the bowel. Escape of fæces is prevented by the tampon.

It is unnecessary to repeat that the upper portion of gut must be pulled well down, so that there will be no tension when it is stitched to the lower end.

Now comes the main difference from the aseptic procedure :—The edges of the gut are united with interrupted sutures to the skin along the whole length of the posterior longitudinal incision ; this arrests the bleeding and at the same time guards against the evil results of infection better than in any other way. The removal of the presacral glands and fat leaves a space which must be packed with iodoform gauze.

Although prolapse of the rectum subsequently occurs, and renders a second plastic operation necessary, the immediate results of this operation are very good, and it gives rise to the least inconvenience to the patient during the after-treatment.

(*d*) *Excision of the Rectum with Vaginal Section.* The method of excising the rectum in women through a vaginal incision must also be considered here as it is not a strictly aseptic operation. Rehn and Liermann, Murphy, and Schuchardt have introduced the vaginal method for high excision of the rectum in women, and look upon it as the normal procedure. It is undoubtedly the case that division of the posterior wall of the vagina from the vaginal part of the cervix to the frenulum offers very convenient access, and we, too, consider that it is advantageous for all cases of rectal carcinoma which can be felt *per vaginam*, *i.e.* when the tumour is adherent to the vagina or uterus.

From the vaginal incision the dissection is carried laterally down to the anterior rectal wall, and, by means of an incision on either side of the anus, it is carried deeply into the ischio-rectal fossa, by which means free access is obtained. Liermann attaches special importance to this backward extension of the incision, and Schuchardt points out the importance of making full use of it in his method of extirpation of a carcinoma of the uterus. The circuit of the rectum is made by Liermann rather more than an inch from the anus, and separation of the rectum is proceeded with from this point. The further procedure is described below.

Eiselsberg also considers the vaginal method very useful, and he points out that he is often able to remove at the same time part of the vagina or uterus. This is the advantage peculiar to this operation. Where there is a suspicion that a rectal carcinoma has involved vagina or uterus, the vaginal operation should certainly be selected as it allows of free removal of all the disease. Gynecologists (Krönig and Friedrich), in cases of primary carcinoma of the vagina, go so far as to demand an *a priori* excision of the rectum, because of the frequency of recurrence in its neighbourhood. If the vagina and the region of the cervix are involved, it is necessary to remove the lymphatic glands which lie at the bifurcation of the common iliac artery, as they receive the lymphatics from these parts. The chief feature of the operation is that Schuchardt's paravaginal incision is used when the rectum and uterus have to be excised at the same time. The vaginal incision naturally depends on the extent of the adhesions. Excision of the rectum may make other incisions necessary in addition to the paravaginal incision, or a combination with laparotomy may be required (*vide infra*).

159. The Sacral Method of Amputating the Rectum. Kraske must be regarded as the pioneer of modern operative measures for the removal of the rectum, on account of his communication on the sacral method delivered at the Berlin Surgical Congress in 1885. By proving that part of the sacrum can be removed, as a rule without ill effect, and that thereby the highest portion of the rectum can be made accessible for operation from behind, he has made a lasting advance.

The value of his work is not detracted from even now when it has been recognised that in the majority of cases resection of the sacrum is unnecessary. One has only to look through the publications issued by German clinics for the last six years, to see that the sacral method is being more and more abandoned in favour of the coccygeal method. N. Senn describes the sacral operation as not only unnecessary but "absolutely harmful." He employs resection of the coccyx as a general rule, but often does without even this preliminary.

We have not found it necessary to perform the sacral operation for many years, and therefore shall not describe it in detail (for a full description, see Kraske's publication). Neither will we consider its modifications, *e.g.* Hochenegg's parasacral incision, or the osteoplastic transverse division of the sacrum, as the chief objection to all sacral operations is, not merely that they are not necessary for the customary excision of a tumour of the rectum accessible from below, but that in difficult cases of a highly situated carcinoma, which is not very movable, an operation has been introduced (the so-called combined method) which is steadily gaining ground, and is, indeed, regarded as the normal operation by a number of surgeons.

160. The Combined Method[1] of Amputation of the Rectum. (*Abdomino-perineal, Abdomino-coccygeal, and Abdomino-sacral Method.*) For a historical survey of this operation we refer the reader to the works of Ito and Kunika,[2] Gouillod and Faysse,[3] and to the discussion on the subject introduced by Kraske at the German Surgical Congress in 1906.

According to Kraske, the method was proposed by Volkmann and first performed by König. Quénu utilises the combined method to its fullest advantage. His method consists in laparotomy, division of the pelvic colon well above the tumour and of the diseased glands in the mesentery, fixation of the upper end into the abdominal wall as an artificial anus, and removal of the lower rectal portion down to the anus, even should it be 12, 16, or 24 inches long. The rectum is removed as a closed tube, or as Quénu says, "comme un cyste," along with its mesentery, perirectal fat, and glands.

It is obvious that in this way not only can the diseased bowel, and the tissues directly implicated by the growth, together with suspicious lymphatics, be removed, but the groups of glands in the meso-rectum above and to the inner side can be cleared out more thoroughly than by any other method. As Hartmann states, the clearing-out process is only limited by the pelvic wall and adjacent organs. Further, there is less risk of tearing the gut[4] during its separation, *i.e.* the operation will be thoroughly aseptic. Lastly, the main vessels of supply can be ligatured within the abdomen. According to Giordano and Quénu, both internal iliac arteries may be tied.

It is to be conceded *a priori* to Quénu and the supporters of his method that a greater number of radical cures are obtained by the combined operation than by less drastic procedures, although as yet there are not a sufficient number of cases to afford suitable comparison. At the same time the radical cures have been obtained at the cost of the certainty of the immediate result. Gouillod and Faysse, who strongly advocate Quénu's method, estimate the mortality as 6·2 per cent in women, and 66·6 per cent in men, from a series of 31 cases of which 16 were women and 15 men: Ito and Kunika place the mortality as 9 per cent in 22 women, and 64·3 per cent in 28 men. These statistics, therefore, show that the total results are materially worse than after the coccygeal or perineal method. Rotter's mortality out of 25 cases was 44 per cent. In addition, in very extensive excisions, the bladder is liable to be injured. Those injuries occurring in cases of resection are of a transitory nature (Brüning). W. J. Mayo,[5] using a modification of Quénu's method in 19 cases, has had a mortality of 26·3 per cent, and 50 per cent of radical cures among the survivors, which is equivalent to 36·8 per cent of radical cures on all cases operated on. Jaffé in cases of

[1] We follow Rotter in using this very simple designation.

[2] *Deutsche Zeitschr. f. Chir.* Bd. 75.

[3] *Revue de chir.* July 1905.

[4] Hartmann considers that the greater operative mortality in men is due to the fact that it is much more difficult to separate the bowel anteriorly without causing tearing, as the bladder, prostate, and urethra early become adherent.

[5] *St. Paul Med. Journ.* April 1906.

simple resection has found implantation metastases in the lower end of the rectum in 10 per cent of his 30 cases.

To sum up: The typical perineal and coccygeal excisions described above must be regarded in the meantime as the best for malignant disease of the rectum where the tumour is easily palpable from below, and where its mobility can be determined. When, however, the tumour is situated higher up, and information cannot be gathered as to its extent and mobility, the combined method can furnish results obtainable by no other methods.

Technique of the Combined Method with Amputation of the Rectum. We need not describe the details of the technique, for the method consists in amputation, with the formation of an artificial anus at the upper part of the pelvic colon, as already described, with the addition of removal from above of the lower portion of the pelvic colon.

A loop of the upper part of the pelvic colon is brought out through an incision similar to that recommended for colostomy and is clamped with two pairs of crushing-forceps. The lower pair are taken off, the bowel is ligatured and cut across close to the upper pair, the mucous membrane and the redundant tissues of the stump are excised, and the latter is invaginated first with a sero-muscular suture and then with a serous layer as described in resection of the intestine (*e.g.* ileo-cæcal resection). The bowel is then freed by passing an aneurysm-needle underneath it and ligaturing and dividing as much of the mesentery as is necessary to permit of the closed end being replaced inside the abdominal cavity. The forceps are left on the upper end.

The incision is now prolonged two fingers' breadth above Poupart's ligament as far as the middle line, ligaturing the superficial and deep epigastric arteries (the latter lying on the fascia transversalis), and dividing the insertion of the rectus (or if necessary of both recti) into the symphysis pubis. In this way ample room is got without inflicting much injury, and a hernia is subsequently prevented by careful suture of the abdominal wall in layers.

Rotter, Brüning, Gouilloud, and Faysse state that better access is given by an incision in the middle line. The latter is necessary if one intends to follow Quénu and ligature both internal iliac arteries, but personally, we agree with Rotter that ligature of both internal iliacs is not necessary, as the bleeding can be adequately controlled by using a sufficient number of artery forceps. We consider, however, that as a rule, the median incision gives better access, and for this purpose a large retractor is very useful for widely separating the edges of the wound.

The mesentery of the pelvic colon is now divided from the inguinal incision and the bowel mobilised (there may be firm adhesions along the upper and inner surface), after which the vessels (sigmoid and superior hæmorrhoidal [1]) are isolated with the finger or an aneurysm-needle, tied in bundles, and the lower part of the bowel freed, forceps being applied to the distal ends of the vessels.

The bowel is freed in this way along the mesentery of the lower part of the pelvic colon, taking care to remove along with the growth any glands in the neighbourhood. Mayo ligatures the middle sacral artery and cleans out the fat and glands down to the periosteum covering the hollow of the sacrum. Rotter points out that this can be done by blunt dissection as far as the levator ani. The peritoneum forming the floor of the pouch of Douglas is then divided and the rectum freed all round, while the bladder and prostate (or vagina) are dissected off it in front. Rotter has even removed a portion of the bladder without harm. Laterally the vessels may be torn through with blunt dissection (Rotter). The tear in the peritoneum is repaired by suture so as to form a new pouch of Douglas, and the peritoneum is stitched over the raw surface underneath the flexure. As a rule, however, a gauze tampon should be placed in the depths of the pelvic wound in order to keep the peritoneal cavity shut off while the separation is being continued from below.

This finishes the part of the operation performed from above, and the abdominal wound is closed in layers. The upper portion of the bowel is still retained in the

[1] Mayo speaks of ligature of the left inferior mesenteric artery above the promontory. Is it not the superior hæmorrhoidal, after the left colic is given off, which is meant?

grasp of the forceps in the upper angle of the wound, and a part of the wound, for a distance corresponding to the diameter of the gut, is left open (if a mesial incision is employed, one need not trouble at present about the small incision for the iliac anus), after which the peritoneum alone is stitched to the serous coat of the bowel all round, about two inches beyond the forceps.

Up to this point the patient has been in the Trendelenburg position, but now, for the second stage of the operation, he is put in the lithotomy position, the perineal operation being used for a carcinoma situated low down, and the coccygeal for one higher up. An incision is made round the margin of the anal orifice, which is then closed with a firm ligature. The cavity is plugged so that it may heal slowly by granulation. The bowel, stitched in the abdominal wall, is opened, according to the rules given under enterostomy, and a glass tube fixed into it, from which the contents are led off by a large rubber tube. One or two days should elapse before it is opened; Mayo waits twenty-four hours.

161. Resection of the lower part of the Pelvic Colon. Resection of the lower part of the pelvic colon, as distinguished from amputation, is called for when there is a prospect of performing the operation aseptically, as otherwise the stitches will not hold. It has, therefore, in the first place to be considered for the removal of the lower part of the pelvic colon where the divided bowel is completely covered by peritoneum and can be freely isolated, the ends closed, and a lateral anastomosis made with two or three layers of sutures. Schloffer strongly advocates resection from above, but we only consider it a safe procedure when the above conditions can be fulfilled.

The same rules must be followed here as in resections of other parts of the large intestine. First of all, the contents of the intestine above must be emptied "in toto" by means of an artificial anus.[1] The question of ileo-proctostomy is only to be considered in exceptional cases, when it is possible to bring a loop of ileum in contact with the rectum below the site of suture.

The technique of this method is similar to that of the combined method. An incision is made over the outer third of Poupart's ligament, the upper part of the pelvic colon is pulled out, and an artificial anus made by cutting it across and inserting a glass tube in each end.

The incision is then extended towards the middle line, or what is even better, a separate mesial[2] incision is made, and the tumour thoroughly examined. If it is found that the tumour along with the mesentery of the pelvic colon can be freed sufficiently to allow of the removal of glands and infiltrated tissues, and that sufficient healthy bowel can be got below, after removing the tumour, to join with the bowel above, then resection should be preferred to amputation, for the former operation has the advantage that there is no disturbance of defæcation.

Rehn has shown on anatomical grounds that in separating the vessels in order to free the bowel preparatory to resection, the mesentery should not be divided close to the bowel, as the terminal anastomosis takes place close to the bowel. Further, as in amputation, it is most important to have the ends of the gut so free that there will be no tension when they are sutured together, for, according to Rehn, tension interferes with the circulation even more than the division of vessels. Tension on the superior hæmorrhoidal artery may cause kinking at the point where the inferior mesenteric is given off.

A large tube should always be passed down to the pouch of Douglas, and it is advantageous to thoroughly wash out the lower end of the gut by passing a large glass tube through the anus before closing the abdominal wound.

Resection of the Rectum. The method of resecting a circumscribed carcinoma in the rectum, *i.e.* in the ampullary portion of the rectum, has been described in the appendix to the coccygeal method under septic excision of the rectum. In our experience, it is as safe an operation as amputation in regard to immediate results.

[1] In one of Goldmann's cases, enterotomy had to be performed subsequently, on account of symptoms of ileus after resection.

[2] Brüning as well as Gouillod and Faysse are in favour of the mesial incision.

The danger of fæcal soiling of the wound followed by infection and cellulitis is avoided by uniting the gut only along its anterior aspect and providing for the escape of the intestinal contents posteriorly by stitching the mucous membrane to the skin.

It is a different question whether, after freeing the rectum from behind and isolating a tumour situated below the peritoneal reflexion, or higher up where the bowel is only covered on its anterior surface by peritoneum, one ought to undertake a resection with circular suture. Suture in the circumstances often succeeds and gives very satisfactory results. We have got perfect union in these cases with a Murphy's button as well as with suture. Nevertheless, every surgeon of experience will admit that one cannot count with certainty on healing taking place by first intention, and one must always be ready on the slightest sign of the suture giving way with escape of fæces to interfere, otherwise one will be guilty of gambling with the life of the patient.

An artificial iliac anus must either be made beforehand, and the fæces entirely prevented from entering the rectum, or a large strong tube must be passed into the rectum above the site of suture and the fæces led off as long as there is a large raw surface. In addition, there is the risk of a fæcal fistula forming. This, however, closes whenever a free escape downwards is established. We advise suture with silk of all but a portion $\frac{1}{2}$ cm. wide, and a longitudinal incision upwards and downwards at this point to admit the tube, since in this way the site of suture is made wider.

At the very least, and this is the usual practice, a wide track to the surface must be kept open by packing right down to the seat of suture. When a large Murphy's button is used, we endeavour to prevent accumulation of fæces above it by passing as large a tube as possible *per* anum through the lumen of the Murphy's button and irrigating frequently.

It must be emphasised, however, that (with the exception perhaps of a small circumscribed tumour situated at the lower limit of the pelvic colon) it is better as a rule for the operator to perform amputation of the rectum down to the anal portion, preserving the sphincter and levator ani, and making the anastomosis here without tension. The functional results by this way are equally good, and the dangers from defective suturing are avoided.

Further, by this low supra-anal anastomosis, the treatment of all types of fistulæ (division) and strictures (dilatation and plastic operation) is greatly facilitated.

The Combined Method for Resection of the Rectum. This method can be used as a substitute for the radical operation of Gaudier and Quénu. It differs from the latter, however, in that, while the pelvic colon is separated through a mesial incision in an exactly similar manner, it is not cut across and utilised as a permanent iliac anus, but is pulled down and united to a healthy portion of the rectum lower down.

From evidence derived from Schloffer's statistics and Ito and Kunika's publication, Brüning (*loc. cit.*) has made a comparison between the dangers of the combined method for amputation and resection. In 38 cases where the former was used, he finds a mortality of 45 per cent, and in 25 cases of the latter 52 per cent. There is, therefore, not a great difference between the two methods as regards mortality. In women amputation gives rather better results.

Brüning holds that the invagination method introduced by Trendelenburg, Kümmel, and others, and recommended by Maunsell, in which the tumour is mobilised from the abdomen and evaginated through the anus, so that the resection is entirely extra-anal, with subsequent reposition, should be rejected on account of the results. Its mortality in 9 cases is 66 per cent. The invagination is often very difficult and involves very extensive separation, stretching, and tearing of the tissues.

We will here only deal with the combined method in regard to cases where the tumour is first mobilised intra-peritoneally, then exposed by our coccygeal method from below and resected, with union of healthy intestine above to healthy intestine below.

It is unnecessary to refer again to the statements we made in connection with resection of the extra-peritoneal portion of the rectum, and to further emphasise

that healthy gut be pulled down and joined to the upper part of the anal portion since this merely depends on preservation of the latter; and, according to Rehn's observation, the flexure can more easily be mobilised in so free a manner that it can be united to the anal portion without any tension and therefore without interference with the circulation. We therefore consider sigmoideo-anal anastomosis the best method, particularly if there is a question of employing the combined method on account of the high situation and extent of the tumour.

Kümmel[1] has shown that the nutrition of the transverse colon is even less affected by division of its mesentery than is the pelvic colon, since a marginal artery running in a wide arch gives off the vasa recta to the gut: de Quervain[2] has employed Kümmel's method with success. The accompanying figure (Fig. 390), taken from Gegenbauer's *Anatomy*, will illustrate the justification of extensive division of the transverse mesocolon and the mesentery of the descending colon between the middle and left colic arteries, and even farther down, if it is desired to sacrifice the whole of the intestine below.

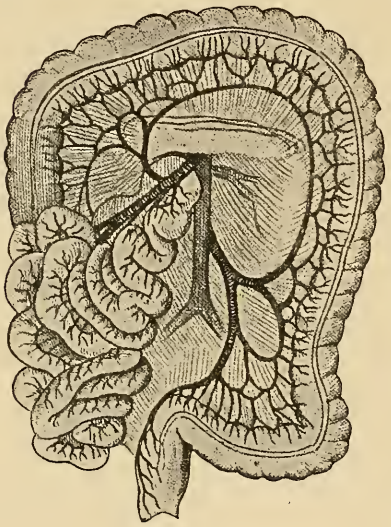

Fig. 390.

Rotter draws attention to the advantage of the combined resection method over the radical operation with the formation of an iliac anus. Even in cases when resection proved either impossible (14 out of 25 cases) or the lower part of the intestine became necrotic and a sacral anus had to be made, Rotter was able at a subsequent operation to establish complete continence in the majority of the cases by means of circular suture and a plastic operation.

162. Excision of Hæmorrhoids. When hæmorrhoids cause trouble they should be at once removed. If an operation is to be performed it is essential that anæsthesia should be complete to allow of the anus being fully stretched so that the upper bunches of hæmorrhoids can be thoroughly brought down into view. The method of removing the masses by cutting them off (Langenbeck and Smith used the Paquelin cautery), after applying a wing-shaped clamp, is open to the risk of serious secondary hæmorrhage, although Baracz recently speaks in favour of it. We have, however, never seen injurious effects follow ligature and removal of the distal part of a hæmorrhoid, provided that the stump left to necrose is not too large. To avoid this the following methods should be adopted :—

(*a*) *Method by Ligature.* The anus is stretched after the patient is well anæsthetised. The prominent bluish masses are now seized with powerfully-closing ring forceps, which should be similar to pressure-forceps, with the ring of an ovoid shape, the narrower part being at the free end. After the base of the mass has been crushed with these forceps, a catgut ligature is passed through the pedicle and carried first round one side, and then, as the forceps are removed, it is tied round the whole of the crushed base, and the superfluous tissue is cut off. By this means all tissue containing fluid beyond the ligature is removed and the liability to gangrene from sepsis originating in it is prevented. Each mass is treated in a similar manner. A bismuth suppository is introduced thrice daily, and the bowels are prevented from acting by rigid attention to diet and by opium.

(*b*) *Injection Method.* Instead of the operator ligaturing and removing the piles after seizing them with fine curved forceps, a strong solution of carbolic acid (20 to 50 per cent in alcohol) or of gelatine (2 per cent) may be injected.

[1] *Berliner Chirurgenkongress*, 1900. [2] *Revue médicale*, 21st annual volume.

(*c*) *Excision by Whitehead's Method.* The method described by Whitehead of extirpating hæmorrhoids, together with the mucous membrane of the anal canal, is attractive on account of the neatness of the operation, which may be done under cocaine anæsthesia. We perform it as follows:—As soon as the patient, by straining, has forced out the bluish-red folds of the mucous membrane containing the varicose veins, an incision is made at one side of the anal margin at the junction of the skin and mucous membrane, and the latter is grasped with forceps and pulled down. Projecting from the outer surface of the mucous membrane are the varicose masses, which, as a rule, can easily be separated from the sphincter.

The mucous membrane, which has been freed and pulled down, is now divided transversely above the level of the piles, and the healthy mucous membrane above is at once stitched with interrupted catgut sutures to the anal margin, and this is repeated until the whole diseased mucosa of one side is excised and the healthy mucous membrane above it is united to the anal margin. The same procedure is carried out on the other side. In this method of performing the operation, hæmorrhage is reduced to a minimum. If care be taken to introduce the stitches so as to include the whole of the floor of the wound, no after-hæmorrhage takes place into the tissues. Bismuth is applied to the sutured surface and, as recommended above, a bismuth suppository is introduced thrice daily and the bowels are kept confined.

This operation removes the piles very completely, and the healing is very satisfactory. It is, however, not always easy to strip the mucosa and the varicose veins quite cleanly from the sphincter, and when the varicosities are very large and reach high up, a dense circular scar cannot be avoided. Even in simple operations of this kind, the scar is always indurated because it is not formed asceptically. In spite of every precaution, slight infection and inflammation, with cutting of the stitches, as a rule occurs. In these cases the result is anal stenosis, which for a long time causes the same discomfort to the patient as accompanies a fissure, especially if one or other of the stitch-ulcers remains open. The condition is aggravated if the patient dreads and strives to prevent a motion of the bowels.

In consequence of the occurrence of such complications, we have found it necessary to modify considerably Whitehead's method, and we now only employ it in its typical form in exceptional cases. M'Burney[1] disapproves of Whitehead's operation on account of the danger of a stricture forming, and only excises single hæmorrhoids, never more than 2 or 3. The anus must be capable of dilatation to a considerable degree if the bowel is to be emptied without inconvenience. This is impossible if the anal margin is the site of a circular scar, no matter how fine. On this account the ligature method is, as a rule, to be preferred.

On the other hand, it is quite permissible to separate and ligature isolated piles by small incisions in the anal margin. Tags of skin, which are frequently met with, may be excised, and the mucous membrane is stitched to the skin.

163. Operation for Prolapse of the Anus and Rectum. The majority of cases of prolapse of the anus in children can be remedied in a short time by curing the diarrhœa or constipation, and employing cold douches to tone up the levator ani and sphincters and by replacing the prolapse immediately after its descent.

In adults, on the other hand, after a time the lax tissues become œdematous, the mucous membrane comes down after every stool, and protrudes in a fold, as in the case of hæmorrhoids.

The simplest method of dealing with these cases is often to seize the fold in ring-forceps (applied in the long axis as for hæmorrhoids) and then transfix, ligature, and cut it off. Langenbeck's method is much less reliable on account of the risk of subsequent bleeding.

In the more severe cases of rectal prolapse, steps must be taken to restore the muscular resistance of the pelvic floor. For, according to Waldeyer, the prolapse originates like a hernia either because of the congenitally-low position of the pouch of Douglas, or because the latter sinks down as a result of pressure on and stretching of the muscles forming the floor of the pelvis. In other words, the anus becomes a

[1] *New York and Philad. Med. Journ.*, 1905.

hernial orifice, through which the mucous membrane or the whole wall of the rectum is protruded by the force of the intra-abdominal pressure.

The extent to which the whole perineal and anal region bulges under strong pressure is easily seen in children: in adults with weak muscles the conditions are similar. In the early stages, therefore, the question is one of limiting the stretching of the pelvic floor.

Thiersch has described a simple operation in which the calibre of the anal ring is reduced (like the orifice of a hernia) by passing a thick silver-wire suture threaded on a curved needle subcutaneously round the anus, the wire being left in position.

Verneuil first attempted to reduce the circumference of the rectum by cutting a triangular flap, the base of which is at the anus and the apex at the coccyx, and stitching the muscular coat transversely. The benefit of the operation, however, lay in the fact that the stitches were passed transversely through the skin at a high level; in other words, a rectopexy was performed at the same time. This method had been extended by Gérard Marchant, who passed the stitches through the sacro-sciatic ligament, while Cuneo in addition performed a temporary resection of the coccyx. Duval and Lenormant completed the suture of the levator ani and employed Marchant's plication suture of the rectal wall.

Hoffmann [1] attains the same object by making a)—(-shaped incision behind the anus, and exposing the sphincter and posterior fibres of the levator ani, after which he stretches the wound out antero-posteriorly with sharp hooks, and sutures it transversely in layers. Helferich [2] employs a crescentic incision behind the anus, and detaches the sphincter ani on both sides so that they can be slid over one another and thus shortened, in which position they are sutured.

It is easier to employ a posterior mesial incision as recommended by Gérard Marchant, in opposition to Verneuil, and through it to expose the sphincters and posterior fibres of the levator ani and the coccygeus. These muscles can then be shortened by means of a suture, and in a similar way the sphincter in front of the anus, as well as the recto-urethralis muscle (Roux) can also be shortened, so that stretching is impossible.

This operation inflicts less injury than Kehrer and König's method of excising a wedge-shaped portion of the anus and rectum, and it has the further advantage that no sensitive scar is formed in the region of the rectum itself, as the mucous membrane is left intact.

Strengthening the pelvic floor, even if combined with rectopexy, is not enough in a severe case of prolapse of the rectum. When it is not merely the mucous membrane, as in prolapsus ani, or only the lowest part of the rectal wall that is prolapsed, but when the rectum is evaginated from above and escapes through the anus, the displacement must be prevented by anchoring the bowel high up, or by excising the movable portion.

Rectopexy is one of the suspension operations, but in reality its value consists in shortening the muscles and making a strong posterior support for the rectum. It is always worth while to fix the sutures to the coccyx at the same time.

Colopexy is another matter. Proposed by Jeannel, simplified by Verneuil, and independently carried out by Bogdanik and Tuttle, it has up to the present time given good results when properly performed. Lenormant [3] was able to collect 101 cases in which it had been employed (108 operations) without a fatality. One case died of hæmorrhage from a duodenal ulcer which was present at the time. He is fully justified in stating that the numerous objections to it that have been raised, viz. the danger of ventral hernia, volvulus, and internal strangulation, are largely of a theoretical nature, and are in part attributable to imperfect technique.

On the other hand, Lenormant has come to the conclusion that recurrence took place in nearly half the cases which were observed for one year. It is therefore important to select each case after a careful examination, while, according to Ott and

[1] *Centralbl. f. Chir.*, 1905, No. 35. [2] Biefinger, Inaug. Dissert., Kiel, 1903.
[3] *Revue de chir.*, Paris, Feb. 1907.

Hoffmann,[1] it is probably better to combine the operation with reconstitution of the perineum.

We agree with Lenormant in recommending an additional plastic operation on the perineum in front of the rectum, using a transverse incision and stitching the levator ani longitudinally with deep stitches; and a similar operation performed behind (Hoffmann) but with a simple transverse incision and longitudinal suture of the muscles.

Technique of Colopexy. An incision, 4 to 6 inches long, is made above the outer two-thirds of Poupart's ligament, dividing skin, superficial fascia, and the aponeurosis of the external oblique. The superficial epigastric artery is ligatured. The fibres of the internal oblique and transversalis muscles are split, and the transversalis fascia is divided and the peritoneum opened.

The pelvic colon, which is occasionally found to be abnormally long and free, is pulled forward and its lower part drawn upwards, while an assistant controls the amount of traction *per* rectum. When satisfied that the rectum can be pulled upwards and put on the stretch, one proceeds to suture.

We do not see any advantage in excising a portion of the pelvic peritoneum; we prefer to proceed at once to stitch the serous coat of the bowel to the peritoneal covering of the anterior abdominal wall below the incision for a length of 4 inches. The bowel is pulled firmly up and carefully applied to the iliac fossa while this is being done, and over the first row of stitches a second row may be inserted, so as to include the fascia at a point where there are no vessels or nerves.

The risks of the operation are greatly increased if the bowel has to be opened for disease of its mucous membrane (as in Jeannel's first method), or if resection of the long pelvic loop is undertaken to avoid the possibility of volvulus or kinking. Unless there are absolutely definite and urgent indications, it is well to avoid anastomosis, resection, or the formation of an artificial anus.

Resection of the prolapsed gut without colopexy is a different matter. The method which has been chiefly developed by Delorme and Rehn has given good permanent results in suitable cases, but is not free from the dangers of infection and stenosis. Total circular resection, as practised chiefly by Mikulicz, is suitable for cases in which, as the result of congestion and inflammation, there are considerable changes in the prolapsed portion of bowel, such as thickening, ulceration, and narrowing of the lumen.

If excision of the diseased prolapse is decided on, it is very essential to see that the divided edges of the bowel above and below are healthy preparatory to undertaking anastomosis. After replacement of the intestinal coils which occupy the prolapsed pouch of Douglas, two strong stays are passed through the whole thickness of the edges of the gut at the apex of the prolapsed bowel which is forcibly pulled down and clamped transversely. The bowel is then cut across by dividing first the mucous membrane, then the muscularis, and finally the serous coat (as far as the latter comes into the prolapse).

The larger vessels on the posterior aspect of the bowel are tied, and after a thorough cleansing with lysol the edges of the wound are sutured, silk being used for the serous and muscular coats and catgut for the mucous membrane.

The sutures are first introduced in front where the pouch of Douglas extends lowest, a continuous suture being employed in such a way as to bring two broad surfaces in contact. Over this a continuous hæmostatic suture is inserted which includes all the coats with the exception of the mucous membrane, the latter being united separately with a continuous catgut stitch.

When it is impossible to clamp the bowel securely above, we begin the excision in front, cutting through the mucous, muscular, and serous coats of the outer tube and the serous coat of the inner. The bleeding points are then secured and the serous coats are at once united, the stitches being left long. This we continue step by step, stitching the edges immediately after division so that separation of the divided gut cannot take place. The long ends of the stitches are only cut short when the continuous suture through all the layers has been begun.

[1] Cf. also Weiss (v. Eiselsberg) Langenbeck's *Archiv*, Bd. 73.

Excision without clamps is more uncertain as regards asepsis, and it is important that the bowel should not be allowed to slip back for an instant, otherwise complications from bleeding and infection of the peritoneum may be set up. Resection is the most dangerous of the operations for prolapse. According to Lenormant, the mortality in 110 cases was 10·9 per cent.

Not uncommonly stenosis results some while after circular resection, and the necessary treatment by dilatation is a source of trouble to the patient. It is, therefore, a question in these cases where the bowel is much altered, whether it is not better to confine oneself to a regular coccygeal amputation of the rectum; the latter operation, when carried out in the manner we have already described, with preservation of the sphincteric muscular apparatus, has decided advantages over resection in the region of the rectal ampulla.

(k) Surgery of the Kidneys

164. General Remarks. Before undertaking any operation on the kidney, one must be absolutely sure that the other kidney is functionally efficient. This is a rule which must never be transgressed. It is essential to know in certain cases, *e.g.* in a difficult nephrotomy, partial nephrectomy, or when one finds a condition different from what was expected, whether one is justified in undertaking entire removal of the kidney. Unless we have this previous knowledge we are in an embarrassing position.

Preliminary segregation of the urine should also be performed and a comparison be made between the secretion of the right and left kidneys. If there is any uncertainty, the ureter, at least on the diseased side, should be catheterised and the urine of that side compared with the mixed urine passed.

Kümmel of Hamburg has recently[1] published the results of his large experience in this direction. If the urine obtained by ureteral catheterisation is of normal specific gravity, with a freezing point of 1 to 2, as a rule the kidneys may be regarded as efficient, even should an abnormal constituent such as albumen be present. Rovsing regards the freezing point of the blood as unimportant, but if it is much reduced, *i.e.* from 0·56 to 0·62 or more, it is probable that the renal functions are at fault.

Much more reliable information is gained from an examination of the urine than from palpation of the kidney (in regard to size or tenderness on pressure, etc.), as very often when one kidney is at fault, or seriously diseased, the enlarged and palpable kidney is the healthy one.

If the second kidney is functionally healthy, it is quite safe to pass from nephrotomy to nephrectomy, or to undertake an operation which may seriously impair its function temporarily or for a considerable time. Although the amount of urine secreted is regularly diminished by a half or more after unilateral nephrectomy, it always rises in a few days and within a fortnight may regain the normal.

We entirely agree with Garré and Ehrhardt[2] that acute nephritis, with blood, albumen and casts may be produced after unilateral nephrectomy, but we attribute this to the avoidable toxic effects of prolonged chloroform anæsthesia, and especially to the use of antiseptics such as perchloride of mercury and carbolic acid in the preparation and treatment of the wound.

165. Incision to expose the Kidney and Ureter. It is a mistake to place side by side all the possible incisions which are recommended for exposing the kidney, as is done in the latest text-books on renal surgery. The surgeon must always adapt himself to the individual case, and, when necessary, make exceptions to the rule. This does not, however, prevent us from regarding one incision as a rational one on anatomical and physiological grounds—an incision which should be adhered to as the normal by all who have not had large enough experience to employ modifications of it.

Rational incisions are those which expose the diseased organ with the least

[1] *Gynecology, Surgery, etc.*, Chicago, 1907. [2] *Nierenchirurgie*, Berlin, 1907.

damage, avoiding especially injury to large muscles and their nerve-supply, and to blood-vessels, and which can be simply and firmly united by suture.

FIG. 391*a*.—Oblique incision for lumbar nephrotomy.

FIG. 391*b*.—Mesial incision for transperitoneal nephrectomy (left). The incision on the right side is for ureterotomy (obliquely three fingers'-breadth above Poupart's ligament, terminating as a pararectal incision).

The oblique incision is the one which satisfies the above conditions when exposing the kidney from the loin, the mesial incision, when the abdominal route is chosen. Unless there is any reason to the contrary, the lumbar route is always selected, as it gives the most direct access to the kidney, and with the oblique incision there is no unnecessary injury to muscles and nerves. We therefore reject Simon's vertical incision for nephropexy. Our incision does not correspond to the oblique lumbar incision described by Garré and Bergmann, but closely resembles that recommended by Czerny-Braun.

The oblique incision (see Fig. 392) has the inestimable advantage that it can be readily extended forwards (cf. Trendelenburg's oblique incision) without doing serious damage, if more room is required, *e.g.* in following down the ureter, or if the tumour is a large one. On the other hand, we agree with Garré, and as early as 1877 gave it as our opinion, that very large renal tumours are best exposed with least injury by the intraperitoneal route. We also pointed out that when the mesial incision is used the posterior layer of the peritoneum must always be divided to the outer side of the colon.

FIG. 391*c*.—Prolongation of oblique incision for combined nephrotomy and ureterotomy.

Nephrotomy by the intraperitoneal route is best performed through Sänger's mesial incision, and not as in Hartmann and Langenbeck's operations through an incision at the outer border of the rectus (pararectal),

as in the latter the nerves to the rectus are divided and the resistance of the abdominal wall is impaired. If the mesial incision alone does not give enough room, it is much better to divide the rectus transversely at the level of the umbilicus, *i.e.* at a tendinous intersection by means of an incision at right angles. This procedure is also recommended by Hartmann. The addition of the transverse incision gives excellent room and the muscle can be securely sutured without any harm resulting.

While we do not regard the oblique incision as the normal one in the case of a large tumour, which requires a long incision, we consider the prolongation that Israel employs for exposing the ureter after removal of the kidney as the proper procedure. The oblique incision, when prolonged into the inguinal region, follows the direction of the fibres of the external oblique and is parallel to the nerves supplying it. As shown in Fig. 391c, we curve the incision downwards to the edge of the rectus and carry it through the united aponeurosis of the three great abdominal muscles, and sometimes the rectus sheath, down to the fascia transversalis. It is analogous to that employed in ligature of the common iliac artery, and gives just as good access low down, while it allows the upper edge of the wound to be retracted much more. (For details, see Exposure of the Ureter.)

166. Exposure of the Kidney with Division of the Capsule. Decortication. Nephropexy. The kidney can be exposed and the capsule incised quickly and without much bleeding by means of the short oblique incision already mentioned. Rapid exposure is also very urgently called for in rupture of the kidney, which not uncommonly follows an injury in the loin, and which may be accompanied by serious hæmorrhage. The bleeding may be arrested by exposing the kidney and ligaturing or suturing the tear in its substance; in many cases, however, removal of the organ has to be undertaken.

Acute inflammation of the kidney is to be regarded as another urgent indication for operation. We owe to Reginald Harrison the discovery of the fact, that in certain forms of acute nephritis not only can the nephralgic pain, hæmaturia, and albuminuria be rapidly arrested, but also the reflex functional disturbances of the other kidney (*i.e.* according to Israel, the ischæmia reflexly produced by irritation of the sensitive nerves in the pedicle).

According to Korteweg, anything which obstructs the kidney, even urinary retention, causes a venous congestion and a sort of strangulation, resulting in anuria which can be removed by an incision to relieve tension. When one considers how very often the medical treatment of an acute nephritis (following scarlet fever or other infections) leaves the kidney in a chronic inflammatory state, which results in contraction and often death, one is led to the conclusion that during the acute stage early and thorough relief of the renal circulation by incision should be resorted to.

We agree with Lennander that a wider sphere must be assigned to the surgical treatment of acute nephritis than is usually accepted. Lennander recommends incising the capsule and freeing the kidney by open treatment in cases of oliguria or anuria as well as when there is severe pain and tenderness on pressure in cases of nephritis. The same treatment should be followed when there is danger of the condition passing into a chronic stage with constant pain.

The object of exposing the kidney and dividing the capsule in chronic nephritis is not to relieve tension but to enable a collateral anastomosis to be formed with the vessels in the surrounding tissues. A few surgeons, Edebohls in particular, are as enthusiastic over the results of this operation as the greater number are indifferent.

Asakura, Stursberg, Zaajer, and Ceccherelli have shown by experiments that the new vascular anastomosis, between the decapsulated kidney and the surrounding tissues, produced by the operation, is quite extensive enough to directly influence the blood-flow through the kidney. Johnson, it is true, could not corroborate this.

Babes[1] attempted to provide a good blood-supply to the decorticated organ by opening the abdominal cavity, and either placing the kidney inside the peritoneum or by pulling out the omentum and wrapping it round the kidney.

Exposure and division of the kidney capsule are especially indicated in nephropexy

[1] *Centralbl. f. Chir.*, April 1904.

for floating kidney, and give very good results where morbid symptoms (pain, colic with or without intermittent hydronephrosis and congestion, gastric disturbances,

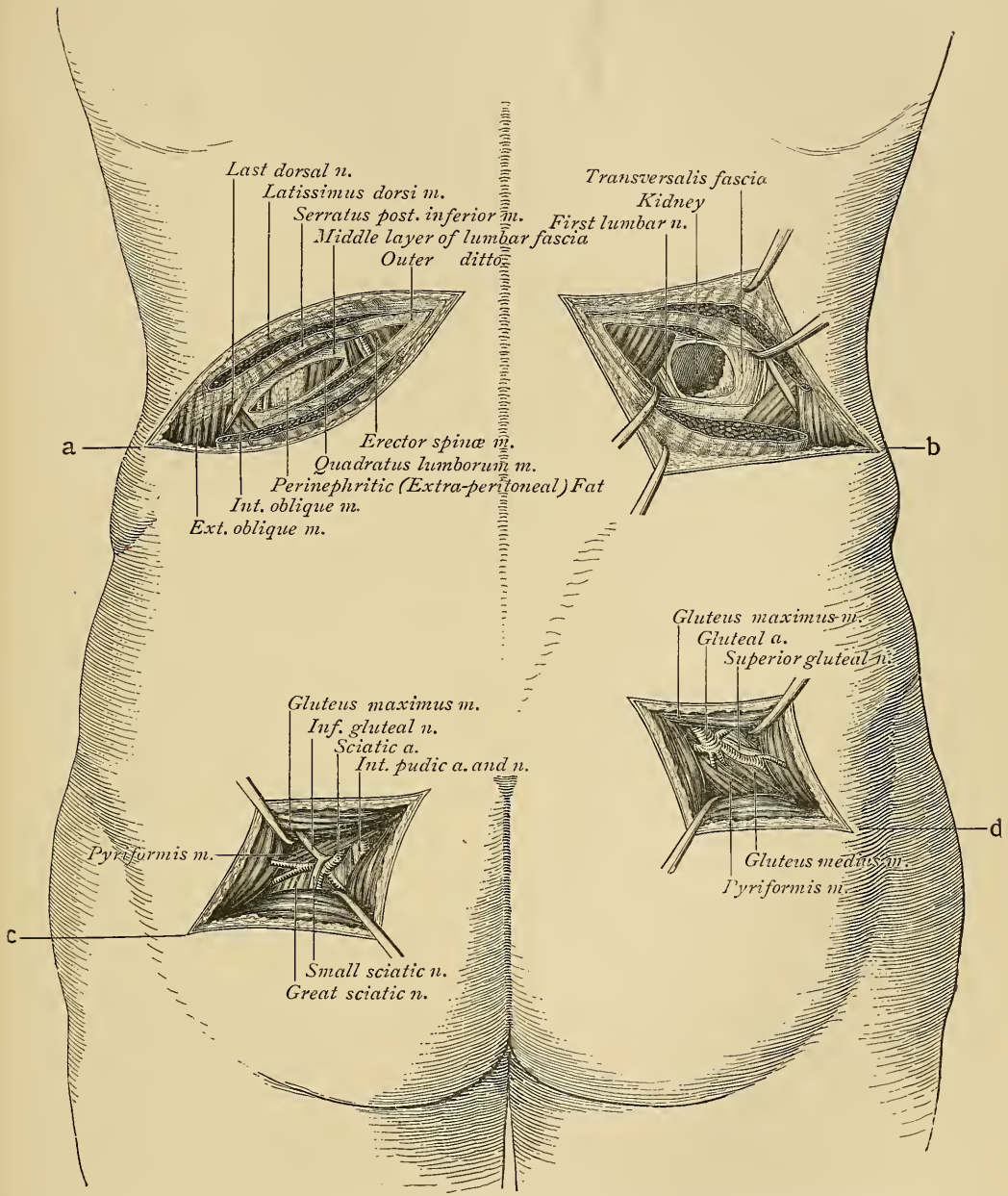

FIG. 392.—(*a*) and (*b*) Nephrotomy. (*c*) Ligature of the sciatic and internal pudic arteries, and exposure of the great sciatic, small sciatic, and internal pudic nerves. (*d*) Ligature of the gluteal artery and exposure of the superior gluteal nerve.

vomiting, etc.) can be recognised as definitely dependent on the floating kidney, particularly when mere "neurasthenia" or hysteria can be excluded. After fixation

of the kidney the symptoms remain entirely absent. In most cases the kidney can be reliably fixed if a proper technique is employed, even when it occupies a position lower than the normal.

Technique of Exposure of the Kidney.—The incision begins posteriorly over the prominence of the erector spinæ muscle, in the angle between it and the twelfth rib, and extends forwards as far as the mid-axillary line. It divides the skin and subcutaneous tissue, the strong lumbar fascia, and the muscles arising from it, viz. the latissimus dorsi and the subjacent serratus posticus inferior. The outermost digitation of the latissimus dorsi appears as a broad flat mass. The serratus posticus forms a thin muscular layer where it overlies the sacro-lumbalis, but beyond it the fibres pass obliquely upwards and outwards, forming a still thinner layer, which is not always well enough developed to be distinctly recognised. The edge of the sacro-lumbalis may either be nicked or drawn forcibly inwards. When a larger incision is made, the posterior border of the external oblique muscle of the abdomen, which descends from the last rib at the anterior angle of the wound, is divided transversely for a short distance, as also are the subjacent fibres of the internal oblique, which ascend obliquely upwards and forwards. Beneath the erector spinæ, and occupying the interval between it and the nicked edges of the oblique abdominal muscles, is the strong, glistening, transversely-striated lumbar fascia, which gives origin to fibres of the transversalis abdominis muscle. In *nephroraphy* it is only necessary to divide the latissimus dorsi and the lumbar fascia between the outer border of the erector spinæ and the posterior edges of the oblique abdominal muscles, the muscles themselves being left uninjured. After this fascia is divided, the edge of the quadratus lumborum is seen passing almost vertically upwards parallel to the margin of the erector spinæ, beyond which it projects. The last dorsal nerve appears at the lower border of the twelfth rib, and passes obliquely downwards and forwards, sometimes beneath and sometimes over the edge of the internal oblique. The ilio-hypogastric nerve (from the first lumbar) extends downwards and outwards from (in the prone position) beneath the edge of the quadratus.

The outer edge of the quadratus may either be nicked or drawn inwards. The abundant loose post-renal fat, and the vessels which lie beneath the transversalis fascia, are then exposed. The kidney is now reached by carefully separating this fatty capsule with the finger.

If the kidney does not occupy a normal situation, it is not always easy to expose it sufficiently freely for accurate inspection and palpation by an incision merely through the soft parts. In such cases one must not hesitate to divide subperiosteally the twelfth or the eleventh, or even a rib still higher. The upper edge of the wound is retracted upwards, an incision made down on to the rib, and after reflection of the periosteum the rib is divided.

Nephropexy. For fixation of a floating kidney,[1] we adhere to the method finally adopted by Hahn (who first proposed nephropexy in 1881), and employed by N. Senn. The kidney is pushed up into the wound by pressure made by an assistant on the anterior abdominal wall, its true capsule nicked, and carefully detached with a blunt dissector. After catching the edges with our toothed artery forceps, the incision is prolonged towards the lower pole, which is pulled upwards by its capsule.

Considerable force is required in stripping off the capsule, but it must be done with care, as the capsule is easily torn, and it is desirable to separate it for as great an extent as possible. In stripping the capsule off the concave surface care must also be taken not to rotate the kidney into an unsuitable position, otherwise the ureter may be kinked or transfixed by the needle. Basham[2] asserts that one cause of failure consists in fixing the kidney too low down or in an abnormal position, and a second in associated lesions (pyelitis, stone, kinking of the ureter) which are not corrected.

After the capsule has been separated, it is stitched along with the fatty capsule

[1] The operation of nephrectomy formerly practised, and recommended by Martini for floating kidney, is no longer to be regarded as a normal procedure. It may occasionally be necessary later on if disturbance of the urinary secretion or urinary fistula remain after a conservative operation, or if the trouble continues in cases complicated by nephritis.

[2] *American Journal of Surgery*, May 1906.

to the lumbo-costal and lumbo-dorsal fascia with 8 to 10 silk sutures threaded on a curved needle, so that a portion of kidney substance lies quite free in the bottom of the tunnel formed by the capsule. The surgeon then satisfies himself that the kidney lies firmly in this position and is no longer pushed down on respiration. In passing the sutures, the last dorsal and first lumbar nerves, which are seen in the upper and lower extremities of the wound, must be borne in mind, as if they are included in the sutures, radiating pain, which may persist for some time, is the result.

The capsule is now still further separated round the lower pole, and xeroform gauze is packed round the latter and brought out through the wound. The gauze fills up the wound and is in contact with all the exposed area of the denuded kidney surface. It is well to partly close the wound with a couple of deep sutures and leave in the gauze. The latter is only removed after fourteen days, for the object is to procure a granulating surface right down to the kidney, which will give rise to extensive cicatrisation between a large part of the surface of the kidney and the connective tissue and fascia of the loin.

Catgut should not be used, as the sutures must hold the kidney firmly in position for a considerable time. We consider it unnecessary and even dangerous to pass the suture round the last rib, for the pleura may readily be injured, and no better hold is got than by stitching the kidney to the strong fascia between the rib and the crest of the ilium. We consider any attempt to pass the sutures through the substance of the kidney to be absolutely useless, as they cut out either at once or at least subsequently on the slightest pull, and do not fix the kidney so well as simple suture through the capsule. Gardner [1] points out that a renal fistula may arise from injury of the central calyx, which generally comes near the surface of the kidney.

Exonephropexy, *i.e.* placing the kidney in the soft parts of the loin, is associated with the danger of kinking of the vessels or ureter. We have tried it and have abandoned the operation. Beck, Baldwin, and Kukula push the capsule or the kidney itself through a slit in the quadratus lumborum; Kukula, however, lost one patient out of three from vomiting and anuria.

167. Nephrotomy. Nephrolithotomy.[2] **Pyelotomy.** When the kidney has been exposed in the manner described in the previous section, one may have to incise its pelvis or split the kidney itself *in situ* to evacuate collections of fluid or remove stones. Garré rightly asserts that in nephrotomy the capsule should not, as a rule, be removed, *i.e.* the kidney should not be decapsulated, to avoid giving rise to more severe bleeding. The converse is the rule in nephrectomy. Among the fluids to be dealt with are blood, urine, contents of cysts or pus; anuria from obstruction by a stone or from acute congestion of an inflammatory nature is one urgent indication for immediate nephrotomy. Some surgeons have incised the kidney itself in cases of congestive hyperæmia, while others are satisfied with decapsulation.

(*a*) *Nephrotomy and Nephrolithotomy.* Tuffier's so-called "sektionsschnitt" is the incision most generally adopted when there is a choice in the site of the nephrotomy opening. Zondeck, however, has made some admirably-injected preparations to demonstrate the correct situation for incision of the kidney. He has shown that the anterior and posterior vascular territories of the organ are fairly-distinctly demarcated from one another, and that by making the incision about 1 cm. behind the convex border and cutting towards the pelvis no large vessels will be encountered. We have already alluded to a case which we saw in the practice of one of our colleagues where fatal hæmorrhage occurred after an absolutely healthy kidney had been incised.

Before the kidney is incised, it must be brought out of the wound. Clamps can then be applied to the vessels in the hilum and the hæmorrhage controlled. The incision should only be 3 to 4 cm. long to begin with, *i.e.* just large enough to admit the finger for examining the pelvis and calices. Once the finger is in the pelvis, it is much easier to extend the incision upwards and downwards with a probe-pointed knife without doing damage. If it is merely to drain an abscess, there is no need for the longer incision necessary for the removal of large impacted stones.

[1] *Annales des mal. génito-urinaires*, 1905, No. 8.

[2] Garré states that Czerny first performed nephrolithotomy, and Morris pyelolithotomy.

In a case of nephrolithotomy it is essential to examine the kidney both from the outside and inside so as to be sure that no concretions are left behind. A sound should also be passed down the ureter, or coloured fluid injected through it into the bladder to ascertain that it is patent.

If there is copious hæmorrhage from the division of a large vessel, a suture should be passed round the latter and tied. A deep suture is a very certain means of arresting hæmorrhage, having, however, the disadvantage that it may interfere with the circulation to such an extent that necrobiosis and necrosis may take place, as may happen after ligature of any large vessel. Not very long ago we had occasion to note the separation of large necrotic portions of the kidney in the course of a case (an arterio-sclerotic kidney which ran a normal aseptic course) after using numerous catgut sutures. Albarran maintains that by employing loose tampons instead of sutures the kidney regains its functional activity much more readily.

Sutures should only be employed when one is sure that the outflow by the ureter is quite free and that there is no sepsis present. A mild degree of infection must always be taken for granted in cases of nephrotomy, for both Tavel and ourselves have shown that even with a healthy kidney one can never be sure that bacteria excreted with the urine will not infect the wound. Whenever sutures are employed, a drainage tube must be passed down to the kidney, while helmitol and urotropin are subsequently administered.

If hæmorrhage occurs after an infected kidney or pelvis has been opened, the kidney must be packed, and if the incision is a large one, sutures must be inserted as well, and a drainage tube passed into the pelvis. In the case of multiple abscesses plugging alone is permissible.

(*b*) *Pyelotomy.* Pyelotomy is indicated when stones have to be removed from the pelvis of the kidney, especially when a small stone is impacted in the ureter. It is also indicated when the pelvis is dilated and a portion of it is to be resected, or a plastic operation performed on the upper end of the ureter (*vide infra*, Transpelvic Ureterostomy).

When the renal pelvis is dilated, pyelotomy is a much more simple and bloodless operation than nephrotomy. There is, however, more chance of a persistent urinary fistula resulting, and at the same time it gives poor access to stones situated in the calices. If the pelvis is properly exposed from behind and opened at an easily-accessible point, a fistula can be prevented by inserting two layers of fine silk sutures. If pus is present in the pelvis, the latter must be drained, and should a fistula result, it can be subsequently closed.

Appendix. Nephrostomy and Pyelostomy. A permanent urinary fistula has occasionally to be made either in the kidney itself or in its pelvis, in the treatment of certain conditions necessitating operation on the ureter and bladder, especially in total excision of the bladder for malignant new growths.

168. Nephrectomy. We owe this operation as well as the development of renal surgery to the researches of Simon. It is clearly indicated in the case of a unilateral renal tumour, and in rupture of the kidney, with hæmorrhage which cannot otherwise be controlled. It is, however, more frequently undertaken in suppurative conditions of the kidney, especially tuberculosis. In suppurative cases it must be proved by segregation of the urine that the function of the renal parencyma is already seriously impaired, and also (possibly by means of the kryoscope (Koryani)) that the other kidney is able to respond to the increased demands made upon it.

In tuberculosis of the kidney the conditions are similar in so far that the functional efficiency of the other kidney must be determined. When, however, there is no doubt about the diagnosis, the indications for nephrectomy are still more definite, and the operation is performed even when the function of a tuberculous kidney is still comparatively good. Excellent results are obtained by early operation in the case of renal tuberculosis, and we consider early excision by far the best treatment.

Even when the disease is bilateral, excision is still indicated, provided that the function of the other kidney is not yet really diminished by the disease. Here, of course, there must be special reasons for excising the more diseased kidney in the

shape of bleeding, pain, or suppuration and its sequelæ. Experience has shown that the condition of the other kidney improves and its functional activity increases correspondingly as soon as the evil effects on the rest of the body are removed.

The lumbar operation is the correct one in traumatic, suppurative, and tubercular cases, as well as in a persistent renal fistula, while the transperitoneal route is to be preferred for tumours.

(*a*) *Lumbar Nephrectomy.* The same incision is employed as that described for nephrotomy, the operator prolonging it, if necessary, forwards towards Poupart's ligament (cf. Bergmann's lumbar incision). Bergmann's incision is often the best for a diseased floating kidney. In any case, the incision should always be made long enough in the first place.

Before attempting to remove the kidney, decapsulation should always be performed if the capsule is not adherent, as otherwise considerable difficulties may be encountered. In attempting extracapsular nephrectomy when the capsule has become adherent to the surrounding parts as the result of inflammation or new growth infiltration, neighbouring structures, *e.g.* colon, peritoneum, and particularly the great vessels (vena cava) are very liable to be injured.

It not infrequently happens, however, that the capsule is involved in the disease and is considerably thickened (up to 1 cm. or more in tuberculous pyonephrosis). However, the correct way to excise the kidney is first of all to shell it out of its capsule, when this is possible, after which an excision of the capsule (in most cases only partial) can be undertaken if not too dangerous.

It is not always possible, when there are multiple abscesses, to avoid opening into some of them in stripping off the capsule, but this is a much less serious accident than the bleeding and injury which is associated with pericapsular excision. There is no doubt, also, that the capsule may be sometimes directly invaded by the new growth. The case must then be regarded as too far advanced for a radical cure to be obtained, in so far as the capsule cannot be subsequently removed without serious risk.

The treatment of the pedicle in the case of a large tumour, or when there is much inflammatory thickening of the capsule and perirenal tissue is by no means easy. After the kidney has been detached from its capsule (in the case of a tumour numerous vessels have to be ligatured), it is sometimes as well to incise the capsule round the hilum so that a securer type of pedicle may be obtained.

If a long enough pedicle can be got, the artery and vein should be isolated separately with an aneurysm needle, tied and cut across. Strong catgut should be used in infective cases, silk in an aseptic case. One is often glad enough to be able to tie a single ligature tightly round the whole pedicle and afterwards, if the individual vessels can be seen in the stump, they may, for greater security, be tied separately.

The ureter, which lies posteriorly, should be separated from the vessels whenever possible. In suppurative and tuberculous conditions great care must be taken that its contents do not infect the surrounding parts. The ureter should be ligatured low down and a pair of artery-forceps applied on its renal side, after which it is cut across between the two with the thermo-cautery. A ureter, the muscular wall of which is still intact, is securely closed in this way.

When, however, the wall of the ureter is diseased and thickened, as occurs in tuberculous cases, it is quite a different matter. Here the most rational procedure would appear to be to excise the ureter *in toto* right down to the bladder. We are satisfied, however, that it is only reasonable to do this when the terminal part of the ureter is healthy, for infection arising from the deeply placed stump is far worse than if the upper end of the ureter is accessible in the region of the wound. We have seen miliary tuberculosis with a fatal issue result from the development of a small tuberculous abscess after the low removal of the ureter.

In these cases it would be better to follow Kümmel's advice and resect a portion of the bladder wall, provided that one has learnt by means of the cystoscope the extent and degree of affection of the bladder. As a general rule, the ureter is merely ligatured above (Israel, Rovsing, and others) and iodoform injected into the stump, which is sutured in the wound. According to Rovsing, the disease of the bladder

should be treated with carbolic injections (1 to 20 carbolic acid injected twice daily and allowed to remain in the bladder for five minutes).

When nephrectomy is undertaken for a tumour of the kidney, the only difference is, that very copious hæmorrhage often occurs in separating the fatty capsule, and that it is seldom possible to strip off the "capsule proper." We much prefer the access afforded by the transperitoneal operation in dealing with large tumours, *e.g.* a renal sarcoma in children, although with the extended oblique incision it is often possible to get access to the region of the colon extraperitoneally and then proceed immediately to the separation of the latter.

(*b*) *Transperitoneal Nephrectomy.* We were the first (1876) to adopt the transperitoneal operation on the strength of a deliberate diagnosis. The case was a large renal sarcoma. We recommend an incision in the middle line to which, if necessary, may be added a transverse incision, as shown in Fig. 391*b*.

The tumour is at once exposed, covered by the peritoneum of the posterior abdominal wall, in front of which is the ascending or descending colon. If it is impossible to keep the intestines packed away in the other side of the abdomen, they must be wrapped in warm sterile towels. The veins on the surface of the tumour are usually enormously distended. We found in our first case that it is best to incise the peritoneum parallel to, and to the outer side of the colon, and displace the latter inwards. The rest of the peritoneum is retracted outwards, and all the vessels, especially veins, are isolated with an aneurysm needle.

Carefully arresting the hæmorrhage step by step, we reach the space between the fatty capsule and the tumour posteriorly. Here the separation proceeds more easily till the pedicle is reached and can be tied.

One must afterwards be careful to see whether the blood-supply to the colon has been damaged, for if so resection may be necessary. The large raw surface is then covered over by drawing together the edges of the peritoneum with sutures. Drainage in front is unnecessary, but a tube is inserted through a small incision in the loin, at the outer border of the quadratus lumborum.

Hyper-nephromata are among the most favourable tumours for radical treatment, only, however, so long as they can be separated from their surroundings by blunt dissection. We shall record our experiences elsewhere. Wenzel, from an experience based on twenty-three operations for "epinephroma," recognises the decided superiority of the transperitoneal method.

The transperitoneal method has the advantage that one can easily examine the condition of the other kidney. Before the introduction of segregation, ureteral catheterisation, and cryoscopy, we used to determine this (as regards its vessels) by palpation in cases of lumbar nephrectomy, passing the hand through an incision in the peritoneum external to the colon.

169. Excision of the Suprarenal Body. The suprarenal body has recently been excised in the treatment of Addison's disease. Hadra and Oestreich performed laparotomy for a supposed malignant retroperitoneal growth, the incision extending between the xyphoid cartilage and the umbilicus. After division of the small omentum, a pulsating tumour the size of a hen's egg was separated from the aorta. It proved to be a tuberculous suprarenal capsule. The wound was stuffed and the patient recovered. The Addisonian symptoms (marked weakness, emaciation, and severe gastric pain) disappeared. There had been complete absence of bronzing of the skin.

(l) Surgery of the Ureter

170. General Remarks. A great advance has been made since the last edition in the treatment of injuries and other conditions of the ureter requiring incision, or resection with either end-to-end anastomosis or implantation into the bladder, and occasionally into the bowel and abdominal wall.

Anastomosis and implantation of the ureter have been, as a rule, performed on account of accidental injury during operations, especially on the female reproductive

organs, and in consequence have generally been carried out intra-peritoneally. Krönig has performed uretero-cystostomy no less than 25 times, 23 being intra-peritoneal, with only one death.

Total excision of the ureter is chiefly called for in tubercular disease, when it has become extensively involved from the kidney.

Incision and resection of the ureter are most often undertaken for the relief of obstruction, more especially when a calculus, in its passage from the kidney, has become impacted in the ureter, but also in stenotic and valvular conditions secondary to injuries and inflammation, particularly in connection with obstruction (uro-nephrosis) and floating kidney.

Lastly, tumours, especially of the bladder, call for resection of the ureter. When undertaken for the treatment of a ureteral fistula, the latter is, as a rule, the result of an operative lesion.

With regard to technique, it is well to distinguish between the lumbo-renal portion of the ureter, *i.e.* the portion continuous with the pelvis of the kidney, the abdomino-iliac, and the pelvi-vesical portions. Finally, a clear distinction must be drawn between the intra-peritoneal and extra-peritoneal operations in these three regions.

171. Intra-peritoneal Anastomosis of the Ureter with Ureter and Bladder. As mentioned above, it is chiefly as a result of injury during laparotomy that restoration of the ureter by anastomosis is called for. We anticipate the discussion of this, since it also demonstrates the method of establishing normal conditions in cases of intentional exposure and opening of the ureter.

(*a*) *Uretero-anastomosis.* Experience has shown that in the case of a divided ureter union by simple end-to-end suture (Schopf), by lateral anastomosis with occlusion of the ends (Monari), and even by the better end-to-side method, is not reliable. A partial wound can be repaired with a double row of fine silk sutures which do not include the mucous membrane, after the fashion of Lembert's sutures, but in the case of a total division the invagination method is required.

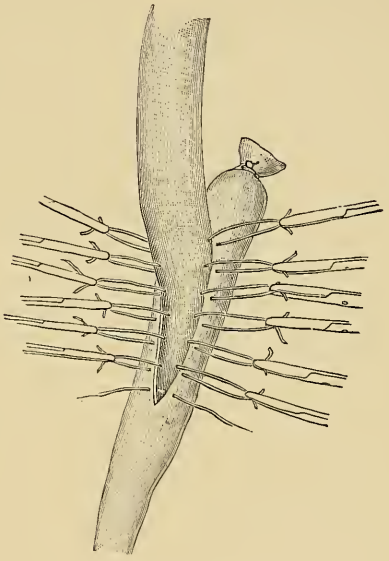

Fig. 393.—Ureteral anastomosis, invagination method.

The invagination method which was introduced by Weller van Hook, and improved by Emmet Bache, is strongly recommended by Döderlein and Krönig. As in an end-to-side intestinal anastomosis, the vesical portion of the ureter is closed with a circular occluding suture and a longitudinal slit is made lower down into which the renal end of the ureter (best divided obliquely according to Depage and Mayer) is inserted, care being taken that it projects some millimetres beyond the lowest angle of the wound. The edges of the slit are then stitched with fine sutures all round to the wall of the portion implanted in it.

In the intra-peritoneal operation, if peritoneum can be united to peritoneum, there is no need for drainage, provided that there has been no escape of infective contents from the ureter.

(*b*) *Uretero-cystostomy.* The idea of reimplanting the ureter in the bladder after dividing its lower end only occurred as a possible alternative after the method of implanting it into the gut had been evolved. Yet it is by far the more natural and less dangerous method, because in this case the fear of an ascending infection, always present and of great importance in implantation into the gut, need not be entertained. Boari has published an excellent paper on the subject of uretero-cysto-

neostomy. The operation is indicated, according to Boari, in cases of injury to the lower end of the ureter, and more especially in fistula formation, as in uretero-vaginal and uretero-uterine fistulæ. Poggi originated the idea in 1887, and Paoli and Busacchi performed the first experiments on animals. Novaro (1893), Bazy, Hegar, and Schede have performed the operation on the human subject.

Novaro inserted the end of the ureter directly into an opening in the apex of

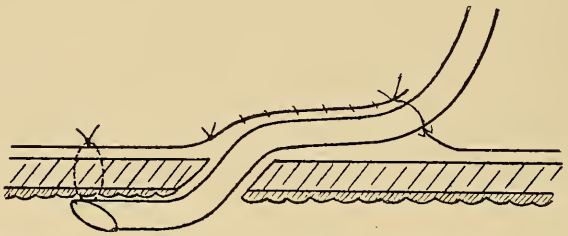

Fig. 394.—Uretero-cysto-neostomy, Depage's method. The figure shows the manner in which the ureter is inserted into the bladder. The peritoneum has been stitched over part of the ureter.

the bladder, and converted the suture subsequently into an extra-peritoneal one. Boari used the same method.

A laparotomy is performed and the ureter is sought for. The parietal peritoneum covering it is divided. If a fistula is present, the ureter is cut through above it. The bladder, a part of which has been rendered prominent by introducing a catheter, is incised close to its apex, to prevent backward flow of urine. A ureteral sound is passed into the ureter (Bazy) from below through the incision in the bladder.

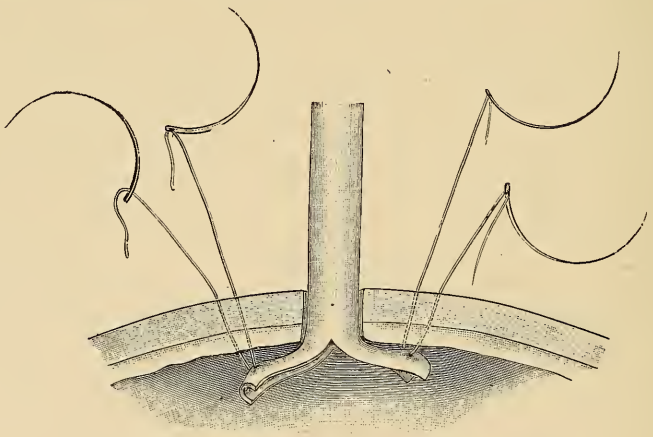

Fig. 395.—Uretero-cystostomy, Sampson-Krönig method.

Fine catgut sutures are now put in so as to unite the mucous membrane of the ureter—the opening of which may be split laterally if necessary—to the mucous membrane of the bladder. The remaining layers are next sutured. Care must be taken not to narrow the ureter by these stitches.

Bazy employs side-to-side anastomosis. He makes a lateral slit in the ureter, and stitches the edges to a corresponding opening in the bladder. End-to-side union between the ureter and bladder has, however, proved much better. Margarucci[1] points out that if the periureteral tissues in which the ureteral arteries (branches of

[1] *Policlinico*, Rome, 1904.

the renal arteries) lie, are preserved, the ureter can be safely isolated for 8 to 10 cm. (3 to 4 inches). Garré emphasises the extent to which it can be stretched.

Fritsch was the first to call attention to the necessity of pulling the ureter well down so as to project into the bladder. Witzel then instituted the method of implanting it obliquely into the bladder wall, after his manner of making an oblique fistula in the stomach and intestine. Depage simplified the latter operation in the manner illustrated in Fig. 394, and has had very good results.

Depage and Mayer,[1] who have reported on 64 cases of uretero-cystostomy (up to 1904) with a mortality of 11·7 per cent (the purely operative mortality being 5·9 per cent), recommend that, after division of the peritoneum, the ureters be cut obliquely. A small hole is then made in the bladder, and the ureter pulled through it by means of a fine silk thread, the ends of which are passed through the bladder wall, about 15 mm. distant from the opening, and tied. The opening in the bladder may be partly closed, if necessary, while the detached peritoneum is replaced and stitched over the ureter as it enters the bladder for a distance of 3 cm.

Fig. 396.

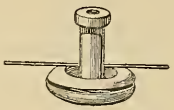

Fig. 397.

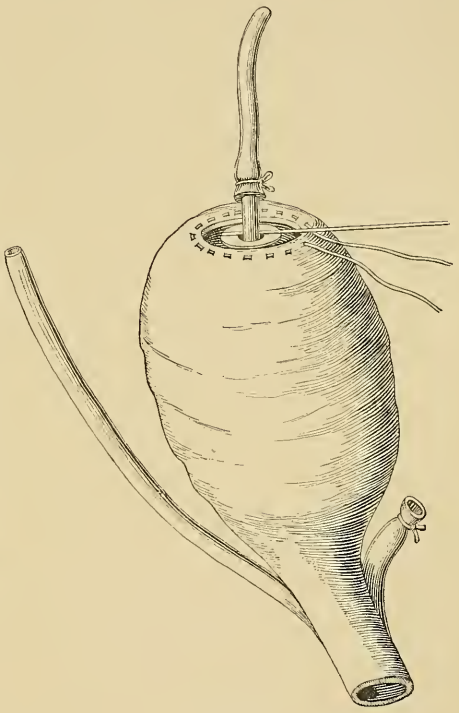

Fig. 398.

The difference between Krause and Sampson's methods, and their modifications by Döderlein and Krönig, is similar to that between those of Witzel and Depage. Both split the ureter for some distance (*vide* Fig. 395), pull the two flaps through the hole in the bladder by means of a double suture, and fix the ureter near the opening with stitches. But while Krause merely fixes the flaps to the mucosa, Sampson, Döderlein, and Krönig pass the stitches through the whole thickness of the bladder wall.

Krönig has only had one death out of 23 cases of intra-peritoneal implantation using Döderlein and Krönig's modification of Sampson's method. Double implantation has even been carried out successfully. Rissmann made two openings in the bladder and pulled the split ureter in through the one and out through the other (distant 3 cm.) and fixed it in the latter.

Novaro has further pointed out that it is desirable, in intra-peritoneal implantation, to unite the peritoneum over the isolated strand of ureter running through the abdomen : Witzel also adopts the same method.

To effect this, Novaro strips the peritoneum back from the front of the bladder over the site of suture and stitches it there.[2]

Boari has introduced a button (Fig. 396, 397) analogous to that of Murphy, of which the narrow end is tied into the ureter and the broad end into the bladder. The walls of the two openings are pressed apart by the pressure of a spring. The button greatly simplifies the operation. When the broad part of the button has

[1] Langenbeck's *Archiv*, Bd. 74.

[2] Cf. Lichtenauer, *Monatsschr. f. Geburtshilfe*, Bd. 22, and Stoeckel, *ibid.* Bd. 51.

been introduced into the opening in the bladder, the latter is fixed round it with a purse-string suture, as in the case of Murphy's button (Fig. 398, borrowed from Boari's work). Boari did not lose a single animal in which this method was employed, and no fistulæ resulted. Boari, following Novaro, recommends that the peritoneum of the bladder should be raised up as far as the site of implantation, and that a gauze drain should be put in, a glass tube, however, probably being better for this purpose.

Unlike implantation into the intestine, the operation gives rise to no functional disturbance, neither to infection nor to stenosis.

In cases of defect of the ureter, which, in spite of traction on the ureter and freeing of the bladder (according to Kelly by division of its pubic ligaments), do not permit of union, Boari recommends a uretero-plastic operation, which may best be illustrated by two diagrams borrowed from his work on the subject (Figs. 399, 400). It consists in the formation of a long flap with its base above: this is converted by suturing into a tube, and the ureter is invaginated into its upper end.

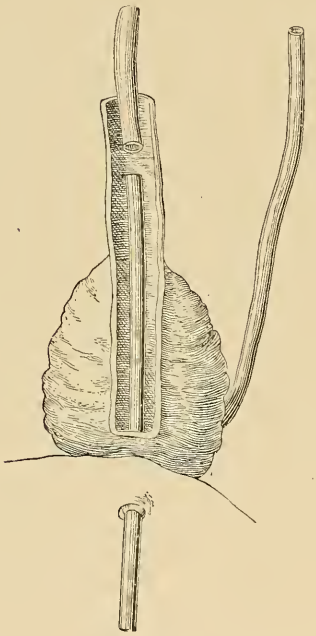

Fig. 399.

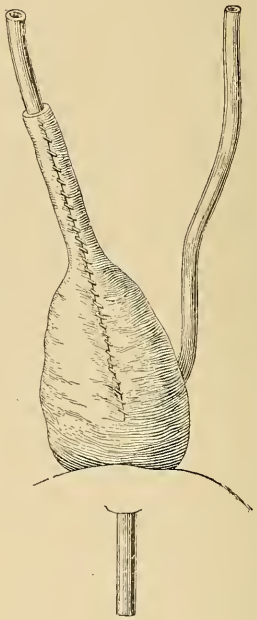

Fig. 400.

(*c*) *Uretero-Trigono-Sigmoideostomy* (*Maydl*). According to Garré, Bardenheuer and Novaro devised the operation from experimental observations. The first to perform it, besides Maydl, were Eiselsberg and Herczel.

The above name was introduced by Reuben Peterson, who has published an excellent work on uretero-enterostomosis. He has performed a large number of experiments with the special object of getting a clear idea of the effects of the operation on the kidneys. He finds the conditions identical in man and animals. The result of his studies of the literature on the subject, and of his experiments, is very definite. All endeavours to prevent infection ascending to the kidneys when the ureters are implanted in the intestine are unavailing, and consequently general infection or severe lesions of the kidneys cannot be prevented. In thirty-three cases in human beings the mortality was 33 per cent. Secondary stenosis cannot be prevented and results in hydro- and pyo-ureteritis, or hydro- and pyo-nephrosis.

The operation is therefore unjustifiable. How far Franck's operation of cysto-

proctostomosis has a future before it is still undecided. Halstead has performed it with success. On the other hand, the operation called by Peterson uretero-trigono-enterostomy, namely, implantation of the ureters with the part of the bladder wall immediately surrounding their terminations, has quite justified itself. The mortality is small, the danger of severe infection passing upwards is insignificant, although no valve or muscular sphincter can be formed. The rectum tolerates the urine quite well, and its sphincter action is sufficient to prevent incontinence.

The idea of keeping the openings of the ureters intact originated with Tuffier, but Maydl first performed the operation in its present form in a case of extroversion of the bladder. The mortality in thirty-six cases has only been five.

The operation, as described by Maydl and modified by Peterson, is as follows:—

No purgative must be given, nor must the rectum be washed out beforehand, but after the patient is under the anæsthetic the rectum and colon are thoroughly washed out. For cases of extroversion of the bladder (according to Tuffier) an

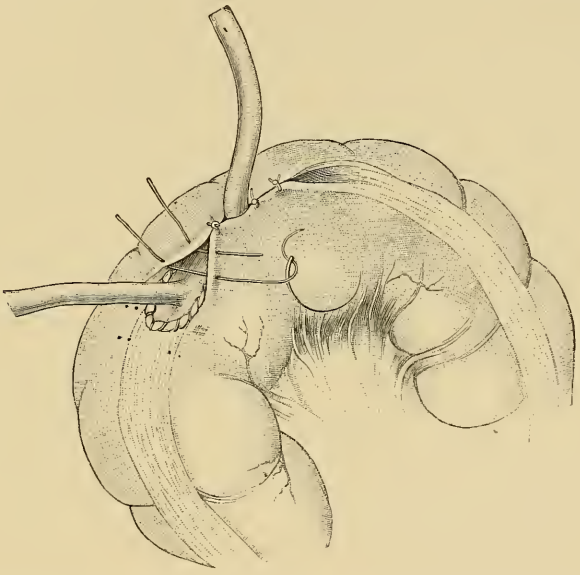

FIG. 401.—Implantation of the trigone and ureters into the pelvic colon. The trigone has been united all round to the opening in the bowel, and invaginated.

incision is made round the bladder, which is freed extra-peritoneally. Peterson divides the bladder as far as the fundus with scissors. A rectangular piece, at least $1\frac{3}{4}$ in. square, is next cut out round the orifices of the ureter. It would probably be more convenient for suturing if the piece was more elliptical in shape. The abdominal cavity is opened and the sigmoid flexure (in dogs the descending colon) is pulled out, and an incision is made in its long axis (the loop of bowel should be emptied, and a clamp applied) corresponding in length to the portion of bladder excised. The latter is now placed along one margin, serous coat to serous coat, and a suture put through the whole thickness, as shown in Fig. 401 (borrowed from Peterson's work). The suture is continued all round (Peterson only cuts down as far as the mucous coat, and does not excise this till two-thirds of the suture has been inserted). The parts are now thoroughly cleansed and the serous suture is introduced.

Peterson has discovered that, in dogs, the trigone of the bladder is supplied by the vesical arteries, and these must therefore be carefully preserved, as they have very little anastomosis with the arteries to the ureters. Boari's button cannot, of

course, be used. The reason why ascending infection does not occur is, that at the end of the ureters there is neither wound nor suture which could propagate infection (of coli bacilli, etc.) upwards, nor does the mouth of the ureter gape. No known method has succeeded in establishing a valvular or muscular closure, and operative endeavours to this end are rather injurious than useful.

It is a great improvement to isolate a portion of the intestine as a reservoir for the urine. If the pelvic colon can be pulled out sufficiently, it should be emptied and clamped as low down as possible (*vide* Fig. 402) and the afferent

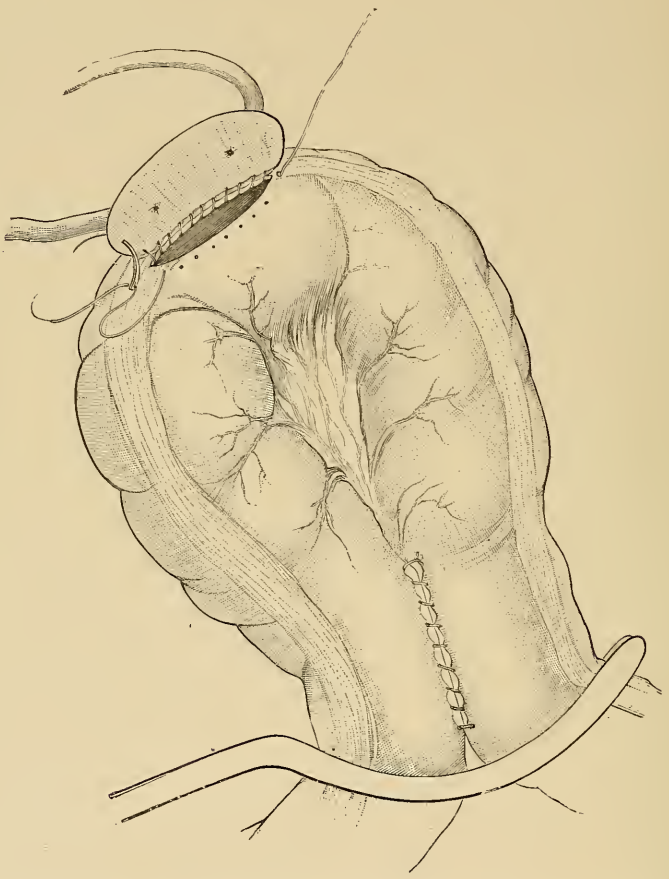

Fig. 402.—Implantation of the trigone of the bladder with the ureters into the pelvic colon, associated with entero-anastomosis. Stage 1 : The figure shows the mucous membrane of the trigone with the orifices of the ureters united on one side with the bowel.

anastomosed directly to the efferent limb, after which the trigone is inserted into the summit of the loop (Fig. 402). End-to-side anastomosis is more certain, but is more difficult to perform than lateral anastomosis. In the former the afferent bowel is divided, its distal portion closed with an occlusion suture, and its proximal end inserted into the base of the efferent limb.

172. Extra-peritoneal Operations on the Ureter. (*a*) *Surgery of the Lumbo-renal portion.* To expose the ureter at its commencement, the oblique incision described for nephrotomy is used. It is employed in the form of pyelolithotomy already described to remove stones impacted in the upper part of the ureter, and as

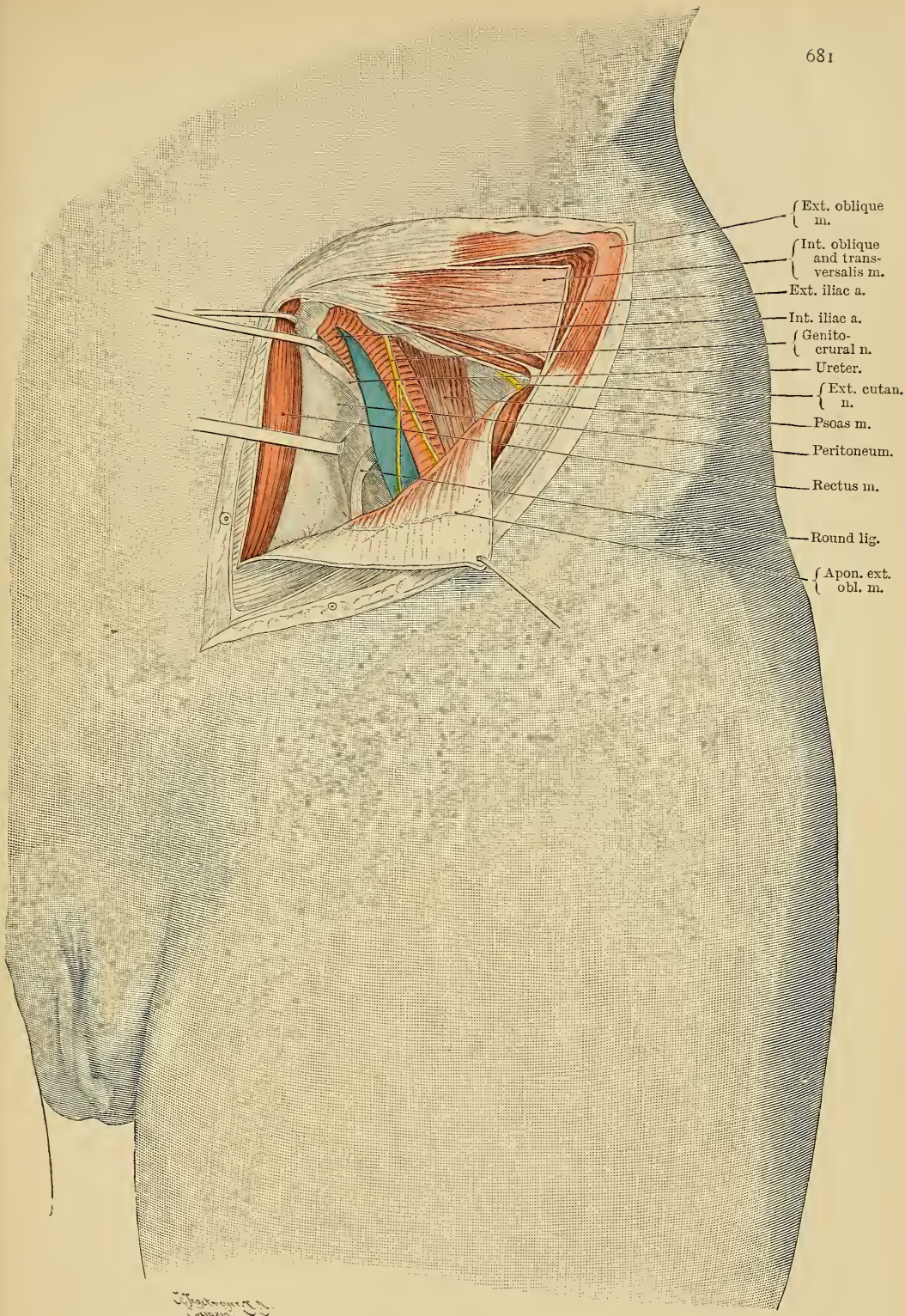

FIG. 403.—Angular incision for ligature of the common iliac artery.
(Only a small part of the trunk of the artery is here represented.)

pyelo-ureterostomy, when there is a valvular constriction, or when the opening of the ureter into the pelvis is oblique.

The latter conditions may be either congenital or the result of hydronephrosis (uronephrosis). Donati has shown that when hydronephrosis is experimentally produced by tying the ureter, the renal parenchyma is rapidly destroyed and does not recover. When, therefore, the functional power of the kidney is found to be poor, one does not hesitate to excise the kidney, provided, of course, that the estimation of the capacity of the other one is satisfactory.

As an alternative an anastomosis may be made with a portion of the ureter favourable for the outflow of urine, followed possibly by excision of the sac, pyeloplication, or pyelostomy. A lateral anastomosis is made at the lowest point of the sac of the hydronephrosis (Küster), or the principle of Finney's gastroduodenostomy may be applied and the spur between the ureter and the sac divided in its whole extent down to the bottom of the sac, the edges being united by sutures (Trendelenburg).

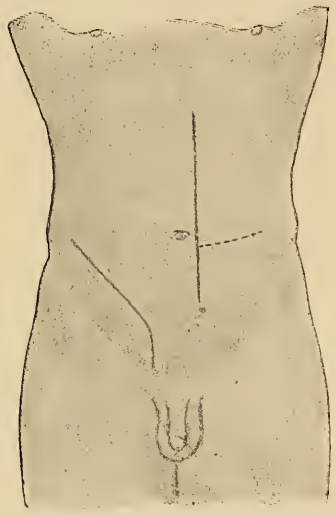

Fig. 404.—Mesial incision for transperitoneal nephrectomy (left). The incision on the right side is for ureterotomy (obliquely three fingers'-breadth above Poupart's ligament, terminating as a pararectal incision).

(*b*) *Operation on the Abdomino-pelvic portion of the Ureter.* The portion of the ureter, which crosses the bifurcation of the common iliac artery at the brim of the pelvis in its course to the bladder, can be exposed in its whole extent by an incision analogous to that described for ligature of the common iliac artery (*vide* Fig. 403 for the dissection and Fig. 404 for the line of incision).

The incision is made three fingers'-breadth above Poupart's ligament, obliquely downwards to the outer border of the rectus. The aponeurosis of the external oblique and the united fasciæ are divided at the border of the rectus. The muscles are split and the flap retracted downwards. The transversalis fascia and peritoneum can now be raised from the internal iliac fascia over the edge of the psoas towards the middle line.

The ureter is lifted off the great vessels along with the peritoneum. It is easily recognised and isolated; and can be followed downwards along the wall of the pelvis, and upwards on the posterior abdominal wall.

Fowler[1] has reported two cases in which calculi in the ureter were removed through the iliac incision. Morris collected 46 cases in 1899 and later on reported 16 more.

(*c*) *Operations at the Intra-mural and Intra-vesical end of the Ureter.* When a stone is impacted in the termination of the ureter, it is best removed by suprapubic cystotomy. A tumour, stricture, or a prolapse of the ureter in this situation should be dealt with in a similar way.

Young[2] has made a careful study of the anatomy of the lower end of the ureter, and has published a series of very interesting operations, chiefly for the removal of calculi impacted in the lower end of the ureter. A suprapubic incision was used, and the stones were removed through the bladder.

In these cases a transverse incision through the skin and fascia is to be recommended, for then the mesial incision between the recti can be easily carried outwards through the muscle.

[1] *Annals of Surgery*, Baltimore, 1903, No. 5.
[2] *Annals of Surgery*, Dec. 1904.

(m) To Expose the Bodies of the Lumbar Vertebræ

173. Lumbo-Vertebrotomy. We insert here the description of the operation for exposing the bodies of the lumbar vertebræ, as the region under consideration is the same as that for nephrotomy.

From the size of the lumbar vertebræ it is most common to find that circumscribed tuberculous foci here tend to give rise to abscesses, or to pain and disturbances of function without abscess, so that a speedy and thorough removal of the focus has, therefore, to be considered. The bodies of the lumbar vertebræ are exposed from the back in the following manner :—

A longitudinal incision is made towards the outer border of the prominence formed by the erector spinæ, and the lumbar aponeurosis is divided till the muscle fibres appear. In the upper part of the incision, fibres of the latissimus dorsi and serratus posticus inferior, which have their origin from the aponeurosis, are divided.

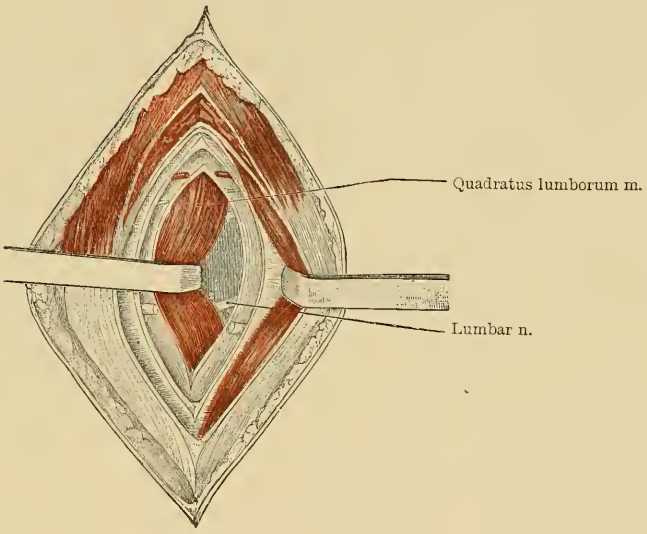

Fig. 405.

The erector spinæ is retracted towards the middle line. The deep layer of the lumbar aponeurosis is then divided and the quadratus lumborum exposed. The slips of this muscle are separated from the transverse processes of the vertebræ. In doing this the lumbar arteries and nerves, which run obliquely downwards beneath the quadratus, must be remembered. The origin of the psoas is then detached from the transverse processes, and the muscle raised from the lateral aspect of the vertebræ along with the fibres which take their origin therefrom.

(n) Surgery of the Bladder

174. High (Suprapubic) Cystotomy. Opening the bladder above the symphysis is, as a rule, quite simple, but, in order to avoid the risk of opening into the peritoneum, or of bleeding from the bladder wall, and infiltration with urine from a defective outlet, certain rules must be followed out.

Introduced by Franco in 1556 it was formerly only exceptionally performed on account of the great danger of infection, it is now, although regarded as the normal

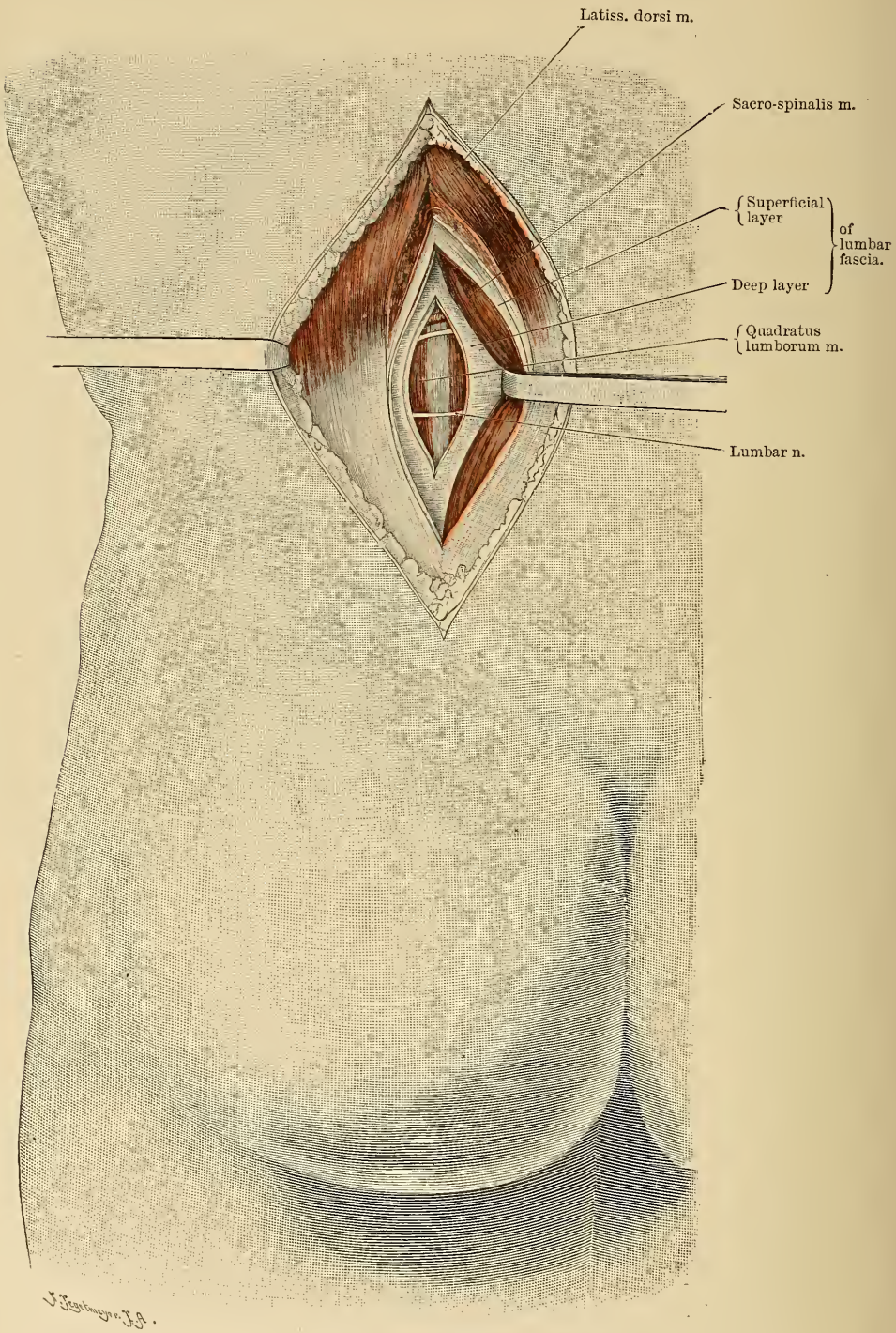
Latiss. dorsi m.
Sacro-spinalis m.
Superficial layer
of lumbar fascia.
Deep layer
Quadratus lumborum m.
Lumbar n.

FIG. 406.

method for removing foreign bodies and calculi, and for the treatment of ulcers, the extirpation of growths, and for repairing a tear in the bladder. We have learned how to avoid the dangers of infection with stagnation of urine and their results, which were formerly the main disadvantages of the method. As Fracassini[1] has shown, provided there is no infective process present, wounds of the bladder heal rapidly and well.

The operation may be quite well performed under local anæsthesia, if there are any objections to the employment of a general anæsthetic. Bier's lumbar anæsthesia is occasionally indicated and is often of value, especially if there are affections of the kidney or stomach associated with the bladder lesion. The bladder mucosa is particularly sensitive, and injury to it produces an intense desire to micturate, with pain referred to the penis.

The suprapubic incision in the case of a vesical calculus gives absolute certainty of complete removal, and offers the great advantage of primary union. On the other hand, for all cases in which the bladder must be left open and drained, the perineal opening is more satisfactory. The opening above the symphysis occasionally leaves a fistula, and, according to Auneau, the continual and often incomplete outflow from the bladder causes the patient constant annoyance.

The normal incision for sectio alta, also employed by Bardenheuer, is made, curved transversely from one inguinal ring to the other in the fold above the symphysis, through the skin and superficial fascia. A few symmetrical vertical veins in the skin must be ligatured. The fascia covering the recti is then divided and dissected upwards off the muscles, after which a vertical incision is made in the middle line and the attachments of the recti to the symphysis are in part divided, together with the pyramidalis muscles. Very convenient is the introduction of a strong ecarteur. The finger is now introduced behind the symphysis so as to draw upwards the thin fascia transversalis, the extra-peritoneal fat, and the reflexion of the peritoneum, which can either be seen or felt as a transverse fold or projection. By means of this manipulation, combined with elevation of the pelvis, forcible distension of the bladder, or of the rectum, as recommended by Peterson, is quite superfluous; a process which is attended with a danger of rupture or injury. After thoroughly irrigating it with warm boric lotion, about 6 ounces of the lotion, or an equivalent of air, are injected into the bladder.

The smooth bluish-white bladder wall, covered with a thin layer of fatty tissue containing veins, is now exposed and is easily recognised by the longitudinal direction of its muscular fibres. A loop of silk is passed through the entire thickness of the muscular coat at the lowest part of the bladder which can be conveniently reached, a second loop being similarly passed through the muscular coat below the line of reflexion of the peritoneum. The introduction of these two fixation sutures greatly simplifies the subsequent suturing of the empty bladder. Dandolo inserts the fixation sutures laterally, but they then give no help in the subsequent introduction of the linear sutures.

The muscular coat of the bladder is divided vertically between the two fixation loops until the mucous membrane is seen to bulge forward in the form of a bluish vesicle. The bleeding having been arrested, the bladder is opened by plunging the knife through the bulging mucous membrane. The finger is introduced into the opening before all the fluid or air is allowed to escape. The edges of the mucous membrane must be immediately caught up with hooks or with a thread, after which the opening may be enlarged to suit the necessity of the case, for example, to admit of the removal of a calculus or a new growth, or of the mere inspection and digital exploration of the bladder. The mucous membrane, on account of its greater extensibility, does not require to be so freely divided as the muscular coat. The bladder is closed by a double row of silk sutures, of which the first row includes the mucous membrane only. The superficial one, also continuous, includes both the muscular coat and the superjacent cellular tissue.

Before inserting the second layer of sutures the wound is thoroughly irrigated,

[1] *Policlinico*, 1905.

the hands are purified and gloves are put on. A glass drain is placed between the bladder and the symphysis and left in position for eight days. After the fascia is united, the skin wound is closed.

Suture of the bladder is strongly recommended both by Rydygier and Hofmann. If the urine is healthy and there is no inflammation and ulceration, and no bruised or necrotic tissue has been left, the wound heals best and quickest. We regard silk as the only proper suture material; catgut does not resist the tension long enough as the bladder fills and empties. We agree with Rydygier that a continuous suture is much more reliable. According to Fracassini the mucous membrane heals rapidly underneath a sero-muscular suture.

As regards after-treatment, it is best to tie in a catheter (Nélaton) and syphon the contents of the bladder into a vessel containing carbolic lotion, all aseptic precautions being employed. Sometimes the systematic passage of a catheter is preferable, if spontaneous micturition is impossible, especially if the continued pressure of the catheter causes pain and catarrhal irritation.

In all cases where the bladder has been bruised or torn in removing a tumour, and where necrotic tissue is left, or still more in the presence of infective conditions such as cystitis and ulcer, no sutures must be inserted. The wound in the bladder as well as the external wound must be left open and treated throughout by the open method. In the latter case a longitudinal incision is preferable to a transverse one through the soft parts, as it brings the superficial and deep edges of the wound parallel.

The patient enjoys greater comfort if the wound is simply left open without any packing or drainage, and the escaping urine is caught in dressings, which are frequently changed. Patients on whom we had to operate more than once greatly appreciated this open method of treatment.

The wound is only to be packed when there is fear of bleeding, and it must be drained with a large drainage tube down to the bottom of the bladder (and cavity of the wound) if the urine tends to be retained in a pocket of the bladder.

175. High (Suprapubic) Cystostomy. Reginald Harrison and Poncet place great value on the formation of a vesical fistula above the pubis in certain affections of the bladder. It is especially indicated in all cases in which micturition is painful and difficult and where the passage of a catheter, whether temporary or continuous, occasions great discomfort. Intolerable pain is experienced under the ordinary treatment in cases of severe catarrh of the bladder with consecutive urethritis, whether it be primary, or as usual a secondary inflammation associated with tuberculous and other ulcers or with new growths of the bladder and affections of the prostate.

With regard to affections of the prostate and new growths, surgery has become frankly radical and ventures to aim at removal of the primary disease. In the presence of signs of severe inflammation it may be very desirable to perform cystostomy as a preliminary to a radical operation. Temporary cystostomy may also be required in the treatment of rupture of the urethra and its sequelæ, although perineal incision or possibly repeated puncture of the bladder are sufficient.

The technique of cystostomy is similar to that of cystotomy up to the point when the bladder is opened, but, as a rule, a mesial incision should be used and extended down to the symphysis. The pyramidalis muscles should be nicked on each side above the symphysis.

The preparation of the patient is of importance. It consists in the internal administration of urinary antiseptics, *e.g.* urotropin, helmitol, and vesipyrin (30 gr. per diem) recommended by Hofmann, in washing out the bladder, and even the preliminary injection of a strong solution of silver nitrate (1 per cent).

The after-treatment is also very important. Poncet and Delorme hold that by suturing the edges of the bladder to the skin, infiltration of the surrounding tissues with urine is most effectively prevented. This, however, only affords partial protection, for the wound round about is already infected, and the stitches are likely to hinder discharge escaping from the paravesical tissue.

It is better either to insert a large drainage tube down to the bottom of the bladder, and pack the external wound all round it with antiseptic (xeroform or vioform) gauze till the risk of sepsis is past, or else stitch a tube into the bladder in a "watertight" manner and syphon off the contents, either leaving the wound round the tube open, or packing it with gauze if there is a tendency to the formation of pockets.

176. Cystectomy, Total and Partial. (*a*) *Resectio Vesicæ.* Partial resection of the bladder is undertaken in the majority of cases for tumours. No general description of the technique is required as the operation varies so much according to the position of the tumour. As long as sufficient healthy bladder can be preserved in continuity with the trigone and urethra to form a new bladder, the method of procedure can be deduced from what has been already described (*vide* Surgery of the Ureters).

One or even both ureters may be excised at the same time, and, as Krönig's experience has shown,[1] if a sufficient extent of the bladder is preserved, both ureters may, by following definite rules, be successfully implanted into a newly-formed bladder cavity. If the amount of bladder left is not large enough to allow of the ureter being implanted into it, or if the latter operation is too difficult, provided one ureter is not interfered with, the other may be implanted into it by an end-to-side anastomosis: the invagination method described above, for uniting the renal and vesical ends, cannot, of course, be used.

One point in particular which deserves further attention in the case of an extensive resection of the bladder is the selection of a method which will give sufficient room to allow of the bladder being securely stitched and at the same time enable one to implant the ureters in the reduced bladder cavity.

In order to get better access to the bladder, the suprapubic incision has been prolonged downwards with resection of the symphysis. Niehans has attempted unilateral resection of the symphysis, while Helferich excised subperiosteally a triangular portion (the base upwards). Brahmann turns up a similar wedge leaving it in connection with the recti and pyramidalis, and afterwards fixes it again in position as an osteoplastic flap. Heussner has proposed to chisel through the pubis on both sides.

Manz[2] has lately recommended an osteoplastic resection of the symphysis pubis, which gives very good access with moderate damage. He takes advantage of the simplicity and security afforded by the use of Gigli's wire saw in dividing the pubis. Through an incision extending from one pubic spine to the other, he carefully separates the root of the penis from the pubis, and divides subperiosteally the descending ramus of the pubis with the wire saw as far as the mid-point of the obturator foramen. The horizontal pubic ramus is then dealt with in the same way. Care must be taken in making the skin incision to avoid the spermatic cord, and in separating the periosteum and dividing the bone the dorsal vessels of the penis and the obturator vessels and nerves must not be injured.

The flap is turned up along with the recti and pyramidalis muscles, and, after the operation is completed, is replaced and fixed accurately in position.

One has to decide in each individual case whether resection of the symphysis is unavoidably necessary for excision of a tumour of the bladder. As a rule it is possible to get satisfactory access to the bladder as far as the prostate by a suitable abdominal incision with section of the pyramidales and the use of a strong retractor; the operation can in any case then be carried out extraperitoneally by packing off the peritoneum or even by turning it back and temporarily closing it with sutures.

Berg has devised a radical operation for malignant growths of the bladder analogous to Wertheim's operation for carcinoma uteri. Laparotomy is performed and the peritoneum divided behind the bladder so as to allow of the lymphatic vessels and glands lying along the internal iliac artery being removed. The wound is then drained from the perineum or vagina and the peritoneum is closed above.

[1] Matthias (*Beitr. z. klin. Chir.* Bd. 42) has described two cases of carcinoma of the bladder successfully treated by Mikulicz in this way by cystoneostomy of one ureter.

[2] *Centralbl. f. Chir.*, 1904, No. 15.

(*b*) *Total Excision of the Bladder.* F. S. Watson[1] has published the results of the operative treatment of bladder tumours in 653 cases,[2] including those reported by Albarran. Of these, 410 were malignant. The mortality in 91 malignant cases in which partial resection was performed was 18·6 per cent; in 222 cases, in which the tumour was removed by suprapubic operation without resection, the mortality was 28 per cent; while in 25 cases in which total extirpation of the bladder was performed for cancer, it was 56 per cent. Of the cases of carcinoma operated on, 10 per cent remained free from recurrence after three years, which corresponds precisely with the percentage in the case of papillomata. The worst results as regards mortality and recurrence occurred in sarcoma and myxoma.

Technique of Suprapubic Total Excision (according to Watson's description). Laparotomy by a mesial incision. The peritoneum covering the bladder is split in the sagittal plane from front to back in its whole extent (adherent portions must be removed with the bladder), and separated by blunt dissection as far as the entrance of the ureters. The latter are then ligatured and divided. If the prostate and seminal vesicles are involved, they must always be removed.

The urethra is then transfixed from behind forwards with a curved needle at the junction of its prostatic and membranous portions, and the ligature tied on both sides. It is again transfixed and ligatured a little higher up, after which it is divided between the ligatures, and the bladder and prostate are removed. The hæmorrhage is arrested, the peritoneum stitched, the laparotomy wound is completely closed, and perineal drainage employed.

Combined Method. Watson recommends a combined method (analogous to the combined method previously described of excision of the rectum) especially for those cases in which the prostate and seminal vesicles are to be removed at the same time. In it the prostate and seminal vesicles are first separated through a wound in the perineum, and then laparotomy is performed as described above.

The most important point in connection with total excision of the bladder is the method of dealing with the ureters. In regard to this, Watson takes up a very definite position. He does not attempt any form of ureteral implantation, as it is to this cause that the mortality is attributable. He performs lumbar nephrostomy instead some time (four to six weeks) before. In this way the second operation is shortened, and the danger of retention of urine, ascending infection of the kidneys and infiltration of urine into the peritoneum is avoided.

Watson gives a table showing the results of implantation of the ureters in 114 such cases. The death-rate due to the ureteral implantation was 44·6 per cent, whereas in 979 cases in which nephrostomy was performed, the mortality was only 15 per cent; these include 626 cases collected by Schmieden. Nephrostomy should not be performed on both sides simultaneously, but an interval should elapse between the two operations.

The simplest form of nephrostomy consists in pyelostomy, either by stitching the edges of the opening in the renal pelvis to the skin, or by inserting a drainage tube into it, and stitching it in position. The ureter is ligatured and cut across close to the pelvis of the kidney. Even when the nephrostomy is performed through an incision in the kidney substance, and a drainage tube is inserted to keep the wound in the latter open, it is very well borne and functions for years without any trouble.

Another method is that proposed by Goldenberg.[3] Goldenberg, as a result of operations on dogs, recommends implanting the ureters into a loop of the lower ileum, which is then closed, and sutured to the abdominal wall where it is opened.

[1] *Annals of Surgery*, Dec. 1905.

[2] *Vide* also Rafin, Assoc. française d'urologie, Oct. 1905.

[3] A loop of ileum might first of all be isolated, as in Roux's œsophago-jejuno-gastrostomy, by resecting a portion lower down, preserving its blood-supply, and implanting it under the skin of the anterior abdominal wall down as far as the scrotum or under the skin of the penis, or by keeping both ends open by stitching them to the skin, the oral end above, and the anal end below. At the main operation the ureters would be brought into this open receptacle, which has been thoroughly cleansed, and which by peristalsis carries the urine downwards, where it could be caught at the scrotum or penis in a receptacle.

Arnold Schwytzer[1] has performed one complete extirpation of the bladder by the combined method, and inserted the ureters into the rectum. He comes to the conclusion, however, that it is best to follow M'Cosh's plan and simply conduct the ureters into the subperitoneal space left by the removal of the bladder, and collect the escaping urine in a receptacle. It is not improbable that in men the false bladder would empty into the urethra, as occurs after excision of the prostate.[2]

177. Perineal Cystotomy. The perineal route used to be the favourite one for opening the bladder, especially for the removal of stones. Before measures for keeping the wound aseptic were known, chief attention was given to mechanical considerations, viz. the drainage of urine from the open bladder, and the discharge from the wound; as primary union was out of the question, there was no advantage in being able to see clearly either to suture the bladder or to close the wound in layers.

In the old days perineal lithotomy was a very simple operation. The lateral operation in the hands of expert surgeons lasted only a few minutes and was performed in three steps: (1) Opening of the membranous urethra by cutting down on to a grooved staff; (2) Division of the prostatic urethra and base of the bladder together with the prostate in a backward and outward direction with a probe-pointed knife; (3) Passage of lithotomy forceps into the bladder and extraction of the stone. A drainage tube surrounded by a tampon was inserted into the bladder and the intervening space packed with gauze so as to check any bleeding.

Cunningham's collection of cases in 1887 shows how good the results were even in the days when aseptic methods were but little developed; of 7201 cases of perineal lithotomy only 11 per cent died (42 per cent in 147 suprapubic). White also records a mortality of 3 per cent from the perineal and 12 per cent from the suprapubic operation in children. This is now entirely changed and the perineal operation is rarely employed. It is only used in cases where there are severe disturbances in the bladder, and where everything depends on obtaining rapid and safe drainage and also where stones are lying in diverticula at the back of the bladder.

(o) Surgery of the Prostate and Urethra

178. General Remarks. Although the prostate properly belongs to the reproductive system, it is so intimately connected with the bladder and urethra that it is better to consider its surgery here. Further, it gives rise to urinary disturbances much more than to disturbances of the reproductive functions.

Now that it has been proved that prostatectomy affords a radical and safe cure in patients suffering from enlargement of the gland, the surgery of the prostate has in recent years received a great impulse. Such an abundant literature has accordingly sprung up that the attempt to cover even the most important works on the subject would overstep the limits of a text-book. We will, therefore, only consider the conclusions arrived at by numerous discussions and describe the operative technique which at the present time is most to be recommended.

In addition to hypertrophy, surgical interference has to be considered in other affections of the prostate, *e.g.* in malignant disease, especially in its commonest form, carcinoma, or in tuberculosis and prostatic abscess. Tuberculous disease of the prostate is usually combined with a similar affection of the seminal vesicles.

179. Prostatectomy.[3] This operation is called for when the enlargement of the

[1] *St. Paul's Med. Journal*, 1905.

[2] Instead of a false bladder bounded merely by the surfaces of the wound, the isolation and transposition of a loop of ileum into the position of the bladder might here be considered. After shutting off the peritoneum above, the loop might be simply left open above and below and the ureters placed in the upper oral end, the peristalsis being left to carry the urine into the open membranous portion.

[3] According to Watson, Leroy d'Etiolles performed the first prostatotomy in 1832, and Billroth and Dittel performed the first total prostatectomy. American surgeons were the first to employ it generally. The perineal method is associated with the names of Gouley, Goodfellow, Murphy, Nicoll, White, Carpenter, and M'Lean, the transvesical with the names of M'Gill and Delafield, Watson, Fowler, Guiteras, Fuller, and Young. In England, Reginald Harrison and before all Freyer have brought the transvesical method into great prominence. In Germany, Czerny and Mikulicz employed perineal

gland gives rise to retention of urine, a symptom which is generally the first to attract the patient's attention. Of course the paradoxic type of frequent micturition is often present. It is not justifiable to operate merely because the prostate is hypertrophied without there being any disturbance of urination. But, on the other hand, the indications for operation are clear in all cases where the patient has otherwise before him the inconveniences and ultimate fate of a catheter life.

There are, of course, cases in which it is advisable not to operate, as, for example, when complications exist which would involve risk to life in the event of operation being undertaken. Certain complications, as, for example, local inflammatory conditions with fever, will yield to operative interference. In these cases, however, it is often better simply to drain the bladder (cystostomy) first of all, and delay the radical operation for some time.

Associated disease in other organs must of course be regarded as a contraindication. The general condition of every patient must therefore be taken into account and considered according to the rules given in the introduction. According to Legueu, particular attention must be paid to the condition of the kidneys, for Watson has shown that one-third of the cases in which kidney complications are present succumb to operation. If associated with bladder trouble, they are not always easy to recognise.

The most remarkable fact which the extensive employment of prostatectomy has revealed is, that one can remove the prostatic portion of the urethra in whole or part together with the prostate, without producing any real impairment of the function of the bladder. This is largely contrary to our notions regarding the sphincter-action of the bladder, and seems to show that continence of urine depends much more, or even essentially, on the preservation of the musculature of the membranous urethra, rather than on the so-called neck of the bladder.[1]

Legueu gives an extremely instructive description of the results 1½ months after prostatectomy by Freyer's method.[2] The cavity left by the removal of the prostate forms a simple smooth dependent pocket of the bladder and opens with smooth edges into the shortened urethra.[3]

The development of the technique of prostatectomy as illustrated by the numerous discussions in the surgical societies of all countries forms an interesting study terminating in the present view that the intravesical operation, called after Freyer, is to be preferred to the perineal.[4] Experience has taught the strongest adherents of the latter operation to appreciate the advantages of the high operation. Experience has also shown that, as a rule, prostatectomy takes the form of enucleation not of extirpation with the knife, the latter being only necessary in dealing with malignant growths.

Since this point has been realised, the technique of the intravesical operation has been greatly improved, and the mortality which was formerly much higher than after the perineal operation has been reduced to proper proportions. What necessarily brought the majority of surgeons to adopt the transvesical method is the great simplicity of the operation, and still more the certainty of the result as regards normal evacuation of urine, with preservation of the reproductive function, since the vasa deferentia and seminal vesicles remain intact.

(*a*) *Transvesical Enucleation of the Prostate.* This operation, first practised by

prostatectomy most commonly. Kümmel and Rydygier have given an account of their own operations of intracapsular resection. French surgeons, Proust, Hartmann, Tuffier, Legueu, and, most of all, Albarran, have accurately described the technique of the perineal method.

[1] This supports Finger's view that the function of the compressor urethræ is to retain the urine, though Leedham Green has shown that it is not true that the prostatic portion is filled with urine when the bladder is full (*Brit. Med. Journ.*, Aug. 1906).

[2] Freyer has contributed two and Verhoogen one post-mortem report.

[3] Fig. 407 shows the truth of Schwytzer's and M'Cosh's statement, that in the case of a total excision of the bladder, the ureters open simply into the cavity left, and the urine is discharged per urethram ; cf. chapter on Total Excision of the Bladder.

[4] The French surgeons, Albarran, Hartmann, Tuffier, Proust, Legueu, and others who were formerly ardent supporters of the perineal method, have now resorted to the intravesical method, especially Hartmann, Proust, and above all, Legueu.

McGill, but called after Freyer, its most zealous exponent, is performed as follows[1] :—

The bladder is opened according to the rules laid down for suprapubic cystotomy (*vide supra*). It is first thoroughly washed out and partly filled with warm boracic lotion. The patient is placed in the Trendelenburg position, the bladder exposed through a mesial incision and steadied, while a longitudinal incision is made into it. The edges of the bladder wound are grasped and the interior swabbed out.

With the finger-nail, blunt dissector, or the knife, the mucous membrane is

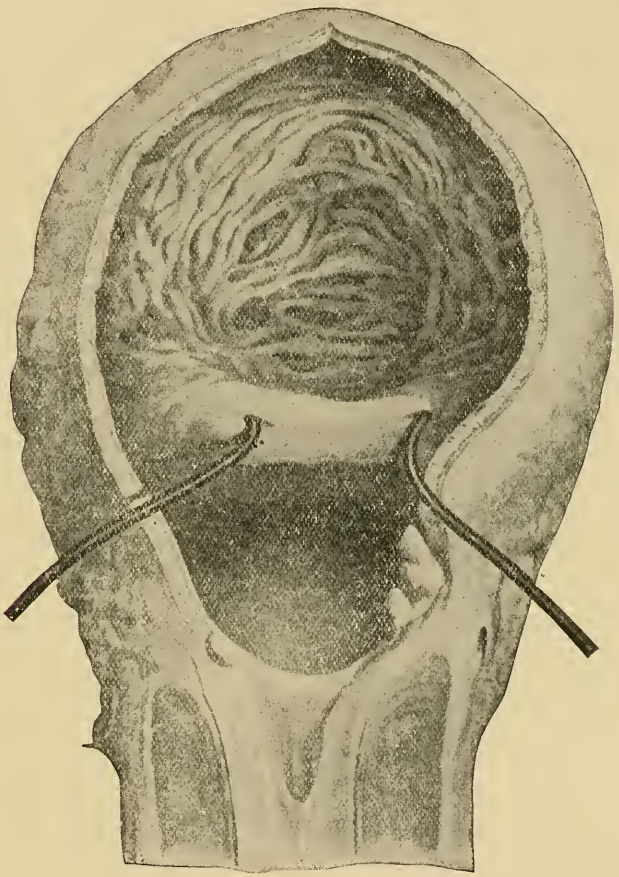

Fig. 407.

torn or cut through immediately behind the internal orifice of the urethra, while at the same time the prostate is forcibly pushed upwards by the fingers of an assistant or of the operator's left hand in the rectum. Guiteras grasps it from above with bullet-forceps. The finger is now insinuated under the mucous membrane on the posterior aspect of the prostate between the capsule and the sheath, and the latter is separated from the whole of the posterior surface as far as the ejaculatory ducts and vas deferens. By gradually burrowing under the prostate the hypertrophied mass can either be detached from the urethra or if it is too firmly adherent

[1] The description follows that of Legueu, with whose kind permission we reproduce the figures from his report read at the 15th International Congress at Lisbon in 1906.

it can be removed along with the portion of the urethra containing the colliculus seminalis, by division of the membranous urethra.[1]

The after-treatment of the wound is as important as the preparation. Freyer passes a large tube ($\frac{3}{4}$ of an inch in diameter) down to the base of the bladder, through which irrigation with a weak antiseptic is carried out, the dressings being frequently changed. The tube is taken out after four or five days, and irrigation is then practised through the urethra. In the case of a septic bladder, careful preliminary treatment is of more importance than the formation of a perineal drain, as Fuller and Israel recommend. Direct drainage of the prostatic space is restricted

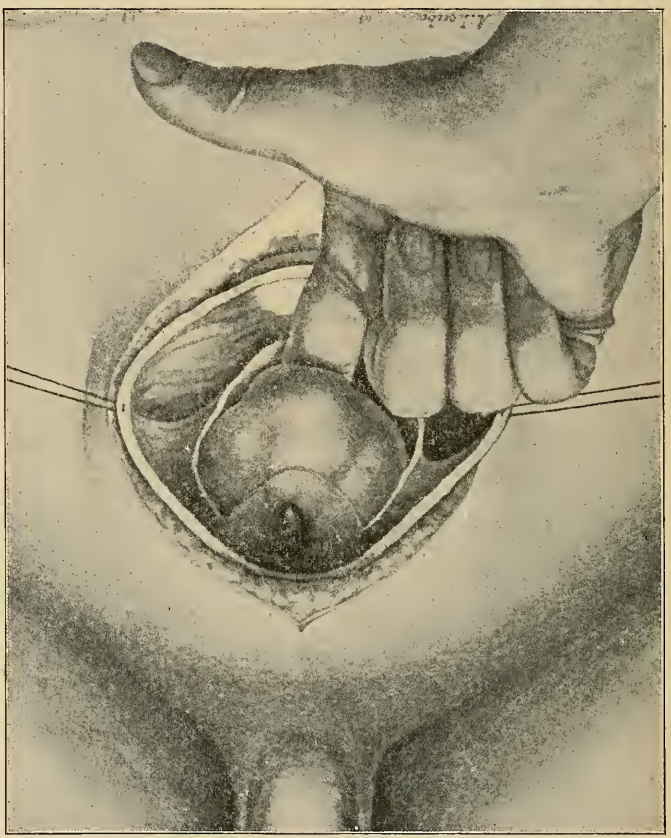

FIG. 408.—Transvesical enucleation of prostate (Legueu). The mucous membrane behind the internal urinary meatus is incised and the posterior surface of the prostate freed by pushing the finger between the capsule and the sheath.

to cases where there is a high degree of urinary decomposition, and in these cases it is probable that the perineal operation would be better.

Legueu checks the bleeding by packing the cavity left by the removal of the prostate with gauze soaked in peroxide of hydrogen, and inserts a double tube, after the Guyon-Perier pattern, through which the bladder is syphoned and irrigated. The gauze is left in for four days.[2]

[1] White (*Annals of Surgery*, Dec. 1904) regards suprapubic total enucleation without injury to the urethra as the only correct operation.

[2] Thomson (*Brit. Med. Journ.*, July 1906) employs calcium chloride as a prophylactic against bleeding. We consider the very efficacious "Klysmen" with 2 per cent gelatine solution (to 200 g.) still more valuable.

The retention is always relieved and natural evacuation of urine commences in the second or third week. Very rarely does a fistula form. This, however, does not apply to partial prostatectomy which Rovsing recommends in cases where the middle lobe is especially prominent. The results of partial prostatectomy are no better than those obtained by Bottini's operation, which is still approved by Freudenberg, Jaffé, Giordano, and others.

(*b*) *Perineal Prostatectomy.* This was the earliest form in which prostatectomy was performed. It is now restricted to cases which are unsuitable for enucleation, *i.e.* diffuse, hard, and comparatively small prostates, the removal of which has to be carried out with the knife instead of by blunt dissection. It is also employed

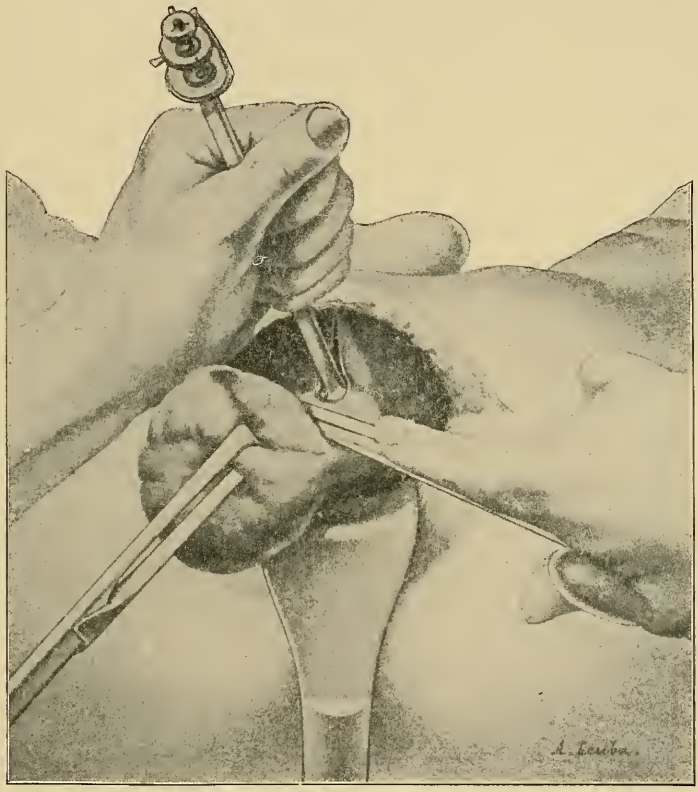

FIG. 409.—Perineal prostatectomy (Legueu). The prostatic tractor, which has been inserted into the bladder through an incision in the urethra, forcibly depresses the floor of the bladder.

in cases where the general condition of the patient is not good, and where there are marked changes in the bladder accompanied by fever. In such cases one has often to consider whether it would not be better merely to treat the urgent symptoms in the first instance and drain the bladder.

If there is a doubt whether prostatectomy is feasible, the perineal operation is the more suitable, as it is attended with less danger. Although the prognosis as regards mortality is better, Legueu, who collected the cases reported by Watson, Escat, and Proust, has shown that in 1026 cases[1] a fatal issue occurred in 9 per cent.

[1] The causes of death after prostatectomy are fully considered in a paper by Teuney and Chase (*Journ. of American Med. Assoc.*, May 1906). Uræmia is the most frequent, then hæmorrhage and pneumonia. The authors emphasise the great importance of the preliminary and after treatment and the necessity of letting the patient up early.

When enucleation from below is impossible and the gland has to be removed with sharp instruments, in addition to loss of sexual function the rectum is liable to be injured, an accident which may lead to the formation of a fæcal and urinary fistula. It is in this class of case especially that the perineal method is useful. If we follow Young and Rydygier's advice and employ the perineal method in cases that are suitable for enucleation, two lateral incisions are made, and then the lobes are reached and removed by forcible blunt dissection, the above disadvantage being thus avoided.

The last objection to the perineal operation, viz., that incontinence of urine often results, is removed if the enucleation is performed only through an incision in the sheath. Incontinence occurs when the membranous urethra has been injured. The musculature of this portion is not interfered with in suprapubic enucleation, and thus closure of the bladder is guaranteed as described above.

Technique of Perineal Prostatectomy. When the perineal operation is employed in preference to the transvesical method, it is essential to have good access. The mesial incision must therefore be abandoned. This applies all the more to those cases where the hypertrophy is diffuse and firm, where the gland is difficult to enucleate, and where there is a suspicion of malignancy. According to Young[1] one-seventh of the prostatic enlargements in men over fifty are cancerous. The cancer may remain intracapsular for a long time, grows slowly, and rarely gives rise to local metastasis and glandular disease. Good access in these suspicious cases is essential if a thorough excision is to be performed. We agree with Zückerkandl and adhere to the incision we described in the first edition of this text-book. Albarran and Watson use a similar incision, while in malignant cases Young uses a V-shaped incision.

As in the suprapubic operation, perineal prostatectomy may be performed under local anæsthesia (Tinker) with a very short administration of a general anæsthesia. Novocain and adrenalin are injected in front of and internal to the tuber ischii. The adrenalin limits the bleeding. A curved incision is carried from one ischial tuberosity to the other, its convexity reaching forwards to the lower border of the pubic symphysis (Fig. 410). After division of the skin and thin superficial fascia, the incision comes down laterally upon the fatty tissue which is continued upwards into the ischio-rectal fossæ between the pelvis and the rectum. This fatty tissue is now dissected through as far as the under surface of the levator ani, the fibres of which extend from before backwards and from without inwards towards the rectum. By this means the inferior hæmorrhoidal vessels and nerve situated posteriorly, and the transverse perineal vessels and nerve, the artery and nerve to the bulb, and the transverse superficial perineal muscles, all situated anteriorly, are pushed forwards and drawn out of the way. The bulb of the urethra, and the muscular fibres of the accelerator urinæ, which extend forwards and outwards from either side of the median raphe, are exposed at the anterior part of the wound. The fibres of the transverse perineal muscles extend from the posterior end of the bulb outwards towards the ascending ramus of the ischium. The fibres which connect the external sphincter ani, the accelerator urinæ, and deeper, the recto-urethralis muscle (Roux), at the central point of the perineum are divided transversely close to the bulb, which is then drawn forward along with the transversus perinei. By cutting transversely and more deeply towards the posterior surface of the bulb, we expose the posterior fibres of the compressor urethræ muscle, which covers the under surface of the membranous urethra. Above this muscle is the prostate, which is covered on its postero-inferior surface by a dense layer of connective tissue (part of the capsule of the prostate, derived from the pelvic fascia) containing non-striped muscular fibres. This layer must be drawn downwards and divided transversely, the smooth posterior surface of the prostate being thereby exposed, so that the finger can now be pushed upwards upon it as far as its upper border. The vasa deferentia may be easily recognised still deeper, converging downwards and forwards (Fig. 411). Lying immediately outside these are the vesiculæ seminales, which may be dissected out with a blunt instrument.

[1] *Journ. of American Med. Assoc.*, March 1906.

By drawing backwards the rectum with a long blunt hook, a layer of connective tissue with fibres of the levator ani is put on the stretch upon either side.

The subsequent steps of the operation vary. Those surgeons who prefer the perineal method even for enucleation, divide the sheath laterally (Nicoll, Pyle, Young, and Rydygier), grasp it with forceps, and then remove first the lateral lobes and then the middle lobe, generally without dividing the prostatic urethra, sometimes dividing it as is the practice of Albarran and Watson.

Here again the difference between enucleation and excision of the prostate must be stated. The conditions are analogous to those of colloid goitres. One may either excise, *i.e.* remove the gland which is compressed and atrophied in places

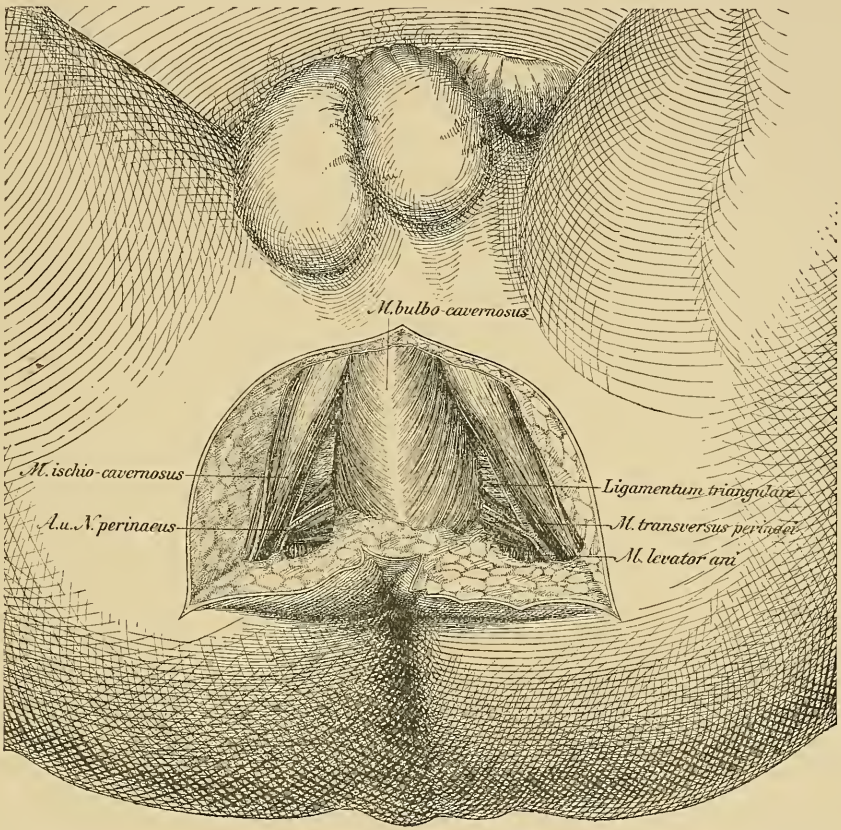

FIG. 410.—Dissection to expose the prostate, seminal vesicles and vasa deferentia through a curved incision in the perineum.

by the development of the colloid masses, and which is spread out over the latter like a capsule, merely leaving the connective tissue, the outer capsule, as is done in our intracapsular excision. Or the masses may be shelled out not merely from the outer capsule, but also from the inner, the gland capsule being left behind (as Burkhardt has shown) *i.e.* enucleation is performed.

The removal of the adenomatous masses of the prostate by blunt dissection should also be called enucleation. For as Legueu emphatically states "every prostatectomy is incomplete" in so far as the prostate is left behind. Examination of the preparations made by him and also by Motz, shows that prostatic tissue is always left behind like a glandular capsule, after removal by blunt dissection. It is often atrophic and compressed by the new formation of the nodules.

In cases in which the prostate might be easily enucleated by the suprapubic method, but in which for some reason the operator prefers to employ the perineal route, the technique of the operation after exposing the prostate and retracting the rectum with a broad retractor, is usually the following :—

The urethra is opened on a grooved staff as near to the prostate as possible (avoiding the compressor urethræ). A finger is pushed into the bladder to determine the length of the prostate and whether there is a middle lobe. Young's instrument or Legueu's "desenclaveur" is inserted through the opening, and the floor of the bladder

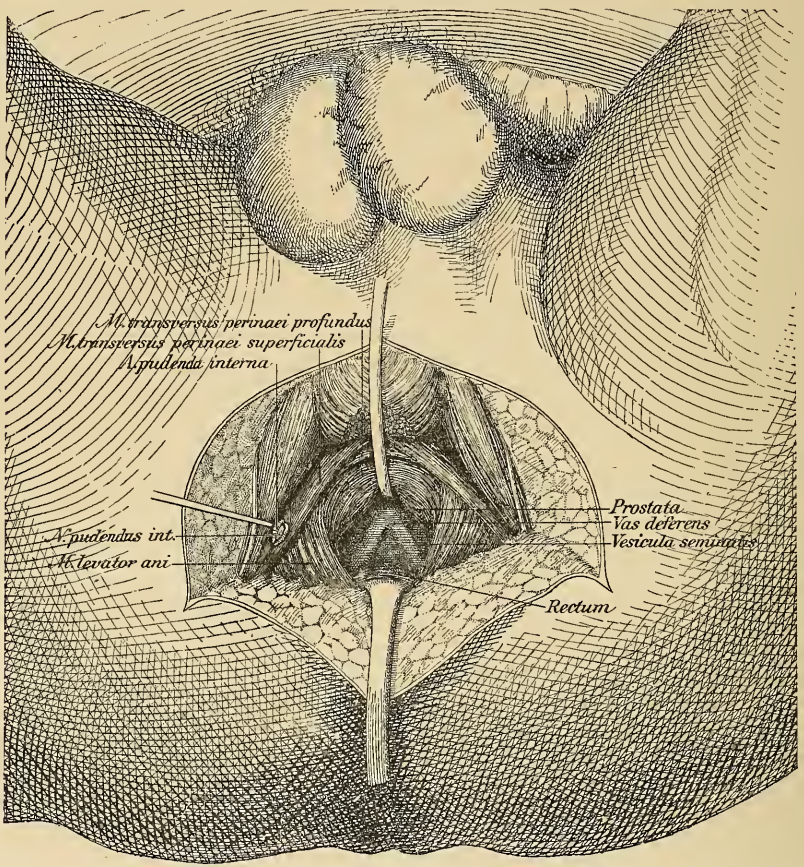

FIG. 411.—Dissection to expose the prostate, seminal vesicles and vasa deferentia through a curved incision in the perineum.

is pressed firmly downwards. The prostatic urethra (Albarran and Watson) is divided in the middle line as far as the neck of the bladder.

If, contrary to expectation, it is found that the prostate can be enucleated from the incision in the urethra, one proceeds to remove it by blunt dissection with the finger or dissector, possibly even pulling out the nodules with Museux's forceps. If it is found that enucleation is impossible, or if there is a suspicion of malignant growth one proceeds to a real total excision of the prostate.

(*c*) *Real Total Excision of the Prostate.* Young[1] describes the following method for carcinoma of the prostate. After insertion of the instrument for depressing the floor of the bladder, the gland along with the seminal vesicles

[1] *Bulletin of Johns Hopkins Hospital*, October 1905.

is separated behind from the rectum, Denonvillier's fascia being removed along with it.

The membranous urethra is cut across and the puboprostatic ligaments are divided. The prostate is then freed laterally, the bladder pulled well forward, and incised behind the prostate, so that we expose the trigone and orifices of the ureters. The bladder is divided transversly 1 cm. in front of these, after which the seminal vesicles, glands, and the vasa deferentia are separated (high up) and cut across.

Young states that it is easy to suture the membranous urethra to the bladder, and to close the latter in a sagittal direction. After uniting the edges of the levator we partly close the skin wound, insert a tampon down to the site of suture and maintain a catheter in the bladder for some time.

180. External Urethrotomy with Excision and a Plastic Operation. If it is desired simply to expose the urethra, a short mesial incision is all that is required, the so-called raphe-incision. It inflicts much less damage than a lateral incision which involves branches of the internal pudic artery and nerve as they run towards the middle line (inferior hæmorrhoidals, perineal arteries, and the artery to the bulb).

This is the principal operation performed on the perineum for diseases in the region of the urinary passages, as it often suffices to give the necessary access in cases of bladder disease. The operation is performed for relapsing stricture, for strictures complicated by fistulæ and abscesses, and in cases which are combined with infection and infiltration of urine.

Reginald Harrison reports cases in which rigors and other threatening symptoms following internal treatment of a stricture immediately disappeared when external division was performed.

The operation is also indicated in dense and impermeable strictures, especially those of traumatic origin. These require either simple external division, or excision of the narrowed portion along with the surrounding cicatricial tissue, which forms a fibrous mass in the corpus spongiosum. Harrison points out that, in cases of rupture of the urethra, division of the canal from without lessens the amount of cicatricial tissue on account of the free drainage which it establishes.

As regards the operation, Harrison employs Wheelhouse's method. Unless the stricture is completely impermeable, with a fistula behind it, he will not operate without previously performing internal urethrotomy. He considers that any stricture which allows of the passage of urine will also admit a small sound, and consequently a preliminary operation with Maisonneuve's instrument can be performed so as to admit of the introduction of a suitable grooved staff. If the stricture is not dilated it may be a difficult matter to discover the urethra behind a stricture or a tear. It is even necessary occasionally to open the bladder above the symphysis and perform retrograde catheterism. A preliminary internal urethrotomy, followed by the introduction of a grooved staff, renders the operation as simple as the division of a normal urethra for digital exploration of the bladder, as in Harrison's method. It should be done with a median incision.

For excision of a cicatrix, or for resection of the urethra, the canal should be opened in front of and behind the stricture and the fibrous mass excised. The ends of the divided urethra are carefully united with fine silk and catgut, after which the wound should be completely closed with sutures (preferably Socin's fine aluminium bronze wire) which extend down to the urethra. No drain should be introduced. Primary union is obtained along with an excellent passage for the urine. A soft catheter should be kept in till the wound is healed, *i.e.* for fourteen days, and the bladder maintained empty by syphon drainage into a vessel containing carbolic lotion. Irrigation should also be carried out.

If it is impossible to pass an instrument through the stricture beforehand, the urethra should be opened in front of the stricture by cutting on to a silver catheter, and the edges retracted with fine sharp hooks. A fine silver probe may then be passed through the narrow portion and the stricture be divided. The callous cicatrix (usually situated in the corpus spongiosum) is then excised and the healthy edges of urethra behind are grasped with hooks, and stitched to the urethral mucous membrane in

front with three or four silk sutures with intermediate ones of catgut. The deep soft tissues covering the urethra are then very carefully united with several sutures, which are passed deeply so as to take a good grip, the Nélaton catheter having been previously introduced. Finally the skin is closed without drainage. Traumatic as well as gonorrhœal cicatrices can be accurately excised in this way.

Forgue[1] exposes the posterior urethra without using a staff through an incision similar to our pointed incision (the anus being closed with clamps). He lays particular emphasis on the importance of Roux's muscle the "recto-urethralis," which according to Proust and Gosset is the key to the situation in the recto-prostatic space. It is divided, care being taken to avoid injuring the rectum. The fibres of the levator ani are separated at the sides of the prostate, and the prostato-peritoneal fascia is pushed back. The point of exit of the urethra is well seen at the apex of the prostate.

v. Hacker and Beck were the first to make use of mobilization of the urethra, together with the corpus spongiosum, for covering in by "distensionsplastik" large gaps (up to 6 cm.) left after the excision of strictures, fistulæ, new growths, and after rupture of the urethra.

In all cases where the urethra is united by suture success can only be looked for if strict asepsis is adhered to, including the internal use of urinary antiseptics and irrigation of the bladder. In the case of an impermeable stricture, and especially if there is incontinence at the same time, this can only be obtained by puncturing the bladder above the pubis, emptying it, and thoroughly washing it out, as otherwise, after division of the stricture, there is a free flow of infective stagnant urine, and if the wound is sutured, very acute infection may result. We have seen the temperature remain at 42° C. for days, and progressive infection only arrested by cutting the stitches.

C. Beck, v. Hacker, and Bardenheuer first employed "distensionsplastik" in hypospadias; Beck dissected up the urethra with the corpus spongiosum along with a strip of skin at the abnormal meatus, mobilized it and implanted the urethra into the glans after dividing the skin in front and preparing the glans. It is as well to bring the urethra out rather high up in the glans as it has a tendency to become displaced downwards. Vuillet makes a preliminary perineal incision.

(p) The Surgery of the Male Reproductive Organs

181. General Considerations. The surgery of the male genital organs is so simple that no detailed description of the individual technique is required. One incision is applicable for all operations on the testicle and spermatic cord—our inguinal incision. Although we described this incision in our earlier editions, it has been repeatedly rediscovered since, most recently by Pasquimangali, and is even referred to in the *Centralbl. f. Chir.* No. 47, 1906, as something quite new.

We have shown that the incision over the inguinal canal, whether combined or not, according to the nature of the case with opening of the canal, enables one, after dividing the infundibuliform fascia (covered by the cremaster) to dislocate upwards moderate-sized tumours of the testicle, and *a fortiori* of the spermatic cord, and to incise or excise them, without encroaching on the skin of the scrotum, which does not heal readily by first intention. It is only when there are adhesions and fistulæ that a corresponding portion of skin must be cut out. If the latter is extensive, the inguinal incision is not necessary.

The inguinal incision presents, moreover, the great advantage that the spermatic cord is exposed at a point where it can be readily ligatured, temporarily compressed, or shortened (as in cases of varicocele); and at the same time it allows one to reach the vas higher up (in cases of tuberculosis) and to deal with a hernia which is frequently associated with affections of the testis. It has the further advantage that enlarged glands can be reached not only in the groin, but in the iliac fossa and extending up into the pelvis. Hence we include the latter operation here.

[1] *Deutsche Zeitschr. f. Chir.* Bd. 75.

182. Castration. An oblique incision is carried downwards and inwards over the inguinal canal a finger's-breadth above and parallel to the inner half of Poupart's ligament. This incision corresponds exactly to the line of cleavage of the skin, and therefore comes together very easily. Two large veins which descend in the superficial fascia, the one at the outer and the other at the inner part of the wound, require to be ligatured. When the incision is prolonged outwards the superficial epigastric vessels are divided. The external spermatic fascia, which is prolonged down upon the cord from the edges of the external abdominal ring, is then divided; next, the muscular fibres of the cremaster (from the internal oblique) are similarly treated; and, lastly, the strong infundibuliform fascia, the continuation of the fascia transversalis. Within the latter lie the spermatic cord, or the round ligament, according to the sex, and possibly a peritoneal diverticulum in the form of a hernial sac.

In *castration* the testicle is pulled upwards, the vas deferens is cut through, and the vessels (spermatic artery, artery to the vas deferens, and the venous plexus) are individually caught up and divided. When this must be done higher up, on account of the presence of tumour nodules, or of disease (tubercle) of the vas deferens, the anterior wall of the inguinal canal (aponeurosis of the external oblique) must be slit up. Should the disease extend still deeper subperitoneally, the posterior wall of the canal must also be slit up and the canal very carefully sutured again.

Provided the testicle is not adherent to the scrotum, or markedly enlarged, it may easily be pushed upwards out of the wound and removed. Even when this cannot be done, it is well to begin by dividing the spermatic cord through an inguinal incision, for then, if the tumour is a large one, the size of a head (*e.g.* sarcoma), it can be removed without practically any bleeding. Only a few large veins between the tunica and the skin need be tied. When the cord is thickened either as a result of tumour infiltration or inflammation, it is quickest to divide it between two pairs of forceps. The large vessels are then easily seen and can be caught and tied separately.

When the skin is adherent, *castration* is performed by means of a *transverse incision in the coronal plane* at the lower end of the scrotum. After division of the skin and dartos between the larger visible scrotal vessels the testicle is shelled out. As the incision is parallel to the scrotal vessels, and parallel also to the branches of the spermatic vessels which ramify upon the surface of the tunica vaginalis towards its lower pole, it is a much more suitable incision than that which is generally employed, viz. a vertical incision, descending upon the anterior surface of the scrotum.

That castration is the correct treatment for malignant new growths is universally conceded, but there are many opponents to its adoption in tuberculosis. In spite of this important opposition, the fact remains that, in every case showing clinically undoubted tuberculosis of the testicle or epididymis, there is a danger that severe tuberculous infection may be set up by the disease spreading along the vas deferens to the seminal vesicles and prostate. The remarkable researches of Baumgarten, which met with so great approval at the thirtieth Congress of the German Society of Surgeons, 1901, show that, in animals, spread of tuberculosis can only take place upwards from the testicle, and never from the prostate downwards. All Baumgarten's pathological and anatomical researches in the human subject agree with this. Moreover, as cure without operation is very rare, and frequently imperfect, and, further, as it only occurs, as a rule, after long and troublesome suppuration, and, after all, usually results in destruction of the function of the organ, we may consider that the necessity for early unilateral excision of the testicle for tuberculosis is well established. Bruns lends his entire support to this view. In many discussions which have been held on this important subject, a sharp enough distinction has not been drawn between true castration with removal of both testicles, and the removal of one testicle only. All the disadvantages which are put forward refer only to the double operation. The unilateral operation alone has advantages, and can hardly be performed too early.

In early excision the inguinal incision is the ideal method. It allows the vas deferens to be exposed high up, and to be divided where it is healthy. The testicle can easily be freed and pulled upwards into the inguinal incision. If there are scrotal fistulæ present they can be cauterised, then excised, and the thermo-cautery applied to the wounds. The method of exposing the vas deferens and carefully inspecting it is to be preferred to Büngener's evulsion method, although the latter is very simple, because when the vas deferens is diseased it is not only of importance to divide it above the disease, but also to prevent a dissemination of tuberculous material into the surrounding tissues, in case part of the disease be left behind. To attain this object it would seem a more satisfactory procedure to expose the vas freely and to divide it with the thermo-cautery, after compression with pressure-forceps, rather than to tear it, a process which is open to the element of chance. It seems to be a good plan to inject some iodoform, or formol-glycerine, into the part of the vas which remains. Such an injection has been shown by Büngener's researches to fill the seminal vesicles.

This method will not satisfy those surgeons who adopt extreme measures and excise the seminal vesicles as well. In cases where such a thorough procedure is demanded, even this is generally not thorough enough, and the operation requires to be extended to the prostate and prostatic part of the urethra.

183. Operation for Varicocele. The incision is made parallel to Poupart's ligament, passing inwards over the external abdominal ring through skin and superficial fascia. The veins passing upwards towards the middle line are ligatured. The prolongation of the fascia of the external oblique muscle, which surrounds the cord under the name of Cooper's fascia, is divided. The looped fibres of the cremaster muscle which now appear are divided, together with the tunica vaginalis communis (infundibuliform fascia), which lies below it. Traction is made on the cord till the testicle is pulled out of the wound.

The spermatic vein, which may be as thick as a pencil, is now isolated at the external inguinal ring. The higher up this is done the more easily is it performed. The isolation is then carried downwards, and the branches joining it from time to time are ligatured and divided. In this way 4 to 6 ins. of the vein can be isolated. The tributaries begin to get more entangled and more numerous just before the testicle is reached. The main vein is now ligatured above and below, the ends of the ligatures being left long. These ends are tied together after the vein has been resected so as to shorten the cord and suspend the testicle higher up.

The results thus obtained are very good. In 25 of our cases treated in this way, whose history Hauswirth was able to trace a number of years afterwards, 23 were found to be quite cured; in no case did any atrophy of the testicle result. In none of our 47 cases collected by Hauswirth (Berne Dissertation) were there any evil consequences. Vince (*Journal de chir. belge*, Sept. 1904) tries to improve the function of the cremaster by resecting a transverse strip of it about 2 inches broad. In our opinion, the innervation of the muscle would be destroyed by this procedure: at the most plication and suture might be permissible.

Should a much dilated vein be found at the external abdominal ring closely associated with the vas deferens it must be tied as high up as possible.

Finally, if the scrotum be particularly lax, a part of it should be resected so as to shorten it. The wound is closed, and no drain is inserted. The operation may quite well be performed after the injection of cocaine. Narath slits up the inguinal canal in order to apply the ligatures higher up, but this we consider unnecessary. The principal object to be attained is to interrupt the pressure of the column of blood extending from the left renal vein to the vessels of the cord.

184. Operation for Hydrocele.—The sac is reached by the incision described for castration. If very large it may first be partially emptied by puncture. The tunica vaginalis communis (infundibuliform fascia) is very carefully divided, and the tunica vaginalis propria, which is tense and translucent, is freed up to the testicle by stripping off the tunica communis. The propria is now opened, the fluid evacuated, and the condition of the testicle and epididymis is carefully examined.

The parietal layer of the tunica propria is then removed, with exception of just enough to cover the testicle closely when united with a fine continuous silk suture. We have always obtained a radical cure after this operation.

185. Orchidopexy for Retention of the Testis. Lanz[1] has shown that a retained testis is at the same time imperfectly developed, and that this is the cause of the incomplete descent. He has in addition discovered atypical gland epithelium in the retained testis. He was not able to demonstrate the presence of strong peritoneal adhesions.

On the other hand we have seen the descent of the testis very considerably interfered with by a short and generally patent processus vaginalis, as well as by adhesions between it and the tunica vaginalis communis (infundibuliform fascia).

By careful incision and division of Cooper's fascia, the cremaster, infundibuliform fascia, and above all the processus vaginalis peritonei all round, the testicle can often be pulled well down and fixed by sutures to the surrounding parts. It is not always possible, however, to bring the testicle down to the bottom of the scrotum (as we found recently in the case of a man aged thirty-four) and still less to keep it permanently there.[2]

Numerous attempts have recently been made to keep the testicle down by fixing it to some unyielding part in the thigh. Stitching to the scrotum or to the other testicle (Gersuny) is not sufficient. Lohnhard and Katzenstein have adopted the most drastic measures. They push the testicle out through a slit in the bottom of the scrotum and stitch it to the thigh. De Beule stitches the scrotal wound as well to the edges of the incision in the thigh so as to cover over the testicle.

Lanz transfixes the lower pole of the testicle with a loop of thread, which is brought out of the scrotum and fixed to a strip of adhesive plaster on the thigh. More recently he has used elastic thread for the purpose, which he passes through the tunica albuginea of the lower pole of the testicle, so that the latter is pulled downwards and the cord put on the stretch.

We regard it as very important to divide thoroughly all the attachments in the neighbourhood of the spermatic cord, as if there is too great tension the circulation in the cord is injured. Like Lanz, we have simply brought the thread fixed to the lower pole of the testicle through a small opening in the bottom of the scrotum, but after fixing it there and closing the small wound, we then pull the scrotum down by means of the thread, the ends of which are left long and stitched firmly to a fold of skin lower down on the thigh. In this way absolutely no wound is left.

186. Vasectomy. Of all the various methods employed from time to time to diminish the size of the prostate, vasectomy has yielded the best results. The important observations of Ramm and White (the original discoverers of the castration treatment of prostatic hypertrophy) show that castration exercises a marked influence on the size of the prostate, and have led to the development of a procedure which avoids all the deleterious effects and dangers of castration, and in nearly all cases produces the same beneficial result.

Vasectomy has the advantage of not causing atrophy of the testicle although the prostate decreases in size. It can be performed without a general anæsthetic, and without confining the patient to bed—matters of great importance where elderly people are concerned. Under cocaine anæsthesia a small incision is made down on to the cord, which is first fixed between the finger and thumb. The tunica vaginalis communis is divided, a loop of the tough vas deferens is drawn out, and a portion of considerable length is excised. It is unnecessary to tie the ends. The wound is stitched and a collodion dressing applied.

Appendix.—Vasodidymostomy. Penzo,[3] in support of partial resection of the epididymis and vas deferens, has attempted to anastomose the divided vas deferens

[1] Lanz, *Centralblatt für Chirurgie*, April 1905.

[2] According to Bewan the nutrition and development of the testicle might be seriously interfered with were the vessels to be cut through.

[3] *Rivista ven. di sc. mediche*, Venedig, 1905.

with the parenchyma of the testicle by making several openings in the stump of the vas deferens and implanting the latter into the testicle. In animals he succeeded in obtaining a really functional anastomosis.

187. Excision of the Seminal Vesicles. Total Castration including the Vasa Deferentia and Seminal Vesicles. Spermatocystectomy has to be considered chiefly in connection with tuberculosis of the seminal vesicles while, as we have already indicated, it forms part of the operation for the removal of malignant growths of the prostate and bladder. It is, however, a rare operation. Legueu and Riese have recently published a series of cases of this operation. Experienced surgeons, like Israel and Körte, agree that it is scarcely indicated.

The procedure follows closely that of perineal prostatectomy in regard to exposure of the parts. Since Baumgarten, by his experiments, and Bruns, by clinical observations, have proved that tuberculosis of the genital organs is primarily an ascending one, that is, that it passes from the testicle successively to the vas deferens, seminal vesicles, and prostate, and does not spread in the reverse direction (from prostate to genital organs), total excision of the male organs of reproduction has received special attention. There are, however, many surgeons who even nowadays are opposed to operation in cases of tuberculous disease of the testicle.

Beloseroff, at Roux's request, investigated the historical development of castration and ascribed to Reclus the honour of having, in 1875, distinguished genital tuberculosis as a primary [1] disease, as opposed to Louis' and Dufour's tuberculous diatheses. It is now definitely proved that a number of patients remain quite healthy after castration. Tavel recently discovered a case in which tuberculosis of both epididymes was discovered post mortem, without any manifestation of tubercle elsewhere, even in the lungs. The case was one of primary tuberculosis of the epididymis. But it is undoubted that it is only the minority of cases which reach the surgeon at a time when the affection is still entirely limited to the testicle, and when, therefore, simple castration, or excision of the epididymis (Bardenheuer, 1880), may be performed.

The vas deferens, at any rate, is generally involved, hence it must be removed above the highest diseased focus by dissecting it out high up. If the seminal vesicle is also involved it should be excised. In many cases, of course, tuberculous foci are still left in the prostate: excision of the vesicula seminalis, along with the vas deferens and testicle, is only justifiable when the seminal vesicle is specially seriously involved, and when the prostate is quite healthy.

If the tuberculous process develops quickly, the vas deferens, seminal vesicles, and prostate are sometimes rapidly involved as we saw not long ago in a post mortem. In the individual in question, miliary peritoneal and general tuberculosis led quickly to death from meningitis. Ullmann performed the first spermatocystectomy in 1889.

Villeneuve attempted excision from the groin, while Schede, Fuller, and Routier employed the sacral route, as recommended by Kraske and Rydygier. The proper route is from the perineum, as practised by Ullmann, Zuckerkandl, Büngener, Guelliot, and ourselves. We have performed the operation through the prerectal incision in the form of the sharply curved incision described for the exposure of the prostate. This method may confidently be recommended, and it occasions far less injury than either the inguinal or the sacral methods.

Beloseroff objects to the prerectal incision on the grounds of want of space, of difficulty in arresting the hæmorrhage, and of the great injury inflicted on the parts. We can only admit the justice of the first objection, and then only to this extent, viz. that the incision recommended by Roux certainly gives more room, but either or both ends of the horse-shoe incision may be easily extended backwards. On the other hand, a lateral incision must necessarily divide more of the levator ani and of the nerve twigs passing transversely towards the middle line than does

[1] With regard to primary tuberculosis of deeply-seated organs, it is almost unnecessary to observe that we do not imply that the tubercle bacillus entered at this point, but rather that its effects were first recognised clinically here.

the prerectal incision which gives access in the middle line, and, for this reason, allows of the muscles being held aside.

Roux's Paramedian Method for Spermatocystectomy with Total Vasectomy and Castration. Roux performs castration, frees the vas deferens as high as possible, and divides it obliquely, so that if it is twisted out from below he can exclude the possibility of a tear. In cases where the section passes through caseous mucous membrane we advise that the stump should be cauterised with Paquelin's instrument.

A paramedian incision 4 ins. long is then made in the perineum (about $\frac{3}{4}$ in. from the middle line) as far as the level of the ischial tuberosities, and the fibres of the levator ani are divided. The seminal vesicle is protruded into the wound by a finger introduced into the rectum and is secured by a suture. Its attachments are separated with a blunt dissector, and the vas deferens is pulled out. The neck of the seminal vesicle is divided at the prostate, and the cut end is closed by three layers of catgut sutures. Iodoform gauze is introduced for twenty-four hours and the wound sutured.

Young (Langenbeck's *Arch.* vol. lxii. p. 456) has described a very radical procedure for extirpation of the testicles together with the cord and vesiculæ seminales. He makes a long abdominal incision reaching up to the umbilicus, strips the peritoneum from the posterior wall of the bladder, isolates the seminal vesicles and vasa deferentia from above, and excises them in one piece with the testicles. To gain sufficient room for the procedure, the recti are divided transversely at the level of the umbilicus and united again by sutures. When the bladder is diseased it may be incised, or a part may even be excised. This method is certainly radical, but, on account of the serious nature of the operation, it should be limited to suitable cases.

188. Amputation of the Penis. Removal of the penis is performed almost entirely for malignant disease, which generally originates either in the region of the prepuce or of the corona. Formerly, on account of the danger of infection, it was usual to effect the removal with the galvano-caustic snare or with the thermo-cautery. But, if the parts are properly disinfected, removal with the knife is preferable, because it allows one to make a proper urethral orifice from the first, and the patient is thus spared very great discomfort, and is protected from a secondary stricture.

Hæmorrhage is prevented by tying a thin drainage-tube round the base of the penis. The skin is divided transversely, and, after it has been drawn back, the corpora cavernosa of the penis are divided down to the corpus spongiosum of the urethra. It is easily seen when the thick tunica albuginea of the corpus cavernosum of the penis is divided. On the back of the penis the median dorsal vein and the two dorsal arteries are ligatured, as are also the deep arteries in the right and left corpus cavernosum. The loose tissues covering the corpus spongiosum are then retracted and the latter is cut across along with the urethra 1 to 2 cm. lower down. This stump, from which the radiating folds of the urethral mucous membrane can be easily pulled out, is sutured to the lower edge of the skin wound. Immediately after the arteries are ligatured, the tunica albuginea is stitched vertically over the cut surfaces of the corpora cavernosa and the latter are securely sutured together so that when the tourniquet is removed any hæmorrhage can be controlled.

The rest of the skin edge is united in a vertical direction.

In this way primary complete closure of the wound is obtained, and a well-formed urethral orifice is provided, which does not become narrowed later on by cicatricial contraction. The urine escapes freely without soiling of the wound, and thus recovery is rapid and complete.

Jansen (*Centralbl. f. Chir.*, May 1905) describes a method Witzel has employed so as to prevent the orifice of the urethra retracting downwards and backwards. He sutures the corpora cavernosa together horizontally, curves the urethra upwards, sutures it to the tunica albuginea, and makes a hole in the skin on the dorsum (which is left longer) into which he stitches the mucosa. The edges of the dorsal skin are united to the ventral skin on the under aspect of the penis.

189. Removal of Lymphatic Glands from the Groin, and from the Region of

the Iliac and Obturator Vessels. The typical incision for clearing out the inguinal glands is that recommended by Lauenstein, viz. an oblique incision along Poupart's ligament, with Lennander's addition of a vertical one along the femoral vessels. The operation of complete removal of the lymphatic glands in the groin should only be performed when they are the seat of malignant disease, and thus a source of danger to the life of the patient. On the other hand, in tubercular and various inflammatory conditions the removal should be limited to the diseased glands. Riedel has shown that complete excision of the inguinal glands can give rise to stasis of the lymph flow and consequent elephantiasis of the lower limbs.

If, as in carcinoma, sarcoma, and tubercle, the indications for removing the glands are obvious, we agree with Lennander that they should be followed up into the pelvis along the vessels and removed in the same thorough manner as in dealing with the axillary glands. They extend along the external and common iliac vessels as far as the aorta, as well as along the obturator vessels to the internal iliac.

Lennander, in order to expose the deep glands, recommends that the muscles of the abdominal wall should be freely separated from the pelvis. Poupart's ligament is detached from the pubis and the fascia lata, and the muscles of the abdomen are detached as far back as the centre of the iliac crest, or even farther. In this way access can be got to the glands as far as the aorta, and to those in the cavity of the pelvis.

In such cases we have contented ourselves with the following procedure:—An incision is made just above Poupart's ligament, the superficial fascia is divided, and the superficial epigastric artery and some vertical veins are ligatured. The aponeurosis of the external oblique is split close above the ligament. The internal oblique and transversalis muscles are separated from the ligament and the fascia transversalis is divided.

The muscles, together with the cord (or round ligament), are now retracted and the dissection is continued upwards subperitoneally along the vessels. If this does not give sufficient access, the incision may easily be prolonged outwards and the muscles separated from the iliac crest, a step, however, which makes the operation much more serious. Very thorough access to the deeper parts may be obtained if the divided muscles are forcibly pulled aside after the fasciæ have been divided.

In some circumstances it is better to add a vertical incision upwards to that over Poupart's ligament. By dividing the attachment of the rectus to the symphysis this may be made in the linea alba. When the iliac glands are involved (*e.g.* in malignant disease of the testicle) the parietal peritoneum must be divided all round the tumour so that it may be raised up off the great vessels. In making a thorough dissection of the glands about the sacral promontory it is essential for safety to have plenty of room. In regard to the after-treatment, even when there are large gaps which cannot be covered in with peritoneum, the drain may be removed after two days, and complete primary union obtained.

(q) Surgery of the Female Reproductive Organs

190. The Alexander-Adams Operation. Gynecologists have been slow to appreciate the advantages of the Alexander-Adams operation in the treatment of retroflexion of the uterus, and we are convinced that it does not yet receive the support which the excellence of the results following its employment indicate. We have frequently had to undertake it in women who had for years worn pessaries—a form of treatment which is most inefficient in an uncomplicated easily-movable retroflexion. The explanation of this lukewarm attitude is to be found in the injuries which are reported to have followed its use,[1] *e.g.* cicatricial adhesions of the genito-crural nerve, severe arterial hæmorrhage, thrombosis, etc.

Fehling,[2] in opposition to his colleagues, states that these accidents only occur

[1] v. Hocheisen, *Berl. klin. Wochenschr.* No. 2, 1905.
[2] *Centralbl. f. Gynäkologie,* February 1905.

when the operation is incorrectly performed, *i.e.* when the incision is made too far out. He, however, goes to the opposite extreme and cuts too near the middle line. He employs a curved incision extending from the centre of Poupart's ligament on one side across the symphysis pubis to a corresponding point on the other side, and searches for the ligament after its exit from the inguinal canal. As the ligament is here sometimes very thin, it naturally not infrequently gives way when traction is made on it.

Traction can only be made on the ligament with safety before it enters the

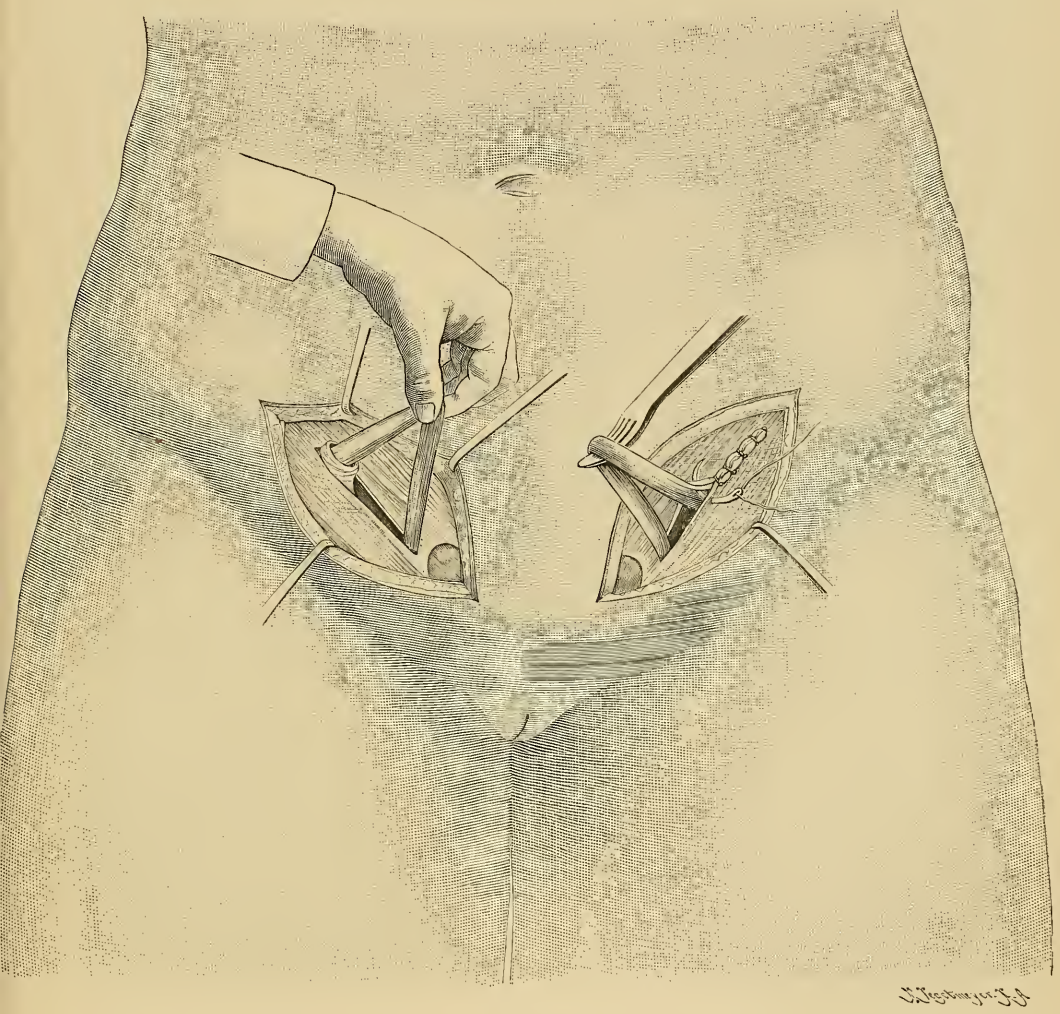

FIG. 412.

inguinal canal (Hocheisen adopts the method which we described in our earlier editions). Even here, if the ligament is thin, it may occasionally give way, but an accident of this sort only occurs in attempting to replace a uterus which is not sufficiently movable, *i.e.* when the examination has been too cursory and the indications for the operation have not been properly established. When the uterus is retroflexed and fixed, and a laparotomy has to be undertaken to free it, the ligament may be shortened intraperitoneally or it may be fixed to the sheath of the rectus by Gilliani's or a similar method.

Technique of the Operation. Our inguinal incision, 5 to 6 cm. in length, parallel to Poupart's ligament is quite sufficient, and in time leaves a barely perceptible scar. After division of the skin and superficial fascia ½ cm. above Poupart's ligament, the aponeurosis of the external oblique, *i.e.* the anterior wall of the inguinal canal, is divided, but the separation is not carried right down into the external abdominal ring (*vide* Fig. 412). In the superficial fascia the superficial epigastric artery is divided as well as a vertical vein which is often found at the inner angle of the wound. A blunt dissector is now passed along the concavity of Poupart's ligament and the internal oblique and transversalis muscles between which the ligament runs are raised up. The muscles are then allowed to slip off the end of the dissector till the ligament is recognised, after which it is grasped between the finger and thumb and held up, care being taken not to put much strain on the distal end, as it is here thin and easily torn. The soft parts are stripped back to the internal abdominal ring, and traction is made on the upper end of the ligament till the cone of peritoneum is brought into view. The latter can be readily pushed back with a gauze swab. The artery which accompanies the round ligament is ligatured, to prevent it being torn, and is then allowed to retract.

A strip of gauze is now passed underneath the ligament, while the ligament on the opposite side is dealt with in a similar manner. When they are both freed, traction is made on them in order to effect the reposition of the uterus, the amount of traction being regulated per vaginam, and, if necessary, assisted by pushing up the body of the uterus.

The method by which the sutures are introduced is illustrated in Fig. 412. Beginning at the outer angle of the wound, a series of interrupted sutures are passed through both edges of the aponeurosis, including one-third of the thickness of the round ligament. The sutures, which should always be silk, are continued till only a small opening is left, through which the redundant portion of the round ligament is replaced in the inguinal canal. The aponeurosis is then united over it and the skin closed with a continuous stitch, a collodion dressing being applied without drainage.

It will be observed that the ligament is neither cut through nor removed. Its normal attachments are retained. It is merely pulled out, and securely fixed to the anterior wall of the inguinal canal. There is no risk of a hernia resulting (we have never seen hernia occur) if one or two stitches are passed through the cone of peritoneum, especially if the peritoneum has been torn.

When the proper cases are selected, the operation affords a certain radical cure, the wound being healed in eight to fourteen days. We cannot therefore understand why so many gynecologists still persist in the use of pessaries for months and years.

191. Exohysteropexy. Exohysteropexy, *i.e.* extraperitoneal fixation of the whole uterus (vide *Deutsch. Med. Woch.*, January 1904) is a very simple and efficacious operation and gives good results (1) in the enucleation of myomata when there is the least danger of subsequent bleeding or sepsis; (2) in cases of severe prolapse in women beyond the menopause.

The following description refers to a simple case of severe prolapse in an elderly woman :—

A mesial incision is made, the length of which is determined by replacing and pushing the uterus in contact with the abdominal wall. The skin, linea alba, transversalis fascia, and peritoneum are divided, the opening in the latter being just sufficient to allow the uterus as far as the os internum to be pulled out. The tubes and ovaries are not brought out. The peritoneum is now sutured above and below the uterus at the junction of the body with the cervix, a portion of the peritoneal covering of the uterus being included both in front and behind. The bladder is, of course, avoided, as it lies lower down. The body of the uterus is laid upon the shelf of peritoneum thus formed and its anterior surface covered over with the fascia transversalis. The edges of the linea alba are united, and a fold of the round ligament on either side is stitched as high as possible to the fascia. In this manner the uterus is securely anchored outside the peritoneum, under cover of the fascia of the anterior

abdominal wall. The skin wound is then closed, a drain being inserted down to the opening in the peritoneum through which the uterus has been brought.

The operation is quite simple and does not inflict the mutilation of a vaginal hysterectomy. Even for old women, therefore, it has not the serious nature of the former operations. We have taken the trouble to follow up our cases, and are able to state that in only one was disturbance of the bladder noted, and in her case cystitis and urinary trouble had existed previously. As all our other patients had absolutely no complaints, we are justified, therefore, in recommending the operation for suitable cases.

If the operation is performed in connection with enucleation of a uterine myoma, the bed of the tumour must, of course, be closed in layers in the usual manner. As is well known, however, the results of enucleation are by no means so assuring as to lead one to confidently recommend the operation, even in the case of young robust individuals. The stitches may give way at the onset of menstruation, and by causing hæmorrhage into the peritoneal cavity may give rise to peritonitis, while a similar complication may be produced by necrosis.

By suturing the uterus to the abdominal wall, a great security is provided against peritonitis—the chief danger of the operation. A drainage tube is passed down to the sutures in the peritoneum, while one or more may be inserted down to the seat of the enucleation. If in addition a gauze tampon is employed, it should be removed in one or two days, the tubes being left for a slightly longer period. The smallest sign of hæmorrhage or sepsis can be at once recognised, and the necessary steps taken for their arrest.

Danger from a subsequent pregnancy need scarcely be apprehended, as, generally speaking, one is dealing with barren women. Should, however, the occasion arise, and the uterus does not replace itself, one need not hesitate to divide the peritoneum and restore it to its intraperitoneal position.

APPENDIX

Excision of the Wrist (Figs. 413, 414, and 415). Excision of the wrist, as practised by the Prussian surgeon Beyer, and by Moreau (one of its earliest introducers), has given better results since Lister pointed out the importance of always performing a complete excision. Treves considers the two dorsal incisions of Ollier preferable to the two incisions recommended by Lister. For the different methods we refer the reader to the exhaustive and historical work of Catterina (Padua, 1893). In practically every case a single dorsal incision is sufficient. Formerly we regularly employed the method most usually adopted, viz. that known as Langenbeck's. Farabœuf states that the dorso-radial incision was employed by Böckel in 1869, and Treves describes it as Böckel's method, but holds that Lister had previously used it. We employed the same incision before Langenbeck, not only on the living body, but also demonstrated it in the operative course upon the cadaver. It is through Langenbeck, however, that the method has become widely known. It has great advantages over the methods formerly employed.

Dorso-Radial Incision. With the hand forcibly flexed to the ulnar side, a straight incision is carried through the skin from the middle of the second metacarpal bone over the middle of the wrist-joint, and upwards along the axis of the forearm for a corresponding distance above the joint. The incision strikes the interval between the tendons of the extensor communis digitorum and extensor indicis on the one side, and the extensor secundi internodii pollicis on the other. The skin is divided gradually so as to avoid the branches of the radial nerve going to the middle finger. The upper part of the incision passes through the posterior annular ligament and the fascia, down to the radius. Opposite the wrist-joint it is carried through the capsule and downwards upon the base of the third metacarpal bone. The tendons of the extensor carpi radialis brevior and longior are now detached along with the periosteum from the bases of the third and second metacarpals respectively, and the posterior surface of these bones with the intervening interosseous muscle are exposed. The tendons are now displaced laterally from their grooves in the bones, and the detachment of the capsule of the wrist-joint is commenced.

The disadvantage of the Böckel-Langenbeck method is, that in order to get sufficient room it is necessary to detach the radial extensors. Even although the subperiosteal method is strictly adhered to (as recommended by Trélat), considerable damage is nevertheless sustained by the chief dorsal flexors of the hand, which is apt to be flexed towards the palm and the power of dorsiflexion seriously impaired. It is therefore preferable, on account of the frequency with which the radial extensors are injured, to place the incision upon their ulnar side.

Dorso-ulnar incision (Figs. 413, 414, and 415). Our incision must be of considerable length, 7 to 8 cm. (3 to $3\frac{1}{2}$ in.), and so placed that with the hand slightly flexed to the radial side, it extends from the middle of the fifth metacarpal bone upwards over the middle of the wrist-joint, and from thence along the middle of the back of the forearm. At its lower end the incision avoids the origin of the posterior

ulnar vein and the dorsal branch of the ulnar nerve, which is not so likely to be injured as is the radial nerve by the dorso-radial incision, because the dorsal branch of the ulnar winds towards the back of the hand at a lower level. After dividing the fascia along with the strong transversely-striated posterior annular ligament, the incision opens the sheaths of the extensor minimi digiti and extensor communis tendons which are drawn to the radial side, while beneath the tendons the ligaments upon the base of the fifth metacarpal, the unciform, the cuneiform, and the ulna are divided. The capsule is now separated towards the ulnar side, and along with it the tendon of the extensor carpi ulnaris, which is attached to the fifth metacarpal.

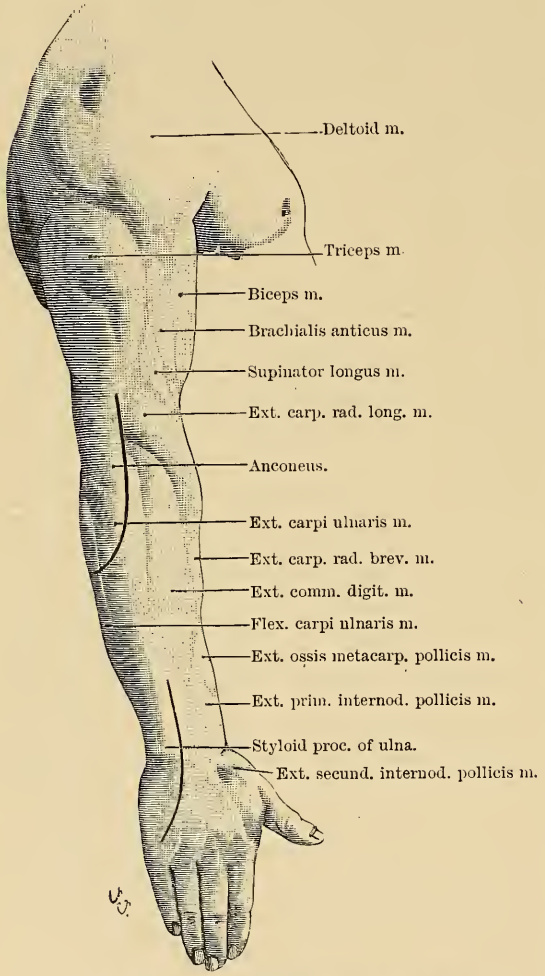

FIG. 413.—Arthrotomy of the elbow and wrist.

The detachment of the tendon of the extensor carpi ulnaris has not the same disadvantage as has that of the two radial extensors. The ulnar extensor has much less share in dorsiflexing the hand than the radial extensors which lie upon the radiocarpal articulation, which forms the main part of the wrist-joint. The extensor carpi ulnaris assists mainly in producing ulnar flexion, which is the very movement which occurs to an undue extent after excision, in consequence of the weight of the hand, which is subsequently often displaced to the palmar and ulnar aspects—that is to say, appears to be contracted in this direction. The division of this tendon, therefore, may act rather beneficially than otherwise. Moreover, in the dorso-ulnar incision the extensor tendons have less tendency to protrude from the wound than in the dorso-radial incision. The special extensor of the little finger is the one most interfered with, but as this finger is provided with a double extensor, and has a far less important function than the index, this disadvantage may be disregarded.

Above, the tendon of the extensor carpi ulnaris is lifted out of its groove in the ulna, and the capsule is separated from around the bone. When the inferior radio-ulnar joint is diseased the miniscus must be excised. The separation of the attachment of the capsule around the ulna is easy. After dividing the capsule at the cuneiform, the joint between it and the pisiform is opened, the tendon of the flexor carpi ulnaris being left in connection with the latter. The hook of the unciform can be more easily exposed and cut across than by the dorso-radial incision. This is a matter of importance, because the deep branch of the ulnar nerve winds round it and must be preserved. The bundle of common flexor tendons can be lifted *en masse* out of their groove

without difficulty, and the ligamentous connections between the three inner metacarpals can be separated upon the palmar aspect, the insertion of the flexor carpi radialis into

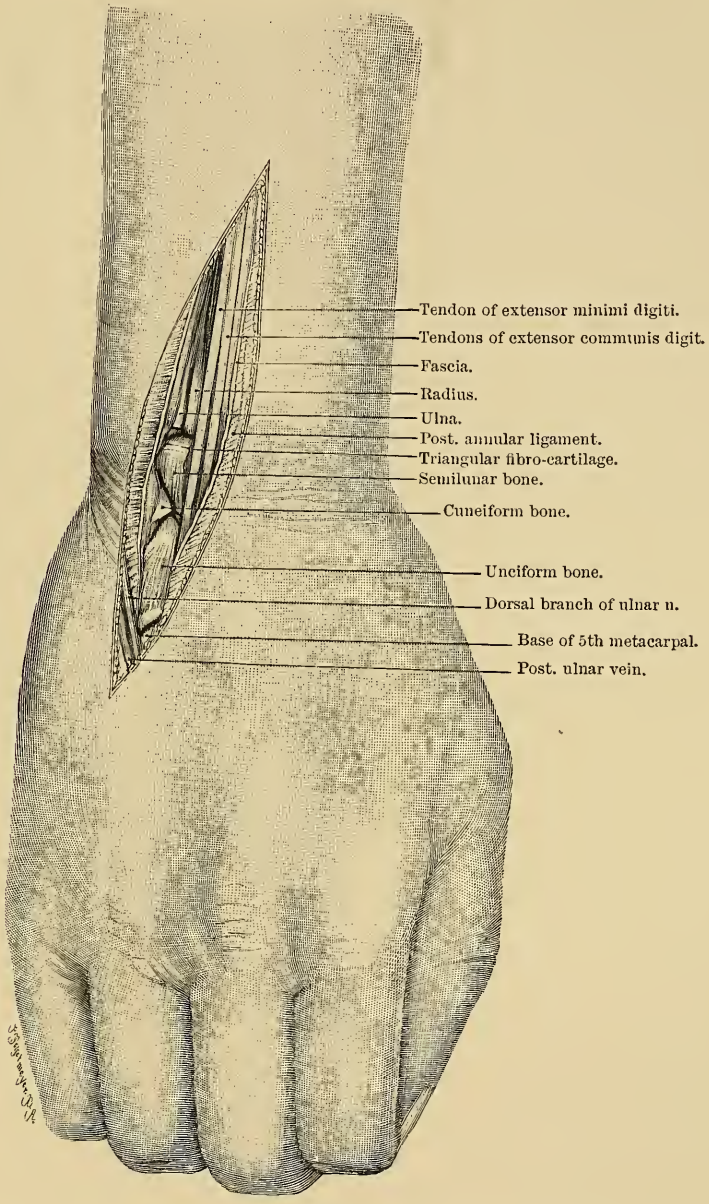

FIG. 414.—Excision of the wrist by the dorso-ulnar incision carried through the capsule.

the second metacarpal being preserved. The attachment of the anterior ligament of the wrist-joint is separated from the anterior border of the lower end of the radius.

Upon the dorsal aspect, the posterior ligament is detached from the lower end of the radius as far as the radial extensors and the extensors of the thumb, and the

tendons are raised from out of their grooves. The tendons of the radial extensors, however, are not detached from their insertions into the dorsal aspect of the third and second metacarpal bones respectively.

The hand is now forcibly and completely dislocated towards the radial and flexor aspects so that the thumb comes in contact with the radial border of the forearm, and

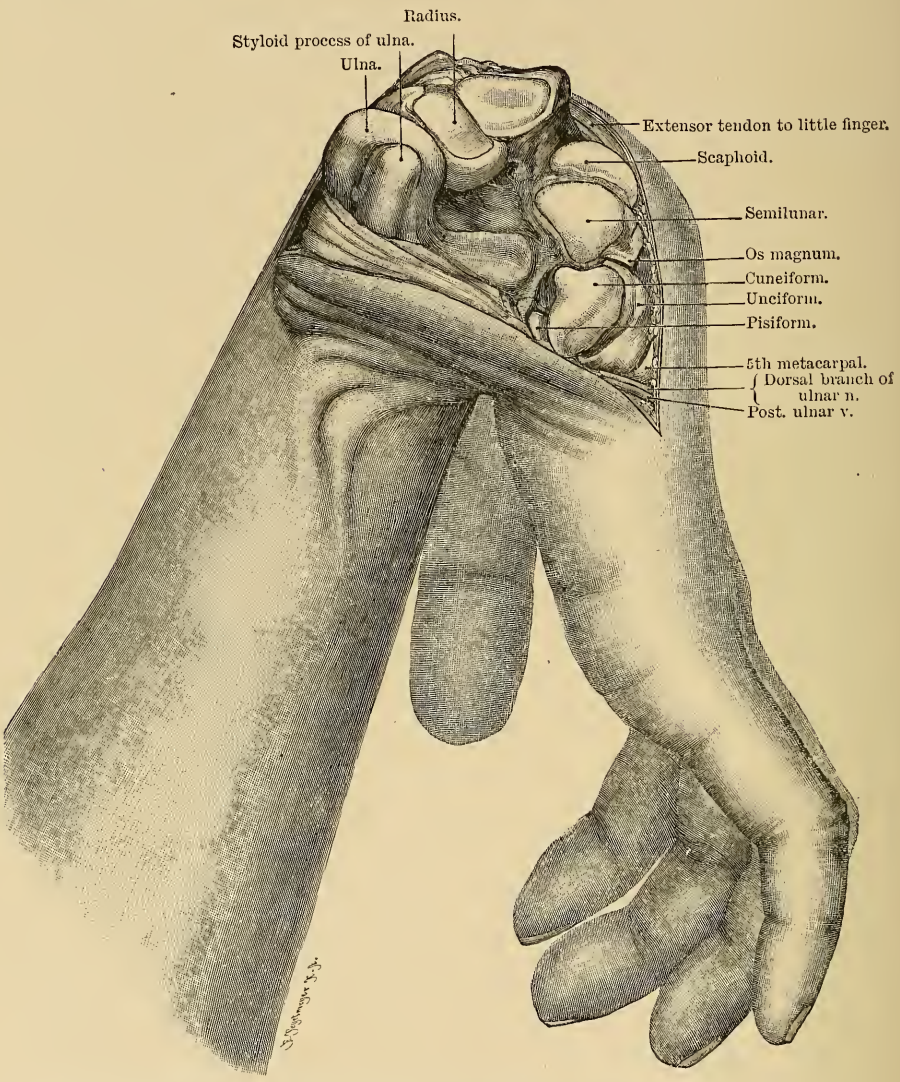

FIG. 415.—Excision of the wrist by the dorso-ulnar incision. Second stage: the wrist-joint is dislocated and the posterior ligament detached from the bones of the forearm.

the extensor tendons come to lie upon the radial side of the radius (Fig. 415). When necessary the capsule may be still more thoroughly detached from the outer border of the radius, and the insertion of the supinator longus exposed. There is now no difficulty in dissecting out the carpal bones, and in removing as thin a layer as possible from the bones of the forearm and from the metacarpals. It is only in the region of the trapezium, the trapezoid, and the bases of the three radial metacarpals that

access is not so readily obtained. In cases where the disease chiefly involves or is limited to the radial aspect of the carpus and metacarpus, the dorso-radial incision possesses advantages over our own method. Especial care must be taken to avoid the radial artery which lies on the dorsum between the trapezium and trapezoid bones, and enters the palm between the bases of the first and second metacarpals to form the deep palmar arch.

The ends of the bones of the forearm and the proximal ends of the metacarpals should be sawn with a surface curved on a transverse axis, as in the elbow, so as to ensure dorsal and palmar flexion.

We especially claim for our method that the tendons of the radial extensors are preserved intact, and that by completely dislocating the joint it is possible to obtain a view of all its recesses, and of each individual bone.

Catterina recommends a method of excising the wrist similar to that of Obalinski for exposing the tarsal joints—that is to say, by an incision extending through from the dorsum to the palm between the third and fourth metacarpals. The palmar incision only reaches to the superficial palmar arch. The dorsal one, however, extends much higher up, but the transverse direction of the palmar arches and of the deep division of the ulnar nerve renders the proper use of this incision difficult.

In the after-treatment it is of importance to secure dorsiflexion of the hand by means of a splint, such as we have been in the habit of using for years, and which, although keeping the wrist securely fixed, still allows of movement of the fingers. As the finer and more important movements of the fingers are associated with flexion, the wrist should be dorsiflexed, so that by stretching the flexors the fingers are kept in a state of passive flexion, which can be rendered more complete and active by comparatively little muscular effort. Active movement of the fingers should be begun early to obtain a good functional result.

INDEX

Abdomen, surgery of, 506
Abdominal aorta, ligature of, 92, 129
  tuberculosis, laparotomy in, 516
Abscesses, biliary, 554
  cerebellar, 193, 409
  cerebral, 193, 409
  hepatic, 502
  mediastinal, 489
  retropharyngeal, 442
  spinal, 491
  splenic, 565
  subdural, 409
  subphrenic, 502, 514
  temporo-sphenoidal, 409
Acoustic nerve, exposure of, 232
Acromegaly, 400
Acromio-thoracic artery, ligature of, 115
Actinomycosis of lung, 499
Addison's disease, 674
Adrenalin, 41
After-treatment, 35
Air infection of wounds, 72
Alcohol enema, 35
  in disinfection of hands, 11, 70
  narcosis, 63
Alexander-Adams operation, 704
Amputations, including Disarticulations—
  evolution of methods of, 330
  incisions for, 332
  methods of obtaining useful stumps, 335
  aperiosteal, 337
  osteoplastic, 336
  subperiosteal, 338
Amputation at the ankle-joint (Syme), 347
  anterior intertarsal, 344
  arm and shoulder girdle (interscapulo-thoracic), 379
  Chopart's, 345
  elbow-joint, 373
  fingers, 371
  foot, 342
    anterior intertarsal, 344
    posterior intertarsal (Chopart's), 345
    intertarsal, 346
Amputation of foot—
    metatarsal, 343
    metatarso-phalangeal, 342
    osteoplastic (Pirogoff), 348
    subastragaloid, 346
      osteoplastic, 346
    tarso-metatarsal (Lisfranc), 343
    through the metatarsus, 343
  forearm, 373
  hand, 371
  hip, 363
  interilio-abdominal, 367
  interscapulo-thoracic, 379
  knee, 356
    through condyles, 359
    osteoplastic through condyles (Ssabanejeff), 360
    supracondyloid, 361
      osteoplastic (Gritti), 361
  leg, 350
  pelvis, 367
  penis, 703
  rectum, 650
    combined method, 658
  shoulder, 376
  thigh, 357
    middle of, 362
    high, 363
  thumb, 372
  upper arm, 374
  wrist, 373
Anæsthesia—
  general, 12, 46
    contraindications, 13, 54
    ether, 13, 46
      contraindications to, 50
    ether-intoxication, 13
    chloroform, 46, 56
      contraindications to, 50
    comparison of toxic effects of chloroform and ether, 47
    chloroform and ether mixture, 14, 53
    oxygen-chloroform, 56
    chloroform - morphia, in trephining, 176
    ethylbromide, 14, 16, 46, 54
    complications during, 57
  local, 16
    adrenalin, 41
Anæsthesia—
    cocain, 16, 40
    ethylchloride, 40
    novocain-adrenalin in goitre operations, 448
    infiltration (Schleich), 17
    in laryngotomy, 428
    Lennander's investigations, 37
  spinal, 29, 41, 45, 279
  conduction, 18
    perineural injection, 21. *See* Nerves.
    endoneural injection, 28
Anæsthetic, administration of, 15, 55
Anastomotica magna artery, ligature of (arm), 121
  (leg), 148
Ankle, amputation of, 347
  arthrotomy and resection of, 286
Ano-coccygeal nerve, exposure of, 268
Anterior triangle of neck, normal incisions, 425
Antrum of Highmore, 390
Anus, operation for prolapse of, 663
Aorta, ligature of abdominal, 91, 129
Aperiosteal amputation, 337
Appendicitis, operations for, 638
  general peritonitis in, 646
Appendicostomy, 620
Arm, upper, operations on, 318
  amputation of, 373
Arteries, surgery of, 92
  ligature of—
    abdominal aorta, 92, 129
    acromio-thoracic, 115
    anastomotica magna of arm, 121
    anastomotica magna of leg, 148
    anterior circumflex, 115
    anterior tibial, 148, 155
    ascending palatine, 103
    ascending pharyngeal, 103
    axillary, 110
    brachial, 120

Arteries, ligature of—
arteria collateralis radialis superior, 120
arteria profunda brachii, 120
arteria collateralis media, 121
arteria collateralis radialis inferior, 121
arteria collateralis ulnaris superior, 121
coeliac axis, 130
common carotid, 93, 385
common iliac, 132
common interosseous, 125
coronary, 130
deep circumflex iliac, 141
deep epigastric, 139
deep palmar arch, 127
digital, 127
dorsalis pedis, 155
dorsalis scapulæ, 117, 120
external carotid, 96, 386, 400, 416
external circumflex, 146
external iliac, 139
external plantar, 157
facial, 101
femoral, 143
frontal, 105
gluteal, 136
hepatic, 561
inferior mesenteric, 131
inferior profunda, 121
inferior thyroid, 108
inferior vesical, 136
innominate, 93
intercostal, 127
internal carotid, 95
internal circumflex, 146
internal iliac, 134
internal mammary, 107
internal maxillary, 104
internal plantar, 157
internal pudic, 139
internal sacral, 136
lateral sacral, 136
lingual, 99
long thoracic, 115
middle hæmorrhoidal, 136
middle meningeal, 191
obturator, 134
occipital, 102
ophthalmic, 105
palmar arch, superficial, 125
deep, 127
perforating, 148
peroneal, 155
plantar, 155
popliteal, 143, 148
posterior auricular, 103
posterior circumflex, 117
posterior interosseous, 252
posterior scapular, 110
posterior tibial, 151, 155
profunda femoris, 146
radial, 123
renal, 131
spermatic, 132
splenic, 130
Arteries, ligature of—
sterno-mastoid, 102
stomach, pancreas and duodenum arteries of, 130
subclavian, 105
subscapular, 120
superficial palmar arch, 125
superficial temporal, 104
superior intercostal, 108
superior mesenteric, 131
superior profunda, 120
superior thoracic, 115
superior thyroid, 97
supraorbital, 105
thyroid, 468
transversalis colli, 110
ulnar, 123
uterine, 137
vas deferens artery to, 136
vertebral, 106
Arterioraphy, 160
Arthrectomy, 277. *See also* Excisions
after-treatment of, 279
ankle, 236
astragalo-calcanean, 286
elbow, 314
knee, 298
shoulder, 320
total, 326
wrist. *See Appendix*
hip, 303
Arthrodesis, 280
Arthroplasty, 280
Arthrotomy, 277
indications and contraindications, 278
after-treatment of, 279
Chopart's joint, 283
elbow, 314
knee, 292
for habitual dislocation of patella, 300
hip, 303
congenital dislocation of, 307
shoulder, 320
Articular ligaments, surgery of, 275
Artificial anus, 617, 625
in excision of rectum, 659
contrast with fæcal fistula, 613
Artificial respiration, 59
Ascites, Talma's operation for, 556
Astragalus, excision of, 283
Atropin, 612
Auriculo-temporal nerve, exposure of, 228
Axilla, clearance of, 475
Axillary artery, ligature of, 110
vein, exposure of, 168

Base of skull, exposure of, 398
Basedow's goitre, excision of, 13, 467
Bassini's operation for inguinal hernia, 524
Berger, interscapulo-thoracic amputation, 379
Bier's osteoplastic amputations, 336
Bier's spinal anæsthesia, 202
Bile passages, surgery of, 530
Biliary fistula, 545
obstruction, 533
Bladder, extroversion of, 67
puncture of, 683
partial resection of, 687
total excision of, 688
Boari's button, 677
Bones, surgery of, 275
Brachial artery, ligature of, 120
Brain, abscess of, 193
hernia of, 180
puncture of, 172
topography of, 197
tumour of, 194
Branchial fistula, 443
Braun, apparatus for administration of anæsthetic, 15, 62
conduction anæsthesia, 18, 27, 270
Breast, amputation of, 471
radical operation for cancer of, 472
Bromethyl. *See* Ethylbromide
Buccinator nerve, exposure of, 227
Bucco-nasal exposure of nasal sinuses, 390
Burr, Doyen's, 174
Sudeck-Kümmel, 184

Cæcum, tumours of, 630
Calcium chloride in cholæmia, 547
Calculi, ureteral, 682
vesical, 685, 689
Carden's amputation, 359
Cardia, resection and gastrectomy, 599
Cardiac massage, 60, 88
Cardiocentesis, 87
Cardiolysis, 91
Carotid artery, ligature of common, 93
in exposure of nasal cavity, 385
internal, 95
in operations on skull, 178
in excision of jaw, 400
external, 96
Carotid tubercle, 106
Cartilage, excision of semilunar, 299
Castration, 699
Catgut, sterilisation of, 73
and silk in laparotomy, 509
Catterina, anterior tarsectomy, 282
Cerebellar abscess, 193, 409
Cerebello-pontine angle, exposure of, 196
Cerebellum, exposure of, 195
Cerebral abscess, 193, 409
Cervical nerves, exposure of upper four, 236
lower four, 240
Cervical sympathetic, exposure of, 268
Cheek, splitting of, 227, 413
Chloroform, 46, 56
delayed chloroform poisoning, 49

Cholecystectomy, 542
Cholecystendysis, 538
Cholecystenterostomy, 545
Cholecystostomy, 535
Cholecystotomy, 538
Choledochectomy, 551
Choledochoduodenostomy, transduodenal, 551
Choledocho-enterostomy, 550
Choledocholithotomy, transduodenal, 550
Choledocholithotripsy, 549
Choledochotomy, 547
retroduodenal, 548
Cholelithiasis, 537
Chopart's joint, arthrotomy at, 283
operation, 345
Cigarette drain, 508
Circumflex artery, ligature of—
anterior, 115
external, 146
internal, 146
posterior, 117
Circumflex nerve, exposure of, 243
Cirrhosis of liver, surgical treatment of, 555
Clavicle, resection of, 327
Cleft palate, operations for, 423
Club-foot, cuneiform excision in, 283
excision of astragalus, 283
supramalleolar osteotomy, 290
Cocain, 16, 40
Coccygeal plexus, exposure of, 268
Cœliac axis, ligature of, 130
Colon, resection and gastrectomy, 599
Colopexy, 665
Colostomy, 617
Common carotid artery, ligature of, 93, 385
Common bile duct, resection of, 551
Common iliac artery, ligature of, 132
Common interosseous artery, ligature of, 125
Communicans fibularis nerve, exposure of, 264
tibialis nerve, exposure of, 259
Contact infection, 63
Coronary artery, ligature of, 130
Corrosive sublimate, poisoning from, 512
Costo-transversectomy, 491
Cranial nerves, exposure of, 215
Craniectomy, extensive, 179
partial circumscribed, 178
Cranio-cerebral topography, 197
Craniometer, 199
Craniotomy, for covering in osseous defects of skull, 185
circular, 184
Creosotal, in broncho-pneumonia, 5
Cryer-Sudeck burrs, 181
Cryoscopy, 666
Cuneiform excision in club-foot, 282
osteotomy of tibia, 290
resection of femur, 301
Cushing, operation for decompression, 180, 182
trephining in the new-born, 190
Cystectomy, 697
Cysticotomy, 542
Cystostomy, suprapubic, 686
Cystotomy, perineal, 689
suprapubic, 683

Decompression, 172, 175
Cushing's operation, 180, 182
Deep circumflex iliac artery, ligature of, 141
epigastric artery, ligature of, 139
palmar arch, ligature of, 127
Depage, operation for empyema, 496
uretero-cysto-neostomy, 676
Dermoids, treatment of intrathoracic, 471
Digital arteries, ligature of, 127
Diploic veins, plugging of, 167
Disarticulations. *See* Amputations
Disinfection of hands, 11, 66, 69
skin, 65
Dorsalis pedis artery, ligature of, 155
scapulæ artery, ligature of, 117, 120
Doyen's burrs, 174
Duodenum, mobilisation of, 582
Duodenocholedochostomy, 550
Duodenocholedochotomy, 550
Duodenostomy, 614

Ear, exposure of middle, 404
radical operation on middle, 406
intracranial complications in disease of middle, 409
Eck's fistula, 170, 557
Ectopia vesicæ, 679
Elbow, operations at, 313
disarticulation at, 373
arthrotomy and resection and arthrectomy, 314
Empyema, pleurotomy for, 492
treatment of neglected, 494
treatment of chronic, 495
Enema before operation, 35
Entero-anastomosis, 621
lateral, 622
Enterostomy, 515, 611
Enucleation of goitre, 460
Epigastric artery, ligature of deep, 139
Epiplopexy, 557
Eserin, 511
Esmarch's tourniquet, paralysis following use of, 279
Estlander's operation for chronic empyema, 495
Ether, 13, 50
Ether-intoxication, 14
Ethmoidal sinuses, opening of, 393
Ethylbromide, 14, 16, 46, 54
Ethylchloride, 40, 62
Excisions. *See also* Resections
acromio-clavicular articulation, 327
ankle, 286
astragalus, 283
bladder, 687
breast, 472
clavicle, 327
elbow, 314
femur, 301
fibula, 292
goitre, median, 458
movable, 449
hip, 303
humerus, diaphysis of, 319
innominate bone, 367
interphalangeal joints, 311
knee, 292
upper jaw, 394
osteoplastic, 398
to expose base of skull, 398
lower jaw, 400
osteoplastic, 403
leg, lower third, 290
metacarpal bones, 311
metacarpo-phalangeal joints, 311
os calcis, 285
parotid, 411
patella, 300
phalanges, 281, 311
radius, 313
rectum, 648
sacrum, 309
scaphoid bone, 283
scapula, 327
total, 328
shoulder, 320
suprarenal body, 674
temporo-maxillary joint, 403
thyroid gland, 466
tibia, 291
tongue at its root, 421
from mouth, 414
tumours of tonsils, 423
ulna, 313
urethra, 697
wrist. *See Appendix*
Exo-epiplopexy, 557
Exohysteropexy, 706
External carotid artery, ligature of, 386, 400
iliac artery, ligature of, 139
plantar artery, 157
plantar nerve, exposure of, 264
urethrotomy, 697

Face, surgery of, 383
Facial artery, ligature of, 101
nerve, exposure of, 208, 229
paralysis, 231
Facio-accessory anastomosis, 231
Facio-hypoglossal anastomosis, 231
Fæcal fistula, formation of, 613
Femoral artery, ligature of, 143
hernia, radical cure, 526

Femur, supracondylar osteotomy of, 300
sub-trochanteric cuneiform resection of, 301
resection of, 301
supracondyloid amputation, 361
osteoplastic amputation through condyles, 360
Fibula, resection of, 292
Fingers, operations on, 309
amputations of, 371
excision of phalanges and interphalangeal joints, 311
tendon, suture of, 274
Fistula, branchial, 443
Eck's, 170, 557
Foot, operations on, 281
arteries of, 155,
amputations of, 342
anterior intertarsal, 344
posterior intertarsal (Chopart), 345
intertarsal, 346
metatarsal, 343
metatarso-phalangeal, 342
tarso-metatarsal (Lisfranc), 343
subastragaloid, 346
osteoplastic, 346
at ankle joint (Syme), 347
osteoplastic (Pirogoff), 348
Forearm, operations on, 312
amputations of, 373
Freyer's transvesical enucleation of prostate, 690
Frontal abscesses, 193
artery, ligature of, 105
nerve, exposure of, 219
sinus, opening of, 391
radical operation on (Killian), 392
Gall-Bladder, surgery of, 530
indications for operation on, 531
incisions to expose, 533
Gallstones. *See* Cholecystostomy
Gasserian ganglion, extirpation of, 207
Frazier-Spiller operation, 213
Gastrectomy, 585
irregular and partial circular, 598
with resection of cardia, 599
with resection of colon, 599
total, 601
with œsophago-duodenostomy, 602
with œsophago-jejunostomy, 603
Gastric ulcer, 586, 598
Gastroduodenostomy, 579
and pylorectomy, 588
Gastroenterostomy, 567
Gastrojejunostomia, retrocolica inferior longitudinalis, 570
antecolica verticalis cum enteroanastomosi, 575
inferior verticalis, 572
antecolica inferior longitudinalis, 568
Gastrojejunostomia, retrocolica inferior verticalis Y-formis, 576
Gastroplasty, 603
Gastrostomy, 604
Kader's, 607
in resection of œsophagus, 441
in pharyngectomy, 438
Genito-crural nerve, exposure of, 255
Genu valgum, supracondylar osteotomy of femur for, 301
Glands, excision of, in cancer of tongue, 417
axillary, excision of, 476
inguinal, excision of, 704
thymus, excision of, 470
thyroid, transplantation of, 469
Gloves, operating, 66
Gluteal artery, ligature of, 136
nerve, internal, exposure of, 257
Goitre, anæsthesia in, 17, 448
angular incision, 456
collar incision, 448
comparison of methods of operation, 449
conditions influencing extirpation, 447
enucleation of, 460
enucleation-resection and enucleation-excision of, 462
excision of movable, 449
excision of median, 458
excision of inflamed, 468
excision of malignant, 469
excision of exophthalmic, 467
excision of recurrent, 466
excision of, with resection of sternum, 466
evacuation and fragmentation of, 463
indications for and results of operations, 446
operation for intrathoracic, 464
resection of, 461
Gritti's supracondyloid amputation, 361
Groin, excision of lymphatic glands of, 704

Hæmorrhage, arrest of, 33
intracranial, 189
subdural, 190
Hæmorrhoidal artery, middle, ligature of, 136
Hæmorrhoids, excision of—
ligature method, 662
injection method, 662
purification of, 11, 66, 69
Whitehead's method, 662
Hallux valgus, osteotomy in, 281
Hand, amputation of, 371
operations on, 309, 310
Heart, exposure and suture of, 82
massage of, 60, 88
Hepatectomy, 558
Hepatic abscess, 502
artery, ligature of, 561
Hepaticoenterostomy, 553
Hepaticolithotripsy, 552
Hepaticostomy, 553
Hepaticotomy, 552
Hepatocholangioenterostomy, 554
Hepatocholangiostomy external, 554
Hepatopexy, 557
Hernia, cerebral, 180
in children, 524
femoral, radical cure, 526
inguinal, radical cure, 518
umbilical, radical cure, 528
ventral, 509, 528
Hernio-laparotomy, 525
Hip, operations at, 303
arthrotomy and resection, 303
arthrotomy in congenital dislocation of, 307
disarticulation at, 363
excision of, 303
Humerus, osteotomy and resection of diaphysis of, 319
Hydatid cysts of liver, 502, 558
Hydrocele, operation for, 700
Hypogastric artery, ligature of, 134
Hypoglossal nerve, anastomosis with facial nerve, 231
Hypospadias, 698

Ileo-cæcal resection, 630
Iliac artery, ligature of common, 132
ligature of external, 139
ligature of internal, 134
Ilio-hypogastric nerve, exposure of, 252
Ilio-inguinal nerve, exposure of, 252
Implantation infection, 73
Incisions, direction of skin, 30
normal, of face, 384
of upper triangle of neck, 424
of inferior triangle of neck, 427
for kidney and ureter, 667
Infected wounds, treatment of, 79
Infection of wounds—
air, 72
implantation, 73
lesion, 75
necrosis, 77
Inferior lateral triangle of neck, incision to expose, 427
Inferior mesenteric artery, ligature of, 131
profunda artery, ligature of, 121
Inferior thyroid artery, ligature of, 108
vena cava, ligature and suture of, 162
vesical artery, ligature of, 136
Infraorbital nerve, exposure of, 222
Inguinal hernia, radical cure, 518
Innominate artery, ligature of, 93
erosion of, 434
Innominate bone, resection of, 367
vein, ligature and suture of, 164
Instruments, sterilisation of, 9, 63

Intercostal artery, ligature of, 127
superior, ligature of, 108
nerve, exposure of, 252
Interilio-abdominal, disarticulation, 367
Internal carotid artery, ligature of, 95
circumflex artery, ligature of, 146
jugular vein, ligature of, 167
mammary artery, ligature of, 107
maxillary artery, ligature of, 104
pudic artery, ligature of, 139
Interosseous artery, ligature of, common, 125
Interphalangeal joints, excision of, 311
Interscapulo-thoracic amputation, 379
Intestinal occlusion, 621
paresis, 36
Intestine, resection of small, 625
resection of large, 633
Intestines, surgery of, 610
Intracerebral hæmorrhage, trephining for, 190
Iodoform paste (Mosetig), 276, 279

Jaboulay, interilio-abdominal amputation, 367
Jaws, excision of upper, 394
arrest of hæmorrhage in, 394
osteoplastic, 398
to expose base of skull, 398
excision of lower, 400
osteoplastic, 403
to expose upper part of pharynx, 439
Jejuno-gastrostomy (Tavel's), 608
Jejunostomy, 616
Jugular vein, ligature of anterior, 168
common, 166
external, 167
internal, 167

Kader's gastrostomy, 607
Kidney, surgery of, 666
decortication of, 668
movable, 670
and ureter, incision to expose, 666
Killian's radical operation on frontal sinus, 392
Knee, amputations at, 355
arthrectomy, 298
arthrotomy, 292
disarticulation at, 356
operations on, 292
Küttner's muscle flap for anterior triangle of neck, 425

Labyrinth, suppuration in, 409
Laminectomy, 204
Langenbeck's subhyoid pharyngotomy, 434
Langer's lines of cleavage of skin, 30
Laparotomy, 506
transpleural, 508
after-treatment of, 508
complications after, 511
indications and conditions necessary for success, 506
injury to ureter, 675
in peritonitis, 513
in peritoneal adhesions, 517
position of incisions and methods of suture, 509
Large intestine, resection of, 633
Laryngeal nerve, exposure of, inferior and superior, 232
Laryngectomy, total, 431
after-treatment of, 432
Laryngectomy, median subhyoid-pharyngo, 428
partial pharyngo-, 428
Laryngotomy and laryngectomy, circumscribed median, 427
Larynx, surgery of, 427
Lateral sinus, ligature of, 166
thrombosis of, 409
trephining over, 188
Lateral ventricle, puncture of, 174
Leg, operations on, 290
amputations of, 350
Lennander's investigations in regard to local anæsthesia, 37
Lesion infection, 75
Ligature of vessels. *See* Arteries
Ligatures, preparation of catgut, 73
preparation of silk, 75
Lingual artery, ligature of, 99
nerve, exposure of, 229, 413
neuralgia, 227
Lisfranc's operation, 343
Little's disease, 190
Liver, surgery of, 555
abscesses, 558
ascites, Talma's operation, 556
cirrhosis of, 555
fatty degeneration of, following anæsthesia, 49
hydatid cysts of, 502, 558
resection of, 558
Lower jaw, resection of, 400
osteoplastic resection of, 403
Lumbar nephrectomy, 673
nephrotomy, 667
plexus, 252
puncture, 41, 202
vertebræ, to expose bodies of, 683
Lung, abscess of, 498
actinomycosis of, 499
surgical treatment of tuberculous, 499
surgery of injuries of, 501
surgery of tumours of, 500
Lymphatic glands, removal from groin, 704
Lynn-Thomas forceps, 369

M'Graw's ligature, 637
Magnesium plate sutures, 561
Mamma. *See* Breast
Mask, operative, 8, 71
Mastoid process, trephining, 405
Maxillary sinus, opening of, 390
Maydl, uretero-trigono-sigmoide-ostomy, 678
Median nerve, 245
Mediastinotomy, anterior, 488
posterior, 489
cervical, 490
dorsal, 491
Mediastino-pericarditis, treatment of, 92
Medullary anæsthesia, 41
Meniscotomy, 299
Mental nerve, exposure of, 229
Mesenteric vessels, thrombosis of, 513
Metacarpal bones, excision of, 311
Metacarpo-phalangeal joints, excision of, 311
Metatarsal bones, removal of individual, 342
Metatarso-phalangeal disarticulation, 342
Middle ear, exposure of, 404
radical operation in disease of, 406
intracranial complication in disease of, 409
Middle meningeal artery, ligature of, 191
Morphia, 40
Mosetig-Moorhof iodoform bone filling, 276, 279
Moure's operation, pansinusitis nasalis, 388
Mouth, surgery of, 413
Murphy's button, in resection of œsophagus, 504
in œsophago-gastrostomy, 505
in excision of cardia, 600
in gastrectomy with œsophago-jejunostomy, 603
Muscles, surgery of, 271
Musculo-cutaneous nerve, exposure of, 243, 264
Musculo-spiral nerve, exposure of, 250
Myotomy in spasmodic torticollis, 443

Nasal cavity, exposure of, 387
arrest of hæmorrhage, 385
after-treatment, 387
position during operation, 387
sinuses, exposure of, naso-maxillary route, 388
bucco-nasal route, 390
septum, splitting of, 387
deviation of, 387
nerve, exposure of, 219
Neck, surgery of, 424
normal incisions for upper lateral triangle, 424
normal incisions for inferior lateral triangle, 427
operation for congenital fistula in, 443

Necrosis infection, 77
prevention of, 75
Nephrectomy, 672
Nephrolithotomy, 671
Nephropexy, 670
Nephrostomy, 672
Nephrotomy, 671
Nerve-grafting, 230
Nerve-roots, surgery of, 206
Nervous system, surgery of, 171
Nerves, surgery of, 214
Nerves, exposure of—
acoustic, 232
ano-coccygeal, 268
anterior crural, 255
anterior interosseous branch of median, 248
anterior thoracic, 243
anterior tibial, 264
auriculo-temporal, 228
buccinator, 227
cervical, upper four, 236
lower four, 240
sympathetic, 268
circumflex, 243
coccygeal plexus, 268
communicans fibularis, 264
communicans tibialis, 259
cranial, 215
external cutaneous, 255
external plantar, 264
facial, 229
frontal, 219
genito-crural, 255
great occipital, 238
great sciatic, 257
hypoglossal, 236
ilio-hypogastric, 252
ilio-inguinal, 252
inferior dental, 228
inferior maxillary, 224
infraorbital, 222
intercostal, 252
internal cutaneous, 243
internal gluteal, 257
internal plantar, 266
internal popliteal, 259
laryngeal, inferior, 232
superior, 232
lingual, 229, 413
long saphenous, 255
long thoracic, 243
lumbar plexus, 252
median, 245
mental, 229
musculo-cutaneous, 243, 264
musculo-spiral, 250
branches, 250
nasal, 219
obturator, 257
occipital, great, 238
small, 239
ophthalmic, 219
optic, 215
palatine, 223
palmar cutaneous, 248
palmar digital, 248
peroneal, 264
phrenic, 239
popliteal, internal, 259
Nerves, exposure of—
posterior interosseous, 250
pudendal plexus, 267
pudic, 267
radial, 252
sacral plexus, 257
saphenous, 255
sciatic, great and small, 257
small occipital, 239
spinal accessory, 233
subscapular, short and long, 243
superior dental, 222
superior gluteal, 257
superior maxillary, 219
supraclavicular, 239
suprascapular, 243
sympathetic cord, 268
tibial, anterior, 264
trigeminal, 219, 414
intracranial section, 213
ulnar, 125, 248
branches of, 249
vagus, 232
zygomatic, 222
Nerves, perineural injection of—
auricular, great, 26
auriculo-temporal, 24
dorsalis penis, 27
external cutaneous, 24
external popliteal, 24
lingual, 26
median, 21
musculo-cutaneous, 24
occipital, great and small, 24
posterior tibial, 24
superficial cervical, 26
superior laryngeal, 27
saphenous, long, 24
short, 24
supraorbital, 24
Neuralgia, infraorbital, 222
supraorbital, 219
lingual, 229
Neurexeresis (Thiersch), 215, 218
Nose, surgery of. *See* Nasal Cavity
Novocain-adrenalin anæsthesia in goitre operations, 448

Obturator artery, exposure of, 134
nerve, exposure of, 257
ligature of, 167
Occipital sinus, trephining over, 187
artery, exposure of, 102
nerve, exposure of great and small, 239
neuralgia, 239
Œsophagectomy, 440
Œsophagus, surgery of, 434
resection of, 440
transpleural resection of, 505
surgery of thoracic portion, 503
Œsophago-gastrostomy, transpleural, 505
Œsophago-duodenostomy and total gastrectomy, 602
Œsophago-jejunostomy and total gastrectomy, 603
Œsophago-jejuno-gastrostomy (Roux), 609
Œsophagoplasty, 442
Œsophagotomy, 440
transpleural, 504
contraindications, 506
Ophthalmic artery, ligature of, 165
nerve, exposure of, 219
Optic nerve, exposure of, 215
Orbit, operations in region of, 215, 384
Orchidopexy, 701
Os calcis, excision of, 285
Osteoarthrectomy, 277
Osteoarthrectomy at mid-tarsal joint, 282
at metatarso-tarsal joint, 281
Osteoarthrotomy, 277
Osteotomy, 277
supracondyloid of femur, 300
of diaphysis of humerus, 319
of pelvis, 307
of radius, 313
of tibia, 290
of ulna, 313
supramalleolar, 290
Otitis media, operations for, 404
Ozæna, splitting of nasal septum for, 387

Palatine nerve, exposure of, 223
Palmar arch, superficial, 125
deep, 127
cutaneous nerve, exposure of, 248
digital nerve, exposure of, 248
Pancreas, surgery of, 561
exposure of, for injury, 563
palliative operations, 562
solid tumours of, 564
Pancreatic cysts, excision of, 563
Pancreatitis, acute, surgical treatment, 564
Pancreolithotomy, 565
Pansinusitis nasalis, 388
Paracentesis of pericardium, 89
Paralysis, infantile, of foot, 274
Parathyroids, 449
Parotid, excision of, 411
Patella, excisions of, 300
arthrotomy for habitual dislocation of, 300
Pelvic colon, implantation of trigone and ureters into, 679
resection of lower part of, 660
Pelvis, operations on, 303
amputation of, 367
osteotomy of, 307
resection of half the, 308
Penis, amputation of, 703
Pericardium, adhesions of, 91
paracentesis of, 89
puncture of, 83
Peritoneal adhesions, laparotomy in, 517
Peritoneum, parietal, sensitiveness of, 38
Peritonitis, laparotomy in cases of, 513

Peritonitis in appendicitis, operations for, 646
tubercular, 516
after-treatment of, 516
treatment of shock after, 647
Peroneal artery, ligature of, 155
nerve, exposure of, 264
Phalanges, excision of, 311
resection of, 281
Pharynx, surgery of, 413, 434
resection of, lateral, 438
retro-laryngeal resection, 435
Pharyngectomy, medio-lateral, 435
Pharyngotomy, lateral, 438
subhyoid, 434
suprahyoid, 440
Pharyngo-laryngotomy, 428
median subhyoid, 428
Pharyngoplasty, 442
Phrenic nerve, exposure of, 239
Physostigmin, 36, 511, 612
Pirogoff's operation, 348
Pituitary body, removal of, 400
Plantar arteries, ligature of, 155
Pleuroparietopexy, 481
Pleurotomy for empyema, 492
indications for, 492
Pneumonia, post-operative, 36, 52
aspiration, 512
hypostatic, 512
Pneumopexy, 481
Pneumoplasty, 496
Pneumotomy, 498
Polypi, nasal, 398
Polysinusitis, 388
Popliteal artery, ligature of, 143, 148
nerve, exposure of, 259
Portal vein, ligature of, 170, 561
Position of patient during anæsthesia, 9, 59
Position of patient after anæsthesia, 36
Posterior tibial artery, ligature of, 151, 155
Post-operative complications, 35, 52
Preparation of materials for operation, 7
of operating-room, 7
of patient in ward, 3
by medical attendant, 4
Profunda femoris artery, ligature of, 146
Prolapse of anus and rectum, operation, 663
of uterus, 706
Prostate, surgery of, 689
total excision, 696
transvesical enucleation, 690
Prostatectomy, 689
perineal, 693
Pudendal plexus, 267
Puncture of bladder, 683
lateral ventricle, 174
lumbar, 41, 202
pericardium, 89
pleura, 492
Pyelostomy, 672
Pyelotomy, 672
Pylorectomy, 586
with gastro-jejunostomy, 597
with gastro-duodenostomy, 588
Billroth I., 597
Henle, Mikulicz, Rydygier, 597
Pyloroplasty, 585

Rachicocainisation, 29
Radial artery, ligature of, 123
nerves, exposure of, 252
Radius, resection of, 313
osteotomy of, 313
Rectopexy, 664
Rectum, surgery of, 648
amputation of, Lisfranc's perineal method, 650
Kocher's coccygeal method, 650
combined method, 658
sacral method, 657
excision of, introductory, 648
with vaginal section, 657
septic, 656
resection of, 660
combined method, 661
operation for prolapse, 663
Renal artery, ligature of, 131
Resections. *See also* Excisions
Resection of—
common bile duct, 551
goitre, 461
ileo-cæcal tumours, 630
intestine, 625
large, 633
small, 627
liver, 558
manubrium sterni, osteoplastic, 487
œsophagus, 440
transpleural, 505
pelvic colon, lower part, 660
pelvis, half of, 308
pharynx, retro-laryngeal, 435
lateral, 438
rectum, 660
ribs, 483
sternum, 161, 486
sterno-clavicular articulation, 327
ureter, 677
Respiration, artificial, 58
Retroflexion of uterus, 704
Retro-maxillary fossa, exposure of, 400
Retro-pharyngeal abscess, 442
Ribs, resection of, for tuberculosis, 499
for tumour, 483
Roth-Dräger apparatus, 14, 57
Round ligament, shortening of, 706
Roux's œsophago-jejuno-gastrostomy, 609
spermato-cystectomy, 703
Y-gastroenterostomy, 576
Rydygier-Billroth pylorectomy, 597
Rydygier's splenopexy, 566

Sacral plexus, 257
Sacrum, resection of, 309
Saline solution, in vomiting, 35
in peritonitis, 516
rectal infusion in peritonitis, 647
transfusion of, 61
Salivary glands, surgery of, 411
Saphenous vein, exposure of, 255
Scalp, hæmorrhage from, 383
Scaphoid bone, excision of, 283
Scapula, resection and total excision of, 329
Schleich, infiltration anæsthesia, 17, 39
Sciatic artery, ligature of, 136
nerves, exposure of, 257
Scopolamin-morphia, 63
Semilunar cartilage, excision of, 299
Seminal vesicles, excision of, 702
Senn, bone plates, 622
Septum of nose, splitting of, 389
Shock, treatment of, in peritonitis, 647
Shoulder, operations at, 319
disarticulation of arm at, 376
arthrotomy, arthrectomy, and resection, 320
total arthrectomy, 326
Silk, preparation of, 75
Sinuses, exposure of ethmoidal, 393
frontal, 391
lateral, 166
maxillary, 390
nasal, 387
occipital, 167, 187
spheno-parietal, 167
superior longitudinal, 166, 186
Skin, disinfection of, 65
incisions, direction of, 30
Skull and brain, puncture of, 172
Skull, osteoplastic resection of upper jaw to expose base, 398
extensive resection of, 179
osteoplastic resection of, 182
Small intestine, resection of, 627
Spermatic artery, ligature of, 132, 699
cord, exposure of, 699
vein, ligature of, 700
Spermato-cystectomy (Roux), 703
Sphenoidal sinus, 398
Spinal accessory nerve, exposure of, 233
facial anastomosis, 231
Spinal canal, division of posterior roots, 214
cord, exposure of, 202
surgery of, 202
Spine, caries of, 491
Spleen, surgery of, 565
Splenectomy, 565
Splenopexy, 557
Rydygier's, 566
Splenotomy, 565
Ssabanejeff's operation, 360

Status lymphaticus, 55
Status thymicus, 55
Stercorœmia, 515
Sterilisation of catgut, 73
instruments, etc., 9, 63
silk, 75
Sternum, resection of, 161, 486
resection of, in heart injury, 85
Stomach, surgery of, 566
ulcer of. *See* Gastroenterostomy
cancer of. *See* Gastrectomy
crushing-forceps for, 588
Stovain, 29, 44
Stricture, 697
Subarachnoid space, puncture of, 202
Subastragaloid amputation, 346
Subclavian artery, ligature of, 105
Subdural hæmorrhage, trephining for, 189
Subdural abscesses, 409
Subhyoid median pharyngo-laryngotomy, 428
Subhyoid pharyngotomy, 434
Submaxillary salivary gland, 411
Subperiosteal amputation, 338
Subphrenic abscesses, 502, 514
Subscapular artery, ligature of, 120
Subscapular nerve, exposure of, 243
Subtrochanteric cuneiform resection of femur, 301
Sudeck burrs for trephining, 181
Sudeck-Kümmel spherical burr, 184
Superficial palmar arch, 125
Superficial temporal artery, ligature of, 104
Superior laryngeal nerve, exposure of, 232
Superior longitudinal sinus, ligature of, 160, 166, 186
trephining over, 186
Superior maxillary nerve, exposure of, 219
Superior profunda artery, ligature of, 120
Superior thoracic artery, ligature of, 115
Superior thyroid artery, ligature of, 97
Superior triangle of neck, 425
Superior vena cava, exposure of, 161
Supraclavicular nerve, exposure of, 239
Supracondyloid amputation of femur, 361
Supracondylar osteotomy of femur, 300
Supradural hæmorrhage, trephining for, 191
Suprahoid pharyngotomy, 440
Supraorbital artery, ligature of, 105
Suprapubic cystostomy, 686
Suprarenal body, excision of, 674
Suprascapular nerve, exposure of, 243
Sylvian fissure, determination of, 201
Syme's operation, 347
Sympathetic cord, 268
Symphysis pubis, resection of, in cystectomy, 687

Talipes valgus, paralytic, 274
Talipes varus, cuneiform excision in, 282
Talma's operation for ascites, 556
Tarsectomy, anterior, 281
posterior, 286
total, 289
Tavel's jejuno-gastrostomy, 608
Temporo-maxillary joint, resection of, 403
Temporo-sphenoidal abscesses, trephining for, 409
Tendo Achillis, lengthening, 272
Tendons, surgery of, 272
Tendon transplantation, 274
elongation, 272
shortening, 273
Tenoplasty, 272
Testicle, retention of, orchidopexy, 701
excision of, 699, 703
Tetanus, 270
Thiersch's neurexeresis, 215
Thigh, operations on, 300
amputation through middle, 362
amputation, osteoplastic, supracondyloid, 361
high amputation, 363
amputation through, 357
Thoracic artery, long, ligature of, 115
superior, ligature of, 115
Thoracic cavity, drainage of, 482
Thoracic duct, exposure of, 446
Thoracic nerve, anterior, exposure of, 243
long, exposure of, 243
Thoracic organs, advances in surgery of, 478
Thoracic wall, surgery of, 471, 483
Thoracotomy, 496
Thrombosis of veins, 36, 161
in laparotomy, 513
Thumb, disarticulation of, 372
Thymus gland, excision of, 470
status thymicus, 55
Thyroid gland, transplantation of, 469
surgery of, 446. *See also* Goitre
arteries, ligature of, 467, 97, 108
excision of, with resection of sternum and ribs, 466
Tibia, osteotomy of, 290
resection of, 291
Tibial artery, ligature of anterior, 148, 155
ligature of posterior, 151, 155
Tissue necrosis, prevention of, 75
Toes, disarticulation of all, 342
removal of, 342
Tongue, excision of carcinoma of base of, 422
excision of, at its root, 421
excision of, from mouth, 414
excision of, with resection of symphysis, 420
excision of, with resection of lateral portion of jaw, 420
incisions into, 414
operation for advanced cancer of, 417
Tonsils, excision of tumours of, 423
Tonsillotomy, 423
hæmorrhage in, 95
Topography, cranio-cerebral, 197
Torticollis, operations for spasmodic, 443
Tracheotomy, 432, 427
high, 432
low, 434
in resection of œsophagus, 441
in pharyngectomy, 438
Transduodenal choledochoduodenostomy, 551
Transduodenal choledocholithotomy, 550
Transfusion, auto-, 59
intravenous, 60
Transperitoneal nephrectomy, 674
Transpleural laparotomy, 502
Transpleural operations, 502
Transthoracic hepatotomy, 502
Transvesical enucleation of prostate, 690
Trendelenburg position, 10, 428, 508, 660, 691
Trephining, arrest of hæmorrhage during, 176
osteoplastic, 182
special indications, 186
mastoid process, 405
for cerebral abscesses, 193, 409
cerebellar abscesses, 195, 411
decompression, 175
intracranial hæmorrhage, 189
over lateral sinus, 188
occipital sinus, 189
sinuses of dura mater, 186
superior longitudinal sinus, 186
Trigeminal neuralgia, 222
Trigeminal nerve, first division, 219
second division, 219
third division, 224
intracranial section of divisions of, 213
Tropococain, 17, 44
Tuberculosis, abdominal, laparotomy in, 516
of lung, surgical treatment, 499
of testicle, 699

Ulna, resection of, 313
Ulnar artery, ligature of, 123

Ulnar nerve, exposure of, 125, 248
Umbilical hernia, radical operation, 528
Upper arm, amputation of, 373
  operations on, 318
Ureter, surgery of, 674
  incision to expose, 666
  extraperitoneal operations on, 680
  operation on termination of, 682
Uretero-anastomosis, 675
Uretero-cysto-neostomy (Depage), 676
Uretero-cystostomy, 675
Uretero-cystostomy (Sampson-Krönig), 676
Uretero-trigono-sigmoideostomy (Maydl), 678
Urethra, surgery of, 689
  resection of, 697
Urethrotomy, external, 697
  internal, 697
Uterine artery, ligature of, 137
Uterus, extraperitonal fixation of, 706
  prolapse of, 706
  retroflexion of, 704
  shortening of round ligament, 706

Vagus nerve, exposure of, 232
Varicocele, operations for, 700
Varicose veins, 36, 169
Vas deferens, excision of, 699, 702
Vasectomy, 701
Vasodidymostomy, 701
Veins, surgery of, 159
Veins, ligature of—
  spheno-parietal sinus, 167
  occipital sinus, 167
  lateral sinus, 166
  superior longitudinal sinus of dura mater, 166
  anterior jugular, 168
  arm, 168
  axillary, 168
  common femoral, 168
  common iliac, 168
  common jugular, 166
  diploic, plugging of, 167
  emissary, 178
  external jugular, 167
  femoral and internal iliac, tributaries, 169
  hypogastric, 168
  inferior vena cava, 162
    branches of, 168
  innominate vein, 164
  internal iliac, 168
  internal jugular, 167
  ophthalmic, superior and inferior, 167
  portal, 170, 561
  saphenous, long and short, 169, 170
  subclavian, 168
  superior mesenteric, 170
  superior vena cava, 161
Veins, ligature of—
  thyroidea ima, 165
Ventral hernia, radical operation, 528
Ventricle, lateral, puncture of, 174
Vermiform appendix. *See* Appendicitis
Vertebral artery, ligature of, 106
Vertebral tubercle, 106
Vesical arteries, ligature of, 67
Vicious circle, 567, 568
Vomiting, post-operative, 35

Watson-Czerny operation, total laryngectomy, 431
Wave incision, 533
Whitehead's method of excision of hæmorrhoids, 663
Wirsungo-duodenostomy, 565
Wound, closure of, 34
  infection of, air, 72
    implantation, 73
    lesion, 75
    necrosis, 77
  treatment of, 63
Wrist-joint, disarticulation at, 373
  excision of. *See Appendix*
Wry-neck, spasmodic, 443

Zygoma, resection of, 225

THE END

Printed by R. & R. Clark, Limited *Edinburgh.*